

First-in-man use of an Indian-made balloon-expandable covered Zephyr stent and intermediate-term follow-up

Pramod Sagar, Thejaswi Puthiyedath, Kothandam Sivakumar

Department of Pediatric Cardiology, Institute of Cardiovascular Diseases, Madras Medical Mission, Chennai, Tamil Nadu, India

ABSTRACT

Covered stent is used in large-vessel angioplasty in anticipation of vessel wall injury. Apart from aortic coarctation, they are also used in dysfunctional right ventricular outflow conduits and find a recent role in transcatheter sinus venosus defect closure. Different methods of covering stents include glue fixation, sutureless lamination, sandwich, and sintering lamination. Covered Zephyr (Sahajanand laser technology limited, Gandhinagar, India) is a new Indian-made expanded polytetrafluoroethylene-covered balloon expandable cobalt-chromium stent. Its unique C and S links prevent foreshortening. We report the first-in-man use of this new stent in severe discrete postsubclavian coarctation of aorta and its short-term follow-up imaging.

Keywords: Coarctation of aorta, cobalt-chromium stent, expanded polytetrafluoroethylene, nonforeshortening stent

INTRODUCTION

Covered stents are recommended for large-vessel stenting when there is a risk of vessel injury. Large balloon-expandable covered stents are used in coarctation, dysfunctional right ventricular outflow tracts, and transcatheter closure of sinus venosus defects.^[1-3] Expanded polytetrafluoroethylene (ePTFE) is used as the cover due to its high strength-to-weight ratio, low friction, biocompatibility, high thermal resistance, long-term stability, and chemically inert qualities. The methods used for making a covering include manual fixation using glue at each end of the stent, sutureless lamination, sandwich lamination, and sintering lamination.^[4] Zephyr™ stent (Sahajanand Laser technology limited, Gandhinagar, India) is a balloon expandable, nonforeshortening cobalt-chromium uncovered stent with proven clinical efficacy and safety.^[5] A new covered stent is made by covering Zephyr with an ePTFE fabric using two-layer sintering lamination

technology. After laser surface activation of the metal surface, two-layered ePTFE is sintered to the surface at a high temperature just below its melting point. We report first-in-man use of this covered Zephyr stent in a case of severe postsubclavian coarctation of the aorta. The Central Drugs Standard Control Organisation sanctioned license for this covered stent.

CASE REPORT

A 42-year-old female, a known hypertensive for 20 years requiring three antihypertensives losartan, bisoprolol, and prazosin, presented with dyspnea on exertion of 2-year duration. She was diagnosed to have a bicuspid aortic valve with severe aortic stenosis and severe postsubclavian coarctation of the aorta. The blood pressure in the right upper limb was 150/78 mmHg with an arm-to-leg gradient of 76 mmHg

This is an open access journal, and articles are distributed under the terms of the Creative Commons Attribution-NonCommercial-ShareAlike 4.0 License, which allows others to remix, tweak, and build upon the work non-commercially, as long as appropriate credit is given and the new creations are licensed under the identical terms.

For reprints contact: WKHLRPMedknow_reprints@wolterskluwer.com

How to cite this article: Sagar P, Puthiyedath T, Sivakumar K. First-in-man use of an Indian-made balloon-expandable covered Zephyr stent and intermediate-term follow-up. *Ann Pediatr Card* 2023;16:48-51.

Access this article online

Quick Response Code:



Website:

www.annalspc.com

DOI:

10.4103/apc.apc_122_22

Address for correspondence: Dr. Kothandam Sivakumar, Department of Pediatric Cardiology, Institute of Cardiovascular Diseases, Madras Medical Mission, 4A, Dr. J J Nagar, Mogappair, Chennai - 600 037, Tamil Nadu, India.

E-mail: drkumarsiva@hotmail.com

Submitted: 06-Oct-2022

Revised: 15-Dec-2022

Accepted: 10-Jan-2023

Published: 04-Apr-2023

by sphygmomanometry. The peak and mean Doppler gradient across the aortic valve were 77 mmHg and 42 mmHg, respectively. The coarctation segment showed peak and mean gradients of 82/40 mmHg. Transcatheter coarctation stenting was planned before surgical aortic valve replacement to facilitate aortic perfusion during extracorporeal circulation. In view of the associated bicuspid aortic valve and ascending aortic dilatation suggestive of degenerative changes in the aortic wall, covered stent angioplasty was chosen. Informed consent was obtained to implant the new stent and the institutional review board approved its use.

Cardiac catheterization from right femoral arterial access demonstrated 64 mmHg peak-to-peak gradient across the discrete coarctation. The narrowest segment measured 6 mm in diameter and the isthmus measured 15.5 mm. After a bench testing, a 48 mm long-covered Zephyr stent was mounted on a 16 mm × 40 mm Z-med balloon (NuMED Inc, Hopkinton, NY) [Figure 1]. The covered stent-balloon assembly was easily advanced through a 12F Mullins sheath (Cook Medical, Limerick, Ireland) and was deployed across the coarctation at 6 atm. There was no stent migration or under-expansion during deployment. There was no residual gradient across the stent, and the aortogram showed no evidence of dissection or perforation [Figure 2].

On follow-up, the blood pressure was well controlled on bisoprolol which was given primarily for aortic root and ascending aortic dilatation. The computed tomography after 8 months showed a fully expanded stent with a diameter of 14 mm (12.5% recoil) and stent length was 46.8 mm suggesting no significant foreshortening (2.5%). There was no pseudoaneurysm or aortic dissection [Figure 3]. Valve surgery was postponed due to asymptomatic status, normal brain natriuretic peptide levels, and normal left ventricular function.

DISCUSSION

Large balloon expandable vascular-covered stents are used when aortic wall injury is anticipated during coarctation stenting.^[1] It is frequently used to prevent and manage conduit rupture during dysfunctional right ventricular outflow tract stenting.^[2] Longer covered stents find a recent role in the new transcatheter management of sinus venosus defects.^[3] The covered Cheatham-Platinum stent (NuMed, Hopkinton, New York) is the most widely used balloon expandable stent available in premounted or nonpremounted versions.^[1] The closed-cell design leads to significant foreshortening at larger diameters. As the ePTFE covering is glued using cyanoacrylate adhesive only at 0° and 180° of both ends and not to each stent strut, the covering may slide over the struts during expansion leading to its malfunction on overstretching in larger vessels.^[6]




Figure 1: Bench testing of a 34 mm covered Zephyr stent (a) on a 22 mm × 4 mm balloon (b) showing good integrity of the ePTFE cover and minimal foreshortening (c) from 34 mm to 31.5 mm (7.4%) and absence of recoil (d). ePTFE: Expanded polytetrafluoroethylene

The Advanta V12 LD (Atrium medical corporation, Merrimack, NH) was introduced as a revolutionary product with ePTFE cover sandwiching both the interior

and exterior of the stent. This attractive attribute unfortunately resulted in significant recoil leading to the recall of large sizes. It also foreshortens on expansion and is currently only available in limited diameters and lengths.^[7] The Optimus-CVS-covered stent (AndraTec GmbH, Koblenz, Germany), covered Andrastent (Andramed GmbH, Reutlingen, Germany), and BeGraft aortic stent (Bentley Innomed, Hechingen, Germany) are three newer balloon expandable, hybrid cell cobalt-chromium covered stents available for human use. They are characterized by an ePTFE cover thermally bonded to all the metal struts of the stent. The last among them is premounted on a balloon. Though they are shown to be effective in coarctation stenting, they show some degree of foreshortening.^[6,8,9]

In comparison to all these foreshortening stents, Zephyr-covered stent is a nonforeshortening balloon expandable stent, where the ePTFE cover is made using a sutureless lamination technology. Covered Zephyr is the first of the kind to be made in India. In this first-in-man experience in coarctation, the stent could be implanted successfully without any complications such as pseudoaneurysm and dissection noted on follow-up computed tomography. On a bench test, the integrity of the fabric was retained even when expanded to 22 mm. The nonforeshortening stent attribute makes the process of stent length selection easier without the need for considering the diameter of the balloon used for its deployment. This is especially true when longer lengths of stents of very large diameters are needed as in transcatheter sinus venosus defect closure.^[10]

CONCLUSION

The new Zephyr-covered stent with an ePTFE cover created using sutureless lamination technology is safe and effective when used to stent aortic coarctation. However, longer follow-up and more data of this first Indian-made large vessel-covered stent are needed. Its utility on other emerging indications, such as sinus venosus defect, also needs to be studied.

Declaration of patient consent

The authors certify that they have obtained all appropriate patient consent forms. In the form, the patient has given her consent for her images and other clinical information to be reported in the journal. The patient understands that her name and initials will not be published and due efforts will be made to conceal her identity, but anonymity cannot be guaranteed.

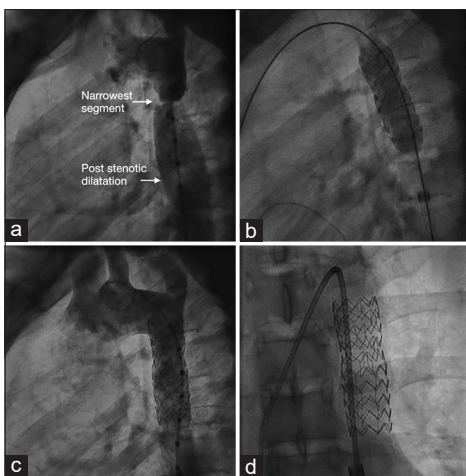


Figure 2: Aortogram in lateral view (a) shows severe postsubclavian coarctation and poststenotic dilatation of descending aorta. After deployment of a 48 mm long covered Zephyr stent on a 16 mm balloon, (b) angiogram with a marker pigtail shows good expansion without foreshortening. (c) Magnified view (d) shows complete stent expansion

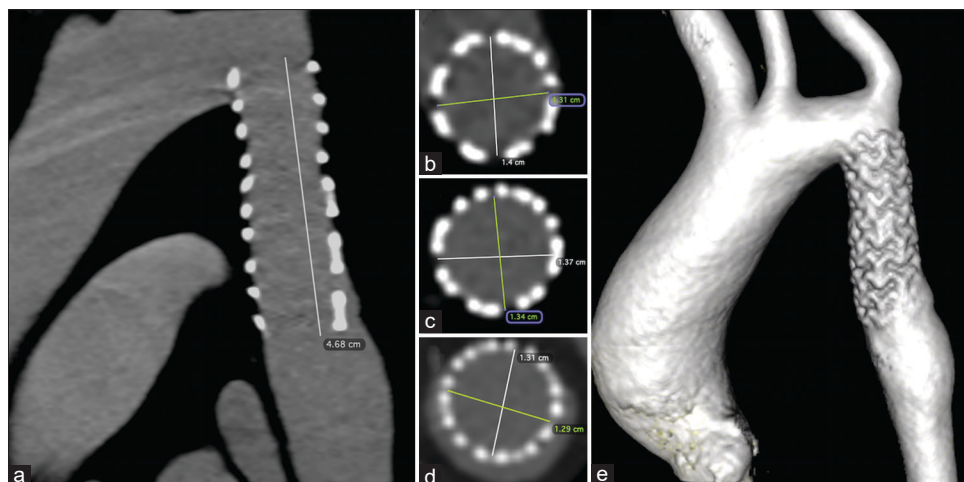


Figure 3: Multiplanar reformatted view shows the stent in the long axis view of the aortic arch (a) on computed tomography at 6-month follow-up. The cross-sectional views at the upper, (b) middle (c), and lower (d) levels and volume rendered image (e) show good opposition of covered stent to the aortic wall without any evidence of pseudoaneurysm. The stent length is 46.8 mm demonstrating negligible foreshortening

Financial support and sponsorship

Nil.

Conflicts of interest

There are no conflicts of interest.

REFERENCES

1. Pedra CA, Peirone AR, Costa RN, Bruckheimer E. Covered-stent implantation in coarctation of the aorta: Indications, materials, techniques and outcomes. *Interv Cardiol* 2011;3:67-78.
2. Delaney JW, Goldstein BH, Bishnoi RN, Bisselou KS, McEnaney K, Minahan M, *et al.* Covered CP stent for treatment of right ventricular conduit injury during melody transcatheter pulmonary valve replacement. *Circ Cardiovasc Interv* 2018;11:e006598.
3. Sivakumar K, Qureshi S, Pavithran S, Vaidyanathan S, Rajendran M. Simple diagnostic tools may guide transcatheter closure of superior sinus venosus defects without advanced imaging techniques. *Circ Cardiovasc Interv* 2020;13:e009833.
4. Vanagt WY, Cools B, Boshoff DE, Frerich S, Heying R, Troost E, *et al.* Use of covered Cheatham-Platinum stents in congenital heart disease. *Int J Cardiol* 2014;175:102-7.
5. Sivakumar K, Anantharaj A, Raghuram P, Krishna Kumar R, Vani P, Neuss M. First in man study of a new semi-open cell design Zephyr cobalt-chromium stent in large vessels and conduits. *Catheter Cardiovasc Interv* 2020;96:367-75.
6. Morgan GJ, Ciuffreda M, Spadoni I, DeGiovanni J. Optimus covered stent: Advanced covered stent technology for complex congenital heart disease. *Congenit Heart Dis* 2018;13:458-62.
7. Bruckheimer E, Birk E, Benson L, Butera G, Martin R, Roberts PA, *et al.* Large diameter Advanta V12 covered stent trial for coarctation of the aorta: COARC study. *Circ Cardiovasc Interv* 2021;14:e010576.
8. Sagar P, Sivakumar K. A covered stent used in aortic coarctation migrates proximally during deployment causing transverse arch obstruction: Transcatheter repositioning after one month. *J Cardiol Cases* 2021;24:23-6.
9. Yilmazer MM, Vuran G, Meşe T, Güven B, Zihni C, Gerçekler E, *et al.* Endovascular treatment of aortic coarctation with a novel BeGraft aortic stent in children and young adults: A single-centre experience with short-term follow-up results. *Cardiol Young* 2022;32:451-8.
10. Rosenthal E, Qureshi SA, Jones M, Butera G, Sivakumar K, Boudjemline Y, *et al.* Correction of sinus venosus atrial septal defects with the 10 zig covered Cheatham-platinum stent – An international registry. *Catheter Cardiovasc Interv* 2021;98:128-36.