

Retrobulbar Optic Nerve Cysticercosis

Sir,

Cysticercosis is the most common parasitic disease involving the central nervous system (CNS). It is caused by infestation of the larval form of *Taenia solium*, with humans being the primary host. Intraocular cysticercosis occurs in 3% of the cases. Optic nerve involvement by cysticercosis is extremely rare, with very few cases in the literature.^[1] A 21-year-old man was referred to our department for computed tomography (CT). He complained of dull headache of the left frontal and temporal region and left ocular pain and mild left orbital swelling and small nodular swelling in left temporal region. The ocular pain was exacerbated with eye movement (ophthalmoplegia). The patient also noted a gradual progressive diminished vision

in the left eye since 1 month. The patient had been treated at an outside hospital with painkillers and steroids, but had experienced no improvement in his symptoms. Direct ophthalmoscopic examination revealed features suggestive of left optic disk edema and congestion. The examination of the right eye was normal. Initial CT was performed in the axial plane with 5-mm contiguous sections followed by 1.25-mm sections. The study revealed an approximately 9-mm cyst located in the mid portion of the left optic nerve [Figures 1 and 2]. A magnetic resonance imaging (MRI) study revealed the lesion to have high T2 signal and to expand the mid portion of the optic nerve in a fusiform manner [Figure 3]. The T1-weighted sequence showed the lesion to be of low signal. The cystic lesion was causing expansion of the nerve with margins of the nerve clearly noted around the cyst. Another small cyst was noted in left temporalis muscle [Figure 4].

Based on the above CT and MRI findings a possibility of cysticercosis was considered. The other possible differential diagnosis of optic nerve glioma, or optic nerve coloboma were also considered. However, the presence of scolex and another similar cystic lesion in temporalis muscle a diagnosis of cysticercosis was considered.

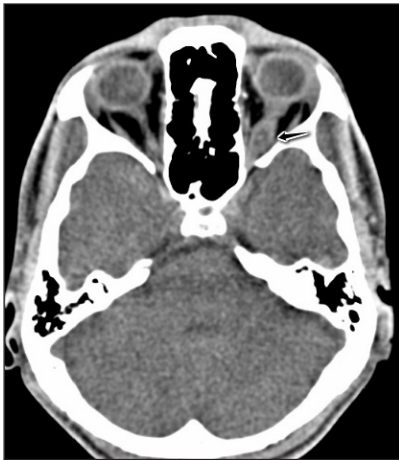

Figure 1: Axial CT section in a 21-year-old patient at the level of optic nerve showing a cyst with mural nodule in the mid portion of left optic nerve (arrow). CT: Computed tomography




Figure 2: Sagittal CT reformations in a 21-year-old patient showing a cyst with mural nodule in the left optic nerve mid portion (arrow)

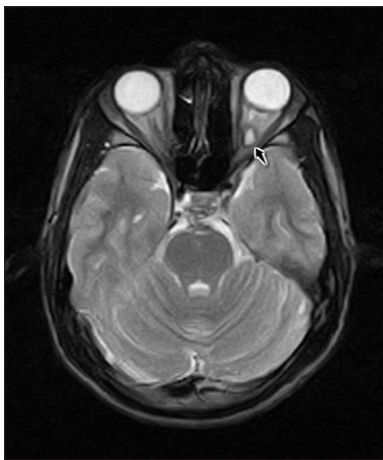


Figure 3: Axial MRI T2W image in 21-year-old patient showing hyperintense cystic lesion in mid portion of left optic nerve (arrow). MRI: Magnetic resonance imaging, T2W: T2-weighted

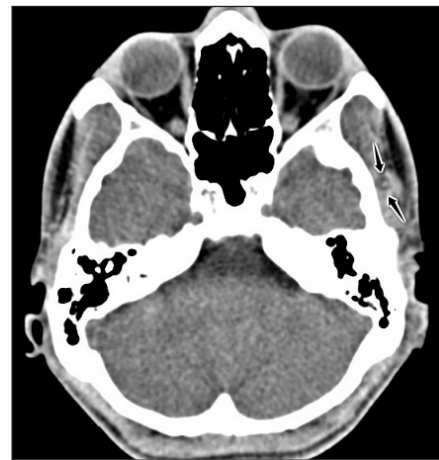

Figure 4: Axial CT in a 21-year-old patient at the level of temporalis muscle showing a cyst with mural nodule in the left temporalis muscle (arrow)

The patient was treated conservatively without histologic confirmation, thereby avoiding a surgical procedure. The patient was treated with a 2-week course of albendazole and prednisolone. There was a substantial improvement in the retinal congestion and edema. A repeat CT done on 30th day showed complete resolution of the lesion.

The diagnosis of cysticercosis is based on clinical, serologic, and imaging findings. The clinical findings and serologic results may occasionally be nondiagnostic. Thus, imaging studies are often helpful in establishing the diagnosis of cysticercosis.^[2]

Four stages are noted in the evolution of cysticercosis: Vesicular, colloidal vesicular, granular nodular, and the nodular calcified stage. The CT and MRI appearances differ with the stage of the disease.^[3] Identification of the cyst and associated scolex is seen in the vesicular stage.^[4] This appearance is strongly suggestive of cysticercosis, especially in endemic regions of the world. The vesicular stage was probably present in our case; our imaging studies revealed a cyst with a mural nodule (scolex). The optic nerve receives its blood supply from a branch of the central retinal artery a branch of ophthalmic artery. Hematogenous spread along the branches of this artery may result in isolated involvement of the optic nerve.

**Ramakrishna Narra,
J Naga Narasimharaju Jukuri¹,
Sushil Kumar Kamaraju²**

*Departments of Radiology, ¹Radiodiagnosis,
²Katuri Medical College, Guntur, Andhra Pradesh, India*

Address for correspondence:

Dr. Ramakrishna Narra, E-mail: narra.ramki29@gmail.com

REFERENCES

1. Madan VS, Dhamija RM, Gill HS, Boparai MS, Souza PD, Sanchete PC, *et al.* Optic nerve cysticercosis: A case report. *J Neurol Neurosurg Psychiatry* 1991;54:470-1.
2. Bonsquet CF, Dufour TF, Derome PC. Retrobulbar optic nerve cysticercosis. Case report. *J Neurosurg* 1996;84:293-6.
3. Teitelbaum GP, Otto RJ, Lin M, Watanabe AT, Stull MA, Manz HJ, *et al.* MR imaging of neurocysticercosis. *AJR Am J Roentgenol* 1989;153:857-66.
4. Rajashekar V, Chandy MJ. Comparative study of CT and MRI in patients with seizures and a solitary cerebral cysticercus granuloma. *Neuroradiology* 1996;38:542-6.

Access this article online

Quick Response Code:



Website:
www.jgid.org

DOI:
10.4103/0974-777X.161743