

Endoscopic holmium laser treatment for ureterolithiasis

Zbigniew Purpurowicz¹, Marek Sosnowski²

¹Department of Urology, Municipal Hospital in Olsztyn, Poland

²I Department of Urology, Medical University of Łódź, Poland

KEY WORDS

holmium laser ► ureterolithiasis ► endourology

ABSTRACT

Introduction. The rapid development and invention of ever more technologically advanced ureterorenoscopes as well as other instruments used in fragmenting ureteral stones have made the traditional surgical treatment of ureterolithiasis very rare.

Material and methods. We investigated 727 patients treated for ureterolithiasis. 769 ureteroscopic lithotripsies (URSL) with the holmium laser were performed. We evaluated the relation of the stone size, the section of the ureter involved, length of time of the stone within the ureter and the condition of the urinary tract to the results of the ureterolithiasis treatment.

Results. A good result of breaking up the stone and passing its fragments out of the ureter within 3 months following the first URSL was observed in 642 (90.9%) out of 706 patients. The remaining 64 (9.1%) patients required additional procedures: ESWL was performed on 44 patients; URSL was repeated for 20 patients. The most serious early post-URSL complications involved: urinary tract infection with symptoms of urosepsis in 10 patients, leading to death in 1 case, ureteral perforation in 3 patients, including 1 case presenting a peri-ureteral leak that necessitated a surgical intervention.

Conclusions. URSL with the holmium laser is an effective and safe method for treating ureterolithiasis.

INTRODUCTION

A safe, effective, and visually controlled method for entering the upper urinary tract was possible due to the development of rigid, semi-rigid, and flexible ureterorenoscopes of even smaller diameters. Improvement with respect to procedural techniques and more effective devices for fragmenting calculi increased URSL effectiveness [1]. The method chosen for fragmenting stones affects the treatment results concerning lithiasis. Following the utilization of electrohydraulic, ultrasound, and pneumatic lithotripsy, laser energy has been introduced as a means of fragmenting stones.

In 1986 Watson and Wickham presented the results of fragmenting stones with a pulsed dye laser [2]. This method was evaluated as safe and effective in ranges from 78% to 88%. The limitations concerning its application were connected with the very high cost of the laser, as was the case with the alexandrite laser introduced in 1991.

The latest laser type, successfully used to fragment stones, is the holmium YAG (Ho: YAG) laser [3, 4]. This laser emits pulsed energy at a wavelength of 2100 nm, and its action is primarily based on the ther-

mal effect. This energy overheats the water, forming a microscopic vapor bubble near the tip of the laser fiber. The collapse of the vapor bubble creates a shock wave that breaks up the stone. Additionally, the energy absorbed by the stone leads to its photothermal, chemical decomposition (chemical bonds are broken) [5]. The overheated zone is very small (0.5 mm) and perfectly controlled. The precise placement of the fiber tip in direct contact with the stone prevents damage to the ureteral wall. Recently, the employment of holmium laser lithotripsy has become more and more common [6, 7, 8].

The aim of this paper is to present our experiences and the results of ureterolithiasis treatment with the holmium laser.

MATERIAL AND METHODS

The study group consisted of 402 males and 325 females with ureterolithiasis, ranging in ages from 17 to 85 years (average age 51). Indications for the procedure included: stones that were unlikely to pass spontaneously (stones >7 mm), colic pain resistant to conservative therapy, permanent hydronephrosis, and renal failure (kidney injury, bilateral hydronephrosis, one kidney). ESWL was not performed when ureterolithiasis was diagnosed. Due to its limited availability in our center, this procedure was reserved for treating nephrolithiasis. All 727 patients underwent URSL in the hospital between May 2002 and December 2008, under spinal or intravenous general anesthesia. Patients received IV ciprofloxacin prior to the procedure as anti-inflammatory prophylaxis. After a complication-free procedure, the antibiotic treatment was continued orally for 5 days.

In 387 patients the stone was detected on the left-hand side, in 332 on the right-hand side, and in 8 cases bilaterally. The stone locations were as follows: upper ureter – 236 patients, middle – 118, and lower – 374. The calculi sizes were estimated on the basis of plain abdominal X-ray images, the average size being 10.1 mm (from 5 mm to 22 mm). All procedures were performed with a 7.2 F semi-rigid ureterorenoscope. The dilatation of the ureteral orifice was not performed routinely. Fluoroscopic control was not applied during the procedures.

A ureterorenoscope was passed into the ureter with the use of a guide wire. The guide wire was removed after reaching the calculus and obtaining good visualization. Then the 365-micron fiber connected to the laser (Ho: YAG Laser Variopulse HL, wavelength of 2120nm, power level of 25W) was inserted through the endoscope's working channel. During this procedure we used an impulse energy ranging from 100 to 3000 mJ, and a frequency from 1 to 20 Hz. Fragmenting the stone with the holmium laser requires a clear view because the tip of the laser fiber should be aimed at the stone. Pointing it at the ureteral wall can lead to its injury. The laser fiber can be also "laid" on the stone but the fiber tip must be directed into the ureteral lumen. When it was found difficult to locate the stone, a technique called the "Jeromin maneuver" (the assistant presses the patient's abdominal wall down or laterally with his hand, facilitating straightening of the ureter and improving the view) was very helpful [9]. Fragments of broken stones >5 mm were evacuated by a Dormia basket under visual control.

In 388 (54.9%) patients a double J (D-J) stent was left in the ureter after the performed URSL procedure. Indications for leaving the D-J stent included: risk of complications mostly connected with residual lithiasis and cases of bleeding, ureteral perforation, and decubitus caused by the stone.

Stones that migrated to the kidney during URSL were later treated with extracorporeal shock wave lithotripsy (ESWL). Percutaneous nephrostomy (PCN) was performed before URSL in 67 (9.4%) patients for the following reasons: urinary system infection with hydronephrosis, insufficient kidney with urinary retention, very large impacted stones (for several months), and numerous ureteral stones. Such a large number of nephrostomies resulted from a large number of patients with hydronephrosis accompanied with symptoms of generalized infection.

The first routine post-hospital follow up visit was scheduled 2 weeks following URSL, the next one after 3 months, and periodical visits within 2 years if the patient presented urological problems. During control visits USG and X-ray of the urinary system were performed. Urography was carried out before or after the procedure only in selected cases.

RESULTS

In 21 patients the stone was not reached during the first ureterorenoscopy (URS). In this sub-group the URSL procedure was repeated in 20 patients, and in 1 case it was carried out 3 times. Three patients underwent open ureterolithotomy due to the absence of desired effects.

Table 1 presents the effectiveness of URSL with the holmium laser in the group of 706 patients in whose case the stones were reached during the first URS procedures. A positive effect after the first URSL, involving breaking up the stone and the complete passing of its fragments from the ureter during 3 months after the procedure, occurred in 642 (90.9%) patients. The result was defined as positive if stone fragments of 2-3 mm created as the result of the lithotripsy were passed spontaneously; if after 3 months stone fragments still remained in the urinary tract it was regarded as a failure (negative result).

Sixty-four (9.1%) out of 706 patients required additional procedures. Due to the migration of the stone to the kidney, ESWL was performed in 44 (5.66%) patients. URSL was repeated in 20 (2.97%) patients from this group. The main causes for the repeated URSL were numerous stones or stones that were too large >2 cm. Eight patients underwent successful, complication-free, simultaneous bilateral URSL.

In 47 (6.65%) patients small stone fragments created during laser lithotripsy were extracted with the Dormia basket.

The average time of the URSL procedure was 38.4 minutes, the longest procedure lasted 130 minutes, and the shortest one took 10 minutes.

The procedure's effectiveness depended on stone size. Among 10 patients with stones up to 5 mm in diameter, the success rate was 100%. Among 120 patients with stones ranging from 5 to 7 mm, effectiveness amounted to 98.33%. Among 204 patients with stones ranging from 7 to 9 mm, effectiveness reached 94.11%.

Table 1. Effectiveness after single URSL

Location	Patients	Positive	Negative
Upper	223	190 (85.2%)	33 (14.8%)
Middle	112	97 (86.6%)	15 (13.4%)
Lower	371	355 (95.7%)	16 (4.3%)
Total	706	642 (90.9%)	64 (9.1%)

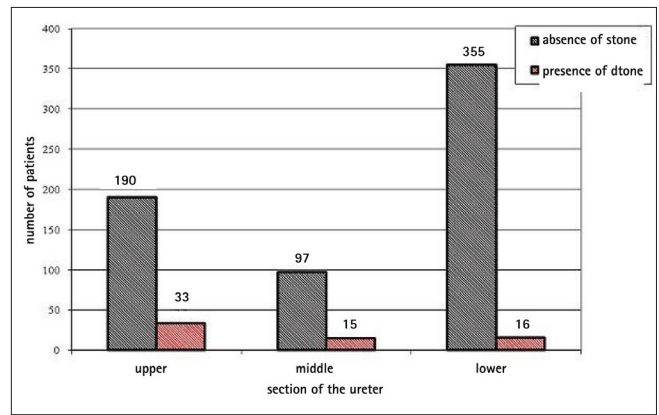


Fig. 1. URSL effectiveness depending on the section of the ureter involved.

Among 192 patients with stones ranging from 9 to 11 mm, the success rate was 92.70%. Among 110 patients with stones ranging from 11 to 13 mm, effectiveness amounted to 80%. Among 42 patients with stones ranging from 13 to 15 mm, effectiveness was 85.71%. Among 28 patients with stones >15 mm, the success level was 71.42%.

Stone location within the ureter significantly affected the success rate of the procedure. The highest effectiveness of 95.7% was obtained in the distal section. In the middle and proximal sections the success rates were 86.6% and 85.2%, respectively.

The length of time concerning the presence of the stone within the ureter also impacted on the procedure's effectiveness. The most effective procedures were observed when the stone was in the ureter for a relatively short period of time up to 10 days, with a success rate of 92.9%. When the stone was in the ureter between 3-4 weeks, effectiveness amounted to 91.6%. If the stone was in the ureter >30 days, effectiveness decreased to 84%.

Urinary retention in the urinary tract influenced the effectiveness of the procedure as well. Stones were removed in 85.6% of cases in 436 patients with dilated urinary tract, and success was observed in 99.6% of the 270 patients without dilatation.

Effectiveness of the procedure in patients with the placed ureteral stent amounted to 85.6%; whereas, in patients without the stent it was significantly higher and reached 97.5%.

URSLs were always performed after controlling the patients against urinary infection; consequently the infection factor had no impact on the result of lithotripsy.

Complications were divided with respect to the time of development and seriousness involved.

Major early complications included: urinary tract infection with symptoms of sepsis in 10 patients (1.41%), ureteral injury with urine and fluid leak treated surgically in 1 patient (0.14%), incarceration of the guide wire and basket in the ureter in 2 patients (0.28%), ureteral perforations with insignificant urine leakage successfully repaired with a double J stent in 2 patients (0.28).

Early mild complications occurred in 15 patients (2.1%) and included minor damage to the ureteral wall that did not require URSL to be aborted.

Delayed major complications involved: stenosis of the ureteral lumen that necessitated surgical treatment in 3 patients (0.42), and stenosis of the ureteral lumen that required endoscopic treatment in 7 patients (0.99%). In the group of delayed mild complications we observed recurring urinary infections in 34 patients (4.8%).

Summing up, serious complications amounted to 3.54% of the total number of complications. They occurred mostly in the initial period of introducing URSL procedures as hospital treatment.

Table 2. Effectiveness of laser lithotripsy depending on stone size

Effectiveness of laser lithotripsy	Stone size in mm															
	up to 5		(5-7>		(7-9>		(9-11>		(11-13>		(13-15>		larger than 15		Total	
	n	%	n	%	n	%	n	%	n	%	n	%	n	%	n	%
Absence of stone	10	100	118	98.3	192	94.1	178	92.7	88	80	36	85.7	20	71.4	642	90.9
Presence of stone	0	0	2	1.7	12	5.9	14	7.3	22	20	6	14.3	8	28.6	64	9.1
Total	10	100	120	100	204	100	192	100	110	100	42	100	28	100	706	100

Table 3. Effectiveness of laser lithotripsy depending on the stone's length of time within the ureter

Effectiveness of laser lithotripsy	Stone's length of time within the ureter							
	up to 10 days		10 to 20 days		20 days and longer		total	
	n	%	n	%	n	%	n	%
Absence of stone	222	92.9	336	91.6	84	84	642	90.9
Presence of stone	17	7.1	31	8.4	16	16	64	9.1
Total	239	100	367	100	100	100	706	100

Table 4. Effectiveness of laser lithotripsy depending on urinary retention

Effectiveness of laser lithotripsy	Condition of the urinary tract – presence of urinary retention					
	present		absent		total	
	n	%	n	%	n	%
Absence of stone	373	85.6	269	99.6	642	90.9
Presence of stone	63	14.4	1	0.4	64	9.1
Total	436	100	270	100	706	100

The average hospitalization period following URSL was 2 days in patients presenting no complications, and 6.5 days in patients who developed complications.

DISCUSSION

Electrohydraulic, ultrasound, pneumatic and laser lithotripsy can be used to break up stones. Laser lithotripsy was introduced as the last of these methods at the beginning of the 1990s [3, 4].

Laser energy is effective for fragmenting all types of calculi. Laser energy directed at stones produces tiny fragments that can then be passed spontaneously. In the first reports (Matsuoka et al. 1995, Denstedt et al. 1995) the effectiveness and safety of this method were emphasized [4, 11]. This is due to the precision connected with the good visualization of stones and the full control of the tip of the laser fiber that can be safely and precisely aimed at the stone. The utilization of narrow fibers to transmit laser energy enabled the design of miniature ureteroscopes, thus decreasing the risk of ureteral injury. According to Gupta, the combination of a narrow ureteroscope with a holmium laser is the ideal system to treat ureterolithiasis [12]. Teichman et al. demonstrated that out of all methods available it is the holmium laser that breaks up stones into the smallest fragments [13]. Currently it is believed that the effectiveness of URSL is comparable to the results of fragmenting ureteral stones using electrohydraulic and pneumatic energy as well as ESWL.

Factors affecting safety and effectiveness of intraureteral fragmentation of stones by endoscopic techniques include: stone size, its location and length of time within the ureter, infection and urinary retention, type of instrument used and the operator's experience.

In our material we obtained a success rate at a level of 90.9% after a single URSL procedure. This is consistent with published results reported by other centers performing holmium laser lithotripsy [6, 7, 8, 14-18].

The highest, almost 100%, effectiveness was obtained in the case of stones smaller than 10 mm in diameter, located within the lower ureter. Effectiveness decreased alongside with the increase of the stone diameter, its location within the upper sections of the ureter, longer period within the ureter, and the presence of urinary retention.

URSL effectiveness with respect to stone diameter was, respectively: 100% for a diameter up to 5 mm, 92.7% for diameters ranging from 9 to 11 mm, and it clearly decreased to 71.42% for stones larger than 15 mm in diameter. Biyani et al. similarly described the occurrence of stone size as the negative factor influencing URSL success [19]. Stone location within the ureter was also significant to the procedural result. The highest effectiveness of 95.7% was achieved for lower ureteral stones. Effectiveness decreased the higher the stone was located and was, respectively: 86.6% for the middle ureter and 85.2% for the upper ureter. Two factors are decisive with respect to successful URSL in the upper ureter: stone accessibility and stone migration to the pyelocaliceal system during lithotripsy [20, 21]. URSL effectiveness of 85.2% achieved by us for upper ureteral stones is consistent with the results reported by other centers. Kijviakai, Haleblan, Preminger, and Rosette reviewed and analyzed results reported in the literature for URSLs performed in the upper ureter between 1997-2005. Holmium laser effectiveness ranged from 80.5% to 100% [22]. Bagley reported 100% effectiveness of URSL in the upper ureter. Procedures were carried out using a flexible ureteroscope [23, 24]. What we found extremely interesting with respect to fragmenting upper ureteral

stones using URSL is that the effectiveness of the procedure was higher for stones of a diameter larger than 13 mm. Most probably it was connected with the fact that they were less likely to migrate to the renal pyelocaliceal system.

The length of time concerning the presence of the stone within the ureter was an additional factor that decreased URSL effectiveness. No significant differences were observed for a period shorter than 10 days (success level of 92.9%), and not exceeding 4 weeks (91.6%). Effectiveness evidently decreased when the stone was present within the ureter longer than 30 days and then success amounted to 84%. This was connected with a more obstructed view of the stone resulting from the mucosal edema.

In more than half of patients (54.9%) who underwent URSL, D-J stent was left after the procedure. This occurred in the case of patients at high risk of renal colic due to the size of the fragmented residual stones. Before the procedure patients had been informed about the possibility of such treatment and potential subsequent problems. Cevik et al. evaluated the necessity of leaving the ureteral catheter. They did not recommend doing this routinely after a complication-free URSL [25].

The safety of holmium laser lithotripsy is proven by the small percentage of serious complications, which reached 3.54% in our study. In the early period complications included: ureteral perforation – 3 cases, i.e., 0.42%; in the delayed period: ureteral stenosis – 10 patients, i.e., 1.41%. These results do not differ from those reported in the literature [7, 12, 15]. Other serious complications included: incarcerated basket (1 patient – 0.14%), guide wire looping (1 patient – 0.14%), and 10 (1.41%) cases of acute urinary tract infection with symptoms of urosepsis (1 patient died but this was not caused directly by the performed procedure).

CONCLUSIONS

Endoscopic holmium laser treatment for ureterolithiasis is a safe and effective method. A narrow laser fiber facilitates using narrow ureterorenoscopes that can reach the stone far easier. Ureterorenoscopes of a small diameter do not damage the mucous membrane lining the ureter, thus not leading to its stenosis. The holmium laser is effective for all types of stones and crushes them into small fragments. When used skillfully, the holmium laser does not cause upward migration of the stone. The effectiveness of URSL with the use of the holmium laser depends mostly on stone size, its location and length of time within the ureter as well as on the urologist's experience.

REFERENCES

- Netto NR Jr, Lemos GC, D'Ancona CAL, et al: *Is routine dilatation of the ureter necessary for ureteroscopy?* Eur Urol 1990; 17: 269-272.
- Watson GM and Wickham JEA: *Initial experience with a pulsed dye laser for ureteric calculi.* Lancet 1986; 1: 1357-1361.
- Sayer J, Johanson DE, Price RE, et al: *Ureteral lithotripsy with the holmium: YAG laser.* J Clin Laser Med Surg 1993; 11: 61-65.
- JD, Razavi HA, Sales JL and Eberwein PM: *Preliminary experience with holmium: YAG laser lithotripsy.* J Endourol 1995; 9: 257-259.
- Vassar GJ, Chan KF, Teichman JMH, et al: *Holmium: YAG lithotripsy: Photothermal mechanism.* J Endourol 1999; 13: 181-190.
- Humański P, Dykczyński P: *Leczenie w przypadkach kamicy moczowodowej energią lasera holmowego na oddziale urologii jednego dnia.* [Application of holmium energy for desintegration of ureteral stones in an outpatient setting]. Urol Pol 2008; 61: 21-24.
- Nuttall MC, Abbaraju J, Dickinson IK, Sriprasad S: *A review of studies reporting on complications of upper urinary tract stone ablation using the holmium: YAG laser.* Br J Med Surg Urol 2010; 3: 151-156.
- Gerber GS, Acharya SS: *Management of Ureteral Calculi.* J Endourol 2010; 24: 953-954.
- Jeromin L, Sosnowski M: *Ureteroscopy in the Treatment of Ureteral Stones: Over 10 Years Experience.* Eur Urol 1998; 34: 344-349.
- Gurbuz ZG, Gonen M, Fazlioglu A, Akbulut H: *Ureteroscopy and pneumatic lithotripsy, followed by extracorporeal shock wave lithotripsy for treatment of distal ureteral stones.* Int J Urol 2002; 9: 441-444.
- Matsuok A, Iida S, Nakanami M, et al: *Holmium: yttrium-aluminum-garnet laser for endoscopic lithotripsy.* Urology 1995; 45: 947-951.
- Gupta PK: *Is the Holmium:YAG laser the Best Intercorporeal Lithotripter for the Ureter? A 3-Year Retrospective Study.* J Endourol 2007; 21: 305-309.
- Teichman JMH, Vassar GJ, Bishoff JT, et al: *Holmium: YAG lithotripsy yields smaller fragments than pulsed dye, Lithoclast or electrohydraulic lithotripsy.* J Urol 1998; 159: 18-27.
- Cheung MC, Lee F, Yip SKH, et al: *Outpatient holmium laser lithotripsy using semirigid ureteroscope.* Eur Urol 2001; 39: 702-708.
- Weimin Yu, Fan Cheng, Xiaobin Zhang, et al: *Retrospective treatment of upper ureteral stones: A 5-year retrospective study.* J Endourology 2010; 24: 1753-1757.
- Babpat Shivedeo S, Pai Ketan V, Purnapartre S, et al: *Comparison of holmium laser and pneumatic lithotripsy in managing upper-ureteral stones.* J Endourology 2007; 21: 1425-1427.
- Pearle MS, Nadler R, Bercowsky E, et al: *Prospective randomized trial comparing shock wave lithotripsy and ureteroscopy for management of distal ureteral calculi.* J Urol 2001; 166: 1255-1260.
- Jiang H, Wu Z, Ding Q, Zhang Y: *Ureteroscopic treatment of ureteral calculi with holmium: YAG laser lithotripsy.* Endourol 2007; 21: 151-154.
- Biyani CS, Cornford PA, Powel CS: *Ureteroscopic holmium lasertripsy for ureteric stones.* Scand J Urol Nephrol 1998; 32: 92-93.
- Lee H, Ryan RT, Teichman JMH, et al: *Stone Retropulsing During Holmium:Yag Lithotripsy.* J Urol 2003; 169: 881-885.
- Marquet CG, Sung JC, Springhart WP, et al: *In vitro comparison of stone retropulsion and fragmentation of the frequency doubled, double pulse ND: YAG laser and holmium: YAG laser.* J Urol 2005; 173: 1797-1800.
- Kijviakai K, Haleblan GE, Preminger GM, de la Rosette J: *Shock wave lithotripsy or ureteroscopy for the management of proximal ureter calculi: An old discussion revisited.* J Urology 2007; 178: 1157-1163.
- Tawfik ER, Bagley DH: *Management of upper urinary tract calculi with ureteroscopic techniques.* Urology 1999; 53; 1: 25-31.
- Bagley DH: *Expanding role of ureteroscopy and laser lithotripsy for treatment of proximal ureteral and intrarenal calculi.* Curr Opin Urol 2002; 12: 277.
- Cevik I, Diloglugil O, Akdas A, Siegel Y: *Is stent placement necessary after uncomplicated ureteroscopy for removal of impacted ureteral stones?* J Endourol 2010; 24: 1263-1267.

Correspondence

Zbigniew Purpurowicz
Department of Urology
Municipal Hospital
44, Niepodległości Street
10-200 Olsztyn, Poland
phone: +48 89 532 62 75
purp8@wp.pl