



Epidemiology, Pathogenesis, and Diagnosis of Cardiac Sarcoidosis

REVIEW

SHEETAL V. MATHAI, MD

SNEHAL PATEL, MD

ULRICH P. JORDE, MD

YOGITA ROCHLANI, MD

**Author affiliations can be found in the back matter of this article*

HOUSTON
Methodist[®]
DEBAKEY HEART &
VASCULAR CENTER

ABSTRACT

Cardiac sarcoidosis (CS) is a widely underdiagnosed yet clinically significant form of granulomatous myocarditis associated with significant morbidity and mortality. Clinical presentation ranges from silent cardiac involvement detected on imaging to cardiomyopathy or sudden cardiac death. Diagnosis of CS remains challenging due to the lack of sensitivity and specificity of any single diagnostic method, underscoring the importance of elevated clinical suspicion and the use of multimodality imaging to guide diagnosis and treatment. In this review, we discuss the epidemiology, pathogenesis, clinical features, and diagnosis of this clinically evading and enigmatic disease.

CORRESPONDING AUTHOR:

Yogita Rochlani, MD

Division of Cardiology,
Montefiore Medical Center
and Albert Einstein College of
Medicine, Bronx, New York, US

yrochlani@montefiore.org

KEYWORDS:

cardiac sarcoidosis; cardiac
FDG-PET; granulomatous
myocarditis; inflammatory
cardiomyopathy

TO CITE THIS ARTICLE:

Mathai SV, Patel S, Jorde UP,
Rochlani Y. Epidemiology,
Pathogenesis, and Diagnosis
of Cardiac Sarcoidosis.
Methodist DeBakey Cardiovasc
J. 2022;18(2):78-93. doi:
10.14797/mdcvj.1057

INTRODUCTION

Sarcoidosis is a multisystem granulomatous disease of unclear etiology that typically affects individuals between 25 and 60 years of age and is more common in women.¹ The underlying cause is not entirely understood, but theories suggest that, in genetically susceptible individuals, an unknown antigenic trigger sets off an inflammatory cascade that results in granulomatous inflammation followed by fibrosis and scarring in some individuals.¹ Environmental and genetic factors impact disease development and progression, resulting in geographic and racial differences in the prevalence and outcomes of affected patients.¹ Although sarcoidosis can involve any organ system, it affects the lungs and thoracic lymph nodes in 90% of cases.² Approximately 5% of patients have clinically manifest cardiac involvement, often presenting as conduction system abnormalities, ventricular arrhythmias, or cardiomyopathy, while asymptomatic cardiac involvement has been reported in up to 25% of cases.²

Diagnosis of cardiac sarcoidosis (CS) remains challenging as it requires a combination of clinical and radiological findings in addition to histologic evidence of noncaseating granulomas with exclusion of any other potential causes of such histologic findings.³ While its overall course depends on the organ systems involved, cardiac involvement is a prominent driver of morbidity and mortality. The prevalence of CS has been increasing over the past two decades, likely due to utilization of advanced cardiac imaging.⁴ However, CS continues to remain underdiagnosed as a reversible cause of cardiomyopathy and arrhythmias. In this review, we discuss the epidemiology, pathogenesis, clinical features, and diagnosis of CS with the purpose of increasing awareness about this disease since timely diagnosis and treatment can lead to better outcomes.

EPIDEMIOLOGY

The incidence and prevalence of sarcoidosis varies widely across the globe and has been reported to be higher in populations of northern European and African American descents.¹ The highest incidence has been reported in Scandinavian countries, with an estimated 11.5 cases per 100,000 individuals. In the United States (US), it ranges from 8 to 11 per 100,000 people and is reported to be lower in other parts of the world, including Canada (6.8 per 100,000) and East Asian countries such as South Korea (0.5-1.3 per 100,000).⁵ Similarly, reported prevalence ranges from 140 to 160 per 100,000 in Sweden and Canada, to 1 and 5 per 100,000 in South Korea, Taiwan and Japan.⁵ A US national healthcare database analysis between 2010 and 2013

revealed a three-times higher prevalence among Black Americans (141.4 per 100,000) compared with Whites (49.8 per 100,000), and a lower prevalence in Hispanics and Asians (21.7 vs 18.9 per 100,000, respectively). The highest prevalence was noted among Black American women (178.5 per 100,000).⁶ The Black Women's Health Study estimated the average annual incidence among Black American women to be as high as 71 per 100,000 and a prevalence of nearly 2%.⁷ Mortality also is reported as higher among women and Black Americans.⁸

The lung is the most commonly involved organ system, occurring in more than 90% of patients with sarcoidosis,⁹ followed by extra-thoracic sites such as lymph nodes, skin, heart, spleen, liver, and other organs and tissues.³ Disease usually occurs in patients aged 25 to 45 years, with a second peak occurring in women > 50 years in Japan and European countries.^{3,10}

Cardiac involvement can occur with multisystem sarcoidosis or may be the initial and only manifestation of the disease. Studies estimate 5% of patients with sarcoidosis have clinically manifest CS and up to a third have clinically silent disease as detected in imaging and autopsy studies.^{2-4,11,12} Moreover, up to half of the cases of cardiac involvement might present as isolated CS.⁴ Prevalence of CS has increased over the years as evidenced by studies in Finland showing a greater than 20-fold increase in detection between 1988 and 2012.⁴ Similarly, the US rate of transplantation for CS increased from 0.1% to 0.5% between 2011 and 2014.¹³ Use of advanced imaging modalities that aid prompt detection of CS potentially elucidates this increasing prevalence.

PATHOGENESIS

Although the inciting antigenic trigger is yet to be identified, several factors are implicated in the pathogenesis of CS, including genetic susceptibility coupled with immune dysregulation, prior history of infections, and occupational or environmental factors. Human leukocyte antigen (HLA) alleles in the major histocompatibility complex gene are influential in the disease's course. For example, HLA-DR17(3) is most associated with sarcoidosis in a White population, DRB1*03 is associated with spontaneous resolution, and HLA-DR15(2) or DR14(6) are associated with a chronic disease course.¹⁴ Implicated infectious agents include mycobacteria, *Propionibacterium*, *Borrelia burgdorferi*, *Rickettsia helvetica*, Epstein-Barr virus, and human herpes virus 8.¹⁵ Workers in lumbering and wood processing industries who are exposed to industrial organic dust showed elevated risk of sarcoidosis.¹⁶ Further clues on the role of environmental agents are drawn from observations

indicating an increased incidence of sarcoidosis-like granulomatous pulmonary disease in World Trade Center survivors.^{17,18}

Formation of discrete noncaseating granulomas consisting of epithelioid histiocytes and multinucleated giant cells surrounded by lymphocytes, plasma cells, and fibroblasts is the histological hallmark of sarcoidosis.¹⁹ The multinucleated giant cells are initially foreign body type (with haphazardly arranged nuclei) and later become Langhans type (with peripherally arranged nuclei). They may contain cytoplasmic inclusions, particularly Schaumann bodies or asteroid bodies.²⁰ The immunological basis responsible for sarcoid generation is primarily driven by an exaggerated TH1 cell response with production of cytokines, including interleukin (IL)-2, interferon, and IL-12.^{20,21} This is followed by an anti-inflammatory TH2 type response marked by the presence of IL-4, IL-5, IL-10, and IL-13 cytokines.²⁰ Interestingly, the development and disappearance of cardiac granulomas parallels the presence of these cytokines in the specified order.²² Fibrotic transformation of chronic granulomas is mediated by the switch to TH2 type response with contribution from platelet-derived growth factor-B, insulin-like growth factor 1, and insulin-like growth factor binding protein-related protein 2.^{20,23} Recent studies also demonstrate the role of Th17 cell mediated production of IFN- γ in pathogenesis of sarcoidosis and suggest imbalances in Tregs and Th17 cell response to be an added mechanism.^{23,24}

In CS, myocardium is usually involved with endocardium or epicardium as an extension of the disease.^{19,20,25} Granulomas are frequently found in the basal interventricular septum, left ventricular (LV) free wall, right ventricle, and atria.²⁶⁻²⁹ With disease progression, the granulomatous inflammation elicits a repair response with scarring, different from the scarring seen in myocardial infarction, which is patchy rather than maximal in the subendocardial region or transmural.²⁰ While distribution of granulomas in the interventricular septum results in conduction blocks that may be responsive to steroid therapy, patchy myocardial scarring provides a nidus for ventricular tachyarrhythmias, focal aneurysms, and systolic or diastolic LV dysfunction.

CLINICAL FEATURES OF CARDIAC SARCOIDOSIS

Cardiac sarcoidosis can present as (1) asymptomatic disease incidentally detected on screening in the setting of pulmonary/systemic sarcoidosis, (2) clinically manifest CS along with symptomatic or asymptomatic extra-CS, or (3) isolated CS. The cardinal manifestations of CS include high-

grade atrioventricular (AV) blocks, ventricular tachycardias (VT) potentially resulting in sudden cardiac death (SCD), and cardiomyopathy. Rarer presentations include atrial arrhythmias, papillary muscle dysfunction and mitral regurgitation, constrictive pericarditis, pericardial effusion, or mimics of myocardial ischemia.^{20,29,30} Consequently, patients present with a history of dizziness, near-syncope or syncope, palpitations, fatigue, dyspnea, or other symptoms of congestive heart failure (HF).

Conduction abnormalities are the most common clinical manifestation of CS (12-62% of patients) and can present as bundle branch blocks (right or left), AV blocks of varying degrees, or even sinus arrest.³⁰ These result from direct granulomatous inflammation of the septum involving the conduction system. Sustained or nonsustained VT has been reported in 2% to 42% patients with CS, while SCD may present in 12% to 65%.³⁰ The most common mechanism of VT is re-entry from scar formation, while some studies also point to a role of active inflammation.^{31,32} Due to the patchy nature of the myocardial inflammatory process, multiple morphologies of VT also may be present. Occurrence of frequent premature ventricular contractions or polymorphic VT raises suspicion for active inflammation.³¹ VT often is the first manifestation of CS and predicts mortality.³²

CS cardiomyopathy has a prevalence of 10% to 30% and can manifest as left, right, or biventricular-systolic or diastolic dysfunction in the early inflammatory or late fibrotic stages.^{30,31} Granulomatous infiltration of the myocardium can result in wall motion abnormalities in a noncoronary distribution, valvular regurgitation, LV dysfunction, LV wall thinning, aneurysmal dilation, scarring, or wall rupture. Moreover, reduced ventricular compliance from LV stiffening leads to diastolic dysfunction. Right ventricular (RV) dysfunction can result from granulomatous inflammation or more commonly as a consequence of LV dysfunction and sarcoid-induced pulmonary hypertension.²⁹ One study showed a 3% incidence of HF in CS, twice that of the general population. Moreover, HF at presentation or RV involvement is associated with poor clinical outcomes.^{4,33,34}

DIAGNOSIS OF CS

Diagnosis of CS is clinically challenging due to the lack of sensitivity or specificity of any modality in isolation. Hence, multiple diagnostic tests need to be interpreted with the clinical context in mind. Tissue histology using endomyocardial biopsy remains the gold standard for definitive diagnosis. Advanced cardiac imaging techniques such as cardiac magnetic resonance (CMR) imaging and ¹⁸fluorine-fluorodeoxyglucose-positron emission tomography

(FDG-PET) have emerged as invaluable tools to aid disease detection as well as follow disease activity and response to treatment. Here we describe findings associated with CS on various testing modalities.

BASIC CARDIAC EVALUATION

EKG FINDINGS

Abnormalities on electrocardiography prompting suspicion and further imaging for CS include right bundle branch block, advanced or complete AV blocks, and ventricular arrhythmias, including ventricular tachycardia or fibrillation.³¹ Other nonspecific electrocardiogram (EKG) changes hinting at cardiac involvement in patients with sarcoidosis are axis deviation, abnormal Q waves (pseudoinfarct pattern), and ST changes in noncoronary patterns.^{31,35} VT can be the only presentation in sarcoidosis³⁶ and can predict onset of heart failure in CS patients.³⁷

ECHOCARDIOGRAPHY

Echocardiography plays an important role in screening for CS but has low sensitivity and specificity as a diagnostic tool.³⁸ The most specific finding on echocardiography is basal ventricular septum thinning included as part of the Japanese Circulation Society (JCS) diagnostic criteria.³⁵ It is defined as the thinning of the ventricular septum at 10 mm below the aortic annulus and/or the ratio of this measure to the thickness of the normal ventricular septum of ≤ 0.6 .³⁵ Other commonly reported abnormalities include ventricular aneurysm formation, myocardial thickening from edema or infiltration mimicking myocardial hypertrophy, unusual wall motion abnormalities in noncoronary patterns, and papillary muscle dysfunction.^{38,39} Moreover, echocardiography may also determine left atrial dysfunction, pulmonary hypertension, RV dysfunction, and the degree of diastolic dysfunction.^{38,40} Speckle tracking echocardiography can potentially enhance the yield of screening. A recent meta-analysis highlighted the utility of global longitudinal strain (GLS) imaging in predicting subclinical myocardial involvement and major cardiac events.⁴¹

BIOMARKERS

Established markers of systemic sarcoidosis such as angiotensin converting enzyme (ACE) can be elevated in CS.⁴⁰ Moreover, several known cardiac markers such as atrial natriuretic peptide, brain natriuretic peptide (BNP), high-sensitivity cardiac troponin T and I, and N-terminal proBNP have also been studied in CS.^{40,42} Interestingly, studies show that troponin levels can predict risk of arrhythmias, and levels often decrease with improvement in cardiac function and inflammation after treatment.⁴³⁻⁴⁵ Elevated

BNP levels also have been reported as a marker of cardiac involvement in patients with extracardiac sarcoidosis.⁴⁵ Markers of inflammation, including serum levels of soluble IL-2 receptors, neopterin and cytokines such as IL-1, IL-2, IL-12 p40, and IFN- γ have been evaluated as markers of disease activity in small studies although sensitivity and specificity have been poor.^{35,40} The utility of biomarkers in clinical practice remains limited, and most are still being studied in research protocols.

ADVANCED CARDIAC IMAGING FOR CS

CARDIAC MAGNETIC RESONANCE IMAGING

CMR is considered the initial step in evaluation of CS due to its superior spatial resolution, ability to provide tissue characterization, and simultaneous structural and functional evaluation of the heart.^{46,47} In one study, CMR detected subclinical disease in 9.3% of asymptomatic patients without EKG abnormalities and in 4.7% of patients without any abnormalities at initial evaluation.⁴⁸ Both acute and chronic stages can be discerned with different technical aspects of CMR. Late gadolinium enhancement (LGE) is the most reliable tool in CMR assessment. There is no pathognomonic distribution pattern for CS. However, studies show LGE in mainly subepicardial or midmyocardial areas of the basal septum and LV lateral wall with extension into the RV.^{28,49-51} Rarely, LGE also can be subendocardial, mimicking an infarct pattern.⁴⁹ While LGE helps detect more chronic phases of diseases attributed to fibrosis or scarring, T2 mapping detects increased water content or edema in areas of active inflammation.⁴⁶ A meta-analysis by Zhang et al. estimated the sensitivity and specificity for CS diagnosis by CMR at 95% and 92%, respectively.⁵² Among patients with extra-CS, CMR has shown diagnostic accuracy and independently predicted mortality, VT, and HF hospitalizations in those with cardiac symptoms and/or an abnormal EKG (HR 12.71; 95% CI, 1.48-109.35; $P = .021$).⁴⁸ In patients with known or suspected CS, a pooled analysis of 760 patients showed that the presence of LGE in CMR increased likelihood of death from any cause and of future arrhythmogenic events.⁵³

FDG-PET

¹⁸F-DG-PET imaging has become an important part of the multimodality approach used to diagnose and follow treatment response in CS. PET imaging serves as an indicator of ongoing inflammation. The principle follows uptake of ¹⁸F-DG, a glucose analogue, into cells in macrophage-rich areas via the glucose transporter (GLUT); the GLUT is then metabolized to form ¹⁸F-DG-6-phosphate, whose further intracellular metabolism via glycolytic pathway is

terminated, resulting in metabolic trapping that enables detection using imaging techniques. The test involves suppressing glucose uptake in the normal myocardial cells, thus allowing for detection of uptake by inflammatory cells with increased metabolic activity. A joint expert consensus report of the Society of Nuclear Medicine and Molecular Imaging and American Society of Nuclear Cardiology recommend use of cardiac PET for CS diagnosis in the following clinical scenarios: (1) patients with histological evidence of extracardiac sarcoid or positive screening test for CS; (2) unexplained, new-onset significant conduction abnormality such as second- or third-degree AV conduction block in a patient < 60 years; (3) idiopathic sustained ventricular tachycardia; and (4) patients on treatment for CS to guide therapy.⁵⁴ In the absence of recent whole-body PET imaging or the presence of clinical suspicion for extra-CS, a concomitant whole-body PET study should be performed, or at least imaging of chest, liver, and spleen to detect any extracardiac involvement that could be accessed to confirm a histologic diagnosis.⁵⁴ Moreover, in patients in whom MRI is contraindicated and in advanced renal disease, PET can be a useful diagnostic tool.⁵⁵

Inflammatory activity in CS using PET is interpreted both visually and quantitatively. Visual interpretation involves simultaneous evaluation for presence of myocardial perfusion defect (employing PET perfusion imaging or SPECT with either ^{99m}Tc-labeled tracers or ²⁰¹Tl) along with ¹⁸F-FDG uptake (**Table 1**). Uptake patterns on PET imaging suggestive of CS include focal and focal on diffuse uptake, whereas suppression of uptake or a diffuse pattern points to normal physiological uptake.^{47,54,55} Rest perfusion images are classified as normal or abnormal, with regional myocardial perfusion further categorized as mild, moderate, or severely reduced. Moreover, quantitative analysis using standard uptake value can add to the diagnostic utility,

although thresholds for this are still under investigation.^{56,57} A recent systematic review showed that the sensitivity of ¹⁸F-FDG-PET in the diagnosis of CS ranges from 27% to 100% with a similar specificity (28-100%) and is dependent on disease activity.⁴⁷ A meta-analysis by Youssef et al. evaluating ¹⁸F-FDG-PET imaging for CS revealed a sensitivity and specificity of 89% and 78%, respectively.⁵⁸ The presence of both perfusion and metabolic abnormality on PET and focal RV uptake has been associated with a 3-fold increase in adverse events including death or VT.³³ In addition to RV involvement, uptake in basal anterolateral area of LV in steroid-naïve patients was predictive of adverse outcomes.⁵⁹

The diagnostic accuracy of PET imaging can be limited by lack of suppression of uptake in normal tissue or false positives due to other inflammatory conditions, ischemia, or hibernating myocardium, leading to confounding results. This can be avoided by adhering to preparation protocols, including a low-carbohydrate, fat-rich diet (such as Atkin's diet) the day before the study followed by at least 12 to 18 hours of fasting before testing.^{33,57}

CMR VERSUS FDG-PET IMAGING FOR CS

Advanced imaging modalities help increase the diagnostic yield, bear prognostic implications, and help direct therapy. CMR and ¹⁸F-FDG-PET imaging have a complementary role in the diagnosis and management of CS since both evaluate slightly different aspects of the disease. The greater specificity and negative predictive value of CMR combined with its ability to help rule out other diagnoses make it an ideal initial screening test.⁴⁶ Imaging with FDG-PET/CT is warranted in equivocal or negative CMR findings in the setting of high clinical suspicion or in cases with CMR findings with highly probable CS to detect active inflammation and plan further therapy.^{47,49} Visual reduction in the intensity and extent of myocardial inflammation on

| FDG UPTAKE | REST PERFUSION | INTERPRETATION |
|--|---|--|
| Normal metabolism and perfusion | | |
| None | Normal | Normal study |
| Diffuse uptake (nonspecific) | Normal | Inadequate myocardial glucose suppression |
| Abnormal metabolism or perfusion | | |
| Focal uptake | Normal | Early disease or normal variant |
| None | Perfusion defect | Scar from any etiology |
| Abnormal metabolism and perfusion | | |
| Focal uptake | Perfusion defect in area of focal FDG uptake | Inflammation + scar in the same area |
| Focal uptake | Perfusion defect in area separate from FDG uptake | Inflammation + scar in different areas |
| Focal on diffuse uptake | Multiple perfusion defects | Diffuse inflammation or inflammation + inadequate glucose suppression and scar |

Table 1 Features of cardiac sarcoidosis as shown on ¹⁸fluorine-fluorodeoxyglucose-positron emission tomography. Adapted from Blankstein et al. *J Am Coll Cardiol*. 2014.³³ FDG: ¹⁸fluorine-fluorodeoxyglucose

follow-up ^{18}F FDG-PET imaging and indices, such as Standard Uptake Value, show utility in monitoring response to therapy.⁶⁰⁻⁶² The exact timing to repeat PET imaging is unknown; however, 4 to 6 months post initiation of treatment has been suggested.³⁸ Moreover, the Heart Rhythm Society (HRS) indicates use of CMR to determine eligibility for implantable cardioverter defibrillator (ICD) placement with indications being reduced LV ejection fraction (35%) after immunosuppressive therapy (Class I) or if LGE is present in patients with LV ejection fraction 35% to 49% after immunosuppression (Class IIb).³

ENDOMYOCARDIAL BIOPSY

The identification of epithelioid noncaseating granulomas in cardiac tissue specimen is considered definitive for diagnosis of CS after exclusion of alternative diagnoses. However, the diagnostic yield of electromyocardial biopsy (EMB) in CS is low, estimated at 20% to 30%.⁶³⁻⁶⁵ Several factors impact yield, including technique, the patchy distribution of lesions having increased predilection for left heart favoring midmyocardial and subepicardial areas, and stage of disease.⁶⁶ If performed during chronic stages, granulomas and lymphocytic infiltration tend to disappear and are replaced by fibrosis.³⁵ EMB is required for confirmation of diagnosis in absence of extracardiac histological diagnosis and isolated cardiac sarcoidosis and to rule out other causes of fulminant cardiomyopathy, such as giant cell myocarditis. In addition to histological evaluation, concurrent staining with Grocott staining for fungal infection and Ziehl-Neelsen staining for acid-fast microorganisms should be conducted as indicated.³⁵ The presence of epithelioid giant cells in myocardial biopsy samples is strongly suggestive of cardiac sarcoidosis.³⁵ Electroanatomic mapping-guided EMB helps increase diagnostic yield up to 41%, with additional benefit from

cardiac imaging.^{64,66} The prognostic yield of EMB remains uncertain, with different studies providing contrasting results.^{65,66}

TESTING FOR EXTRACARDIAC SARCOIDOSIS

Evaluation for extracardiac involvement in patients with suspected CS is crucial and may often be the only feasible approach to establishing a histologic diagnosis. Chest radiography or high-resolution computed tomography (HRCT) can demonstrate bilateral hilar or mediastinal lymphadenopathy along with lung parenchymal findings of nodular and patchy ground-glass opacities, pale infiltrates, and cyst formation that distribute along the lymphatic vessels, suggestive of pulmonary sarcoidosis. HRCT in pulmonary sarcoidosis also demonstrates very fine to fine nodular shadows along the peribronchovascular sheaths, interlobular septa and pleural surface, and tracheal wall thickening, while more advanced cases develop fibrosis and traction bronchiectasis.⁶⁷ Lung or lymph node biopsies obtained through transbronchial needle aspiration (TBNA), endobronchial biopsy, transbronchial lung biopsy, and, more recently, endosonography with nodal aspiration, either endobronchial ultrasound-guided TBNA or esophageal ultrasonography with fine-needle aspiration, can aid in pathological confirmation of diagnosis. Depending on the system involved, cutaneous biopsies, eye examination, and further imaging may be indicated.^{35,67}

DIAGNOSTIC CRITERIA FOR CS

Diagnosis of sarcoidosis requires a compatible clinical and radiologic presentation, pathologic evidence of noncaseating granulomas, and exclusion of other diseases with similar findings (*Figure 1*).⁶⁸ Since histologic evidence

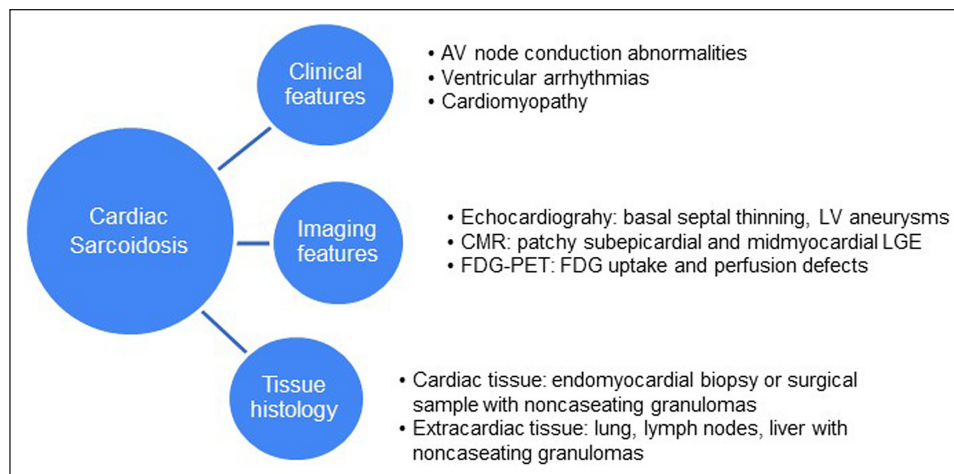


Figure 1 Diagnosis of cardiac sarcoidosis. LV: left ventricular; CMR: cardiac magnetic resonance; LGE: late gadolinium enhancement; FDG-PET: fluorine-fluorodeoxyglucose-positron emission tomography

of noncaseating granulomas in the myocardium can be difficult to establish, CS is typically diagnosed based on clinicopathological findings in conjunction with imaging and extracardiac tissue histology. Three sets of diagnostic criteria have been prescribed by professional societies based on expert consensus. Diagnostic criteria commonly used in practice include the HRS criteria and the Japanese Ministry of Health and Welfare/JCS criteria (*Table 2*).

The HRS recommendations described criteria for “definite” or histological, requiring myocardial biopsy

findings, and “probable” or clinical diagnosis, necessitating biopsy proven sarcoid in an extracardiac site.³ In 2014, the World Association of Sarcoidosis and Other Granulomatous Disorders (WASOG) revised the 1999 WASOG Sarcoidosis Organ Assessment Instrument, which replaced the dated ACCESS (A Case Control Etiology of Sarcoidosis Study) sarcoidosis organ assessment instrument. Based on expert opinion consensus, they categorized the likelihood of organ involvement as either (A) highly probable; likelihood of sarcoidosis causing this manifestation of at least

| HEART RHYTHM SOCIETY GUIDELINES | JAPANESE CIRCULATION SOCIETY GUIDELINES |
|--|---|
| <p>Definite or histological diagnosis: Requires presence of noncaseating granulomas myocardial tissue and absence of alternative cause</p> <p>A. Probable* or clinical diagnosis: Histological diagnosis of extracardiac sarcoidosis AND Presence of ≥ 1 of the following:</p> <ul style="list-style-type: none"> • Steroid \pm immunosuppressant responsive cardiomyopathy or heart block • Unexplained reduced LVEF ($< 40\%$) • Unexplained sustained (spontaneous or induced) VT • Mobitz type II 2nd degree heart block or 3rd degree heart block • Patchy uptake on dedicated cardiac PET (in a pattern consistent with CS) • Late gadolinium enhancement on CMR (in a pattern consistent with CS) • Positive gallium uptake (in a pattern consistent with CS) <p>AND</p> <p>B. Other causes for the cardiac manifestation(s) have been reasonably excluded</p> <p>*Probable is considered adequate to establish a clinical diagnosis of CS</p> | <p>1) Histological diagnosis group: Requires biopsy findings demonstrating noncaseating epithelioid granulomas from endomyocardial biopsy or surgical cardiac specimens</p> <p>2) Clinical diagnosis group: (negative myocardial biopsy or not undergoing myocardial biopsy)</p> <p>A) Extracardiac biopsy proven sarcoid AND clinical findings strongly suggestive of cardiac involvement** OR B) Clinical findings strongly suggestive of pulmonary or ophthalmic sarcoid AND At least 2 out of 5 characteristic lab findings of sarcoidosis*** AND Clinical findings strongly suggestive of cardiac involvement**</p> <hr/> <p>**Clinical findings defining cardiac involvement</p> <ol style="list-style-type: none"> 1) Two or more of the five major criteria (a) to (e) are satisfied 2) One of the five major criteria (a) to (e) and two or more of the three minor criteria (f) to (h) are satisfied <hr/> <p>Criteria for cardiac involvement of sarcoidosis</p> <p>1. Major criteria</p> <ol style="list-style-type: none"> (a) High-grade atrioventricular block or VT/VF (b) Basal thinning of the ventricular septum or abnormal ventricular wall anatomy (ventricular aneurysm, thinning of the middle or upper ventricular septum, regional ventricular wall thickening) (c) Left ventricular contractile dysfunction (LVEF $< 50\%$) (d) ⁶⁷Ga citrate scintigraphy or ¹⁸F-¹⁸FDG-PET reveals abnormally high tracer accumulation in the heart (e) Gadolinium-enhanced MRI reveals delayed contrast enhancement of the myocardium <p>2. Minor criteria</p> <ol style="list-style-type: none"> (f) Abnormal EKG findings: ventricular arrhythmias (nonsustained ventricular tachycardia, multifocal or frequent premature ventricular contractions), bundle branch block, axis deviation, or abnormal Q waves (g) Perfusion defects on myocardial perfusion scintigraphy (h) Endomyocardial biopsy: monocyte infiltration and moderate or severe myocardial interstitial fibrosis |

Table 2 Summary of Heart Rhythm Society and Japanese Circulation Society guidelines for diagnosis of CS. CS: cardiac sarcoidosis; LVEF: left ventricular ejection fraction; VT: ventricular tachycardia; VF: ventricular fibrillation; PET: positron emission tomography; CMR: cardiac magnetic resonance; ¹⁸F-FDG-PET: ¹⁸fluorine-fluorodeoxyglucose-positron emission tomography; EKG: echocardiographic Adapted from^{3,35,42}

*** Clinical diagnosis of sarcoidosis is supported when at least two of the five characteristic findings are observed.

Bilateral hilar lymphadenopathy

High serum angiotensin-converting enzyme activity or elevated serum lysozyme levels

High serum soluble interleukin-2 receptor levels

Significant tracer accumulation in ⁶⁷Ga citrate scintigraphy or ¹⁸FDG-PET

A high percentage of lymphocytes with a CD4/CD8 ratio of > 3.5 in BAL fluid

90%; (B) probable; likelihood of sarcoidosis causing this manifestation of between 50% and 90%; or (C) possible; likelihood of sarcoidosis causing this manifestation of less than 50%.⁶⁹ In 2017, the JCS further revised their 2006 criteria to guide diagnosis based on a histological or clinical basis.^{35,42} Important diagnostic clues such as fatal ventricular arrhythmia (sustained ventricular tachycardia and ventricular fibrillation), abnormal ventricular anatomy, and advanced cardiac imaging findings (CMR, FDG-PET) were incorporated into major criteria, reflecting the significance of these manifestations in CS.⁴² Moreover, diagnosis in the clinical group did not mandate biopsy findings of sarcoidosis from cardiac or extracardiac tissue, a significant change from previous recommendations. The 2017 JCS guidelines also prescribe criteria to diagnose isolated CS.^{35,42}

ISOLATED CARDIAC SARCOIDOSIS

Isolated CS (iCS) is characterized by cardiac involvement in the absence of clinical, histological, or imaging findings of extracardiac disease.⁷⁰ Recognizing iCS as a distinct clinical entity, the JCS laid out criteria for clinical or histological diagnosis (**Table 3**).³⁵ Reported prevalence ranges widely from 3.2% to 54%. **Table 4** summarizes characteristics of studies on iCS published after 2010.⁷¹⁻⁷⁷ Patients with iCS usually present with advanced heart disease and have worse survival outcomes, explained by late diagnosis.⁴ iCS patients present with LV systolic dysfunction or sudden cardiac death more often than patients with extracardiac sarcoidosis with cardiac involvement.⁶⁴ While EMB confers definitive diagnosis, advanced imaging modalities are preferred for their higher yield (95% and 74% sensitivity for CMR and FDG-PET, respectively), and aiding extracardiac sarcoidosis detection. Signs of extracardiac sarcoidosis such as lymphadenopathy can manifest later, although its relevance to treatment and prognosis is unclear.⁷⁰

CLINICAL ENTITIES CONFOUNDING CARDIAC SARCOIDOSIS DIAGNOSIS

Several conditions mimic CS presentation. These differential diagnoses can be clarified using histology or imaging modalities.^{20,78-80} Differentiation is vital because it carries implications in treatment and prognosis. **Table 5** lists the differential diagnosis one must keep in mind when ruling in or out sarcoidosis.

PRACTICAL APPROACH TO DIAGNOSING CS

CS remains a challenge to diagnose, and diagnostic testing needs to be tailored to the clinical scenario in which it is being used. Clinicians may encounter three main clinical scenarios that trigger further testing for CS: (1) patients with clinical features suggestive of CS, ie, new heart block under age 60 years, nonischemic cardiomyopathy with electrocardiographic or echocardiographic features suggestive of CS, or idiopathic VT with known extracardiac sarcoidosis; (2) patients with clinical features suggestive of CS without known extracardiac sarcoidosis; and (3) patients with known extracardiac sarcoidosis without clinical features of cardiac involvement. We suggest a practical approach to diagnostic testing in these scenarios as shown in **Figures 2** and **3**.

In patients with suspected CS based on their clinical presentation, CMR remains the initial test of choice and can be used to guide further testing with ¹⁸F-DG-PET. The HRS guidelines recommend screening for CS in patients with a history of extracardiac sarcoidosis and those under 60 years presenting with unexplained Mobitz II or third-degree AV block and VT of unknown etiology.³ In patients with previously diagnosed extracardiac sarcoidosis, the diagnosis of CS can be made with relative ease if clinical features and imaging findings consistent with CS are present. The challenge often arises in patients with a clinical syndrome

PREREQUISITE CRITERIA

1. No clinical findings characteristic of sarcoidosis are observed in any organs other than the heart. (The patient should be examined in detail for respiratory, ophthalmic, and skin involvements of sarcoidosis. When the patient is symptomatic, other etiologies that can affect the corresponding organs must be ruled out.)
2. ⁶⁷Ga scintigraphy or ¹⁸F-DG-PET reveals no abnormal tracer accumulation in any organs other than the heart.
3. A chest CT scan reveals no shadow along the lymphatic tracts in the lungs or no hilar and mediastinal lymphadenopathy (minor axis > 10 mm).

CLINICAL DIAGNOSIS GROUP

Prerequisite criteria **AND** ≥ three other criteria of the major criteria (a)-(e) are satisfied per JCS guidelines, Table 2*

HISTOLOGICAL DIAGNOSIS GROUP

Demonstration of noncaseating epithelioid granulomas in endomyocardial biopsy or surgical specimens

Table 3 Japanese Circulation Society (JCS) guidelines for isolated cardiac sarcoidosis.^{35,42}

¹⁸F-DG-PET: ¹⁸fluorine fluorodeoxyglucose-positron emission tomography; CT: computed tomography

* Refer JCS guidelines in Table 2 for major criteria a-e

| AUTHOR | STUDY PERIOD | N | STUDY POPULATION | COUNTRY | STUDY POPULATION CLINICAL MANIFESTATIONS N (%) | DIAGNOSTIC MODALITIES (N) | PREVALENCE N (%) | MEDIAN AGE | SEX MALE |
|-------------------|--------------|-----|---|-----------|---|---|--|--------------|----------|
| Kandolin et al. | 1998-2014 | 110 | Patients diagnosed with CS | Finland | AV block 48 (44) VT/VF 36 (33) HF 20 (18) | EMB (55/92) Explant (6) Autopsy (2) mediastinal LN biopsy (18) Whole body PET 31 CMR 59 PET 66 CMR and/or PET (38) Other (9) | Definite: 59/110 (54) | 51 ± 9 | 39 |
| Tezuka et al. | 1995-2008 | 83 | Patients with clinical sarcoidosis | Japan | N = 15 VA 8 (53) VT 7 (47) VF 1 (7) Automatic ICD 9 (60) Complete AV block 3 (20) HF 6 (40) | JCS Criteria CMR FDG-PET EMB | Definite: 11/41 (27) | 63.5 ± 15.9* | 7* |
| Simonen et al. | 2005-2013 | 68 | Patients with known CS | Finland | Complete AV block 37 (54) Sustained VT 18 (26) HF 7 (10) VF 4 (6) PVCs 2 (2.3) | Cardiac ¹⁸ F-DG PET (68) CMR (43) EMB (56) Whole body ¹⁸ F-DG PET (n = 57) Mediastinal LN biopsy (24) | Definite: 13/57 (23) | 50 ± 9 | 21 |
| Juneau et al. | 2017 | 31 | Patients first presenting with clinically manifest CS | Canada | High-degree AV block 18 (58) VT or cardiac arrest 6 (19) High-degree AB block/VT 3 (10) HF 3 (10) Other 1 (3) | Cardiac and whole body ¹⁸ F-DG-PET-CT | Definite: 1/31 (3.2) | 56 ± 8 | 14 |
| Giudicatti et al. | 2007-2018 | 52 | All cases of proven or probable CS based on HRS and local consensus | Australia | HF 17 (53) VF/VT 7 (22) ICD 21 (66) | Cardiac and whole body ¹⁸ F-DG-PET-CT | Definite: 3/32 (9.4) | 59 | 22 |
| Kawai H | 2013-2019 | 94 | All patients with suspected CS | Japan | N = 7* Sustained VT/VF or high-degree conduction block 4 (57) HF 7 (100) | Cardiac and whole body ¹⁸ F-DG-PET-CT | Clinical: 7/34 (21) Based on JCS guidelines | 59.4 ± 14.9* | 4* |
| Sperry BW | 2002-2014 | 27 | EMB-proven CS | USA | High-degree AV block 15 (56) HF 27 (100) VT 16 (59) | ¹⁸ F-DG-PET-CT (16) CMR (12) | Definite: 14/27 (52) | 53.8 ± 9.5 | 16 |
| Chazal et al. | 2000-2017 | 15 | CS in explanted hearts/ATS- or WASOG-based diagnosis of sarcoidosis | France | VT 7 (47) VF 1 (7) Complete AV block 3 (20) HF 6 (40) | Echocardiography CMR (6) FDG-PET (2) | Definite: 3/15 (20) | 48 | 10 |

Table 4 Prevalence of isolated cardiac sarcoidosis.⁷¹⁻⁷⁷ AV block: atrioventricular block; CMR: cardiac magnetic resonance; PET: positron emission tomography; EMB: endomyocardial biopsy; HF: heart failure; HRS: Heart Rhythm Society; JHMW: JHM strain of mouse hepatitis virus; LN: lymph node; VA: ventricular arrhythmias; VF: ventricular fibrillation; VT: ventricular tachycardia; ¹⁸F-DG-PET: ¹⁸fluorine-fluorodeoxyglucose PET; WASOG: World Association for Sarcoidosis and Other Granulomatous Diseases

*In ICS group

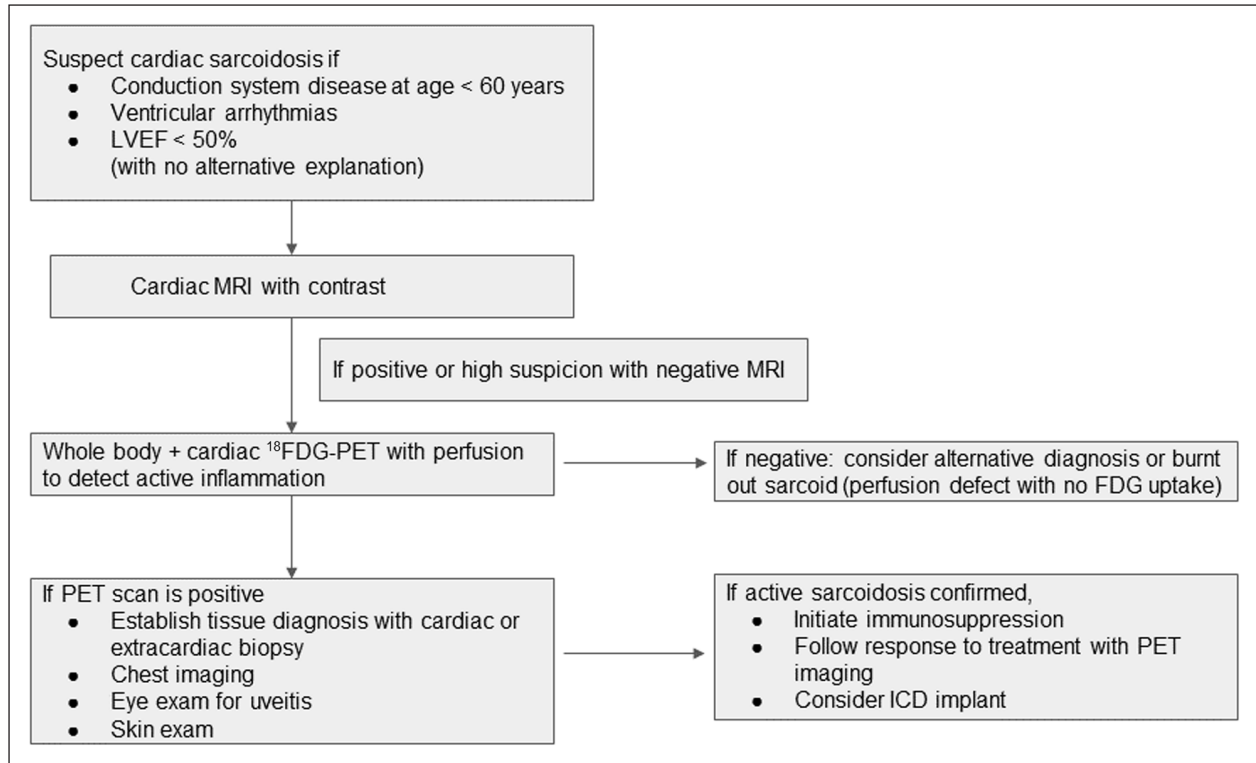


Figure 2 Approach to diagnosis for suspected cardiac sarcoidosis. LVEF: left ventricular ejection fraction; MRI: magnetic resonance imaging; ¹⁸FDG-PET: ¹⁸fluorine-fluorodeoxyglucose positron emission tomography; PET: positron emission tomography; ICD: implantable cardioverter defibrillator

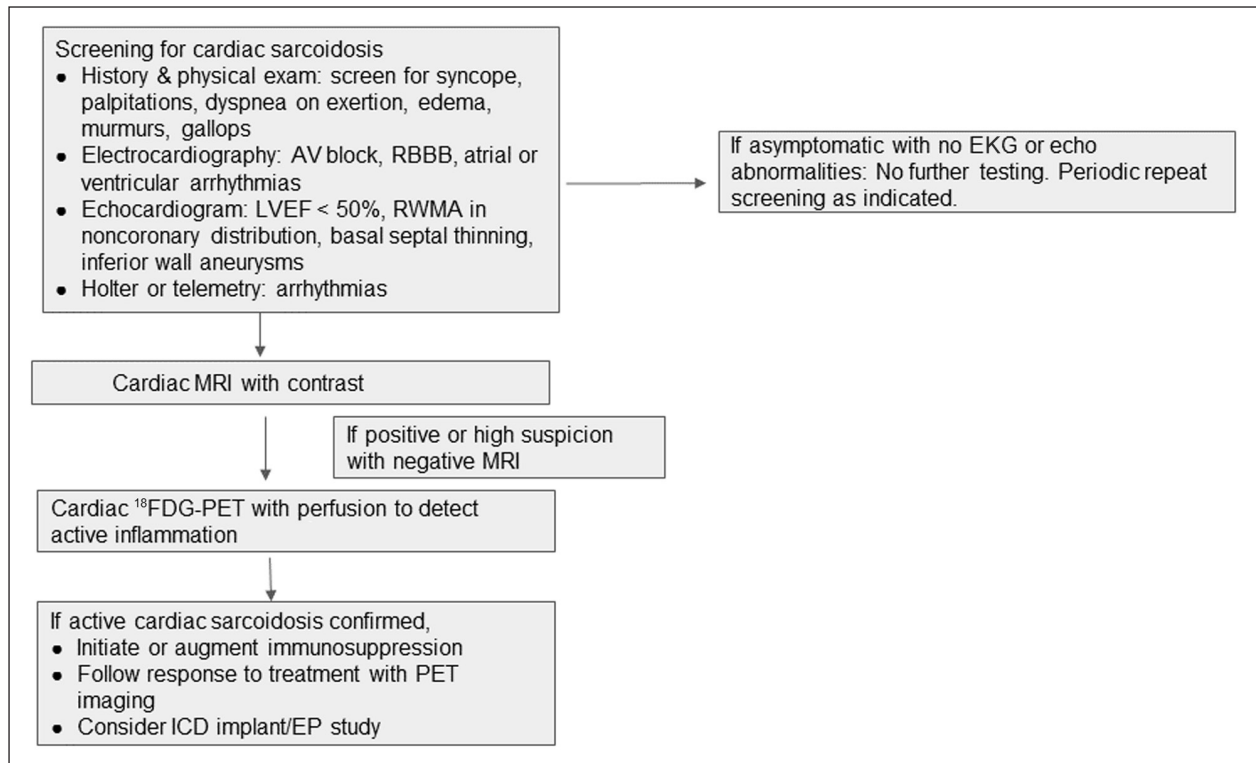


Figure 3 Approach to screening for patients with extracardiac sarcoidosis. AV: atrioventricular; RBBB: right bundle branch block; LVEF: left ventricular ejection fraction; RWMA: regional wall motion abnormalities; MRI: magnetic resonance imaging; ¹⁸FDG-PET: ¹⁸fluorine-fluorodeoxyglucose positron emission tomography; PET: positron emission tomography; ICD: implantable cardioverter defibrillator; EP: electrophysiological; EKG: electrocardiogram; echo: echocardiogram

| DISEASE | CLINICAL FEATURES | HISTOLOGY | IMAGING |
|---|--|---|--|
| Giant cell myocarditis | Ventricular arrhythmias Complete heart block Rapidly progressive heart failure, shock | Lack of granuloma formation Inflammatory infiltrate of eosinophils, lymphocytes, macrophages, and giant cells associated with myocyte necrosis | Echocardiographic findings: wall thickening, normal or enlarged LV size, decreased LV systolic function with acute progression to LV dilation and decreased LVEF |
| Idiopathic dilated cardiomyopathy | Heart failure, arrhythmia Positive family history | Myocyte hypertrophy and replacement fibrosis with variable involvement of the conduction system | Dilated LV with global ventricular dysfunction Linear stripe of LGE in ventricular septum on MRI or no LGE |
| Arrhythmogenic RV cardiomyopathy | Ventricular arrhythmias RV failure Family history Sudden cardiac death | Transmural fibrofatty replacement of myocardium | RV dilatation and dysfunction Fibrofatty infiltration of RV Dyskinesia of RV free wall with RV aneurysms |
| Amyloidosis | Heart failure Heart block Atrial fibrillation Multiple myeloma, renal insufficiency and/or nephrotic syndrome | Amorphous hyaline deposits seen predominantly in the extracellular space Typical apple-green birefringence with Congo red dye under polarized light microscopy and unique cross- β -pleated sheets under electron microscopy | Biventricular hypertrophy including valves and RV Biatrial enlargement Diffuse nulling abnormality of myocardium on MRI with LGE |
| Hypertrophic cardiomyopathy | Heart failure Ventricular arrhythmias Atrial fibrillation Family history | Myocyte hypertrophy and disarray Presence of interstitial and replacement fibrosis | LV hypertrophy > 15 mm (often asymmetric) Scattered patchy midmyocardial scar on MRI and LGE predominant in RV insertion points of ventricular septum |
| Myocarditis (tuberculous, fungal, bacterial, viral) | Heart failure Chest pain Atrial and ventricular arrhythmias Clinical features of causative organism | Necrotizing granulomas in case of TB, disseminated fungal infection Demonstration of implicated organisms on staining Myofiber necrosis Neutrophilic or mononuclear infiltrate Chronic stages: fibrosis with disruption of the normal myocardial architecture | Patchy epicardial LGE Edema on MRI |

Table 5 Clinical, imaging, and histological features of diagnostic confounders.^{20,78-80}

LV: left ventricular; LVEF: LV ejection fraction; LGE: late gadolinium enhancement; MRI: magnetic resonance imaging; RV: right ventricular

suspicious for CS but without a diagnosis of extracardiac sarcoidosis. Prior to labeling these cases as isolated cardiac sarcoidosis, a thorough search for extracardiac sarcoidosis must be undertaken with whole body PET imaging, skin exam, eye exam for uveitis, and biopsies if lymph node, lung, or liver involvement are suspected. In cases of isolated cardiac sarcoidosis, in addition to searching for extracardiac involvement, a comprehensive search for any other potential clinical mimics or causes of myocarditis must be performed.

It is suggested that patients with known extracardiac sarcoidosis without symptomatic cardiac involvement undergo periodic assessment for CS with appropriate history and EKG.⁴⁸ A recent large observational study assessing cardiac outcomes in 12,042 sarcoidosis patients (without prior CS diagnosis) noted a higher risk of cardiovascular events, including incident HF, HF-related death, and composite outcomes inclusive of ICD implantation, ventricular arrhythmias, and cardiac arrest.

This affirms the necessity of early recognition of CS in this population.⁸¹ Utilization of advanced imaging techniques in this population remains debated outside of research studies due to limited knowledge regarding the impact of treatment in asymptomatic individuals, particularly given the risks of immunosuppression.

CONCLUSION

CS is an under-recognized cause of nonischemic cardiomyopathy and arrhythmias. CS can present as the initial, or even the only, manifestation of sarcoidosis and is associated with adverse outcomes. Diagnosis of CS remains challenging and requires a combination of clinical, radiologic, and histologic evidence. Advanced imaging techniques including CMR and FDG-PET are increasingly being used for diagnosis and guiding treatment in CS. Additional studies are required to improve diagnostic

accuracy in cases of isolated cardiac sarcoidosis and to inform screening guidelines and the care of patients with asymptomatic cardiac involvement.

KEY POINTS

- Cardiac sarcoidosis is an under-recognized but treatable cause of cardiomyopathy and arrhythmias.
- Diagnosis of cardiac sarcoidosis is challenging and requires a combination of clinical, radiologic, and histologic findings.
- Endomyocardial biopsies have low sensitivity for diagnosis of cardiac sarcoidosis, and use of imaging or electroanatomic mapping guidance can help improve diagnostic yield.
- Clinical vigilance for cardiac sarcoidosis is important due to high risk of morbidity and mortality if left untreated.

COMPETING INTERESTS

The authors have no competing interests to declare.

AUTHOR AFFILIATIONS

Sheetal V. Mathai, MD

Jacobi Medical Center and Albert Einstein College of Medicine, Bronx, New York, US

Snehal Patel, MD

Montefiore Medical Center and Albert Einstein College of Medicine, Bronx, New York, US

Ulrich P. Jorde, MD

Montefiore Medical Center and Albert Einstein College of Medicine, Bronx, New York, US

Yogita Rochlani, MD

Montefiore Medical Center and Albert Einstein College of Medicine, Bronx, New York, US

REFERENCES

1. **Iannuzzi MC, Rybicki BA, Teirstein AS.** Sarcoidosis. *N Engl J Med.* 2007 Nov 22;357(21):2153-65. doi: [10.1056/NEJMra071714](#)
2. **Birnie DH, Nery PB, Ha AC, Beanlands RSB.** Cardiac Sarcoidosis. *J Am Coll Cardiol.* 2016 Jul 26;68(4):411-21. doi: [10.1016/j.jacc.2016.03.605](#)
3. **Birnie DH, Sauer WH, Bogun F,** et al. HRS expert consensus statement on the diagnosis and management of arrhythmias associated with cardiac sarcoidosis. *Heart Rhythm.* 2014 Jul;11(7):1305-23. doi: [10.1016/j.hrthm.2014.03.043](#)
4. **Kandolin R, Lehtonen J, Airaksinen J,** et al. Cardiac sarcoidosis: epidemiology, characteristics, and outcome over 25 years in a nationwide study. *Circulation.* 2015 Feb 17;131(7):624-32. doi: [10.1161/CIRCULATIONAHA.114.011522](#)
5. **Arkema EV, Cozier YC.** Sarcoidosis epidemiology: recent estimates of incidence, prevalence and risk factors. *Curr Opin Pulm Med.* 2020 Sep;26(5):527-534. doi: [10.1097/MCP.0000000000000715](#)
6. **Baughman RP, Field S, Costabel U,** et al. Sarcoidosis in America. Analysis Based on Health Care Use. *Ann Am Thorac Soc.* 2016 Aug;13(8):1244-52. doi: [10.1513/AnnalsATS.201511-760OC](#)
7. **Cozier YC, Berman JS, Palmer JR, Boggs DA, Serlin DM, Rosenberg L.** Sarcoidosis in black women in the United States: data from the Black Women's Health Study. *Chest.* 2011 Jan;139(1):144-50. doi: [10.1378/chest.10-0413](#)
8. **Mirsaeidi M, Machado RF, Schraufnagel D, Sweiss NJ, Baughman RP.** Racial difference in sarcoidosis mortality in the United States. *Chest.* 2015 Feb;147(2):438-449. doi: [10.1378/chest.14-1120](#)
9. **Baughman RP, Teirstein AS, Judson MA,** et al. Clinical characteristics of patients in a case control study of sarcoidosis. *Am J Respir Crit Care Med.* 2001 Nov 15;164(10 Pt 1):1885-9. doi: [10.1164/ajrccm.164.10.2104046](#)
10. **Morimoto T, Azuma A, Abe S,** et al. Epidemiology of sarcoidosis in Japan. *Eur Respir J.* 2008 Feb;31(2):372-9. doi: [10.1183/09031936.00075307](#)
11. **Pizarro C, Goebel A, Dabir D,** et al. Cardiovascular magnetic resonance-guided diagnosis of cardiac affection in a Caucasian sarcoidosis population. *Sarcoidosis Vasc Diffuse Lung Dis.* 2016 Jan 18;32(4):325-35.
12. **Vignaux O, Dhote R, Duboc D,** et al. Detection of myocardial involvement in patients with sarcoidosis applying T2-weighted, contrast-enhanced, and cine magnetic resonance imaging: initial results of a prospective study. *J Comput Assist Tomogr.* Sep-Oct 2002;26(5):762-7. doi: [10.1097/00004728-200209000-00017](#)
13. **Al-Kindi SG, Oliveira GH.** Letter by Al-Kindi and Oliveira regarding article "cardiac sarcoidosis: epidemiology, characteristics, and outcome over 25 years in a nationwide study". *Circulation.* 2015 Oct 27;132(17):e211. doi: [10.1161/CIRCULATIONAHA.115.016258](#)
14. **Berlin M, Fogdell-Hahn A, Olerup O, Eklund A, Grunewald J.** HLA-DR predicts the prognosis in Scandinavian patients with pulmonary sarcoidosis. *Am J Respir Crit Care Med.* 1997 Nov;156(5):1601-5. doi: [10.1164/ajrccm.156.5.9704069](#)
15. **Ezzie ME, Crouser ED.** Considering an infectious etiology of sarcoidosis. *Clin Dermatol.* May-Jun 2007;25(3):259-66. doi: [10.1016/j.clindermatol.2007.03.003](#)

16. **Barnard J, Rose C, Newman L**, et al. Job and industry classifications associated with sarcoidosis in A Case-Control Etiologic Study of Sarcoidosis (ACCESS). *J Occup Environ Med*. 2005 Mar;47(3):226-34. doi: [10.1097/01.jom.0000155711.88781.91](https://doi.org/10.1097/01.jom.0000155711.88781.91)
17. **Hena KM, Murphy S, Zhang Y, Shao Y, Kazeros A, Reibman J**. Clinical Evaluation of Sarcoidosis in Community Members with World Trade Center Dust Exposure. *Int J Environ Res Public Health*. 2019 Apr 10;16(7):1291. doi: [10.3390/ijerph16071291](https://doi.org/10.3390/ijerph16071291)
18. **Izbicki G, Chavko R, Banauch GI**, et al. World Trade Center “sarcoid-like” granulomatous pulmonary disease in New York City Fire Department rescue workers. *Chest*. 2007 May;131(5):1414-23. doi: [10.1378/chest.06-2114](https://doi.org/10.1378/chest.06-2114)
19. **Belperio JA, Shaikh F, Abtin F**, et al. Extrapulmonary sarcoidosis with a focus on cardiac, nervous system, and ocular involvement. *EclinicalMedicine*. 2021 Jun 27;37:100966. doi: [10.1016/j.eclinm.2021.100966](https://doi.org/10.1016/j.eclinm.2021.100966)
20. **Lagana SM, Parwani AV, Nichols LC**. Cardiac sarcoidosis: a pathology-focused review. *Arch Pathol Lab Med*. 2010 Jul;134(7):1039-46. doi: [10.5858/2009-0274-RA.1](https://doi.org/10.5858/2009-0274-RA.1)
21. **Wahlström J, Katchar K, Wigzell H, Olerup O, Eklund A, Grunewald J**. Analysis of intracellular cytokines in CD4+ and CD8+ lung and blood T cells in sarcoidosis. *Am J Respir Crit Care Med*. 2001 Jan;163(1):115-21. doi: [10.1164/ajrccm.163.1.9906071](https://doi.org/10.1164/ajrccm.163.1.9906071)
22. **Schoppet M, Pankuweit S, Maisch B**. Cardiac sarcoidosis: cytokine patterns in the course of the disease. *Arch Pathol Lab Med*. 2003 Sep;127(9):1207-10. doi: [10.5858/2003-127-1207-CSCPIT](https://doi.org/10.5858/2003-127-1207-CSCPIT)
23. **Liu Y, Qiu L, Wang Y**, et al. The Circulating Treg/Th17 Cell Ratio Is Correlated with Relapse and Treatment Response in Pulmonary Sarcoidosis Patients after Corticosteroid Withdrawal. *PLoS One*. 2016 Feb 4;11(2):e0148207. doi: [10.1371/journal.pone.0148207](https://doi.org/10.1371/journal.pone.0148207)
24. **Ramstein J, Broos CE, Simpson LJ**, et al. IFN-Producing T-Helper 17.1 Cells Are Increased in Sarcoidosis and Are More Prevalent than T-Helper Type 1 Cells. *Am J Respir Crit Care Med*. 2016 Jun 1;193(11):1281-91. doi: [10.1164/rccm.201507-14990C](https://doi.org/10.1164/rccm.201507-14990C)
25. **Serei VD, Fyfe B**. The Many Faces of Cardiac Sarcoidosis. *Am J Clin Pathol*. 2020 Feb 8;153(3):294-302. doi: [10.1093/ajcp/aqz169](https://doi.org/10.1093/ajcp/aqz169)
26. **Bagwan IN, Hooper LVB, Sheppard MN**. Cardiac sarcoidosis and sudden death. The heart may look normal or mimic other cardiomyopathies. *Virchows Arch*. 2011 Jun;458(6):671-8. doi: [10.1007/s00428-010-1003-8](https://doi.org/10.1007/s00428-010-1003-8)
27. **Roberts WC, McAllister HA Jr, Ferrans VJ**. Sarcoidosis of the heart. A clinicopathologic study of 35 necropsy patients (group 1) and review of 78 previously described necropsy patients (group 11). *Am J Med*. 1977 Jul;63(1):86-108. doi: [10.1016/0002-9343\(77\)90121-8](https://doi.org/10.1016/0002-9343(77)90121-8)
28. **Patel MR, Cawley PJ, Heitner JF**, et al. Detection of myocardial damage in patients with sarcoidosis. *Circulation*. 2009 Nov 17;120(20):1969-77. doi: [10.1161/CIRCULATIONAHA.109.851352](https://doi.org/10.1161/CIRCULATIONAHA.109.851352)
29. **Kurmann R, Mankad SV, Mankad R**. Echocardiography in Sarcoidosis. *Curr Cardiol Rep*. 2018 Sep 26;20(11):118. doi: [10.1007/s11886-018-1065-9](https://doi.org/10.1007/s11886-018-1065-9)
30. **Kim JS, Judson MA, Donnino R**, et al. Cardiac sarcoidosis. *Am Heart J*. 2009 Jan;157(1):9-21. doi: [10.1016/j.ahj.2008.09.009](https://doi.org/10.1016/j.ahj.2008.09.009)
31. **Gilotra NA, Griffin JM, Pavlovic N**, et al. Sarcoidosis-Related Cardiomyopathy: Current Knowledge, Challenges, and Future Perspectives State-of-the-Art Review. *J Card Fail*. 2022 Jan;28(1):113-132. doi: [10.1016/j.cardfail.2021.06.016](https://doi.org/10.1016/j.cardfail.2021.06.016)
32. **Okada DR, Smith J, Derakhshan A**, et al. Ventricular Arrhythmias in Cardiac Sarcoidosis. *Circulation*. 2018 Sep 18;138(12):1253-1264. doi: [10.1161/CIRCULATIONAHA.118.034687](https://doi.org/10.1161/CIRCULATIONAHA.118.034687)
33. **Blankstein R, Osborne M, Naya M**, et al. Cardiac positron emission tomography enhances prognostic assessments of patients with suspected cardiac sarcoidosis. *J Am Coll Cardiol*. 2014 Feb 4;63(4):329-36. doi: [10.1016/j.jacc.2013.09.022](https://doi.org/10.1016/j.jacc.2013.09.022)
34. **Yazaki Y, Isobe M, Hiroe M**, et al. Prognostic determinants of long-term survival in Japanese patients with cardiac sarcoidosis treated with prednisone. *Am J Cardiol*. 2001 Nov 1;88(9):1006-10. doi: [10.1016/s0002-9149\(01\)01978-6](https://doi.org/10.1016/s0002-9149(01)01978-6)
35. **Terasaki F, Azuma A, Anzai T**, et al. JCS 2016 Guideline on Diagnosis and Treatment of Cardiac Sarcoidosis – Digest Version. *Circ J*. 2019 Oct 25;83(11):2329-2388. doi: [10.1253/circj.CJ-19-0508](https://doi.org/10.1253/circj.CJ-19-0508)
36. **Uusimaa P, Ylitalo K, Anttonen O**, et al. Ventricular tachyarrhythmia as a primary presentation of sarcoidosis. *Europace*. 2008 Jun;10(6):760-6. doi: [10.1093/europace/eun110](https://doi.org/10.1093/europace/eun110)
37. **Rossides M, Kullberg S, Grunewald J**, et al. Risk and predictors of heart failure in sarcoidosis in a population-based cohort study from Sweden. *Heart*. 2021 May 21;heartjnl-2021-319129. doi: [10.1136/heartjnl-2021-319129](https://doi.org/10.1136/heartjnl-2021-319129)
38. **Slart RHJ, Glaudemans AWJ, Lancellotti P**, et al. A joint procedural position statement on imaging in cardiac sarcoidosis: from the Cardiovascular and Inflammation & Infection Committees of the European Association of Nuclear Medicine, the European Association of Cardiovascular Imaging, and the American Society of Nuclear Cardiology. *J Nucl Cardiol*. 2018 Feb;25(1):298-319. doi: [10.1007/s12350-017-1043-4](https://doi.org/10.1007/s12350-017-1043-4)
39. **Akamatsu K, Ito T, Terasaki F, Hoshiga M**. Myocardial findings evaluated by echocardiography in cardiac sarcoidosis: A report of seven cases. *J Clin Ultrasound*. 2021 Nov;49(9):940-946. doi: [10.1002/jcu.23058](https://doi.org/10.1002/jcu.23058)

40. **Birnie DH.** Cardiac Sarcoidosis. *Semin Respir Crit Care Med.* 2020 Oct;41(5):626-640. doi: [10.1055/s-0040-1712535](https://doi.org/10.1055/s-0040-1712535)
41. **Barssoum K, Altibi AM, Rai D,** et al. Speckle tracking echocardiography can predict subclinical myocardial involvement in patients with sarcoidosis: A meta-analysis. *Echocardiography.* 2020 Dec;37(12):2061-2070. doi: [10.1111/echo.14886](https://doi.org/10.1111/echo.14886)
42. **Terasaki F, Yoshinaga K.** New guidelines for diagnosis of cardiac sarcoidosis in Japan. *Ann Nucl Cardiol.* 2017 Aug 10;3(1):42-45. doi: [10.17996/anc.17-00042](https://doi.org/10.17996/anc.17-00042)
43. **Tanada Y, Sato Y, Sawa T, Fujiwara H, Takatsu Y.** Serial measurement of high-sensitivity cardiac troponin I and N-terminal proB-type natriuretic peptide in a patient presenting with cardiac sarcoidosis. *Intern Med.* 2012;51(24):3379-81. doi: [10.2169/internalmedicine.51.8334](https://doi.org/10.2169/internalmedicine.51.8334)
44. **Kandolin R, Lehtonen J, Airaksinen J,** et al. Usefulness of Cardiac Troponins as Markers of Early Treatment Response in Cardiac Sarcoidosis. *Am J Cardiol.* 2015 Sep 15;116(6):960-4. doi: [10.1016/j.amjcard.2015.06.021](https://doi.org/10.1016/j.amjcard.2015.06.021)
45. **Kiko T, Yoshihisa A, Kanno Y,** et al. A Multiple Biomarker Approach in Patients with Cardiac Sarcoidosis. *Int Heart J.* 2018 Sep 26;59(5):996-1001. doi: [10.1536/ihj.17-695](https://doi.org/10.1536/ihj.17-695)
46. **Jedy J, Burke AP, White CS, Kramer GBG, Frazier AA.** Cardiac sarcoidosis: the challenge of radiologic-pathologic correlation: from the radiologic pathology archives. *Radiographics.* May-Jun 2015;35(3):657-79. doi: [10.1148/rg.2015140247](https://doi.org/10.1148/rg.2015140247)
47. **Oyama-Manabe N, Manabe O, Aikawa T, Tsuneta S.** The Role of Multimodality Imaging in Cardiac Sarcoidosis. *Korean Circ J.* 2021 Jul;51(7):561-578. doi: [10.4070/kcj.2021.0104](https://doi.org/10.4070/kcj.2021.0104)
48. **Kouranos V, Tzelepis GE, Rapti A,** et al. Complementary Role of CMR to Conventional Screening in the Diagnosis and Prognosis of Cardiac Sarcoidosis. *JACC Cardiovasc Imaging.* 2017 Dec;10(12):1437-1447. doi: [10.1016/j.jcmg.2016.11.019](https://doi.org/10.1016/j.jcmg.2016.11.019)
49. **Blankstein R, Waller AH.** Evaluation of Known or Suspected Cardiac Sarcoidosis. *Circ Cardiovasc Imaging.* 2016 Mar;9(3):e000867. doi: <https://doi.org/10.1161/CIRCIMAGING.113.000867>
50. **Vita, T.,** et al., Complementary Value of Cardiac Magnetic Resonance Imaging and Positron Emission Tomography/Computed Tomography in the Assessment of Cardiac Sarcoidosis. *Circ Cardiovasc Imaging.* 2018 Jan;11(1):e007030. doi: [10.1161/CIRCIMAGING.117.007030](https://doi.org/10.1161/CIRCIMAGING.117.007030)
51. **Okasha O, Kazmirczak F, Chen KA, Farzaneh-Far A, Shenoy C.** Myocardial Involvement in Patients With Histologically Diagnosed Cardiac Sarcoidosis: A Systematic Review and Meta-Analysis of Gross Pathological Images From Autopsy or Cardiac Transplantation Cases. *J Am Heart Assoc.* 2019 May 21;8(10):e011253. doi: [10.1161/JAHA.118.011253](https://doi.org/10.1161/JAHA.118.011253)
52. **Zhang J, Li Y, Xu Q, Xu B, Wang H.** Cardiac Magnetic Resonance Imaging for Diagnosis of Cardiac Sarcoidosis: A Meta-Analysis. *Can Respir J.* 2018 Dec 17;2018:7457369. doi: [10.1155/2018/7457369](https://doi.org/10.1155/2018/7457369)
53. **Coleman GC, Shaw PW, Balfour PC Jr,** et al. Prognostic Value of Myocardial Scarring on CMR in Patients With Cardiac Sarcoidosis. *JACC Cardiovasc Imaging.* 2017 Apr;10(4):411-420. doi: [10.1016/j.jcmg.2016.05.009](https://doi.org/10.1016/j.jcmg.2016.05.009)
54. **Chareonthaitawee P, Beanlands RS, Chen W,** et al. Joint SNMMI-ASNC Expert Consensus Document on the Role of 18 F-FDG PET/CT in Cardiac Sarcoid Detection and Therapy Monitoring. *J Nucl Med.* 2017 Aug;58(8):1341-1353. doi: [10.2967/jnumed.117.196287](https://doi.org/10.2967/jnumed.117.196287)
55. **Manapragada PP, Andrikopoulou E, Bajaj N, Bhambhani P.** PET Cardiac Imaging (Perfusion, Viability, Sarcoidosis, and Infection). *Radiol Clin North Am.* 2021 Sep;59(5):835-852. doi: [10.1016/j.rcl.2021.05.009](https://doi.org/10.1016/j.rcl.2021.05.009)
56. **Okumura W, Iwasaki T, Toyama T,** et al. Usefulness of fasting 18F-FDG PET in identification of cardiac sarcoidosis. *J Nucl Med.* 2004 Dec;45(12):1989-98.
57. **Kumita S, Yoshinaga K, Miyagawa M,** et al. Recommendations for ¹⁸F-fluorodeoxyglucose positron emission tomography imaging for diagnosis of cardiac sarcoidosis-2018 update: Japanese Society of Nuclear Cardiology recommendations. *J Nucl Cardiol.* 2019 Aug;26(4):1414-1433. doi: [10.1007/s12350-019-01755-3](https://doi.org/10.1007/s12350-019-01755-3)
58. **Youssef G, Leung E, Mylonas I,** et al. The use of 18F-FDG PET in the diagnosis of cardiac sarcoidosis: a systematic review and metaanalysis including the Ontario experience. *J Nucl Med.* 2012 Feb;53(2):241-8. doi: [10.2967/jnumed.111.090662](https://doi.org/10.2967/jnumed.111.090662)
59. **Bekki M, Tahara N, Tahara A,** et al. Localization of myocardial FDG uptake for prognostic risk stratification in corticosteroid-naïve cardiac sarcoidosis. *J Nucl Cardiol.* 2021 Jul 6. doi: [10.1007/s12350-021-02684-w](https://doi.org/10.1007/s12350-021-02684-w)
60. **Coulden RA, Sonnex EP, Abele JT, Crean AM.** Utility of FDG PET and Cardiac MRI in Diagnosis and Monitoring of Immunosuppressive Treatment in Cardiac Sarcoidosis. *Radiol Cardiothorac Imaging.* 2020 Aug 27;2(4):e190140. doi: [10.1148/ryct.2020190140](https://doi.org/10.1148/ryct.2020190140)
61. **Ahmadian A, Pawar S, Govender P, Berman J, Ruberg FL, Miller EJ.** The response of FDG uptake to immunosuppressive treatment on FDG PET/CT imaging for cardiac sarcoidosis. *J Nucl Cardiol.* 2017 Apr;24(2):413-424. doi: [10.1007/s12350-016-0490-7](https://doi.org/10.1007/s12350-016-0490-7)
62. **Osborne MT, Hulten EA, Singh A,** et al. Reduction in ¹⁸F-fluorodeoxyglucose uptake on serial cardiac positron emission tomography is associated with improved left ventricular ejection fraction in patients with cardiac sarcoidosis. *J Nucl Cardiol.* 2014 Feb;21(1):166-74. doi: [10.1007/s12350-013-9828-6](https://doi.org/10.1007/s12350-013-9828-6)
63. **Uemura A, Morimoto S, Hiramitsu S, Kato Y, Ito T, Hishida H.** Histologic diagnostic rate of cardiac sarcoidosis: evaluation of endomyocardial biopsies. *Am Heart J.*

- 1999 Aug;138(2 Pt 1):299-302. doi: [10.1016/s0002-8703\(99\)70115-8](https://doi.org/10.1016/s0002-8703(99)70115-8)
64. **Kandolin R, Lehtonen J, Graner M**, et al. Diagnosing isolated cardiac sarcoidosis. *J Intern Med.* 2011 Nov;270(5):461-8. doi: [10.1111/j.1365-2796.2011.02396.x](https://doi.org/10.1111/j.1365-2796.2011.02396.x)
 65. **Ardehali H, Howard DL, Hariri A**, et al. A positive endomyocardial biopsy result for sarcoid is associated with poor prognosis in patients with initially unexplained cardiomyopathy. *Am Heart J.* 2005 Sep;150(3):459-63. doi: [10.1016/j.ahj.2004.10.006](https://doi.org/10.1016/j.ahj.2004.10.006)
 66. **Ezzeddine FM, Kapa S, Rosenbaum A**, et al. Electrogram-guided endomyocardial biopsy yield in patients with suspected cardiac sarcoidosis and relation to outcomes. *J Cardiovasc Electrophysiol.* 2021 Sep;32(9):2486-2495. doi: [10.1111/jce.15191](https://doi.org/10.1111/jce.15191)
 67. **Soto-Gomez N, Peters JI, Nambiar AM.** Diagnosis and Management of Sarcoidosis. *Am Fam Physician.* 2016 May 15;93(10):840-8
 68. **Statement on sarcoidosis.** Joint Statement of the American Thoracic Society (ATS), the European Respiratory Society (ERS) and the World Association of Sarcoidosis and Other Granulomatous Disorders (WASOG) adopted by the ATS Board of Directors and by the ERS Executive Committee, February 1999. *Am J Respir Crit Care Med.* 1999 Aug;160(2):736-55. doi: [10.1164/ajrccm.160.2.ats4-99](https://doi.org/10.1164/ajrccm.160.2.ats4-99)
 69. **Judson MA, Costabel U, Drent M**, et al. The WASOG Sarcoidosis Organ Assessment Instrument: An update of a previous clinical tool. *Sarcoidosis Vasc Diffuse Lung Dis.* 2014 Apr 18;31(1):19-27.
 70. **Kupari M, Lehtonen J.** POINT: Should Isolated Cardiac Sarcoidosis Be Considered a Significant Manifestation of Sarcoidosis? Yes. *Chest.* 2021 Jul;160(1):36-38. doi: [10.1016/j.chest.2020.12.037](https://doi.org/10.1016/j.chest.2020.12.037)
 71. **Tezuka D, Terashima M, Kato Y**, et al. Clinical characteristics of definite or suspected isolated cardiac sarcoidosis: application of cardiac magnetic resonance imaging and 18F-Fluoro-2-deoxyglucose positron-emission tomography/computerized tomography. *J Card Fail.* 2015 Apr;21(4):313-22. doi: [10.1016/j.cardfail.2014.12.004](https://doi.org/10.1016/j.cardfail.2014.12.004)
 72. **Simonen P, Lehtonen J, Kandolin R**, et al. F-18-fluorodeoxyglucose positron emission tomography-guided sampling of mediastinal lymph nodes in the diagnosis of cardiac sarcoidosis. *Am J Cardiol.* 2015 Nov 15;116(10):1581-5. doi: [10.1016/j.amjcard.2015.08.025](https://doi.org/10.1016/j.amjcard.2015.08.025)
 73. **Juneau D, Nery P, Russo J**, et al. How common is isolated cardiac sarcoidosis? Extra-cardiac and cardiac findings on clinical examination and whole-body 18 F-fluorodeoxyglucose positron emission tomography. *Int J Cardiol.* 2018 Feb 15;253:189-193. doi: [10.1016/j.ijcard.2017.09.204](https://doi.org/10.1016/j.ijcard.2017.09.204)
 74. **Giudicatti L, Marangou J, Nolan D, Dembo L, Baumwol J, Dwivedi G.** The Utility of Whole Body ¹⁸F-FDG PET-CT in Diagnosing Isolated Cardiac Sarcoidosis: The Western Australian Cardiac Sarcoid Study. *Heart Lung Circ.* 2020 Jan;29(1):e1-e6. doi: [10.1016/j.hlc.2019.07.007](https://doi.org/10.1016/j.hlc.2019.07.007)
 75. **Kawai H, Sarai M, Kato Y**, et al. Diagnosis of isolated cardiac sarcoidosis based on new guidelines. *ESC Heart Fail.* 2020 Oct;7(5):2662-2671. doi: [10.1002/ehf2.12853](https://doi.org/10.1002/ehf2.12853)
 76. **Sperry BW, Oldan J, Hachamovitch R, Tamarappoo BK.** Insights into biopsy-proven cardiac sarcoidosis in patients with heart failure. *J Heart Lung Transplant.* 2016 Mar;35(3):392-393. doi: [10.1016/j.healun.2015.12.005](https://doi.org/10.1016/j.healun.2015.12.005)
 77. **Chazal T, Varnous S, Guihaire J**, et al. Sarcoidosis diagnosed on granulomas in the explanted heart after transplantation: Results of a French nationwide study. *Int J Cardiol.* 2020 May 15;307:94-100. doi: [10.1016/j.ijcard.2019.12.066](https://doi.org/10.1016/j.ijcard.2019.12.066)
 78. **Blauwet LA, Cooper LT.** Idiopathic giant cell myocarditis and cardiac sarcoidosis. *Heart Fail Rev.* 2013 Nov;18(6):733-46. doi: [10.1007/s10741-012-9358-3](https://doi.org/10.1007/s10741-012-9358-3)
 79. **Bharati S, Surawicz B, Vidaillet HJ Jr, Lev M.** Familial congenital sinus rhythm anomalies: clinical and pathological correlations. *Pacing Clin Electrophysiol.* 1992 Nov;15(11 Pt 1):1720-9. doi: [10.1111/j.1540-8159.1992.tb02960.x](https://doi.org/10.1111/j.1540-8159.1992.tb02960.x)
 80. **Moravsky G, Ofek E, Rakowski H**, et al. Myocardial fibrosis in hypertrophic cardiomyopathy: accurate reflection of histopathological findings by CMR. *JACC Cardiovasc Imaging.* 2013 May;6(5):587-96. doi: [10.1016/j.jcmg.2012.09.018](https://doi.org/10.1016/j.jcmg.2012.09.018)
 81. **Yafasova A, Fosbøl EL, Schou M**, et al. Long-Term Adverse Cardiac Outcomes in Patients With Sarcoidosis. *J Am Coll Cardiol.* 2020 Aug 18;76(7):767-777. doi: [10.1016/j.jacc.2020.06.038](https://doi.org/10.1016/j.jacc.2020.06.038)

TO CITE THIS ARTICLE:

Mathai SV, Patel S, Jorde UP, Rochlani Y. Epidemiology, Pathogenesis, and Diagnosis of Cardiac Sarcoidosis. *Methodist DeBakey Cardiovasc J*. 2022;18(2):78-93. doi: 10.14797/mdcvj.1057

Submitted: 01 November 2021

Accepted: 07 January 2022

Published: 14 March 2022

COPYRIGHT:

© 2022 The Author(s). This is an open-access article distributed under the terms of the Attribution-NonCommercial 4.0 International (CC BY-NC 4.0), which permits unrestricted use, distribution, and reproduction in any noncommercial medium, provided the original author and source are credited. See <https://creativecommons.org/licenses/by-nc/4.0/>.

Methodist DeBakey Cardiovascular Journal is a peer-reviewed open access journal published by Houston Methodist DeBakey Heart & Vascular Center.