

A new percutaneous nephrolithotomy position in horseshoe kidney: 45 degrees sided prone

Onur Karsli, Murat Ustuner, Bekir Voyvoda, Omur Memik, Ahmed Omer Halat, Levent Ozcan

Health Sciences University, Derince Training and Research Hospital, Department of Urology, Kocaeli, Turkey

Citation: Karsli O, Ustuner M, Voyvoda B, Memik O, Halat AO, Ozcan L. A new percutaneous nephrolithotomy position in horseshoe kidney: 45 degrees sided prone. Cent European J Urol. 2020; 73: 349-354.

Article history

Submitted: May 6, 2020
Accepted: July 23, 2020
Published online: Aug. 7, 2020

Corresponding author

Onur Karsli
Health Sciences University
Derince Training and
Research Hospital
Department of Urology
Ibni Sina Mah. Lojman
Sokak
Kocaeli, Turkey
phone: +905 3363 698 23
onurkarsli@yahoo.com

Introduction In this study we aimed to determine the effects of the 45 degrees sided prone position to the surgeon's comfort, operation time, fluoroscopy time and complications at the operation of percutaneous nephrolithotomy (PCNL) for the treatment of kidney stone of horseshoe kidney (HK) or rotation anomaly kidney.

Material and methods Thirty eight patients (25 male, 13 female) with renal calculi and HK, underwent PCNL. After the amplatz sheath was inserted into the collecting system, the patients in group 1 (n:20) were taken to the 45 degrees side position to the side of the operation and patients in group 2 (n:18) were operated in classical prone position. Operative data of two groups were compared statistically.

Results Mean stone size of group 1 was $557.8 \pm 244.8 \text{ mm}^3$ (188–1175) and group 2 was $590.7 \pm 172.8 \text{ mm}^3$ (423–909) ($p = 0.639$). In group 1 mean operation time was 78.6 ± 21.8 (45–120) minutes and in group 2 was 95.05 ± 11.5 (69–120) minutes. The difference for operation time was statistically significant and shorter in the sided group ($p = 0.02$).

Conclusions The working position of rigid nephroscope is 90 degrees to the body after the dorsomedial or dorsolateral access. In our study the position of patient is laterally sided 45 degree and the flexion on the surgeon's shoulder was minimised. This new position described for PCNL in HK allows comfortable working position for surgeon after upper pole posterior calyces access.

Key Words: ◊ horseshoe kidney ◊ kidney stones ◊ percutaneous nephrolithotomy ◊ prone ◊ position

INTRODUCTION

One of the most common renal fusion anomalies is horseshoe kidney (HK) with an incidence of 0.25% [1]. The anatomical position of the pelvis and calyces and the high insertion of the ureter in comparison with a normal kidney cause more prevalence of complications in HK [2]. HK is thought to be associated with an increased incidence of stone disease. The prevalence of urolithiasis in HK has been reported to be 20–60% [3, 4].

Percutaneous nephrolithotomy (PCNL) is the most widely used method in HK patients who have failed other therapies and is the treatment of choice for stones larger than 20 mm [5, 6]. Many various safe and effective changes in patient positioning for

PCNL have been proposed over the years, including a reverse lithotomy position [7], prone split-leg position [8], lateral decubitus position [9,10], supine position [11], and Galdakao-modified supine Valdivia (GMSV) position [12].

An ideal patient position would provide good anesthetic conditions and ergonomics with minimal intraoperative complications [13]. In HK, the needle access is generally made to the upper posterior calyces because of the rotation of the kidney. The working angle of the nephroscope to the patient is 90 degrees. This working angle complicates the handling of the instruments for the surgeon. We sided the patient's position 45 degrees to the surgeon's side and saw that the use of instruments was easier than in the prone position. In this study we aimed to deter-

mine the effects of the 45 degrees sided prone position to the surgeon's comfort, operation time, fluoroscopy time and complications of the operation of PCNL for the treatment of kidney stones within HK or rotational anomaly kidney.

MATERIAL AND METHODS

Thirty-eight patients (25 male, 13 female) with renal calculi and HK were enrolled in this prospective study. Patients underwent a PCNL procedure which was performed by two surgeons between September 2014 and January 2020. All patients were evaluated with a detailed medical history and physical examination, complete blood count, serum biochemistry, urinalysis, urine culture, and coagulation tests. Each patient underwent a comprehensive preoperative and postoperative radiologic assessment, including plain abdominal radiography, non-contrast and contrast computed tomography (CT). Estimated stone size was calculated by using Ackermann's formula (volume = $0.6 \times \pi \times r^2$) (r is the half of largest diameter of the stone) and recorded in the data.

An open-ended 5 F ureteral catheter (Marflow™, Marflow AG, Switzerland) was placed in the ureter and was guided by cystoscopy with the patient in the lithotomy position under general anesthesia. After placement, the patient was moved to the prone position. The anatomy of the pelvicalyceal system was visualized with radio-opaque material that was instilled using the ureteral catheter under C-arm fluoroscopy. A 19.5-gauge percutaneous needle (Percutaneous Access Needle, Boston Scientific Corporation, MA, USA) was introduced into the posterior upper calyx system upright in the body. Fluoroscopy was used to place a guidewire (Zebra™ Nitinol Guidewire, Boston Scientific Corporation, MA, USA) in the collecting system for access. The tract was dilated up to 30 F with semi-rigid amplatz dilators (Boston Scientific Microvase Amplatz Tractmaster™, Boston Scientific Corporation, MA, USA) and an Amplatz sheath was inserted into the collecting system (Figure 1).

Patients were divided into 2 groups. Twenty patients were operated in the sided prone position and 18 patients were operated in the prone position.

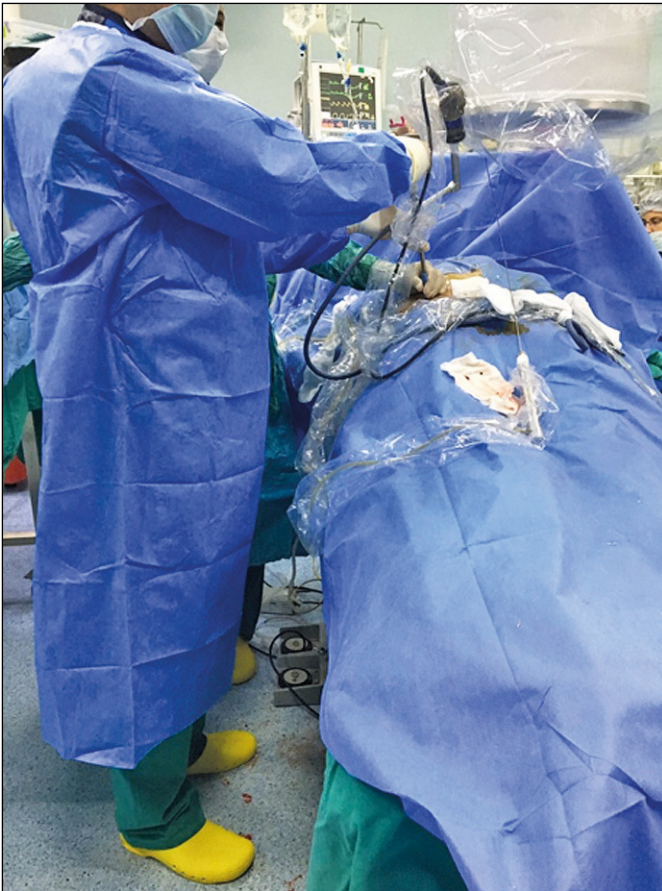


Figure 1. Percutaneous nephrolithotomy in classical prone position.

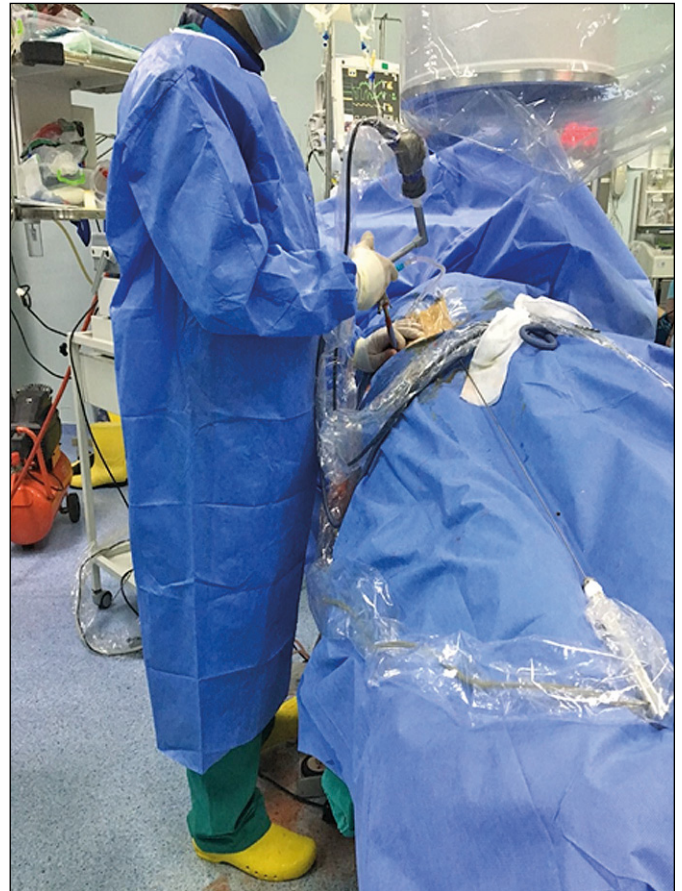


Figure 2. Percutaneous nephrolithotomy in sided prone position.

The randomization of the patients was made by a surgical nurse. The nurse decided in which position the operation will be performed on the day of operation. In the sided prone group, the patient was taken to the 45 degrees sided position to the side of the operator (Figure 2). After the patient was placed in the prone position, the patient was tied to the operation table at the hips, legs and shoulders to avoid possible slips and falls. Then, the patients were placed in a side position. Stone fragmentation was performed using a pneumatic lithotripter (Calculith™ Lithotripter, PCK, Turkey) through a 28 F rigid nephroscope (Karl Storz™ Endoscopy-America Inc.) in both groups. Stone fragments were collected by using forceps and the operations were ended after placement of a 14 F re-entry nephrostomy catheter.

Residual stone situation, operation time, fluoroscopy time and complications were recorded in the data. Residual stone situation was evaluated with low dose computed tomography in the postoperative first month. The patients with no residual fragments were assessed as stone free [14]. Complications were graded according to the Clavien-Dindo classification system which includes 5 grades [15]. Grade 1 and 2 complications require no surgical and radiological interventions. Blood transfusion and total parenteral nutrition were classified as grade 2 complications and grade 3 complication requires surgical or radiological intervention.

Visual Analog Scale (VAS) is a method for measuring pain intensity dimensionally. VAS is a 10 centimeter (100 mm) line and the patient is asked to place a mark on the VAS line at the point which defines their pain degree. VAS score of the surgeon's shoulder, arm and back pain was recorded at 15, 30, 60, 90 minutes after the entry of nephroscope to the kidney. Additionally, in operations longer than 90 minutes one more VAS score was recorded at the end of the operation.

Statistical analysis

Statistical evaluation was completed using the Statistical Package For Social Sciences program version 18 (SPSS Inc). Quantitative measurements are summarized as the mean and standard deviation (the median and the minimum-maximum where necessary). For the comparison of quantitative measurements between the operation groups, Student's T Tests were used when appropriate; Mann-Whitney U tests were used if the assumptions for Student's T Tests were violated. Results were assessed at a 95% confidence interval, and $p < 0.05$ was accepted as statistically significant.

Table 1. Characteristics of patients and operative data

	Group 1	Group 2	P
Patient number (n)	20	18	
Mean age (year)	39.5 ±10.2	39.8 ±9.9	0.712
Male / Female (n)	12 / 8	13 / 5	0.573
Mean stone size (mm ³)	557.8 ±244.8 (188–1175)	590.7 ±172.8 (423–909)	0.639
Operating time (min)	78.6 ±21.8 (45–120) (76)	95.05 ±11.5 (69–120) (95)	0.002
Fluoroscopy time (min)	7.25 ±2.5 (7)	7 ±1.6 (7)	0.724
Stone free rate	75%	61.1%	0.216
Nephrostomy removal (day)	2.9 ±0.7 (2–4)	2.8 ±0.7 (2–4)	0.785
Transfusion rate	5%	16%	0.125

Table 2. Surgeons' mean VAS score

VAS score	Group 1	Group 2	P
15 min	0.15	0.55	0.764
30 min	0.5	2.05	0.634
45 min	1.15	2.94	0.258
60 min	1.62	3.5	<0.005
90 min	1.85	4.3	<0.005
End of operation	2	5.08	<0.005

VAS – Visual Analog Scale

RESULTS

There were 38 patients (25 male, 13 female) included to the study. Group 1 patients were operated on in the sided prone position and group 2 patients were in the prone position. Mean age of group 1 was 39.5 ±10.2 years and group 2 was 39.8 ±9.9 years ($p = 0.712$). Mean stone size of group 1 was 557.8 ±244.8 mm³ (188–1175) and group 2 was 590.7 ±172.8 mm³ (423–909). There were no statistically significant differences between the groups for stone burden ($p = 0.639$). In group 1 mean operation time was 78.6 ±21.8 (45–120) minutes and in group 2 was 95.05 ±11.5 (69–120) minutes. The difference for operation time was statistically significant and shorter in the sided group ($p = 0.02$) (Table 1).

Four patients required blood transfusion (Clavien grade 2) and 1 of these patients was in group 1 and 3 of them were in group 2. None of the patients had fever and lung or bowel complications after surgery. There was no complication due to the positioning of the patients from prone to the sided prone position. In all patients, the urethral foley catheter was removed on the first postoperative day.

DISCUSSION

PCNL is classically performed in the prone position, with well-documented safety and efficacy. The supine position, conversely, has anesthetic advantages, but results in poorer ergonomics and increased surgical difficulty [15, 16]. While previous original articles provided no rationale for the prone approach it nevertheless became the standard for the procedure. In this study a 45 degree sided prone position has advantages for the easy approach and good ergonomics for the surgeon.

In patients with a HK, upper pole percutaneous access is often recommended, because upper pole access allows access to the upper pole calices, renal pelvis, lower pole calices, pelviureteral junction, and proximal ureter [17, 18]. After the dorsomedial or dorsolateral access, the working position of the rigid nephroscope is 90 degrees to the body. In the normal positioned kidneys after lower pole access, the surgeon's forearm angle is flexion of the elbow without any shoulder angulation.

The dorsomedial or dorsolateral access to the kidney makes the position of nephroscope right angled to the patient's body. Because of the rotation of the kidney in the HK the surgeon's position is flexion of shoulder to maintain the vertical position of nephroscope. In the HK with high stone burden, the operation time will increase and the surgeon's arm and shoulder can get tired because of the vertical working position. This difficulty is only in handling the nephroscope. Additionally after the insertion of forceps or lithotripter, the arm will rise up and the wrist will turn down to control the forceps. It is difficult to maintain the arm and wrist in this position. This fatigue can increase the complication rate. In our study the position of the patient is laterally sided at 45 degrees and the flexion on the surgeon's shoulder was minimised. Surgeons' arm, shoulder or back pain was questioned after surgery. VAS score of the surgeons at 15, 30 and 45 minutes into the operations were not different between the groups. But there were a statistically significant difference between the groups for surgeons' VAS score at 60, 90 and later minutes. Surgeons' VAS scores were lower in the sided prone group (Table 2). Working in the laterally sided position mimics the lower pole access in a normal kidney and maintains the surgeon's comfort.

In the literature, ultimately stone-free rates following PCNL in the HK were reported to be within the range of 72–91% [19, 20, 21]. In our data stone-free rate was 81.2% and consistent with the literature. There was no significant difference between the groups for stone-free rates.

Although there are publications in the literature reporting selective embolization due to postoperative bleeding because of the fact that the vessels of the horseshoe kidneys enter the anteromedial hilus and the calyces are oriented towards the posterior, the risk of vessel injury is no higher than in normal kidneys [17, 22]. In the literature transfusion rates were reported as 0–13.3% [23, 24]. In our study a decrease in hemoglobin was seen in 7 patients but only 4 patient required a transfusion. In patients with HK anomalies, adjacent organ injury in PCNL is a risk. El-Nahas et al. have reported colon perforation rates in PCNL with HK as 5.9% [24]. Shokeir et al. reported only one colon perforation in their 34 PCNL patients with horseshoe kidney and the patient had retrorenal colon [21]. Some investigators recommend a preoperative CT evaluation in horseshoe kidney patients [25]. None of the patients we operated with the technique described had any adjacent organ injury but it is not an advantage of this position as we dilate the kidney in the prone position and after the dilation we transfer the patient to the side position.

The operating time with our technique was also evaluated in our study. A recent systematic review by Falahatkar et al. [26] found that the mean operating time of prone and supine PCNL was 99 min and 81 min, respectively. This is comparable with the mean operating time in our own study, which was 78.6 min in group 1 and 95 min in group 2. We found a significant difference between the study groups for operating time. We explained this difference with the easier use of instruments and not getting tired early in group 1.

Proietti et al. stated that the renal sheath angle parallel to the ground is one of the advantages of the supine position. The advantage of this angle to the prone position has been reported as a decrease in intrarenal pressure and spillage of fragments [27]. Since the angle of the sheath, which is 90 degrees to the ground in horseshoe kidney, will be parallel to the ground in the position we have defined, it may contribute to the reduction in intra-renal pressure. Another disadvantage of the upright sheath is the risk of 'bumping into the nephroscope' or 'displacing the nephroscope' which may occur more frequently in the classical prone position. In the sided prone position this risk decreases.

In a multicentre study of Vicentini et al., it has been stated that horseshoe PCNL can be safely applied in the supine position, as well as the prone position [28]. There are advantages in supine PCNL such as not having to reposition the patient, easy access to the intubation tube, covering the patient only once, and a short operative time. Since the sheath is in the

downward position in the supine PCNL, intrarenal fluid pressure and pyelovenous return of the contaminated fluid may be less. However, the nephroscope control and the use of forceps can be ergonomically difficult in the sheath standing downward. In our position the working comfort of the surgeon is superior.

CONCLUSIONS

This study shows that our PCNL position is feasible, efficacious, and safe. This new position described for PCNL in HK allows for a comfortable working position for the surgeon after upper pole posterior calyces access. According to our series, the described technique for PCNL in HK should be an option. Nevertheless these results must be confirmed by further studies.

CONFLICTS OF INTEREST

The authors declare no conflicts of interest.

ETHICAL STATEMENTS

Health Science University Kocaeli Derince Education and Research Hospital ethical committee approved this study. File number: 2019/45.

HUMAN AND ANIMAL RIGHTS AND INFORMED CONSENT

This article does not contain any studies with human or animal subjects performed by any of the authors.

INFORMED CONSENT

Written informed consent was obtained from patients for surgical procedure.

We declare that our manuscript entitled 'A new percutaneous nephrolithotomy position for the treatment of horseshoe kidney stones with the comfort advantage for surgeon: 45 degrees sided prone'. We must also state that the protocol for the research project has been approved by a suitably constituted Ethics Committee of the institution with in which the work was undertaken and that it conforms to the provisions of the Declaration of Helsinki (as revised in Tokyo 2004).

References

- Evans RM. Percutaneous access in difficult kidney. In: Sosa, R.E (ed). Textbook of Endourology, 1st ed. 1997; Philadelphia, WB Saunders, pp. 114-128.
- Etemadian M, Maghsoudi R, Abdollahpour V, Amjadi M. Percutaneous nephrolithotomy in horseshoe kidney: our 5-year experience. *Urol J*. 2013; 10: 856-860.
- Yohannes P, Smith AD. The endourological management of complications associated with horseshoe kidney. *J Urol*. 2002; 168: 5-8.
- Raj GV, Auge BK, Weizer AZ, et al. Percutaneous management of calculi within horseshoe kidneys. *J Urol*. 2003; 170: 48-51.
- Ozden E, Bilen CY, Mercimek MN, Tan B, Sarikaya S, Sahin A. Horseshoe kidney: does it really have any negative impact on surgical outcomes of percutaneous nephrolithotomy? *Urology*. 2010; 75: 1049-1052.
- Sacak V DM, Ozkan S, Toktas MG, Unluer SE, Kuçukpolat S. Atnalı Böbrekli Hastalarda Perkütan Nefrolitotomi Deneyimlerimiz. *İstanbul Tıp Dergisi*. 2011; 12: 25-29.
- Lehman T, Bagley DH. Reverse lithotomy: modified prone position for simultaneous nephroscopic and ureteroscopic procedures in women. *Urology*. 1988; 32: 529-531.
- Grasso M, Nord R, Bagley DH. Prone split leg and flank roll positioning: simultaneous antegrade and retrograde access to the upper urinary tract. *J Endourol*. 1993; 7: 307-310.
- Kerbl K, Clayman RV, Chandhoke PS, Urban DA, De Leo BC, Carbone JM. Percutaneous stone removal with the patient in a flank position. *J Urol*. 1994; 151: 686-688.
- Gofrit ON, Shapiro A, Donchin Y, et al. Lateral decubitus position for percutaneous nephrolithotripsy in the morbidly obese or kyphotic patient. *J Endourol*. 2002; 16: 383-386.
- Valdivia Uría JG, Valle Gerhold J, López López JA, et al. Technique and complications of percutaneous nephroscopy: experience with 557 patients in the supine position. *J Urol*. 1998; 160 (6 Pt 1): 1975-1978.
- Scoffone CM, Cracco CM, Cossu M, Grande S, Poggio M, Scarpa RM. Endoscopic combined intrarenal surgery in Galdakao-modified supine Valdivia position: a new standard for percutaneous nephrolithotomy? *Eur Urol*. 2008; 54: 1393-1403.
- Wei Gan JJ, Lia Gan JJ, Hsien Gan JJ, Lee KT. Lateral percutaneous nephrolithotomy: A safe and effective surgical approach. *Indian J Urol*. 2018; 34: 45-50.
- Suarez-Ibarrola R, Hein S, Miernik A. Residual stone fragments: clinical implications and technological innovations. *Curr Opin Urol*. 2019; 29: 129-134.
- Tefekli A, Karadag MA, Tepeler K, et al. Classification of percutaneous nephrolithotomy complications using the modified Clavien grading system: Looking for a standard. *Eur Urol*. 2008; 53: 184-190.
- Basiri A, Ziaee SA, Nasseh H, et al. Totally ultrasonography-guided percutaneous nephrolithotomy in the flank position. *J Endourol*. 2008; 22: 1453-1457.
- Janetschek G, Kunzel KH. Percutaneous nephrolithotomy in horseshoe kidneys. *Applied anatomy and clinical experience*. *Br J Urol*. 1988; 62: 117-122.
- Razvi S, Zaidi Z. Percutaneous nephrolithotomy (PCNL) in horseshoe kidneys. *J Pak Med Assoc*. 2007; 57: 222-225.
- Tepeler A, Sehgal PD, Akman T, et al. Factors affecting outcomes of percutaneous nephrolithotomy in horseshoe kidneys. *Urology*. 2014; 84: 1290-1294.
- Lingeman JE, Chee SK. Percutaneous operative procedure in horseshoe kidneys. *J Urol*. 1999; 161: 371.

21. Shokeir AA, El-Nahas AR, Shoma AM, et al. Percutaneous nephrolithotomy in treatment of large stones within horseshoe kidneys. *Urology*. 2004; 64: 426-429.
22. Segura JW, Patterson DE, LeRoy AJ, et al. Percutaneous removal of kidney stones: review of 1,000 cases. *J Urol*. 1985; 134: 1077-1081.
23. Miller NL, Matlaga BR, Handa SE, Munch LC, Lingeman JE. The presence of horseshoe kidney does not affect the outcome of percutaneous nephrolithotomy. *J Endourol*. 2008; 22: 1219-1225.
24. El-Nahas AR, Shokeir AA, El-Assmy AM, et al. Colonic perforation during percutaneous nephrolithotomy: study of risk factors. *Urology*. 2006; 67: 937-941.
25. Skoog SJ, Reed MD, Gaudier FA Jr, Dunn NP. The posterolateral and the retrorenal colon: implication in percutaneous stone extraction. *J Urol*. 1985; 134: 110-112.
26. Falahatkar S, Mokhtari G, Teimoori M. An Update on Supine Versus Prone Percutaneous Nephrolithotomy: A Meta-analysis. *Urol J*. 2016; 13: 2814-2822.
27. Proietti S, Rodríguez-Socarrás ME, Eisner B, et al. Supine percutaneous nephrolithotomy: tips and tricks. *Transl Androl Urol*. 2019; 8(Suppl 4): S381-S388.
28. Vicentini FC, Mazzucchi E, Gökce MI, et al. Percutaneous Nephrolithotomy in Horseshoe Kidneys: Results of a Multicentric Study. *J Endourol*. 2020; 10: 1089. ■