

The Management of Postsurgical Pyoderma Gangrenosum following Breast Surgery

Kylie M. Edinger, MD*
Venkat K. Rao, MD†

Background: Postsurgical pyoderma gangrenosum is a rare condition characterized by ulcerative lesion development at surgical sites. It is frequently misdiagnosed as infection and mismanaged with surgical debridement, which only worsens the condition. Achieving the correct diagnosis is crucial to delivering the appropriate medical therapy. This article presents four clinical cases of postsurgical pyoderma gangrenosum in breast surgery patients, and proposes a work-up schematic to aid in its diagnosis based on literature review and author experience.

Methods: Four patients who developed postsurgical pyoderma gangrenosum following breast surgery were identified by chart review at our institution.

Results: The cases include two breast reduction patients, an abdominally based breast reconstruction patient, and a breast augmentation patient. The time to diagnosis and treatment varied greatly between the patients, with diagnosis achieved as early as 13 days postoperatively to as late as one year postoperatively. Two of the four patients were initially mismanaged with surgical debridement, and all patients were treated with at least one course of antibiotics for a misdiagnosis of surgical site infection before they were correctly diagnosed.

Conclusions: Postsurgical pyoderma gangrenosum is a rare, ulcerative condition that is difficult to diagnose and often mismanaged with surgical debridement. Diagnosis requires a high clinical suspicion and should be considered in patients with ulcerative lesions resistant to antibiotic therapy, in patients who have bilateral lesions with NAC sparing, and in those with systemic inflammatory conditions. Diagnosis is usually delayed, so it is imperative that surgeons keep this diagnosis in mind when treating breast patients with postsurgical wounds. (*Plast Reconstr Surg Glob Open* 2022;10:e4282; doi: 10.1097/GOX.0000000000004282; Published online 25 April 2022.)

INTRODUCTION

Postsurgical pyoderma gangrenosum is an inflammatory condition characterized by ulcerative lesion development at surgical sites that is often misdiagnosed as postoperative infection. It is most commonly associated with breast surgery and is frequently mismanaged with surgical debridement of wounds, which only worsens the condition. Achieving the correct diagnosis is imperative to delivering the correct treatment, which consists of medical management with either immunosuppressants or immunomodulators. This article presents four

clinical cases of postsurgical pyoderma gangrenosum in breast surgery patients at our institution, and reviews their clinical course and treatment regimens. This article also proposes a work-up schematic to aid in the diagnosis of postsurgical pyoderma gangrenosum based on literature review and author experience.

BACKGROUND

Pyoderma gangrenosum (PG) is a noninfectious inflammatory condition of the skin that results in rapidly progressing necrotic, ulcerative lesions.^{1,2} It is rare, affecting three to 10 patients per million, and is often misdiagnosed as an infection.^{3,4} PG is a clinical diagnosis of exclusion and can only be made after infection, vasculitis, and neoplasm have been ruled out.⁵

Although underlying systemic inflammation, neutrophil malfunction, and genetic predispositions are thought to be linked to the development of PG, the exact cause is

From the *Division of Plastic Surgery, University of Wisconsin, Madison, Wis.; and †Division of Plastic Surgery, University of Wisconsin, Madison, Wis.

Received for publication January 31, 2022; accepted March 4, 2022.

Copyright © 2022 The Authors. Published by Wolters Kluwer Health, Inc. on behalf of The American Society of Plastic Surgeons. This is an open-access article distributed under the terms of the [Creative Commons Attribution-Non Commercial-No Derivatives License 4.0 \(CCBY-NC-ND\)](#), where it is permissible to download and share the work provided it is properly cited. The work cannot be changed in any way or used commercially without permission from the journal.

DOI: 10.1097/GOX.0000000000004282

Disclosure: The authors have no financial interest to declare in relation to the content of this article.

Related Digital Media are available in the full-text version of the article on www.PRSGlobalOpen.com.

not well understood. It can be triggered secondary to skin trauma or surgery in a phenomenon known as pathergy, which has been reported in 20%–30% of PG patients.³ Postsurgical pyoderma gangrenosum (PSPG) is most commonly associated with breast surgery, accounting for 25% of all PSPG cases.¹ Lesion onset can develop anywhere from several days to several weeks after surgery.⁶

Initial treatment of PSPG is often debridement based on a misdiagnosis of surgical wound infection.⁵ Surgical debridement worsens lesion progression secondary to pathergy, and management recommendations are nonsurgical wound care with systemic immunosuppression and immunomodulation.¹ A diagnosis is important to avoid worsening the condition with incorrect management.

The authors present a case series describing the clinical course of four breast surgery patients complicated by postsurgical pyoderma gangrenosum. The cases include two breast reduction patients, an abdominally based breast reconstruction patient, and a breast augmentation patient.

CASE SERIES

Patient A

History

Patient A was a 50-year-old White woman with a history of right breast infiltrative ductal carcinoma who requested autologous bilateral breast reconstruction. She had mastectomies 9 months prior, and delayed her reconstruction until after she completed radiation.

Hospital Course

Nine months following her mastectomies, she had bilateral DIEP autologous breast reconstruction. She was treated preoperatively with prophylactic antibiotics (2g cefazolin) before incisions were made, and her operation was without complications.

The patient spiked a fever to 39.3°C on postoperative day (POD) 4, and a standard infectious work-up was performed, including urine cultures, blood cultures, and chest x-ray. Her work-up was negative and her examination was without any signs of infection. She was started on a prophylactic 7 day course of Keflex. She had no further fevers and was discharged the following day.

After discharge, the right side of her abdominal incision became red, painful, and warm to the touch. On POD 8, she was admitted to the hospital for IV antibiotics (Vancomycin/Zosyn) for concerns of surgical site infection. She developed bilateral breast ulcerations, raising suspicion for an inflammatory process and biopsy of the left breast mastectomy skin ulceration was taken on POD 10.

The patient had surgical debridement of her bilateral breast and abdominal wounds on POD 12 for suspected infection while biopsy results were pending. Intraoperative bacterial and fungal cultures were obtained and remained negative. On POD 21, her biopsy results showed a dense neutrophilic infiltrate consistent with pyoderma gangrenosum and dermatology was consulted.

Takeaways

Question: How do we help clinicians recognize postsurgical pyoderma gangrenosum in breast surgery patients to arrive at a faster diagnosis and initiate appropriate medical therapies sooner?

Findings: In our four case examples, half the patients were initially mismanaged with surgical debridement, and all were mismanaged with antibiotics before they were correctly diagnosed. Time to diagnosis varied from 13 days postoperatively to 1 year. Once patients received the appropriate medical treatments; all went on to heal.

Meaning: Post-surgical pyoderma gangrenosum remains a difficult condition to diagnose, and we present four breast surgery case examples as well as a novel diagnostic schematic to assist with earlier diagnosis.

Treatment

On POD 21, patient A was started on oral prednisone at 60mg per day, with an anticipated duration of 4–8 weeks. Her prednisone was decreased to 40mg per day after 1 week of treatment and subsequently weaned over the following weeks. She was discharged home on POD 36 from her original breast reconstruction surgery, 29 days after her initial development of ulcerations.

Outcomes

Patient A went on to develop a flare of her PG on attempted steroid wean 6 weeks after discharge to home from the hospital, and was transitioned to cyclosporine with great success. After 3 months of wound VAC therapy, the patient was transitioned to dressing changes and went on to heal her wounds by secondary intention. (See figure, **Supplemental Digital Content 1**, which displays the photograph of Patient A 9 days after surgical debridement, with extensive ulcerative wounds to her bilateral breast and abdominal incisions. <http://links.lww.com/PRSGO/C7>.)

Patient B

History

Patient B was a 35-year-old woman who presented as a consultation from the emergency department, with concerns of a breast infection 8 months after breast reduction. She had a history of Crohn's disease controlled with Humira. She was an active smoker, smoking one half-pack of cigarettes daily.

Hospital Course

Patient B had an inferior pedicle bilateral breast reduction with Wise pattern skin excision at another hospital. She was treated preoperatively with prophylactic antibiotics (2g cefazolin) before incisions were made, and her operation was without complications. In total, 652g of breast tissue was resected from the left breast, with 710g resected from the right breast.

On POD 10, she presented to the emergency department with increasing pain and redness in both breasts. She was afebrile with no wounds or signs of infection and had a leukocytosis of 14.6K per μ L. On POD 21, she

developed a small area of drainage around her left NAC, which was cultured. She was started on Keflex 500 mg QID for 10 days for concerns of surgical site infection. Her culture was positive for pan-sensitive *Staphylococcus aureus*.

Five weeks after surgery she presented to the emergency department with worsening bilateral breast wound breakdown. She was treated with trimethoprim-sulfamethoxazole. She followed-up with her plastic surgeon 3 days later, where she was thought to have wound breakdown secondary to smoking. She was referred to the wound care clinic for wound management.

Despite months of wound care from the wound clinic, patient B's wounds continued to progress. Her plastic surgeon elected to proceed with surgical debridement and re-closure 5 months after her initial surgery. Postoperatively she developed recurrent dehiscence of the left breast incision, and was taken back to the operating room for further debridement and skin grafting.

Six weeks later, she presented to another emergency department with fevers, increasing breast pain, and concerns for left breast infection. She was prescribed Keflex. Three days later, she presented to our emergency department, where she had an inert 8×8cm wound along the inferior left breast. She was discharged with wound care.

Eleven months after her initial breast reduction surgery (and 3 months after she presented to our emergency department), she developed a right breast ulceration. Given the chronicity of her wounds, dermatology was consulted for suspected pyoderma gangrenosum. She received a biopsy of her ulcerations and was diagnosed with pyoderma gangrenosum 1 year after her original breast reduction surgery.

Treatment

After patient B was successfully diagnosed with pyoderma gangrenosum, she was started on an oral steroid taper starting with 60 mg prednisone daily, decreasing by 10 mg every 5 days down to 5 mg daily.

Outcomes

Upon finishing the steroid taper, patient B developed worsening breast wounds requiring a course of Bactrim after wound cultures resulted positive for MRSA. One week later, she presented to the emergency department in sepsis with tachycardia and a leukocytosis of 26K per uL. Her acute PG flare with superimposing infection was treated nonoperatively, and her ulcerations went on to heal by secondary intention (Fig. 1).

Patient C

History

Patient C was a 24-year-old woman who presented to the clinic requesting bilateral breast reduction. She had no medical history aside from obesity and did not take any medications. She was a size 36-DDD cup bra size and had a BMI of 32.44 preoperatively.

Hospital Course

Patient C underwent an inferior pedicle bilateral breast reduction with Wise pattern skin excision. She was treated preoperatively with prophylactic antibiotics (2g cefazolin) before incisions were made, and her operation was without complications. A total of 1264g of breast tissue was resected from the right breast, with 1180g resected from the left breast.

At her 1 week postoperative appointment, she had a small wound at the right breast T junction with no signs of infection. On POD 8, she developed new wounds along the left breast incision extending from her nipple to inframammary fold, with increasing breast pain and serous drainage from bilateral incisions. She was afebrile and her wounds were mildly erythematous but without signs of infection. She was started on prophylactic Bactrim.

On POD 12, she had worsening wounds along her bilateral incisions with skin sloughing and serous drainage. The wounds were full thickness with no intact dermis, and the wound edges were "shaggy and overhanging with

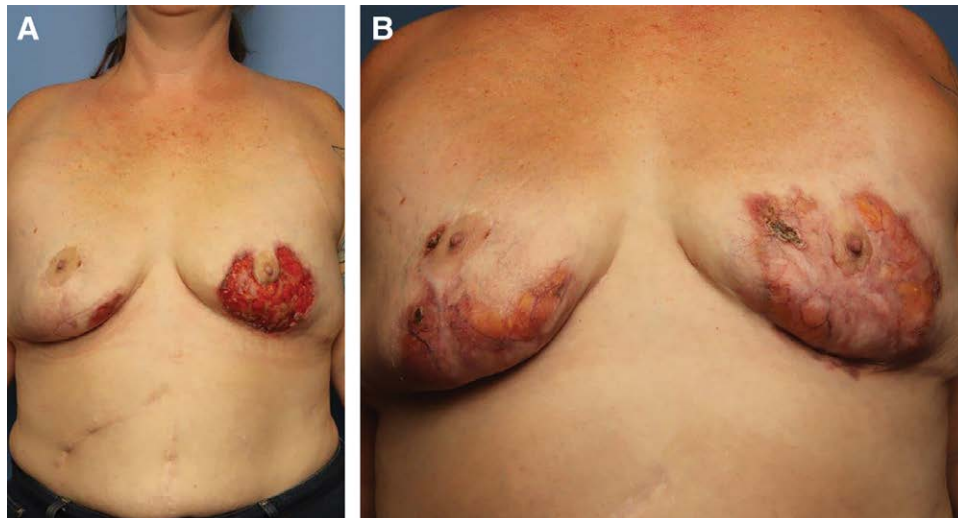


Fig. 1. Photographs of patient B's PSPG wounds taken (A) 3 months after she was diagnosed with pyoderma gangrenosum and started on appropriate therapy and (B) 9 months after her diagnosis (3 months after photograph A).

surrounding inflammation, and minimal surrounding erythema beyond the undermined borders.” There were no signs of infection. Her wounds were concerning for pyoderma gangrenosum, and she saw dermatology the following day. She was diagnosed with pyoderma gangrenosum in the dermatology clinic on POD 13.

Treatment

After patient C was successfully diagnosed with pyoderma gangrenosum, she was started on cyclosporine 175 mg twice daily (the upper end of 4–5 mg/kg/day dosing) as well as a prednisone taper of 60 mg daily for 1 week followed by 40 mg daily for 1 week ending with 20 mg daily for 1 week.

Outcomes

One week after starting her medical treatment for PG, patient C was seen in clinic. She had extensive wounds of bilateral breast incisions and the left nipple-areolar complex. She finished her steroid taper and was started on topical tacrolimus and cyclosporine 5 weeks postoperatively.

She was seen again 3 months after surgery, at which point all of her wounds had healed aside from one small wound on her right breast inframammary fold. She was no longer taking cyclosporine because of worsening renal function and had started topical clobetasol and another prednisone taper. She was last seen in clinic 5 months postoperatively where she continued to have a small wound on the right breast with a new small wound along the right nipple-areola complex. She receives periodic Kenalog injections and ILK10 treatments with dermatology to her wounds and has continued on topical clobetasol (Fig. 2).

Patient D

History

Patient D was a 33-year-old White woman who requested bilateral breast augmentation. She had a history of anxiety and was otherwise healthy.

Hospital Course

Patient D underwent bilateral subpectoral breast augmentation using 325 mL saline breast implants (Mentor smooth round high profile) through a 5 cm submammary incision. She was treated preoperatively with prophylactic

antibiotics (2 g cefazolin) before incisions were made, and her operation was without complications.

At her one week postoperative visit, her incisions were healing well. The following morning she called into clinic, with a 5 mm opening to her left breast incision with serosanguinous drainage. On POD 23, she developed dehiscence of bilateral breast incisions with necrotic ulcerations, but no symptoms of systemic illness. Cultures were taken, which were positive for *Pseudomonas aeruginosa*, and she was started on a 1 week course of levofloxacin.

She underwent surgical removal of her exposed bilateral breast implants on POD 29 with drain placement. Given the concerning examination findings for pyoderma gangrenosum, the patient was referred to dermatology on the day of her implant removal. She was seen in the dermatology clinic on POD 32 from her original augmentation surgery, where she was preliminarily diagnosed with pyoderma gangrenosum. Her intraoperative pathology resulted 1 week later, confirming the diagnosis.

Treatment

After patient D was successfully diagnosed with pyoderma gangrenosum, she was started on a 1 week course of oral prednisone 60 mg once daily.

Outcomes

10 days after starting her medical treatment for pyoderma gangrenosum, patient D was seen in clinic. She had near complete healing of her bilateral breast incisions aside from a small healing wound at her left drain site (Fig. 3).

DISCUSSION

Pyoderma gangrenosum is a difficult condition to diagnose, and is often initially misdiagnosed as a surgical site infection. It has a predilection for breast surgery patients, which is not well understood. PG is often a clinical diagnosis of exclusion made only after ruling out sources of infection, vasculitis, and neoplasm. PG ulcerations can be distinguished clinically by their characteristic violaceous undermined border and surrounding zone of erythema. One of the pathognomonic features of PSPG in breast surgery is a sharp demarcation between the area of ulceration and the border to the nipple-areolar complex, as the

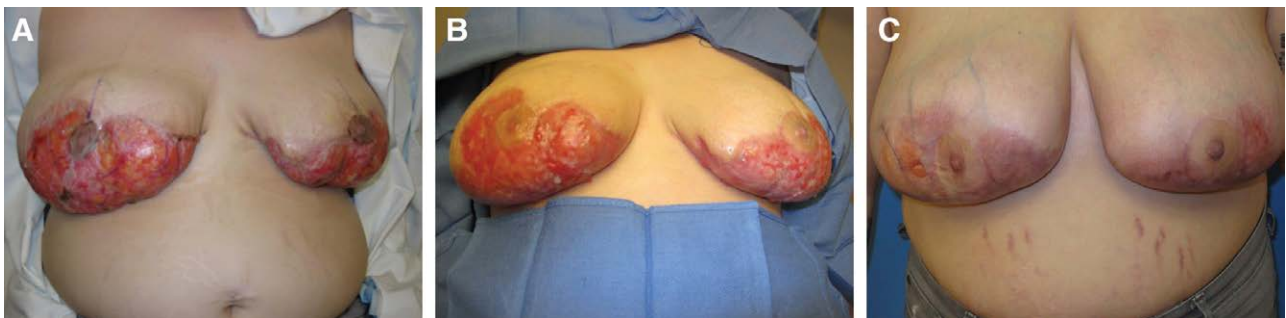

Fig. 2. Photographs of patient C’s PSPG wounds taken (A) 2 weeks after her initial breast surgery with full thickness wounds to the right nipple-areola complex, (B) 8 weeks after her initial breast surgery demonstrating the extent of her bilateral wounds, and (C) 5 months after her initial breast surgery with significant wound healing.

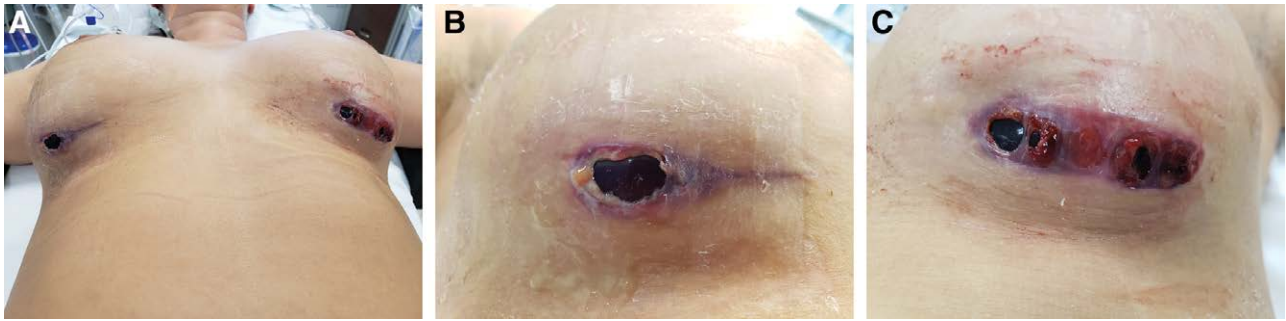


Fig. 3. Photographs of patient D’s PSPG wounds 29 days after her original breast augmentation, on the day of her breast implant removal, showing bilateral breast wound breakdown (A), right breast close-up (B), and left breast close-up (C).

nipple-areola complex is usually spared.¹ Of note, PSPG is not restricted to develop at surgical sites and can develop at distant IV sites, abdominal donor sites for breast reconstruction, or other unrelated sites of trauma.

Per Callen and Jackson, a diagnostic work-up should start with a biopsy and pathologic evaluation of the lesion, and should include basic laboratory tests and blood work to evaluate for autoimmune diseases such as antinuclear antibody, rheumatoid factor, and antiphospholipid antibody assays to rule out other causes for the lesion (Fig. 3).⁷ Patients may also be recommended to undergo gastrointestinal testing to rule out active bowel disease and malignancy as well as chest radiographs to rule out infections and signs of vasculitis.

Pathology of PG lesion biopsies will be nonspecific, demonstrating abundant neutrophils in the absence of bacteria, and the condition will remain unresponsive to antibiotic therapies. Given the lack of definitive diagnostic criteria, Su et al established major and minor diagnostic guidelines in 2004 to aid in accurate diagnosis of the condition.⁸ The major criteria include painful pustules with a surrounding halo, shallow ulcerations with pain out of proportion, and uncomfortable erosions. Minor criteria

include neutrophilic dermal infiltrates with granulomas on pathology with no evidence of malignancy or infection, patient history of systemic illnesses, and evidence of pathology with preceding surgery or cutaneous trauma.^{8,9} (Fig. 4).

Due to high rates of misdiagnosis, PG patients are often initially mismanaged with surgical debridement of the lesions. This only leads to lesion progression, which is why most research is devoted to obtaining the correct initial diagnosis. The literature has focused on describing typical courses of PSPG patients to help inform and guide surgeons to obtain the diagnosis and start the appropriate treatment course earlier.

Zuo et al performed a systematic review in 2014 and identified 220 cases of postsurgical pyoderma gangrenosum reported in the literature from 1946 to 2013.¹ They discovered that breast surgery was the most common surgery to trigger PG (25%), followed by cardiothoracic (14%), abdominal (14%), and OBGYN surgeries (13%). The most common breast surgeries to trigger PG were reduction mammoplasty (45%), breast reconstruction (25%), and augmentation mammoplasty (7%). They found that most patients developed wound dehiscence

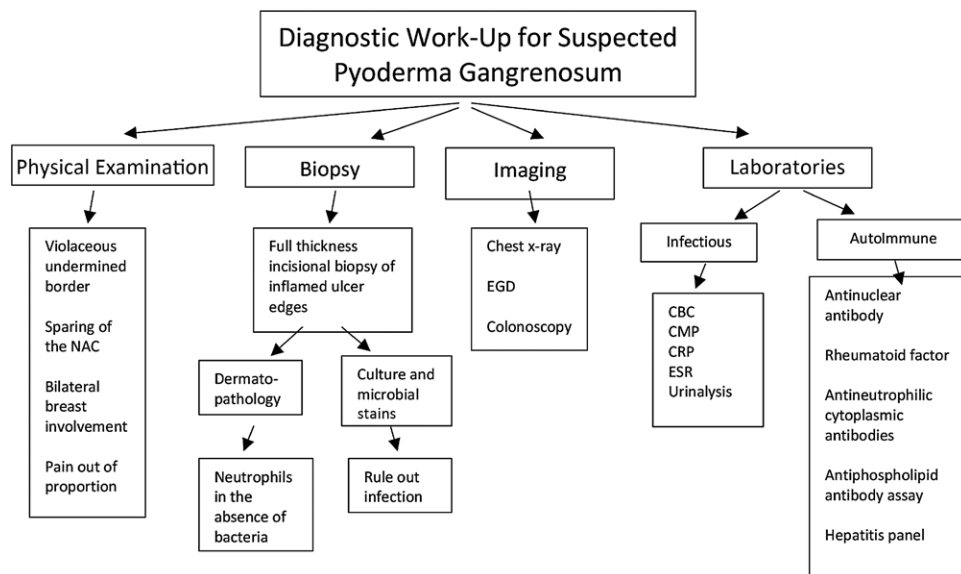


Fig. 4. Work-up schematic for pyoderma gangrenosum.

at an average of 7 days after surgery. The lesions typically started out as isolated pustules and lesions, coalescing into a large exudative ulcer within days.

Tuffaha et al conducted in 2016 a large systemic review examining 49 PSPG cases related specifically to breast surgery.¹⁰ They found 30% of patients had an underlying autoimmune condition, and 17% had wound cultures positive for bacteria or fungus. It took on average 6 days to develop PG lesions after surgery. Of the bilateral breast surgeries performed, 88% had development of bilateral PSPG. Of the abdominally based breast reconstruction surgeries performed, 86% had abdominal donor site lesions. Nipple involvement was spared in 89% of cases. They found that two-thirds of patients initially underwent surgical debridement for a misdiagnosis of infection. They describe skin grafting as a means to speed up wound healing, but only after the ulcerations were controlled with medical therapy.

Ehrl et al performed a large systematic review in 2018 of 68 articles and 87 cases of postsurgical pyoderma gangrenosum in breast surgery patients.¹¹ The majority of cases (44%) were following breast reduction surgery. Fifty-four percent of patients had an underlying malignancy or autoimmune condition, and again the median time from surgery to development of dehiscence was 7 days. The correct diagnosis was achieved on average 12.5 days from initial symptom onset. An estimated 45% of patients presented with fever, and 43% had a leukocytosis. In total, 88% were found to have negative microbiological testing. They discovered that 81% of women presented with bilateral wound dehiscence, and 77% had sparing of the NAC. There were no cases where PG solely affected the NAC.

Treatment of postsurgical pyoderma gangrenosum is not surgical, and surgical debridement of PG can result in worsening ulcerations. Most patients are successfully managed with oral or IV steroids (1 mg/kg/day) or immunosuppressive agents such as cyclosporine or tacrolimus. On average, 84% of patients are treated with steroids and 22% are treated with cyclosporine.¹¹ Patients usually demonstrate completed wound healing within 5 months of starting appropriate medical management.¹¹

When operating on patients with a known history of PG, perioperative corticosteroids or immunomodulators have been shown to diminish the rates of surgical-induced flares.¹ Additionally, Long et al recommends using subcuticular sutures in patients with a history of PG to minimize trauma to the skin, and the use of synthetic sutures to minimize additional inflammation.¹²

CONCLUSIONS

Postsurgical pyoderma gangrenosum is a rare, ulcerative condition that is difficult to diagnose, and often mismanaged with surgical interventions that exacerbate the disorder. Diagnosis requires a high clinical suspicion and should be considered in patients with ulcerative lesions

resistant to antibiotic therapy, in patients who have bilateral lesions with NAC sparing, and in those with systemic inflammatory conditions. Symptoms typically develop 1 week after surgery, and may be accompanied by leukocytosis and fever. Diagnosis is usually delayed, sometimes by several months, and such delays can result in unnecessary surgeries and other potentially harmful treatments. This article provides a novel schematic to aid in the work-up and diagnosis of postsurgical pyoderma gangrenosum in an effort to minimize such delays. Treatment is usually steroids, and patients may require a prolonged duration of immunosuppression before complete wound healing. It is imperative that surgeons keep this diagnosis in mind when treating breast patients with postsurgical wounds.

Venkat K. Rao, MD

600 Highland Avenue

Box 3236, Clinical Science Center

Madison, WI 53792

E-mail: rao@surgery.wisc.edu

REFERENCES

1. Zuo KJ, Fung E, Tredget EE, et al. A systematic review of postsurgical pyoderma gangrenosum: identification of risk factors and proposed management strategy. *J Plast Reconstr Aesthet Surg.* 2015;68:295–303.
2. Marinopoulos S, Theofanakis C, Zacharouli T, et al. Pyoderma Gangrenosum of the breast: a case report study. *Int J Surg Case Rep.* 2017;31:203–205.
3. Braswell SF, Kostopoulos TC, Ortega-Loayza AG. Pathophysiology of pyoderma gangrenosum (PG): an updated review. *J Am Acad Dermatol.* 2015;73:691–698.
4. Larcher L, Schwaiger K, Eisendle K, et al. Aesthetic breast augmentation mastopexy followed by post-surgical pyoderma gangrenosum (PSPG): clinic, treatment, and review of the literature. *Aesthetic Plast Surg.* 2015;39:506–513.
5. Guaitoli G, Piacentini F, Omarini C, et al. Post-surgical pyoderma gangrenosum of the breast: needs for early diagnosis and right therapy. *Breast Cancer.* 2019;26:520–523.
6. Solis E, Salindera S, Kanesalingam K, et al. Post-surgical pyoderma gangrenosum of the breast: a diagnostic dilemma? *ANZ J Surg.* 2020;90:E89–E90.
7. Callen JP, Jackson JM. Pyoderma gangrenosum: an update. *Rheum Dis Clin North Am.* 2007;33:787–802, vi.
8. Su WP, Davis MD, Weenig RH, et al. Pyoderma gangrenosum: clinicopathologic correlation and proposed diagnostic criteria. *Int J Dermatol.* 2004;43:790–800.
9. Grillo MA, Cavalheiro TT, da Silva Mulazani M, et al. Postsurgical pyoderma gangrenosum complicating reduction mammoplasty. *Aesthetic Plast Surg.* 2012;36:1347–1352.
10. Tuffaha SH, Sarhane KA, Munding GS, et al. Pyoderma gangrenosum after breast surgery: diagnostic pearls and treatment recommendations based on a systematic literature review. *Ann Plast Surg.* 2016;77:e39–e44.
11. Ehrl DC, Heidekrueger PI, Broer PN. Pyoderma gangrenosum after breast surgery: a systematic review. *J Plast Reconstr Aesthet Surg.* 2018;71:1023–1032.
12. Long CC, Jessop J, Young M, et al. Minimizing the risk of post-operative pyoderma gangrenosum. *Br J Dermatol.* 1992;127:45–48.