

Case Report

Possible unaware intoxication by anticoagulant rodenticide

Simin Dashti-Khavidaki^{1,2}, Saba Ghaffari², Mohsen Nassiri-Toossi³, Mohsen Amini⁴, Maryam Edalatifard⁵

¹Nephrology Research Center, Tehran University of Medical Sciences, Tehran, Iran

²Department of Clinical Pharmacy, Tehran University of Medical Sciences, Tehran, Iran

³Department of Gastroenterology, Imam-Khomeini Hospital Complex, Tehran University of Medical Sciences, Tehran, Iran

⁴Department of Medicinal Chemistry, Tehran University of Medical Sciences, Tehran, Iran

⁵Department of Internal Medicine, Imam-Khomeini Hospital Complex, Tehran University of Medical Sciences, Tehran, Iran

Received: July 2014

Accepted: August 2014

Corresponding author:
Dr. Simin Dashti-Khavidaki,
E-mail: dashtis@sina.tums.ac.ir

ABSTRACT

Superwarfarin toxicity may be a serious problem. It needs high clinical suspicion in patients with bleeding diathesis without hematologic or liver diseases even in patients with apparent negative history of warfarin or other anticoagulant accessibility. Here we reported a patient with a negative history of any medical diseases or drug administration who was referred with generalized ecchymosis. Increased international normalized ratio and decreased vitamin K-dependent coagulation factors were detected in this patient. His hematologic and liver evaluations were normal. Clinical pharmacist emphasis in taking history revealed using anticoagulant rodenticide all over the farm the patient lived in that might result in unaware intoxication in this patient who suffered dementia.

Keywords: Anticoagulant rodenticides; intoxication; poisoning; superwarfarin rodenticides

INTRODUCTION

Superwarfarin rodenticides (brodifacoum, difenacoum, and bromodialone) are long-acting vitamin K antagonists that have been used since 1970s. Their serum half-lives differ from 16 to 220 days. They are 100 times more potent than warfarin in inhibiting Vitamin K epoxide reductase enzyme.^[1-3]

Up to 2009, >16,000 cases of intoxication by anticoagulant rodenticides have been reported to the

toxic exposure surveillance system of poison control center of the United States.^[4] Most of these intoxication cases happened by accidental ingestion in children, suicide, or homicide.^[4-7] There is also a possible case of superwarfarin intoxication without a definite history of its exposure.^[8] Here, we report a middle age man with dementia who was referred with epistaxis, epigastric pain and generalized ecchymosis. Whose family denied use of any drug or other substances by the patient, but health-care team was suspicious for intoxication with an anticoagulant agent.

CASE REPORT

The 60-year-old man was referred to Imam-Khomeini Hospital Complex, affiliated to the Tehran University of Medical Sciences, Tehran, Iran on February 10, 2013 with the chief complaint of epistaxis, epigastric pain and ecchymosis over his arms, legs and abdomen.

Access this article online



Website: www.jrpp.net

DOI: 10.4103/2279-042X.145394

Symptoms started from >20 days ago, without any past medical history except for dementia. The patient had been hospitalized for 23 days before being referred to our center in an urban hospital in North of Iran. As evident from his discharge report form of that hospital, his initial laboratory data at that center was white blood cell count (WBC) count of $8.2 \times 10^3/\mu\text{L}$ and platelet (Plt) count of $309 \times 10^3/\mu\text{L}$ and international normalized ratio (INR) of 6. Only fresh frozen plasma (FFP) was administered for him at that hospital. In spite of receiving FFP, his INR did not decrease continuously. Symptoms did not improve, and he was referred to our hospital. At our hospital, his physical examinations and vital signs were normal except for ecchymosis over his arms, legs and abdomen. His laboratory tests revealed a hemoglobin level of 14.5 g/dL, WBC count of $15 \times 10^3/\mu\text{L}$, Plt count of $188 \times 10^3/\mu\text{L}$ and reticulocyte count of 1.9%. The prothrombin time (PT), activated partial thromboplastin time (aPTT) and INR were 39.5 s, >120 s, and 6.6 respectively. Serum activities of Factors II, VII, IX and X decreased to 7% (normal 70-120%), 2% (normal range of 55-170%), 3% (normal range of 60-150%) and 10% (normal range of 70-120%), respectively. Factor VIII activity was increased to 299% (normal range 60-150%). Factor V activity was normal at 85% (normal range of 60-130%). His serum fibrinogen concentration was 402 mg/dL (normal range of 200-400 mg/dL). The renal, liver, and thyroid function tests showed no abnormalities. Hematologic disorders were ruled out for him by normal bone marrow aspiration and peripheral blood smear. Abdominal and pelvic ultrasonography and electrocardiography did not show any pathologic finding. Magnetic resonance imaging (MRI) of his brain at admission day revealed a subdural hematoma in right occipital region. Endoscopy showed duodenal ulcer and his *Helicobacter pylori* test were positive. His diet seemed to contain a sufficient amount of Vitamin K as reported by his daughter and son. His past medical history and family history were negative for any diseases with bleeding diathesis. His drug history contained only acetaminophen and acetaminophen codeine for osteoarthritis. Although his family members stated that none of the family member use warfarin, clinical pharmacist was suspicious about intoxication by warfarin or a warfarin-like substance. By asking exact questions regarding warfarin-like substances, clinical pharmacist found that they were using rodenticides for rats in their farm that they were settled in. Patient's daughter reported that rats died with mouth-bleeding. This revealed that they used anticoagulant containing rodenticides not strychnine containing ones. The patient suffered dementia and sometimes went out of the room and did not remember where he went or what he ate. Therefore, possible reason for his coagulopathy could be toxicity by superwarfarin rodenticides. In addition to triple

therapy of duodenal ulcer by pantoprazole, amoxicillin and clarithromycin, due to intracerebral hematoma in his brain MRI intravenous (IV) Vitamin K 10 mg twice daily was administered for him.^[9] After the first 2 days of Vitamin K administration, his INR decreased to 3 and 1.48, respectively. Due to lack of exact evidence of toxicity with warfarin-like substances, Vitamin K administration was stopped, and patient was monitored. INR increased gradually and reached to 3.78 4 days later. Daily dose of 10 mg IV Vitamin K was restarted for him. The patient's INR fell to 1.66, after 1st day of this Vitamin K administration, however INR fluctuated between 1.6 and 2.7 during later several days. Patients' INR changes during hospitalization have been shown in Figure 1. A serum sample was taken for assessment of superwarfarin rodenticides by gas chromatography; however, no anticoagulant substance was detected. This may be due to very low concentration of the suspicious substances after a long-time gap from patient's first hospitalization and sample gathering for such assessment (about 1 month). After 10 days of hospitalization, the patient was discharged in good clinical condition improved ecchymosis and no gastric pain. He was discharged on 20 mg/day oral Vitamin K and weekly monitoring of INR as outpatient. His family members were educated to care the patient in order to have no access to rodenticides. They were provided informed consent form for reporting patient's medical history anonymously. One month later by telephone follow-up, her daughter stated that her father had stable INR of 1.5 for the past two consecutive weeks. She was advised to refer to an internist in their city for Vitamin K discontinuation and INR follow-up.

DISCUSSION

Intoxication with superwarfarin rodenticides have to be considered for any patient with prolonged PT, aPTT, INR

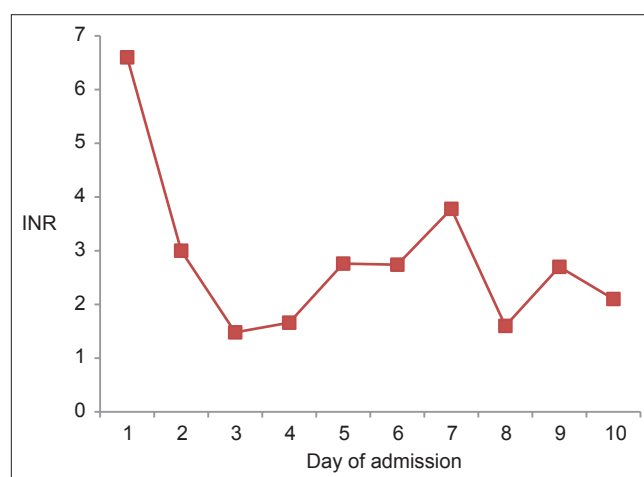


Figure 1: Patients' international normalized ratio (INR) changes during hospitalization

and decreased Vitamin K-dependent coagulation factors especially when INR fluctuates on Vitamin K therapy.^[8] Liver dysfunction as a major cause of increased PT and INR and decreased Vitamin K-dependent coagulation factors was ruled out in our patient by normal liver enzymes, serum albumin concentration, and especially normal serum Factor V level as another coagulation factor that is synthesized by the liver. High consumption of coagulation factors (as seen in disseminated intravascular coagulopathy) was ruled out in our patient by high concentration of serum Factor VIII activity.^[10] Therefore the main clinical suspicious in this patient was poisoning by a Vitamin K-antagonist agent as was emphasized by clinical pharmacist. Clinical pharmacists play substantial roles in detection and management of adverse drug reaction, drug interactions and medication errors in Imam-Khomeini Hospital Complex.^[11,12] With taking exact history, clinical pharmacist found that patient's family was using rodenticide all over their farm, which they lived in. Reported mouth-bleeding in death rats clarified that the used rodenticides were anticoagulant types. This increased clinical pharmacist's suspicious for superwarfarin poisoning in this patient although this suggestion was not confirmed by detection of these substances in patient's blood sample. This failure may be due to long-time from the last exposure of the patient to these rodenticides since he was hospitalized for approximately 1 month at the time of blood sampling. However, INR fluctuation on Vitamin K therapy as seen in our patient is well-reported in superwarfarin rodenticide intoxication even after a long-time after their consumption.^[8] This case highlights the importance of caring old-aged patients especially who suffer dementia and cannot identify what they eat. They may be at risk for unaware intoxication. The health-care workers in poison control centers are usually alert for intoxication in suicidal cases or in the case of accidental poisoning in children that are usually detected by parents; however, all clinicians should think about unaware intoxication in their practice.

Superwarfarin toxicity may be a serious problem. It needs special attention and high clinical suspicious in patients with bleeding diathesis without hematologic or liver diseases even in patients with apparent negative history of warfarin or anticoagulant rodenticides accessibility. Supervision of persons who deal with rodenticides in their home or workplace, especially those suffer dementia is necessary.

AUTHORS' CONTRIBUTION

Simin Dashti-Khavidaki suggested possible intoxication in the patient and contributed in drafting and finalizing the manuscript. Saba Ghaffari contributed in the manuscript drafting. Mohsen Nassiri-Toossi suggested

possible intoxication in the patient and contributed in drafting the manuscript. Mohsen Amini contributed in detecting suspicious substances in the patient's blood sample by gas chromatography. Maryam Edalatifard contributed in the patient management and work up to rule out other possible medical diseases as the cause of patient's signs and symptoms.

REFERENCES

1. Hadler MR, Shadbolt RS. Novel 4-hydroxycoumarin anticoagulants active against resistant rats. *Nature* 1975;253:275-7.
2. Veenstra GE, Owen DE, Huckle KR. Metabolic and toxicological studies on the anticoagulant rodenticide, flocoumafen. *Arch Toxicol Suppl* 1991;14:160-5.
3. Chua JD, Friedenbergr WR. Superwarfarin poisoning. *Arch Intern Med* 1998;158:1929-32.
4. Bronstein AC, Spyker DA, Cantilena LR Jr, Green JL, Rumack BH, Giffin SL. 2008 Annual report of the American association of poison control centers' national poison data system (NPDS): 26th annual report. *Clin Toxicol (Phila)* 2009;47:911-1084.
5. Spahr JE, Maul JS, Rodgers GM. Superwarfarin poisoning: A report of two cases and review of the literature. *Am J Hematol* 2007;82:656-60.
6. Babcock J, Hartman K, Pedersen A, Murphy M, Alving B. Rodenticide-induced coagulopathy in a young child. A case of Munchausen syndrome by proxy. *Am J Pediatr Hematol Oncol* 1993;15:126-30.
7. Altay S, Cakmak HA, Boz GC, Koca S, Velibey Y. Prolonged coagulopathy related to coumarin rodenticide in a young patient: Superwarfarin poisoning. *Cardiovasc J Afr* 2012;23:e9-e11.
8. Lee JH, Kim H, Han HS, Lee KH, Kim ST. A case of superwarfarin intoxication without a definitive history of brodifacoum exposure. *Korean J Hematol* 2009;44:53-7.
9. Freeman WD, Aguilar M, Weitz J. Reversal of anticoagulation in warfarin associated intracerebral hemorrhage. In: Basow DS, editor. *UptoDate*. 2014. Available from: <http://www.Uptodate.com/home/index.html>. [Last accessed on 2014 May 01].
10. Drews RE. Approach to the adult patient with a bleeding diathesis. In: Basow DS, editor. *UptoDate*. 2014. Available from: <http://www.Uptodate.com/home/index.html>. [Last accessed on 2014 May 01].
11. Dashti-Khavidaki S, Khalili H, Hamishekar H, Shahverdi S. Clinical pharmacy services in an Iranian teaching hospital: A descriptive study. *Pharm World Sci* 2009;31:696-700.
12. Zeraatchi A, Talebian MT, Nejati A, Dashti-Khavidaki S. Frequency and types of the medication errors in an academic emergency department in Iran: The emergent need for clinical pharmacy services in emergency departments. *J Res Pharm Pract* 2013;2:118-22.

How to cite this article: Dashti-Khavidaki S, Ghaffari S, Nassiri-Toossi M, Amini M, Edalatifard M. Possible unaware intoxication by anticoagulant rodenticide. *J Res Pharm Pract* 2014;3:142-4.

Source of Support: Nil, **Conflict of Interest:** None declared.