

# Laparoscopic Management of Intestinal Obstruction Due to Phytobezoar

João Eduardo Marques Tavares de Menezes Ettinger, MD, Jadson Murilo Silva Reis, MD, Elias Luciano Quinto de Souza, MD, Euler de Medeiros Ázaro Filho, MD, PhD, Paulo Cezar Galvão do Amaral, MD, PhD, Eric Ettinger Junior, MD, Edvaldo Fahel, MD, PhD

## ABSTRACT

Phytobezoars are a rare cause of small-bowel obstruction and an accurate preoperative diagnosis is very difficult. After diagnosis, the majority of patients in this study underwent surgery. The conventional management of small-bowel obstruction is done by laparotomy. Many studies have demonstrated that laparoscopy can be an alternative to laparotomy for the treatment of small-bowel obstruction in select patients, and it also brings the benefits of minimally invasive surgery. This report demonstrates the case of a patient with intestinal obstruction caused by phytobezoar (mango seed) who was treated laparoscopically. During the laparoscopy, a hard mass 5 cm proximal to the ileocaecal junction was palpable with graspers. An ileotomy was then performed. The bezoar was extracted and inserted into a bag. In this case, the intestinal obstruction management by laparoscopy was safe and feasible.

**Key Words:** Laparoscopy, Minimally invasive, Intestinal obstruction, Bezoar, Mango.

## INTRODUCTION

Intestinal obstruction is a common surgical emergency frequently due to adhesions, tumors, inflammatory disorders, volvulus, and external or internal hernias.<sup>1</sup> Phytobezoars are a rare cause of mechanical alimentary tract obstruction.<sup>2,3</sup> They can occur mainly in patients who have undergone gastric surgery and in multiple sites of the gastrointestinal tract.<sup>2,3</sup> There are many treatments for intestinal obstruction due to phytobezoar (medical, endoscopic, and surgical) though some patients have not undergone surgery.<sup>3,4</sup>

Conventional surgical management of acute intestinal obstruction involves laparotomy.<sup>5,6</sup> Minimally invasive techniques can be used to diagnose and treat intestinal obstructions.<sup>1</sup> The use of laparoscopy in acute intestinal obstruction has been avoided by some surgeons because of technical difficulties and increased risk of bowel injury.<sup>5-7</sup> However, various studies<sup>2,3,5,7,8</sup> have reported laparoscopic management of intestinal obstructions with the improvement of laparoscopic skills. This report describes a case of small-bowel obstruction due to bezoar (mango seed) treated with laparoscopy.

## CASE REPORT

A 74-year-old male was admitted after 24 hours of abdominal pain and vomiting. The patient had accidentally ingested a mango seed 4 days before developing abdominal pain. He did not have any previous medical conditions or abdominal surgery. A physical examination showed normal vital parameters, a distended abdomen, and no evidence of peritonitis or abdominal external hernias. An abdominal x-ray revealed dilation of the small bowel and a circular image in the inferior right quadrant of the abdomen. A colonoscopy identified a hard mass in the terminal ileum, which could not be removed endoscopically. A laparoscopy by the open technique was performed with a 10-mm port placed in the umbilicus. Pneumoperitoneum was established to a maximum pressure of 13mm Hg. After an initial diagnostic laparoscopy, 2 additional 5-mm working ports were placed under direct vision, 6 cm above the umbilicus and 6cm below it in the middle line of the abdomen. The abdominal cavity

General Surgery Division, São Rafael Hospital, Department of Surgery, Escola Bahiana de Medicina e Saúde Pública. Salvador, Bahia, Brazil (all authors).

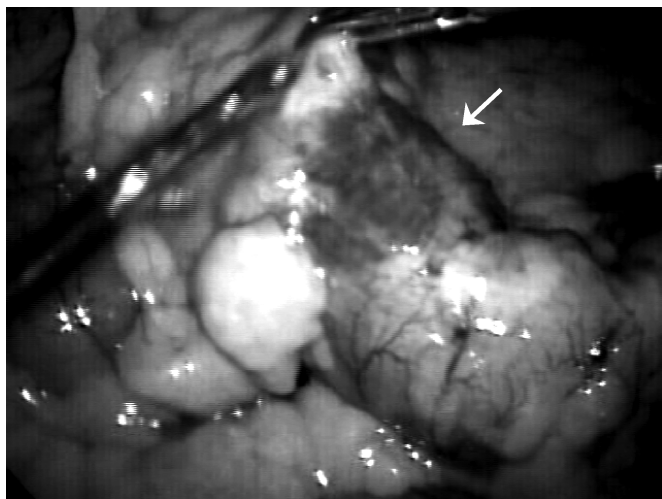
Address reprint requests to: João Eduardo Marques de Menezes Ettinger, MD, Avenida Princesa Leopoldina, nº 21, aptº 1304, Graça, CEP 40.150.080, Salvador, Bahia, Brazil. Telephone: + 55 71 3245 6907, Fax: + 55 71 3393 2332, E-mail: cirurgias@terra.com.br

© 2007 by JLS, *Journal of the Society of Laparoendoscopic Surgeons*. Published by the Society of Laparoendoscopic Surgeons, Inc.

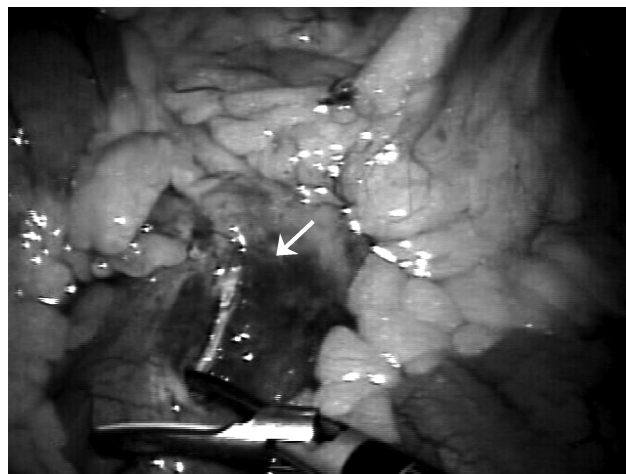
was inspected carefully with atraumatic bowel graspers to minimize the risk of bowel injury. A mechanical obstruction due to a hard intraluminal mass was located approximately 5cm from the ileocecal junction (**Figure 1**). The small bowel was examined from the ligament of Treitz to the cecum to ensure that the obstruction did not involve other areas. Also dilation of the small bowel and ascitic fluid were noted. An ileotomy was performed with a Harmonic scalpel (Ultracision – Ethicon Endo Surgery) along the longitudinal axis (**Figure 2**), which allowed the removal of a 5.0x5.0x4.0-cm phytobezoar that could not be milked towards the colon (**Figure 3**). The phytobezoar was extracted in a latex bag (**Figure 4**). A larger incision on the umbilicus was made to facilitate the removal of the bezoar. The ileotomy was closed along the longitudinal axis with interrupted suture using 3–0 Vicryl (**Figure 5**). The postoperative course was uneventful, and the patient stayed in the hospital for 4 days. The final diagnosis was intraluminal small-bowel obstruction due to phytobezoar (mango seed).

## DISCUSSION

Phytobezoars are an uncommon cause of intestinal obstruction, and an accurate preoperative diagnosis is difficult to obtain.<sup>2,3,5</sup> The main causes reported in the medical literature are oranges, coconuts, cherry tomatoes, and others.<sup>2,3</sup> They can occur mainly in patients who have undergone gastric surgery and in multiple sites of the gastrointestinal tract.<sup>2,3,6</sup> Bezoar formation has also been described in patients with coexisting illnesses affecting gastrointestinal motility, such as Guillain-Barré syndrome, myotonic dystrophy, and hypothy-



**Figure 1.** Hard intraluminal mass localized 5 cm proximal to the ileocecal junction.



**Figure 2.** Ileotomy was performed with a Harmonic scalpel (Ultracision, Ethicon Endo-Surgery) along the longitudinal axis.

roidism.<sup>1,9</sup> Patients with psychiatric illnesses are at an increased risk for bezoar formation due to the possible ingestion of hair and medications.<sup>1,10</sup>

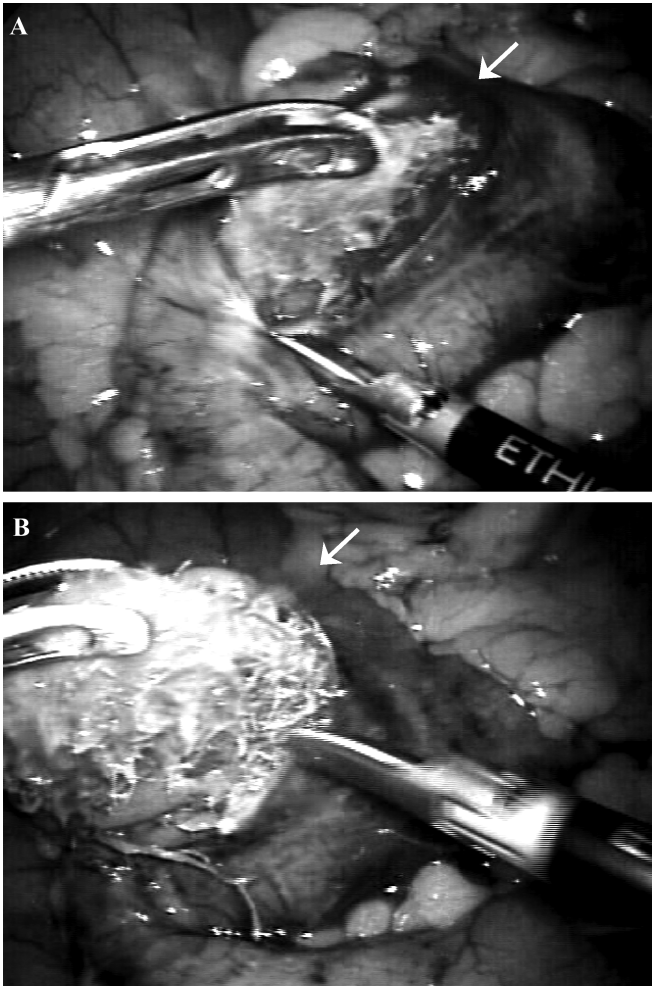
A number of surgical, endoscopic, and pharmacologic treatments have been proposed with differing results.<sup>11–13</sup> Many articles report gastric phytobezoar removal by the endoscopic technique or by using cellulase, but these are reports with few cases, the stomach is easier to access than the ileus, and a well-trained physician is needed.<sup>11,12</sup> There are a few reports about the successful treatment of phytobezoar in the ileus by endoscopy or cellulase.<sup>13</sup>

Laparotomy has been the gold standard treatment for intestinal obstruction when surgical intervention is necessary, although laparotomy itself is an independent risk factor for bowel obstruction.<sup>1,3,5,8</sup>

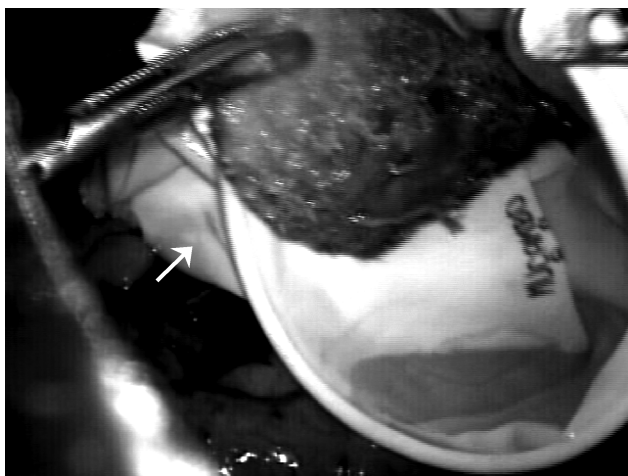In this case, we tried to remove the obstruction endoscopically, but this was not possible because the seed was adhered to the bowel and could have caused a perforation or injury. Mango seeds are very hard and the fibers very resistant; consequently, cellulose was not a good option.

With the improvement in laparoscopic techniques, many authors have considered the laparoscopic approach as an alternative to conventional laparotomy in select cases of intestinal obstruction.<sup>2,3,5–8,14</sup>

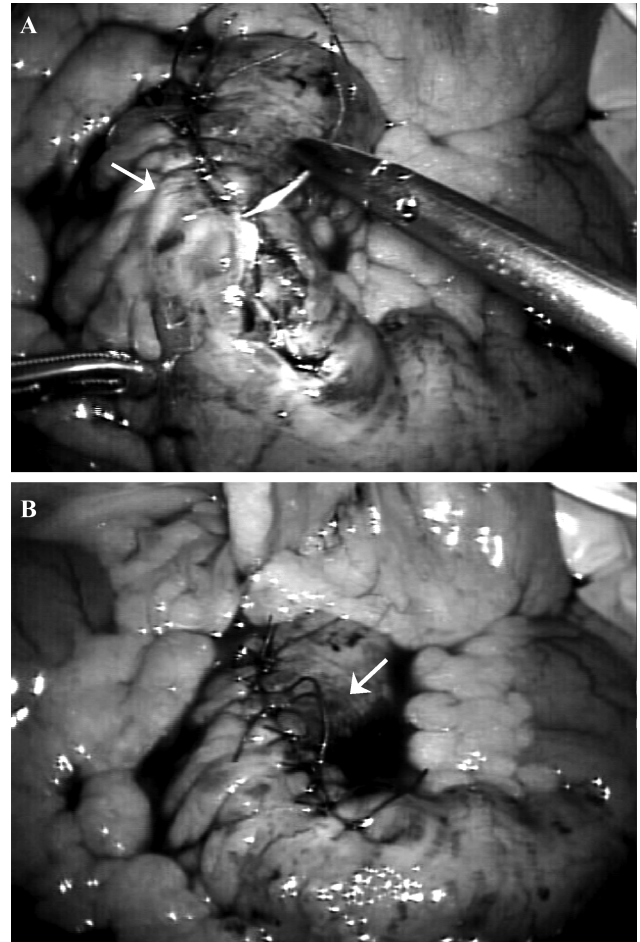
There are no defined guidelines for selecting patients with small-bowel obstruction for the laparoscopic approach.<sup>1</sup> Authors have described some criteria that may be useful to identify patients with small-bowel obstruction who can undergo laparoscopy, which include mild abdominal



**Figure 3.** Removal of 5.0 x 5.0 x 4.0 cm phytobezoar (mango seed) from ileum.



**Figure 4.** The phytobezoar was extracted in a latex bag.



**Figure 5.** The ileotomy was closed along the longitudinal axis with interrupted suture using 3-0 Vicryl.

distension, a proximal obstruction, partial obstruction, shorter duration of symptoms, and others.<sup>1,14,15</sup>

Multiple previous operations, documented intraabdominal adhesions, and sepsis are relative contraindications for laparoscopy.<sup>1,15</sup>

The literature has demonstrated postoperative complication values varying from 0% to 5.7% in patients who undergo laparoscopic treatment for intestinal obstruction compared with 0% to 18.6% for laparotomic treatment.<sup>3,6,7,14</sup>

The average postoperative ileus rate was also shorter in the laparoscopic group (range, 1.5 to 2.2 days) than in the laparotomic group (range, 3 to 4.7 days).<sup>3,6,7,14</sup>

Some reports<sup>3,7,14</sup> mention hospital stay varying from 2.5 days to 6.6 days in the laparoscopic group and 5.8 days to 16.8 days in the laparotomic group.



Some authors<sup>1,3,5,14</sup> suggest that laparoscopic surgical techniques lead to fewer intraabdominal adhesions by reducing tissue trauma.

Gentle manipulation of the intestines should be done to avoid damage to the distended and friable bowel. The open technique to place the first port is recommended for all patients with intestinal obstruction.<sup>1</sup> The procedures performed with open access are safer because the surgeon involved has a direct view of the abdominal contents; the contrary occurs when the procedure is performed in a “blind” way as is done with the Veress needle. This is very important when the patient may have a dilated bowel as in cases of bowel obstruction, because there is an increased chance of intestinal injury caused by the trocar since the bowel is closer to the abdominal wall.

Vertical incisions in the middle of the abdomen were used, because incisions could easily be increased if conversion to laparotomy was necessary.

Pneumoperitoneum was established to a maximum pressure of 13 mm Hg, because high pressures could interfere with cardiopulmonary function. Once safe access is obtained, adequate visualization is necessary to insert the remaining ports. Atraumatic graspers should be used to manipulate the friable and dilated small bowel.

In this case, the authors opened the small bowel intraabdominally because the pneumoperitoneum pressure of 13 mm Hg helped to maintain the bowel contents inside the intestine, and the mango seed was placed into a bag avoiding cavity contamination.

The enterotomy was closed longitudinally, contrary to most surgical principles, because in this case, the intestine was very fragile and the transversal closure led to more tension in the suture, and we observed the bowel lumen was sufficiently ample after the longitudinal closure.

The intestinal resection was not necessary because the bowel segment was viable without signs of necrosis. Several studies suggest that laparoscopy reduces postoperative complications, postoperative ileus, hospital stay, and adhesion formation.<sup>6,7,14</sup>

## CONCLUSION

The laparoscopic approach is a feasible method in the management of bezoar-induced intestinal obstruction when performed by a well-trained and experienced laparoscopic surgeon in select patients.

## References:

1. Ganpathi IS, Cheah WK. Laparoscopic-assisted management of small bowel Obstruction Due to Phytobezoar. *Surg Laparosc Endosc Percutan Tech.* 2005;15:30–32.
2. Schoeffl V, Varatorn R, Blinnikov O, Vidamaly V. Intestinal obstruction due to phytobezoars of banana seeds: A case report. *Asian J Surg.* 2004;27:348–351.
3. Yau K, Siu W, Law B, et al. Laparoscopic approach compared conventional open approach for bezoar induced small bowel obstruction. *Arch Surg.* 2005;140:972–975.
4. Hayanga AJ, Bass-Wilkins K, Bulkley GB. Current management of small-bowel obstruction. *Adv Surg.* 2005;39:1–33.
5. Liauw JJ, Cheah WK. Laparoscopic management of acute small bowel obstruction. *Asian J Surg.* 2005;28:185–188.
6. Wullstein C, Gross E. Laparoscopic compared with conventional treatment of acute adhesive small bowel obstruction. *Br J Surg.* 2003;90:1147–1151.
7. Suter M, Zermatten P, Halkic N, et al. Laparoscopic management of mechanical small bowel obstruction: are there predictors of success or failure? *Surg Endosc.* 2000;14:478–483.
8. Franklin ME Jr., Gonzalez JJ Jr., Miter DB, et al. Laparoscopic diagnosis and treatment of intestinal obstruction. *Surg Endosc.* 2004;18:26–30.
9. Pfau P, Ginsberg G. Foreign bodies and bezoars. In: Feldman M, Friedman LS, Sleisenger MH, eds. *Sleisenger and Fordtran's Gastrointestinal and Liver Diseases.* 7<sup>th</sup> ed. Philadelphia, PA: Saunders; 2002;395–397.
10. De Backer A, Van Nooten V, Vandenplas Y. Huge gastric trico bezoar in a 10-year-old girl: case report with emphasis on endoscopy in diagnosis and therapy. *J Pediatr Gastroenterol Nutr.* 1999;28:513–515.
11. Blam ME, Lichtenstein GR. A new endoscopic technique for the removal of gastric phytobezoars. *Gastrointest Endosc.* 2000;52:404–408.
12. Lange V. Gastric phytobezoar: an endoscopic technique for removal. *Endoscopy.* 1986;18:195–196.
13. Chae HS, Kim SS, Han SW, et al. Endoscopic removal of a phytobezoar obstructing the distal small bowel. *Gastrointest Endosc.* 2001;54:264–266.
14. Levard H, Boudet M, Msika S, et al. Laparoscopic treatment of acute small bowel obstruction: A multicenter retrospective study. *Aust N Z J Surg.* 2001;71:641–646.
15. Duh QY. Small bowel obstruction. In: Touli J, Gossot D, Hunter JG, eds. *Endosurgery,* New York, NY: Churchill Livingstone; 1996;425–431.