

# Emergency transcatheter arterial embolization for massive gastrointestinal arterial hemorrhage

Zhong Xing Shi, MM<sup>a</sup>, Jing Yang, MM<sup>a</sup>, Hong Wei Liang, MM<sup>b</sup>, Zhen Hua Cai, MM<sup>c</sup>, Bin Bai, MM<sup>a,\*</sup>

## Abstract

To evaluate the different arteriographic manifestations of acute arterial massive hemorrhage of the gastrointestinal (GI) tract and the efficacy of emergency transcatheter arterial embolization (ETAE).

A total of 88 patients with acute massive GI bleeding who experienced failure of initial endoscopy and/or conservative treatment were referred to our interventional department for acute GI arteriography from January 2007 to June 2015. After locating the source of bleeding, appropriate embolic agents, such as spring coil, hydroxyl methyl acrylic acid gelatin microspheres, polyvinyl alcohol (PVA) particles, etc., were used to embolize the targeted vessels. The angiographic manifestations and the effects of embolization of acute arterial massive hemorrhage of the GI tract were retrospectively analyzed.

Of the 88 patients, 54 were diagnosed with arterial hemorrhage of the upper GI tract and 34 with arterial hemorrhage of the lower GI tract. Eighty cases were associated with positive angiography, which showed the following: contrast extravasation (only); gastroduodenal artery stenosis; pseudoaneurysm (only); pseudoaneurysm rupture with contrast extravasation; pseudoaneurysms merged with intestinal artery stenosis; GI angiodysplasia; and tumor vascular bleeding. Eight cases were diagnosed with negative angiography. Seven-two patients underwent successful hemostasis, and a total of 81 arteries were embolized. The technical and clinical success rates (no rebleeding within 30 days) in performing transcatheter embolization on patients with active bleeding were 100% and 84.71%, respectively (72 of 85). Within 30 days, the postoperative rebleeding rate was 15.29% (13/85). Of these rebleeding cases, 2 patients were formerly treated with “blind embolization,” 7 underwent interventional embolic retreatment, and 3 had surgical operations. All cases were followed-up for 1 month, and 3 patients died from multiple organ failure. No serious complications such as bowel ischemia necrosis were observed.

ETAE is a safe, effective, and minimally invasive treatment; because of the diversified arteriographic manifestations of acute GI hemorrhage, the proper selection of embolic agents and the choice of reasonable embolization method are essential for successful hemostasis.

**Abbreviations:** CT = computed tomography, DSA = digital subtraction angiography, EATE = emergency transcatheter arterial embolization, ECG = electrocardiography, GI = gastrointestinal, PVA = polyvinyl alcohol.

**Keywords:** acute arterial massive hemorrhage, gastrointestinal, transcatheter arterial embolization

## 1. Introduction

Acute GI arterial massive hemorrhage is a common emergent condition. Massive bleeding can cause hemodynamic instability, which leads to hemorrhagic shock and even death in some

patients with serious conditions. This condition has always been a very tricky problem for clinicians.<sup>[1–4]</sup> In particular, patients experiencing failure of conservative treatment or endoscopic treatment previously needed emergency surgery, which was usually accompanied by many complications that some patients with weaker physiques could not tolerate. In recent years, with the rapid development of interventional radiology in China, interventional radiology hemostasis techniques have become increasingly important in the treatment of gastrointestinal (GI) bleeding and have led to reduced use of surgery in this clinical sphere.<sup>[5–8]</sup> Through retrospective analysis of clinical cases of GI arterial massive hemorrhage with different causes, this study aimed to explore the different arteriographic manifestations of life-threatening GI arterial massive hemorrhage, as well as the efficacy and safety of emergency transcatheter arterial embolization (ETAE) therapy.

## 2. Materials and methods

We studied 88 consecutive patients (42 men, 36 women; mean age: 61 ± 13 years old; age range: 14–76 years) with acute arterial upper or lower GI bleeding who underwent ETAE in the interventional department of our hospital from January 2007 to July 2015. Our local ethics committee approved this retrospective study. Informed consent forms were signed. An INR greater than 1.2 and a platelet count less than 150,000/μL were used to assess

Editor: Weisheng Zhang.

*Ethical approval:* This study has been approved by the ethics committee of the Second Affiliated Hospital of Harbin Medical University, and all the patients included in this study have signed the informed consent.

The authors have no conflicts of interest to disclose.

<sup>a</sup> Department of Interventional Radiology, <sup>b</sup> Department of Radiology,

<sup>c</sup> Department of Pain, the Second Affiliated Hospital of Harbin Medical University, Harbin, Heilongjiang Province, China.

\* Correspondence: Bin Bai, Department of Interventional Radiology, the Second Affiliated Hospital of Harbin Medical University, 246 Xuefu Road, Nangang District, Harbin 150086, Heilongjiang Province, China (e-mail: baibin\_shanghai@sina.com).

Copyright © 2017 the Author(s). Published by Wolters Kluwer Health, Inc. This is an open access article distributed under the terms of the Creative Commons Attribution-Non Commercial-No Derivatives License 4.0 (CCBY-NC-ND), where it is permissible to download and share the work provided it is properly cited. The work cannot be changed in any way or used commercially without permission from the journal.

Medicine (2017) 96:52(e9437)

Received: 18 May 2017 / Received in final form: 5 November 2017 / Accepted: 3 December 2017

<http://dx.doi.org/10.1097/MD.0000000000009437>

bleeding disorders. Before the procedures, there were a total of 19 cases of blood coagulation mechanism disorders in this study. In addition, blood urea nitrogen and creatinine values were used to assess the renal function of patients at the time of transcatheter mesenteric angiography; in this study, 2 cases showed renal insufficiency.

All 88 patients failed to respond to conservative hemostasis and therapeutic endoscopy. A total of 25 patients underwent examinations such as computed tomography (CT), endoscopy, and others before being subjected to interventional procedures. In this study, massive bleeding was defined as bleeding that required transfusion of at least 4 units of blood in 24 hours and was associated with hypotension (systolic blood pressure <90 mm Hg).<sup>[9]</sup> This blood loss was sufficient to endanger patients' lives. It is standard procedure to determine whether to adopt emergency interventional embolization therapy. The final decision to use interventional treatment is made by the patient's attending physician.

The main clinical manifestations of massive GI arterial hemorrhage are massive hematemesis and massive fresh blood in the stool or dark red bloody stools. Patients who are bleeding after surgery can also have large amounts of bright red blood in drainage tubes. Such acute, massive blood loss can lead to hemorrhagic shock.<sup>[8]</sup> Among this group of 88 patients, 29 had symptoms of hemorrhagic shock before interventional embolotherapy.

The equipment included an Artis Zee flat-type digital subtraction angiography (DSA) machine (Siemens, Erlangen, Germany). The 4 and 5 F catheters (RH, Yashiro, Cobra catheter) and the 2.7F SP microcatheter (Cook, Bloomington, IN) were used. The high-pressure syringe had an injection pressure of 300 to 500 psi (1 psi=0.006895 MPa). The contrast medium was Visipaque (GE Healthcare, Cork, Ireland). The embolic agents were steel coils (Cook), 3 hydroxyl methyl acrylic acid gelatin microspheres (Embosphere; Biosphere Medical Company, Rockland, MA), and polyvinyl alcohol (PVA) particles (Cook). There were 5 types of steel coils (MWCE35-3-3, MWCE35-4-3, MWCE35-5-3, MWCE35-10-8 Cook 0.018 in microcoils), 3 types of Embospheres (300–500, 500–700, 700–900  $\mu\text{m}$ ), and 2 types of PVA particles (300–500, 500–710  $\mu\text{m}$ ), which came in bottles with a capacity of 1  $\text{cm}^3$ .

All 88 of the patients signed the informed consent forms before they underwent interventional treatment. For the therapeutic intervention, the patients lay flat on the operating table. They were monitored by electrocardiography (ECG), and blood pressure, oxygen saturation, and heart rate readings were taken.

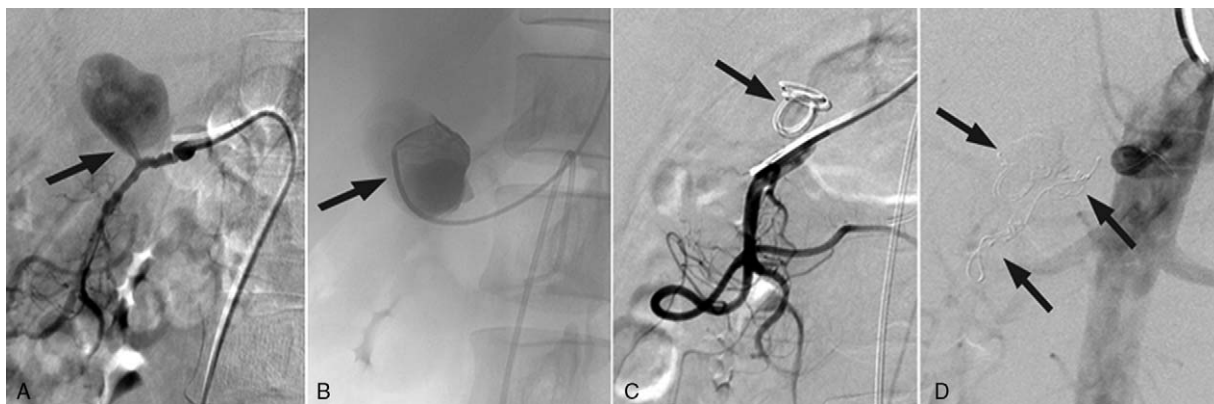
They wore an oxygen mask to keep the respiratory passages open. The patient's skin was disinfected at the inguinal region or supraclavicular region (Fig. 1) and was covered with surgical towels. After local anesthesia near the puncture site in the right groin, the right femoral artery was punctured using a modified Seldinger technique. A 4 or 5 F arterial sheath was then placed. We performed arteriography of the inferior and superior mesenteric arteries, the celiac artery and their branches. Patients with massive posttraumatic or postoperative GI bleeding also required arterial angiography of the surgical site or around the injury site. Then, based on the results at the bleeding site, we undertook superselective arteriography.

We sought direct and indirect manifestations of bleeding during arteriography. These positive manifestations included contrast extravasation, gastroduodenal artery stenosis, pseudoaneurysm, pseudoaneurysm rupture with contrast extravasation, pseudoaneurysms combined with vascular stenosis, and tumor bleeding. After confirming the site of the bleeding artery and the inner diameter, we used various catheters and embolic agents for embolotherapy. Counterchecked angiography was used to determine whether the bleeding arteries were completely embolized.

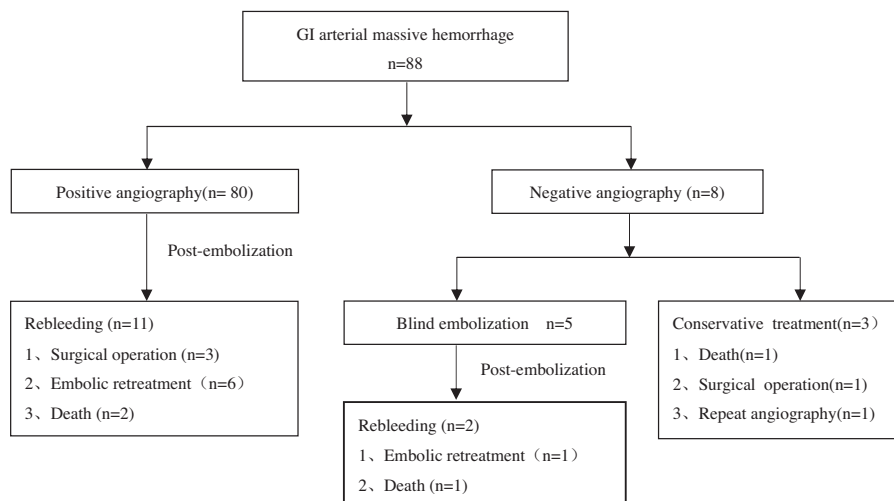
For patients with acute massive hemorrhage, we prescribed blood transfusion therapy based on laboratory results and patient symptoms to correct anemia, supply blood volume, and maintain blood pressure.<sup>[10,11]</sup> Our results suggested that for patients with acute GI bleeding, a strategy of not performing transfusion until the hemoglobin concentration decreased to less than 7 g/dL was a safe and effective approach.<sup>[12]</sup> The infusion threshold could be set to 9 g/dL when patients suffered from complications, especially when the complication was ischemic heart disease. To improve the blood clotting mechanism of bleeding patients, a moderate amount of platelets and plasma was added when infusing with red blood cells. The termination of the anticoagulant therapy was decided by cardiology and multidisciplinary consultation for patients taking anticoagulant drugs. It was necessary to monitor the patient's vital signs closely after ETAE treatment. Symptomatic treatment for postembolization syndrome was administered in a timely fashion. For patients who required surgical treatment, the option of surgical resection was considered.

### 3. Results

Of the 88 patients with GI arterial hemorrhage, 54 patients were diagnosed with upper GI hemorrhage and 34 patients with lower



**Figure 1.** A 60-year-old woman with GI hemorrhage. (A) Gastroduodenal artery arteriography showed a pseudoaneurysm arising from the right hepatic artery with active extravasation. (B and C) Subclavian artery puncture and then superselection into the pseudoaneurysm, depositing 2 spring coils (MWCE35-10-8) using the so-called sandwich technique. (D) Postembolization image showing nonfilling of the pseudoaneurysm (arrow); no further intervention was needed.

**Table 1****Flow diagram of study subjects.**

GI tract hemorrhage. There were 80 cases with positive imaging on the first angiography. The imaging included contrast extravasation (only), gastroduodenal artery stenosis, pseudoaneurysm (only), pseudoaneurysm rupture with contrast extravasation, pseudoaneurysm merged with artery stenosis, intestinal vascular malformation, tumor vasculature, etc. The treatment processes for the 88 patients are detailed in Table 1. There were eight cases with negative imaging. Seventy-two of 88 patients undergoing interventional embolization had successful hemostasis, and 81 arteries were blocked, including 28 gastroduodenal arteries, 7 left gastric arteries, 5 phrenic arteries, 2 branches of jejunum arteries, 3 branches of ileum arteries, 9 ileocecal brachial arteries, 1 middle colic artery, 3 left colic arteries, 13 arteria rectalis superior, and 10 internal iliac arteries. There were 26 procedures using the so-called sandwich technique, including 21 in patients who accepted gastroduodenal arterial embolization treatment. The success rate of first-time interventional technique treatment was 100%, and the clinical success rate was 84.71%. The postoperative rebleeding rate for patients within 30 days was 15.29%. Of the rebleeding cases, 2 patients were formerly treated with “blind embolization,” 7 patients underwent interventional embolic retreatment, and 3 patients had surgical operation. Seven patients experienced temporary liver or renal function failure, and 6 patients had temporary abdominal distension and abdominal ache 2 or 3 days after embolization. Eleven cases had fever, and 5 patients had puncture hematoma. Three died due to multiorgan failure caused by factors such as excessive bleeding. There was no bowel ischemia or other serious complications during follow-up. Eight patients underwent surgical resection of lesions after successful hemostasis by interventional embolization. Postoperative pathological diagnoses were as follows: 3 cases of GI stromal tumor, 2 patients diagnosed with colon cancer, and 3 patients diagnosed with intestinal vascular malformation.

#### 4. Discussion

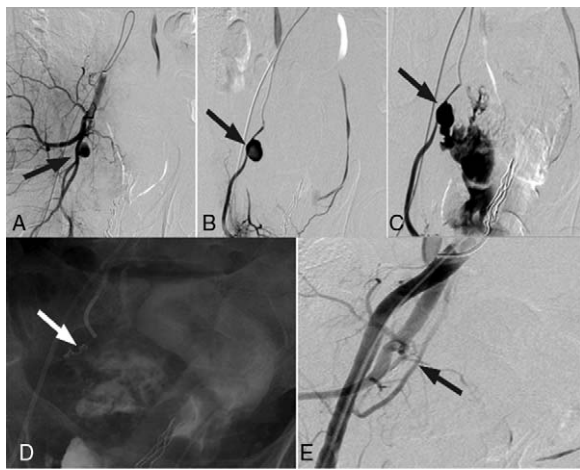
The diversity of blood supply origins, etiologies, and bleeding characteristics has led to differences in imaging and methods of embolization, so the distinction between upper and lower GI hemorrhage has great significance. The upper GI refers to the

ligament from the esophagus to Treitz. The lower digestive tract includes the small intestine, colon and rectum. The situation of GI arterial hemorrhage is generally an emergency, and the etiology is complex. According to previous literature, upper GI arterial hemorrhage is mainly caused by ulcerative bleeding, and digestive tract arterial hemorrhage is mainly caused by diverticulum lesions, vasodilation and enteritis.<sup>[1-15]</sup> In this study, the main reason for bleeding was tumor hemorrhage, which accounted for 30.68% of the cases, followed by traumatic bleeding or iatrogenic causes. Although anti-shock and hemostatic therapy can reduce blood loss and thus reducing the risk of death, most patients cannot achieve permanent hemostasis. We prefer surgery in traditional treatments, but the risk is high, and there are many postoperative complications. Some patients cannot tolerate the complications, which can even lead to situations of surgical hemostasis failure (Fig. 2).

Emergency endoscopic therapy has a certain therapeutic effect, but some patients with acute artery GI bleeding experienced treatment failure because they did not meet the requirements of bowel preparation (Fig. 3). Since Nusbaum's first reported in 1963 of applying arterial angiography in the diagnosis of GI bleeding, interventional therapy with the advantages of rapid positioning, safety and efficiency has been widely used in patients with a high risk of active bleeding. Moreover, it can significantly reduce the odds of hemorrhaging patients having to undergo surgical operations; therefore, it is favored and recommended by clinicians.<sup>[16]</sup>

The arteriographic manifestations of acute arterial massive hemorrhage of the GI tract caused by different pathogeneses are not the same (Table 2). The positive rate of angiography was 90.91% (80/88) in this study, and the imaging results included contrast extravasation (only), pseudoaneurysms, etc. Contrast extravasation is the most direct and most common manifestation seen in hemorrhages caused by various types of ulcers.<sup>[17]</sup> Simple contrast spillover accounted for 28.75% (23/80) of cases in this study, with 6 patients whose contrast overflowed into the lumen. The contrast agent adheres to the intestinal wall when the imaging item changes (Fig. 3). Contrast agent spillover of one patient showed the “pseudovein” sign. Pseudoaneurysm was also common in this study, and the causes mainly were chronic pancreatitis, severe abdominal trauma, or iatrogenic injury.



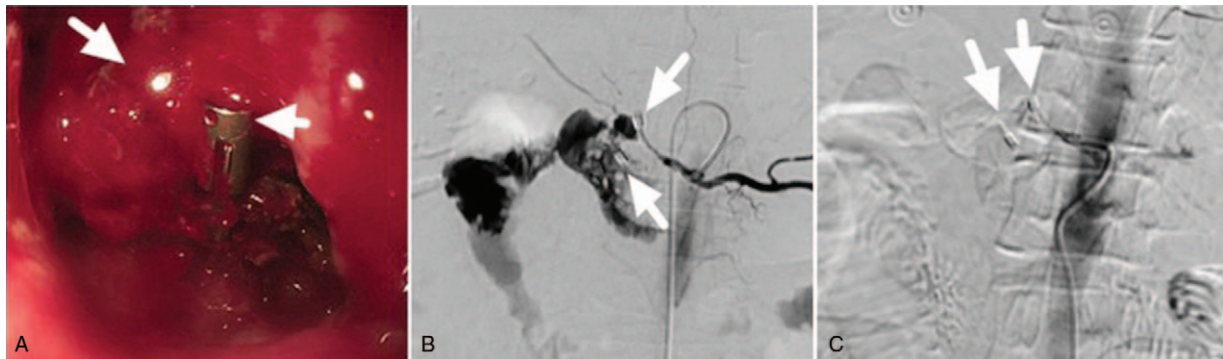


**Figure 2.** A 37-year-old man 2 days after surgical repair of his rectum and bladder, which were damaged by trauma. He had a pelvic hematoma and massive fresh bloody stools. Gauze packing in the rectum was not effective. (A) Right arteria iliaca communis angiography shows that a right internal iliac artery pseudoaneurysm developed (long black arrow). (B) Right arteria iliaca artery superselective angiography shows that a right internal iliac artery pseudoaneurysm developed (long black arrow). (C) Pseudoaneurysm has ruptured (long black arrow), with the contrast agent flowing into the rectum (short black arrow). (D and E) Immediate cessation of hemoptysis was obtained after embolization with steel coils (MWCE35-3-3) and PVA particles (350–560  $\mu\text{m}$ ). Repeated angiography showed that steel coils were located in the internal iliac artery in front of the catheter (short black arrow). Right arteria iliaca communis angiography shows that the pseudoaneurysm disappeared, and no contrast agent was visible. The patient underwent conservative management and did not show any further bleeding 30 days later.

Angiography of 10 patients was characterized by simply localized tumor sample expansion of the arterial lumen. Six patients were diagnosed with pseudoaneurysm rupture, and imaging showed contrast extravasation. Some patients with GI arterial hemorrhage showed vascular stenosis, with circumscribed or diffused contracture on angiography, because the patients lost too much blood, used vasoconstrictor drugs or the artery underwent physical stimulation.

Angiography showed local expansion of blood vessels with contracture on both ends of the vessel when pseudoaneurysms merged with artery stenosis. In this study, there were 6 patients who had vascular malformation, 1 case located in the upper GI tract, and the other 5 cases located in the lower GI tract. Four patients were directly diagnosed with GI arterial hemorrhage by angiography, and among them, 2 patients' DSA angiography showed local uneven thickness of the vascular plexus with peripheral vascular irregular expansion and circuitry. One patient with AVM had angiography that was characterized by venous drainage at the early arterial phase, and it showed the "tram track" sign. When malformed vessels ruptured, angiography mainly showed contrast agent spillover (Fig. 4). Tumor bleeding is mostly caused by the erosion of blood vessels, and on angiography, we can find within the tumor chaotic blood vessels that are obviously stained and swollen, gathering like a ball and supplying blood for the tumor (Fig. 5), and some patients showed obvious contrast agent overflow.

For patients with positive angiography, interventional embolization is effective therapeutically. The selection of embolic material is an important part of the process of interventional embolization. The types of embolization agents, specifications,

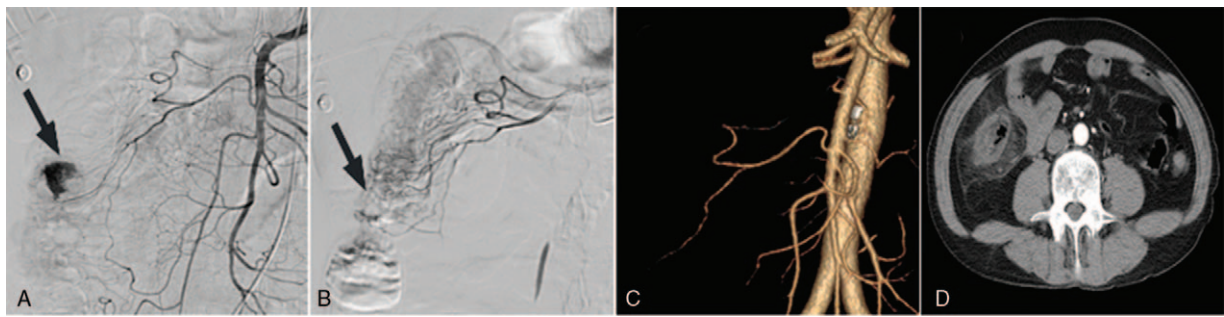


**Figure 3.** A 62-year-old female with postoperative gastric cancer and acute UGI bleeding with hemorrhagic shock. (A) After silver clip and electrocoagulation hemostasis treatment, extravasation of arterial blood from the gastrointestinal anastomosis could still be found by gastroscop (arrows). (B) Angiography before embolization, guided by clip position (arrow); selective celiac trunk angiography demonstrates a large amount of contrast medium extravasation originating from the gastroduodenal artery, which coated the stomach and small intestine wall. (C) Angioembolization of the pseudoaneurysm superselected embolotherapy with microspheres (700–900  $\mu\text{m}$ , 2  $\text{cm}^3$ ) and spring coils (MWCE35-5-3,2). Repeated angiography showed no extravasation of contrast medium.

**Table 2**  
**The GI arterial hemorrhage caused by different reasons has diversified emergent arteriographic manifestations.**

Cause	Contrast extravasation	Arteriovenous fistula	Tumor vasculature	Pseudoaneurysm	Artery stenosis	Total
Gastric or duodenal ulcer	9	0	0	5	3	17
Tumor bleed	0	1	22	0	4	27
Traumatic or iatrogenic	7	2	0	8	4	21
vascular malformation	0	6	0	0	0	6
Diverticula	5	0	0	0	0	5
Others	2	0	0	2	0	4
Total	23	9	22	15	11	80

Patients with negative angiography are not included.



**Figure 4.** A 62-year-old man with lower gastrointestinal bleeding. (A) Superior mesenteric artery angiography shows contrast extravasation in the branch of the ileocecal artery. (B) Superselective angiogram obtained with use of a 2.7-F microcatheter; the ileocecal branchial artery was embolized with microspheres (500–700 and 700–900  $\mu\text{m}$ ). Postembolization arteriogram after superselective embolization shows total occlusion of feeding vessels and cessation of hemorrhage. (C) On the fourth day after embolization, CTA review was performed; normal blood vessels branches are visible. (D) On abdominal enhanced CT 1 month later, the embolization insufflates: inflammatory exudation is surrounded by the intestine, and intestinal canal ischemic necrosis is invisible. The patient underwent surgical resection 2 months later, and we did not find bowel ischemia necrosis in the surgical operation.

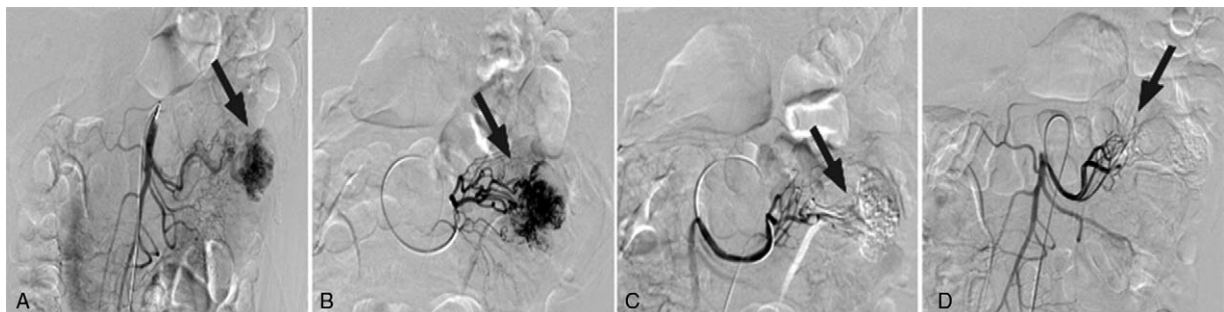
and methods of embolization vary depending on arteriographic manifestations, bleeding locations, causes of disease, blood coagulation state, etc.<sup>[8]</sup> Commonly used GI arterial hemorrhage embolic materials include gelatin sponges, PVA particles, spring coils, etc.<sup>[18,19]</sup> Gelatin sponges are intermediate-acting embolization agent, and they act with the same mechanism as PVA particles in stopping bleeding. However, they are mainly used for adjuvant embolization in the treatment of acute GI arterial hemorrhage.<sup>[15,20]</sup> Steel coils, PVA particles, and acrylic microspheres are permanent embolic agent. Something they share in common is that they all rely on mechanical obstruction to reduce arterial perfusion pressure, and the role of the steel coil also includes platelet activation and starting the clotting chain reaction.<sup>[20–22]</sup> Currently, the selection of the best embolization material remains controversial.<sup>[8,13]</sup> In our study, the most commonly used embolization agents are 3rd-hydroxyl-methyl-acrylic microspheres, PVA particles and steel coils. 3rd-hydroxyl-methyl-acrylic microspheres were approved in 2008 to be used as a new type of permanent embolic agent. Before then, we mainly used PVA particles, which have irregular surfaces and nonuniform size. Worse, dry particles swell by approximately 30% after being suspended in saline, leading to angiography catheter congestion (especially for microcatheters) and possibly causing clinical inconvenience.<sup>[21]</sup>

However, 3rd-hydroxyl-methyl-acrylic microspheres have smooth surfaces and an oval shape, and they are less likely to

block the tube. Although their diameter is greater than that of a microcatheter, microspheres can undergo transformation and obviously shorten the operation time. However, the number of microspheres needed is greater than PVA particles and thus could lead to higher clinical costs. The advantages of steel coils are a clear embolization location and higher operability. Their hemostatic effects are especially obvious in patients with large artery injuries and arteriovenous fistulas and in patients with normal blood clotting mechanisms.<sup>[23]</sup> Patients with clotting mechanism problems can choose 3rd-hydroxyl-methyl-acrylic microspheres, etc.<sup>[24]</sup> In this study, a total of 15 cases had clotting mechanism problems, including 11 cases using 3rd-hydroxyl-methyl-acrylic microspheres or PVA particles for embolization, and the hemostatic effects were obvious.

Regarding the combined use of embolic materials, some studies have shown that using steel coil alone can obtain obvious hemostatic effects.<sup>[18]</sup> In our study, for patients with pseudoaneurysms, we preferred coils. To prevent recanalization or to avoid incomplete embolization, we generally recommend using combined embolic agents when the diameter of the bleeding vessel is large or a pseudoaneurysm ruptures with contrast extravasation.

In the study of patients with positive angiography, a total of 11 patients had pseudoaneurysm rupture bleeding; among these cases, 10 achieved significant hemostatic effects using steel coils in combination with particulate embolic agents, and rebleeding did



**Figure 5.** A 45-year-old man with massive bloody stools. (A) Superior mesenteric arteriography shows a tumor vessel of a remote branch of the jejunal artery (long black arrow) and its feeding artery (short black arrow). (B) Superselective jejunal arteriography shows a feeding artery of a tumor (short black arrow) and a jejunal tumor vessel (long black arrow). (C) Superselective angiography after embolization with 3 hydroxyl methyl acrylic acid gelatin microspheres (500–700  $\mu\text{m}$ , 1  $\text{cm}^3$ ) shows that a feeding artery of the tumor and a jejunal tumor vessel are visible. (D) Postembolization superior mesenteric artery angiography shows that a jejunal tumor and its vessel are visible. The jejunal artery developed normally.

not occur within 30 days. When a wide arteriovenous fistula is found by digital subtractive angiography (DSA), a large number of microspheres or PVA particles can return to the pulmonary artery through the fistula, causing serious complications such as pulmonary embolism. Therefore, we recommend using spring coils as the main embolic material. We also use 3rd-hydroxyl-methyl-acrylic microspheres or PVA particles to improve the therapeutic effects based on the actual situation.

Some patients with GI arterial hemorrhage might experience spasmodic contraction of the bleeding artery and artery stenosis because of conservative drug therapy, excessive loss of blood, the protection mechanism of vessel contraction, etc. When the stimulus is removed, the arterial diameter has the possibility of recovering. Therefore, when using spring coils, we choose one larger than the target vessel or combine it with granular embolic agents at the same time.

For patients with vascular malformation and tumor hemorrhage, the effect of interventional embolization was also obvious. In this study, there were 6 patients with vascular malformations. Superselecting the target vessels with a microcatheter, we used 3rd-hydroxyl-methyl-acrylic microsphere (500–700 or 700–900  $\mu\text{m}$ ) or steel coils to embolize the target arteries. All of the patients achieved hemostasis immediately, and there was no obvious abdominal pain or other symptoms within 30 days.

One month after the intervention embolization, 2 patients with small intestinal vascular malformations and 1 patient with vascular malformation at the ileocecal junction underwent surgical resection, and during which there was no obvious bowel ischemia necrosis. For tumor bleeding, we must superselect the target vasculature, and as for the embolic material, we recommend using 3rd-hydroxyl-methyl-acrylic because it not only can completely block the vessels supplying blood to the tumors, but also can rapidly stop bleeding and reduce the erosion of blood vessels by tumors. Moreover, it can also significantly reduce the amount of bleeding during surgical resection.

Regarding the selection of embolic method, the study superselected all of the patients, and 35 cases of them had their target vessels blocked directly. Gastroduodenal artery arteriography found a total of 17 cases that showed pseudoaneurysms arising from the right hepatic artery, and 13 of the 17 underwent satisfactory embolization of the distal and proximal gastroduodenal arteries, including the anterior and posterior superior pancreaticoduodenal arteries and the right gastroepiploic artery, to prevent retrograde flow (Fig. 1).

Patients with negative angiography for the first time in the study accounted for 9.09% (8/88). Theoretically, for DSA imaging to be positive, there should be more than 0.5 mL/minute contrast agent spillover. In the process of actual surgery, because arterial digestive tract hemorrhage is in the intermittent period, stable hemodynamics or using a large amount of angiotensin before imaging can lead to negative imaging. For patients with negative imaging, “blind embolization” remains controversial, but for patients with clear histories of surgery and endoscopic treatment failure, embolization is quite beneficial.<sup>[2,8]</sup> There were 4 patients who chose blind embolization, and 3 of them suffered from endoscopic treatment failure before the embolization. For patients with negative imaging and no clear etiology, we employed conservative treatment first and then performed DSA imaging again or performed CT or nuclear scans if necessary.<sup>[25]</sup> Some scholars have advocated provocation of bleeding with vasodilators, anticoagulants, etc., but considering the possibility that uncontrollable bleeding might occur, we did not use this method.

Rebleeding episodes were defined as subsequent bleeding episodes with a decrease in hemoglobin of 2 g/dL, which occurred within 72 hours after the initial bleed had stopped.<sup>[26]</sup> The literature reports that the average rebleeding rate of the GI artery after interventional embolization within 30 days is 22%. Early relapsing hemorrhage after embolization is related to the clotting mechanism, large blood transfusions, and the use of a single type of material.<sup>[15,17,20]</sup> The rebleeding rate within 30 days in our research was 14.77% (13/88). Analysis found that rebleeding within 30 days for this group of patients might mainly involve progression of the disease, collateral formation, coagulation disorders, etc.

Following up after the embolization, we did not find any serious complications such as bowel ischemia necrosis.

We note the following: For patients who have GI arterial hemorrhage with uncertain etiology, the normal radiography order should be the superior mesentery first, then the inferior mesentery, and finally the celiac trunk. In this manner, we could avoid the influence of bowel gas and contrast agents in the bladder. For patients with clear trauma or surgical histories, we must check all of the relevant supplying arteries around the lesions. In the meantime, we must superselect the target arteries to avoid false negatives. We should use nonionic isoosmotic contrast agents, such as iodixanol, to reduce the amount of contrast agent and should pay attention to hydration after the operation to reduce the load on renal function. For patients with lower digestive tract hemorrhage who cannot tolerate steel coils, we must use a microcatheter to prevent necrosis of bowel ischemia, and the granular embolic agents should be larger than 700  $\mu\text{m}$ , as advocated by Martí et al.<sup>[27]</sup> We should consider the existence of vascular anatomical variations and collateral circulation after the lesion blood vessels are blocked. This fact is especially true when the stomach right pancreaticoduodenal artery bleeding is involved, and reviewing the imaging of the superior mesenteric artery after vascular embolization is necessary to ensure whether there are communicating branches participating in the blood supply. For acute arterial massive hemorrhage of the GI tract, multidisciplinary treatments such as endoscopy, interventional therapy, and surgery should be considered so that we can achieve thorough hemostasis.

## 5. Conclusion

ETAE is a safe, effective treatment option for controlling massive GI arterial hemorrhage. The arteriographic manifestations of emergency life-threatening massive GI arterial hemorrhage are different, and the choice of the proper embolic agent is essential to stopping bleeding.

Deficiencies of this study include the following: the sample size of the study was relatively small. To explore the best embolic agents and embolic methods based on different causes and imaging of GI arterial hemorrhage, we require a larger sample and research results from more centers.

## References

- [1] Peynircioğlu B, Erkuş F, Cil B, et al. Mesenteric angiography of patients with gastrointestinal tract hemorrhages: a single center study. *Diagn Interv Radiol* 2011;17:368–73.
- [2] Katano T, Mizoshita T, Senoo K, et al. The efficacy of transcatheter arterial embolization as the first-choice treatment after failure of endoscopic hemostasis and endoscopic treatment resistance factors. *Dig Endosc* 2012;24:364–9.



- [3] Chan V, Tse D, Dixon S, et al. Outcome following a negative CT Angiogram for gastrointestinal hemorrhage. *Cardiovasc Intervent Radiol* 2015;38:329–35.
- [4] Soto JA, Park SH, Fletcher JG, et al. Gastrointestinal hemorrhage: evaluation with MDCT. *Abdom Imaging* 2015;40:993–1009.
- [5] Loffroy R. Management of nonvariceal upper gastrointestinal bleeding resistant to endoscopic hemostasis: will transcatheter embolization replace surgery? *Eur J Gastroenterol Hepatol* 2013;25:118.
- [6] Walker TG, Salazar GM, Waltman AC. Angiographic evaluation and management of acute gastrointestinal hemorrhage. *World J Gastroenterol* 2012;18:1191–201.
- [7] Wong TC, Wong KT, Chiu PW, et al. A comparison of angiographic embolization with surgery after failed endoscopic hemostasis to bleeding peptic ulcers. *Gastrointest Endosc* 2011;73:900–8.
- [8] Loffroy R, Rao P, Ota S, et al. Embolization of acute nonvariceal upper gastrointestinal hemorrhage resistant to endoscopic treatment: results and predictors of recurrent bleeding. *Cardiovasc Intervent Radiol* 2010;33:1088–100.
- [9] Yoon W, Jeong YY, Shin SS, et al. Acute massive gastrointestinal bleeding: detection and localization with arterial phase multi-detector row helical CT. *Radiology* 2006;239:160–7.
- [10] Kim BS, Li BT, Engel A, et al. Diagnosis of gastrointestinal bleeding: a practical guide for clinicians. *World J Gastrointest Pathophysiol* 2014;5:467–78.
- [11] Fujishiro M, Iguchi M, Kakushima N, et al. Guidelines for endoscopic management of non-variceal upper gastrointestinal bleeding. *Dig Endosc* 2016;28:363–78.
- [12] Villanueva C, Colomo A, Bosch A, et al. Transfusion strategies for acute upper gastrointestinal bleeding. *N Engl J Med* 2013;368:11–21.
- [13] Loffroy R, Guiu B. Role of transcatheter arterial embolization for massive bleeding from gastroduodenal ulcers. *World J Gastroenterol* 2009;15:5889–97.
- [14] Barnert J, Messmann H. Management of lower gastrointestinal tract bleeding. *Best Pract Res Clin Gastroenterol* 2008;22:295–312.
- [15] Strate LL, Naumann CR. The role of colonoscopy and radiological procedures in the management of acute lower intestinal bleeding. *Clin Gastroenterol Hepatol* 2010;8:333–43.
- [16] Boškoski I, Familiari P, Costamagna G. New and emerging endoscopic therapies for gastrointestinal bleeding. *Curr Opin Gastroenterol* 2014;30:439–43.
- [17] Loffroy R, Guiu B, D'Athis P, et al. Arterial embolotherapy for endoscopically unmanageable acute gastroduodenal hemorrhage: predictors of early rebleeding. *Clin Gastroenterol Hepatol* 2009;7:515–23.
- [18] Morishita H, Yamagami T, Matsumoto T, et al. Transcatheter arterial embolization with N-butyl cyanoacrylate for acute life-threatening gastroduodenal bleeding uncontrolled by endoscopic hemostasis. *J Vasc Interv Radiol* 2013;24:432–8.
- [19] Huang CC, Lee CW, Hsiao JK, et al. N-butyl cyanoacrylate embolization as the primary treatment of acute hemodynamically unstable lower gastrointestinal hemorrhage. *J Vasc Interv Radiol* 2011;22:1594–9.
- [20] Shin JH. Recent update of embolization of upper gastrointestinal tract bleeding. *Korean J Radiol* 2012;13(suppl 1):S31–9.
- [21] Loffroy R, Guiu B, Cercueil JP, et al. Endovascular therapeutic embolisation: an overview of occluding agents and their effects on embolised tissues. *Curr Vasc Pharmacol* 2009;7:250–63.
- [22] Lenhart M, Paetzel C, Sackmann M, et al. Superselective arterial embolisation with a liquid polyvinyl alcohol copolymer in patients with acute gastrointestinal haemorrhage. *Eur Radiol* 2010;20:1994–9.
- [23] Wang HL, Xu CY, Wang HH, et al. Emergency transcatheter arterial embolization for acute renal hemorrhage. *Medicine (Baltimore)* 2015;94:e1667.
- [24] Busch OR, van Delden OM, Gouma DJ. Therapeutic options for endoscopic haemostatic failures: the place of the surgeon and radiologist in gastrointestinal tract bleeding. *Best Pract Res Clin Gastroenterol* 2008;22:341–54.
- [25] Grady E. Gastrointestinal bleeding scintigraphy in the early 21st century. *J Nucl Med* 2016;57:252–9.
- [26] Chang WC, Liu CH, Hsu HH, et al. Intra-arterial treatment in patients with acute massive gastrointestinal bleeding after endoscopic failure: comparisons between positive versus negative contrast extravasation groups. *Korean J Radiol* 2011;12:568–78.
- [27] Martí M, Artigas JM, Garzón G, et al. Acute lower intestinal bleeding: feasibility and diagnostic performance of CT angiography. *Radiology* 2012;262:109–16.