



Inhibition of choroidal osteoma progression using bisphosphonate and RANKL-inhibitory treatment

Mélanie Hébert^a, Kelly Babic^b, Edward C. Hsiao^c, Armin Afshar^b, Nisha Acharya^{b,d}, John A. Gonzales^{b,d,*}

^a Department of Ophthalmology, Hôpital du Saint-Sacrement, CHU de Québec – Université Laval, Québec, Canada

^b Department of Ophthalmology, University of California, San Francisco, San Francisco, USA

^c Division of Endocrinology and Metabolism, School of Medicine, University of California, San Francisco, San Francisco, USA

^d Francis I. Proctor Foundation, University of California, San Francisco, San Francisco, USA

ARTICLE INFO

Keywords:

Alphabetic order): bisphosphonates
Choroidal osteoma
Osteoclast activity
Outer retinal layer thickness
Receptor activator of nuclear factor kappa beta ligand inhibitors

ABSTRACT

Purpose: To describe the use of anti-osteoclastic medications (i.e., bisphosphonates and receptor activator of nuclear factor kappa beta (RANK) ligand inhibitors) in treating choroidal osteoma.

Methods: A 42-year-old male with bilateral posterior choroidal osteomas showed extensive outer retinal atrophy in the right eye secondary to decalcification of a choroidal osteoma and progressive extension of retinal pigment epithelial atrophy in the left eye encroaching on the macula with subtle changes in the choroidal osteoma. Bisphosphonates (i.e., oral alendronate 70 mg weekly) or RANK ligand inhibitors (i.e., subcutaneous denosumab 60 mg every six months) were initiated to prevent calcium resorption.

Results: After the introduction of more directed therapy, there was stabilization of the patient's condition over the next nine years while under bisphosphonate treatment, followed by a switch to RANK ligand inhibitor therapy and later bisphosphonate treatment again. This was made evident through stability in fundus photography, enhanced depth imaging optical coherence tomography, and B-scan ultrasonography regarding outer retinal layers thickness, and choroidal osteoma thickness and calcification.

Conclusion: Anti-osteoclastic therapy using bisphosphonates or RANK ligand inhibitors could be a new treatment paradigm to prevent resorption of choroidal osteomas and prevent the subsequent atrophy of outer retinal layers.

Summary statement: A patient with bilateral posterior choroidal osteomas was treated with bisphosphonates and RANK ligand inhibitors to prevent osteoma resorption in the better-seeing left eye. This has led to stability over six years of outer retinal layers thickness, choroidal osteoma thickness, and choroidal osteoma calcification.

1. Introduction

Choroidal osteoma is a choristoma composed of osteocytes, osteoblasts, and osteoclasts lying between the altered choriocapillaris and the outer choroidal circulation. It typically presents in patients in the fourth decade with a female predominance.^{1–3} It usually presents around the disc and is diagnosed by a yellow/orange hue on fundus examination. It is typically unilateral but can be bilateral in 25 % of cases.¹ There are no current treatment regimens known to prevent progression of osteomas, which is typified by growth, decalcification, subretinal fluid (SRF), hemorrhage, and choroidal neovascular membrane (CNVM) formation, the latter of which is seen in nearly half of patients over follow-up.^{1–3}

Observation is usually recommended to monitor for new-onset CNVM which may require treatment with photodynamic therapy (PDT) or, more recently, intravitreal anti-vascular endothelial growth factors (VEGF).^{3,4}

There have been previous reports suggesting that vision loss from posterior choroidal osteomas can occur through tumor decalcification leading to outer retinal atrophy.^{2,5–7} This has led some clinicians to offer calcium and vitamin D supplementation as a way of decreasing calcium flux⁵; however, the clinical benefit of this is unclear. We hypothesized that use of osteoclast inhibitors could slow the tumor resorption process, decrease tumor decalcification, and thus preserve the outer retinal layers. We present a case of a patient followed over ten years with

* Corresponding author. Francis I. Proctor Foundation, Department of Ophthalmology, University of California, San Francisco, 490 Illinois Street, San Francisco, CA, USA.

E-mail address: john.gonzales@ucsf.edu (J.A. Gonzales).

<https://doi.org/10.1016/j.ajoc.2024.102167>

Received 11 July 2024; Received in revised form 2 September 2024; Accepted 4 September 2024

Available online 12 September 2024

2451-9936/© 2024 Published by Elsevier Inc. This is an open access article under the CC BY-NC-ND license (<http://creativecommons.org/licenses/by-nc-nd/4.0/>).

bilateral posterior pole choroidal osteomas, legally blind in one eye due to choroidal osteoma decalcification, treated with bisphosphonates and receptor activator of nuclear factor kappa beta (RANK) ligand inhibitors to stabilize his disease process.

2. Case report

A 42-year-old male was referred to the Proctor Foundation for evaluation of atypical serpiginous chorioretinopathy in both eyes. Prior to his referral, he described gradual distortion in vision and discomfort behind the right eye 18 years prior, which was treated with rofecoxib and aspirin. Eight years prior to presentation, he experienced an acute vision decline in the right eye and was diagnosed with serpiginous chorioretinopathy. He received sub-Tenon triamcinolone and oral prednisone and was eventually advanced to oral methotrexate. When the left eye developed involvement 4 years prior to presentation, the dose of oral methotrexate was maximized to 25 mg weekly. At this time, visual acuity (VA) was 20/100 in the right eye and 20/20 in the left. However, there was continued progression of vision loss in the left eye (Fig. 1.2), prompting a sub-Tenon triamcinolone injection in that eye and advancement of systemic immunosuppression to cyclophosphamide for 9 months before being maintained on oral mycophenolate mofetil (MMF) 1.5 g twice daily (Fig. 1.3). His ocular disease was stable through the years and the MMF was discontinued 2 years before presentation. At the time of presentation to the Proctor Foundation, he reported new temporal visual field loss in the left eye and visual acuity (VA) decreased from 20/20 to 20/30 (Fig. 1.4).

In the right eye, there was extensive scarring around the optic nerve with chorioretinal atrophy into the central macula (Fig. 2A), while in the left, there was a yellowish/orangish lesion at the level of the choroid extending in toward, but sparing, the fovea. The lesion extended further temporally on the superior aspect than on the inferior aspect of the fovea (Fig. 2B). On fluorescein angiography, there was early hyperfluorescence that developing by 49 seconds corresponding to the areas of the yellowish change in the left eye. In the late frames, there was a subtle increase in some of the hyperfluorescence in these regions and a slight increase in the temporal extent of the hyperfluorescence on the superior aspect of the fovea. No frank leakage was seen but subtle increases in the hyperfluorescence could be discerned when comparing early frames with late frames, including an area midway between the fovea and optic nerve, as well as the area just supratemporal to the fovea. The right eye demonstrated only staining and transmission associated with the scarring and atrophy seen clinically. Such angiographic findings were noted to be incompatible with serpiginous chorioretinopathy. On optical coherence tomography (OCT), subretinal fluid (SRF) in the maculopapillary area with pronounced choroidal thickening in the left eye was seen while choroidal atrophy without fluid was seen in the right. There was also discrete sponge-like appearance of deossified choroidal tissue (Fig. 3A–C). Fundus autofluorescence revealed marked hypoautofluorescence with a ring of hyperautofluorescence around the chorioretinal scar in the right eye (Fig. 2C) and mild hyperautofluorescence along the inferior more than superior arcade in the left eye (Fig. 2D). Notably, the expected hypoautofluorescence alongside the progressing lesion on the left that would be expected in serpiginous chorioretinopathy was not demonstrated. Taken together, the clinical and imaging findings were more compatible with bilateral choroidal masses. On B-scan ultrasonography, we noted a hyperechoic mass in the choroid in the left eye (Fig. 2F), while the right eye exhibited a similar, but less hyperechoic mass as well (Fig. 2E). Computed tomography (CT) of the orbits revealed disclike calcification of the bilateral posterior globes, left greater than right, with choroidal thickening. A diagnosis was established of bilateral choroidal osteomas involving the posterior pole, specifically the nasal peripapillary area with extension into the macula bilaterally, with features of decalcification in the right eye especially along the temporal most border involving the macula. At this juncture, systemic immunosuppression was

discontinued.

Because this patient had significantly reduced VA in the right eye and given the clear progression and SRF in the left eye with concern for impending significant vision loss, care was coordinated with an endocrinologist and anti-osteoclast medication was initiated with the bisphosphonate oral alendronate 70 mg weekly. Stability of the osteoma, particularly in the left eye, was appreciated on subsequent exams, imaging, and B-scan ultrasonography (Fig. 4.1), including the appearance of deossified choroidal tissue (Fig. 3D–E). Approximately 2 years later (Fig. 1.5), it was noted that there was a slight increase in size of the left choroidal osteoma with slight extension of the area of retinal pigment epithelium (RPE) atrophy adjacent to the fovea. In this context, and in discussion with endocrinology, the patient was switched to denosumab (i.e., a RANK ligand [RANKL] inhibitor) 60 mg subcutaneously every 6 months. Two months later, a new retinal heme superonasal to fovea concerning for CNVM was identified in the left eye (Fig. 1.6) and an intravitreal bevacizumab injection led to resolution of the SRF (Fig. 1.7). The patient remained clinically stable throughout RANKL inhibitor treatment (Fig. 4.2 and 4.3). After three years of treatment with denosumab, the patient was transitioned back to alendronate because of newly identified increased fracture risks in osteoporotic patients who discontinue denosumab.⁸ Under denosumab, there was reduction in the prominence of the deossified choroidal tissue (Fig. 3F–G). Since restarting alendronate, the choroidal osteoma has remained stable and visual acuity has remained stable bilaterally (Fig. 1.8 and 4.4). The sponge-like appearance of the deossified choroidal tissue also seemed to be less prominent (Fig. 3H).

3. Discussion

The current conventional treatment approaches in choroidal osteomas is observation for eventual development of CNVM, with some suggesting calcium and vitamin D supplementation to slow progression.⁵ This is, however, not specific in addressing the underlying pathophysiology where tumor decalcification can lead to outer retinal atrophy. Thus, other therapeutic avenues to limit decalcification need to be explored especially in the context of bilateral disease with a pre-existing extensive macular scar. The present case involving bilateral choroidal osteomas treated with osteoclast inhibitors is instructive in demonstrating that such an approach may slow or prevent the progression of outer retinal atrophy associated with tumor resorption. This may have contributed to stability of the osteoma and preservation of vision in the left eye over the nine years of treatment and follow-up. Other factors that may have contributed to the stability of the osteoma was the withholding of corticosteroids which may accelerate decalcification and the natural course of the disease that may have stabilized on its own.

The initial presentation of the patient was suspicious for serpiginous chorioretinopathy leading to escalating immunosuppression to stop progression. The use of corticosteroids during this period may also have led to more rapid calcium resorption. Steroids are known to increase osteoclast activity and decrease osteoblast activity, leading to bone resorption.⁹ Mobilization of calcium can have worsened the vision loss in this patient through outer retinal changes with peripapillary atrophy extending into the fovea as well as posterior pole around the right optic disc. A few elements were not compatible with serpiginous chorioretinopathy, including the absence of hypoautofluorescence of the presumed active lesion when it first appeared in the left eye (Fig. 1D). When the clinical picture does not respond to increasing immunosuppressive treatment, reconsideration of the diagnostic hypothesis and re-evaluation of the imaging modalities including B-scan ultrasonography, OCT, fundus autofluorescence, or CT scanning may be useful to guide management. In this case, OCT demonstrated significant hyper-reflectivity and mass effect within the choroid and fundus autofluorescence was normal in the left eye, features that are compatible with choroidal osteoma as opposed to serpiginous chorioretinopathy.

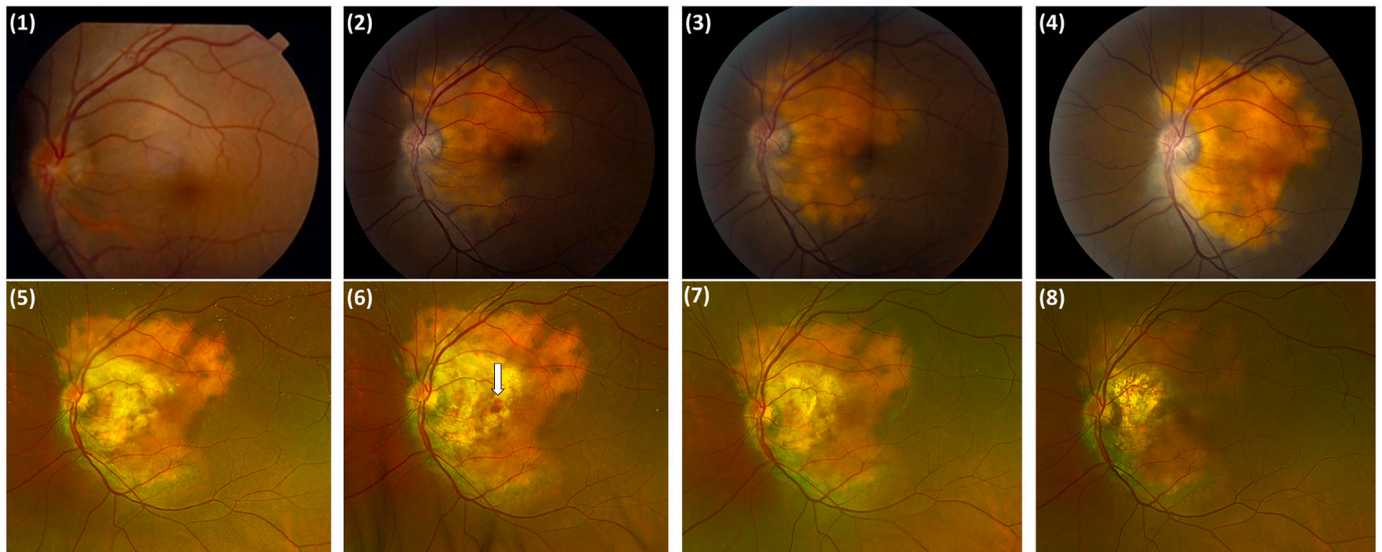


Fig. 1. Fundus photography (1–4: color fundus retinal photography and 5–8: widefield pseudocolor fundus photography) of the left eye showing appearance and progression of the choroidal osteoma until stabilization. (1) Imaging six years prior to involvement of OS showing a normal posterior pole. (2) Two years after start of left eye involvement and progression despite treatment with methotrexate. (3) Slight progression of the lesion towards the fovea one year later after corticosteroid therapy, cyclophosphamide, and mycophenolate mofetil. (4) Time of presentation at Proctor Foundation with new progression towards the fovea after discontinuation of immunosuppression for two years; alendronate therapy started. (5) Decrease in vision led with slight extension of retinal pigment epithelium changes prompted a switch to denosumab therapy approximately two years later. (6) Appearance of new retinal hemorrhage on choroidal neovascular membrane (arrow), treated with anti-vascular endothelial growth factor injections. (7) Six months later, resolution of the hemorrhage and stability of the lesion under denosumab. (8) Final follow-up 6 years later with stability of lesion margins.

Given the atypical bilateral presentation in a middle-aged man, the same picture could be concerning for heterotopic ossification following an inflammatory process. However, this is unlikely given the absence of improvement with escalating immunosuppression, the absence of overt signs of intraocular inflammation including on fluorescein angiography, and the peripapillary pattern of lesion growth in the posterior pole bilaterally which is more consistent with choroidal osteoma.

Once the diagnosis of choroidal osteoma was established, we sought out alternative treatment options to stabilize decalcification of the left eye lesion. The pathophysiology of outer retinal changes in choroidal osteoma has been investigated through long-term follow-up studies, as well as OCT with and without enhanced depth imaging (EDI) studies. Though the underlying cause is still unknown, decalcification seems to be the initial insult, occurring along with choriocapillaris compromise and loss of RPE with subsequent outer retinal layers degeneration.² It was shown in prior OCT studies that photoreceptor atrophy over decalcified choroidal osteomas correlate with poor VA compared to calcified subfoveal tumors.⁵ In an EDI-OCT study, the characteristics of nine eyes with subfoveal osteomas was examined among others. The four eyes with ossified subfoveal osteomas kept an intact outer retinal layer appearance, whereas the five eyes with partially or completely deossified subfoveal osteomas had sustained thinning and atrophy of the outer retinal layers.⁷ In this case, OCT imaging was able to show the typical sponge-like appearance of deossified choroidal tissue that seemed to subside with treatments of anti-osteoclast medications (Fig. 4F–H).¹⁰ However, whether this is true response to treatment and reversal of the deossification with the medications is unclear. Another potential goal in preventing tumor decalcification is that this may in turn reduce the risk of CNVM. CNVM is theorized to occur from RPE disruption, thinning or loss of the outer retinal layer or Bruch's membrane, as well as tumor decalcification.³ Our patient developed CNVM in the left eye within two months of starting denosumab therapy, but this may have been an insufficient amount of time to achieve the desired therapeutic effect. He has not however had recurrence of CNVM or subretinal fluid at follow-up following treatment with one dose of intravitreal bevacizumab.

Decalcification does not always have to be avoided, as it does lead to scarring of the osteoma and involution in certain cases which can be desirable in extrafoveal choroidal osteomas. Being able to slow tumor growth through decalcification can therefore be a therapeutic target in such cases by provoking involution of the tumor at the expense of chorioretinal atrophy, especially in cases where a fovea-threatening margin is progressing.² This can be achieved using PDT.⁴ This approach should not, however, be applied to subfoveal choroidal osteomas in which decalcification results in foveal atrophy and, subsequently, worse visual acuity.

Decalcification of choroidal osteomas is thought to be due to osteoclastic activity.¹ Osteoclasts are responsible for bone resorption and release of calcium, undoing the mineralization process initiated by osteoblasts. These osteoblasts can stimulate osteoclast formation and activation through a cell-surface RANKL and a soluble form of RANKL, both of which can stimulate the RANK receptor on osteoclasts.¹¹ Both RANKL inhibitors and bisphosphonates inhibit osteoclast activity and are widely used for treating osteoporosis. The former medication (e.g., denosumab) is a human monoclonal antibody binding RANKL and preventing the activation of osteoclasts. It can be associated with adverse events such as eczema and cellulitis.¹¹ The latter medication (e.g., alendronate) binds mineralized surfaces and interfere with protein prenylation in osteoclasts, thus impairing bone resorption and increasing osteoclast apoptosis.¹¹ Despite their efficacy in reducing osteoporotic fracture risk, long-term use of anti-resorptive medications are associated with rare but serious complications, including osteonecrosis of the jaw and atypical femur fractures.

Given these mechanisms, and the reported presence of osteoclast-like cells in choroidal osteomas,¹² alendronate and denosumab were used to reduce the tumor turnover in the described case. The patient then had clinical stability with this management over nine years of treatment. In contrast, the previous treatment regimens using oral and/or periocular corticosteroids may have promoted progression of osteoma decalcification as these lead to bone resorption. Glucocorticoids are known to promote osteoporosis and bone loss with doses as low as 5 mg daily of prednisone through increased RANKL activity and decreased

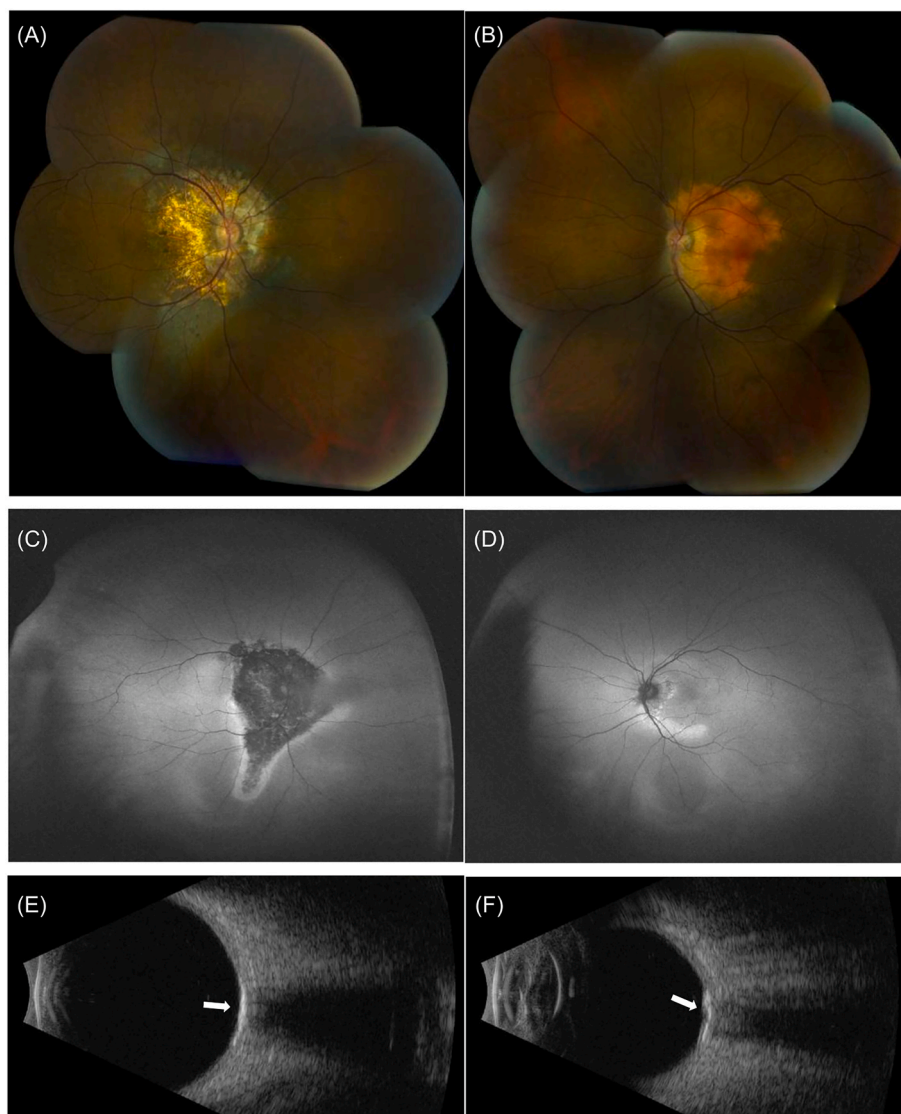


Fig. 2. Multimodal imaging of the patient's eyes in 2014 prior to start of bisphosphonates therapy. Fundus montage photography shows (A) extensive chorioretinal atrophy around the disc encompassing the fovea in the right eye and (B) new yellow-orange hue around the disc encroaching on the macula in the left eye. This is accompanied by (C) marked hypoafluorescence with a ring of hyperautofluorescence around the atrophy in the right eye and (D) mild hyperautofluorescence in a ring along the arcades in the left. A prominent hyperechogenic choroidal mass (arrow) is seen in the posterior pole of (E) the right eye and (F) the left eye.

osteoprotegerin production, among other mechanisms.¹¹ It is therefore important to be aware of this possible complication of high-dose steroids which may initially worsen a patient with an undiagnosed choroidal osteoma.

A limitation of this report is the difficulty to conclusively show that anti-osteoclastic medications such as alendronate and denosumab were responsible for the clinical stability of this patient, or if this would have been the natural evolution of the disease. Many bilateral choroidal osteoma cases maintain good vision in at least one eye, even over long-term follow-up up to 45 years.^{1,6} However, this patient had progressive vision loss prior to being seen by us. In addition, spontaneous decalcification occurring in the proper location could preserve vision in certain eyes by limiting tumor growth towards the macula, but the ensuing chorioretinal atrophy would be undesirable in the foveal region. In addition, it is unknown if the use of intravenous bisphosphonate, such as zoledronic acid, may have more efficacy. Finally, the long-term vision risks for the patient on anti-resorptive therapy are unclear, especially since treatment holidays are used in patients with osteoporosis to decrease the risk of atypical femoral fractures.¹³

In conclusion, we describe the use of anti-osteoclastic medication for

the prevention of decalcification in a patient with bilateral posterior pole choroidal osteomas who remained stable for nine years following initiation of treatment. This could be a new method of preventing tumor decalcification and subsequent outer retinal layers atrophy and vision loss in these patients. How the use of these treatments would influence the development of CNVM would also need to be investigated.

Funding

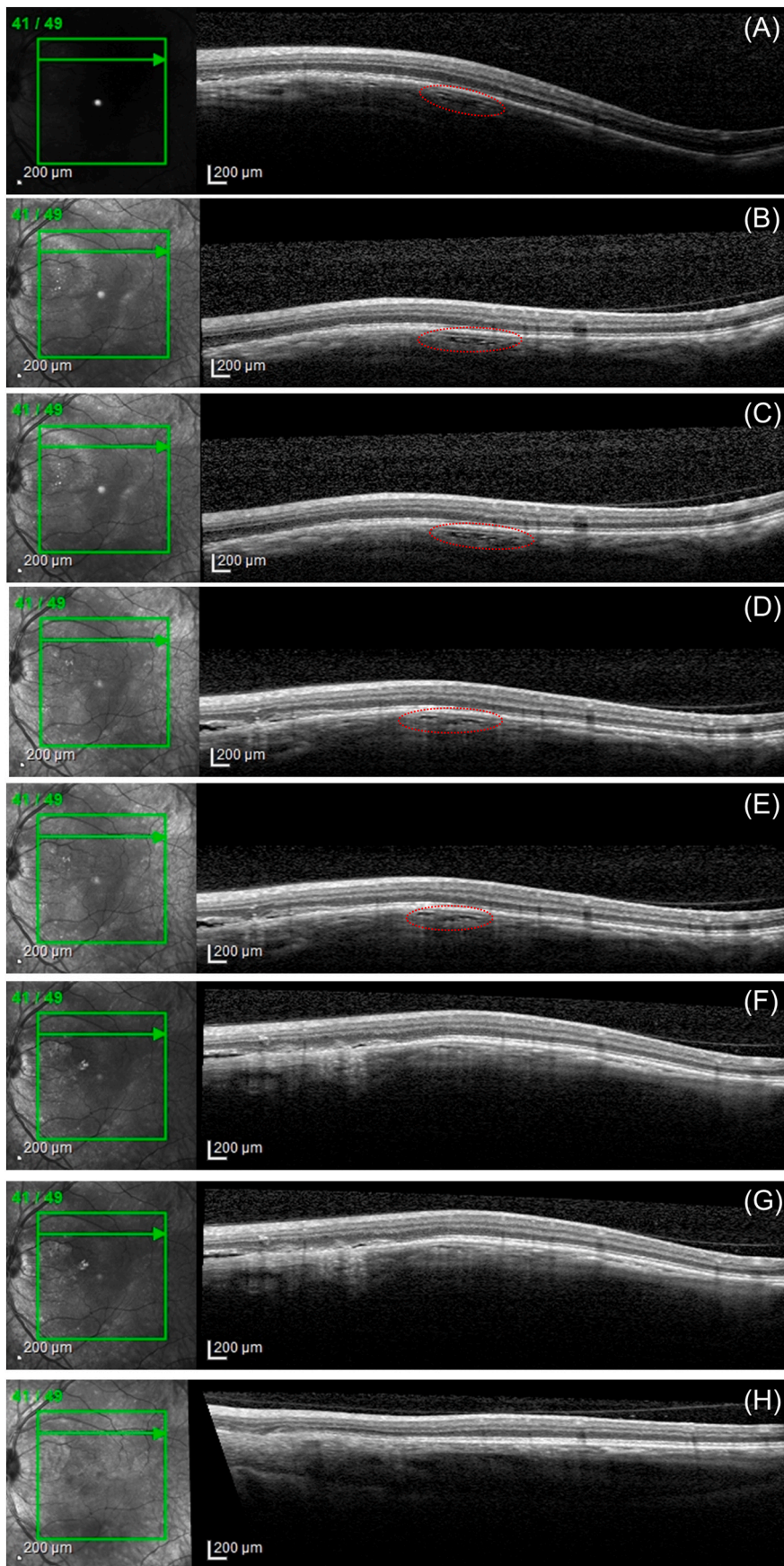
None.

Meeting presentation

Portions of this case were previously presented at the Sociedad Panamericana de Enfermedades Inflammatorias (SPEIO) Meeting on October 19, 2014 in Chicago, Illinois, United States.

Patient consent statement

Written consent to publish this case has not been obtained. This



(caption on next page)

Fig. 3. Optical coherence tomography (OCT) scans through the same area in the left macula showing the typical sponge-like appearance of deossified choroidal tissue (red dotted circle) which then seems to disappear after initiation of treatment with anti-osteoclastic medications. (A–C) OCT line scans showing stable deossified choroidal tissue one year prior to start of alendronate therapy. (D–E) Stable deossified choroidal tissue in the year after the start of alendronate therapy. (F–G) Reduction in appearance of sponge-like appearance of deossified tissue four years later, now under denosumab. (H) Four years after start of denosumab, now under alendronate showing disappearance of the sponge-like appearance of the choroidal tissue.

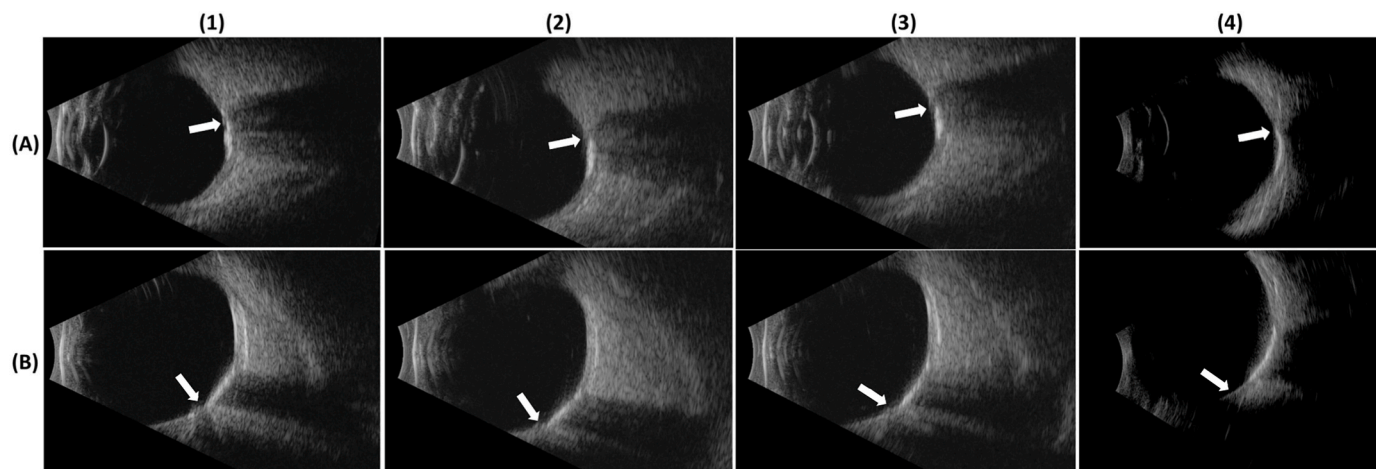


Fig. 4. B-scan ultrasound imaging (1–3: 12 MHz and 4: 18 MHz) of the left eye shows stable echogenic plaque-like calcification of the choroid with adjacent posterior acoustic shadowing consistent echographically with choroidal osteoma stabilization over the follow-up period. (A) Horizontal axial view of the left eye showing echogenic plaque temporal to disc indicated by optic nerve insertion (arrows). (B) Longitudinal scan at 3 o'clock of the left eye showing temporal quadrant involvement with peripapillary echogenic plaque and adjacent acoustic shadowing consistent echographically with choroidal osteoma (arrows). (1) Imaging at the start of anti-osteoclastic medications, under alendronate. (2) Four years since start of anti-osteoclastic medications, now under denosumab. (3) Five years since start of anti-osteoclastic medications, under denosumab. (4) Six years since start of anti-osteoclastic medications, under alendronate. Lesion appears brighter due to increased resolution of 18 MHz probe however landmarks suggest stability of lesion.

report does not contain any personal identifying information.

CRediT authorship contribution statement

Mélanie Hébert: Writing – review & editing, Writing – original draft, Investigation, Formal analysis. **Kelly Babic:** Writing – review & editing, Formal analysis. **Edward C. Hsiao:** Writing – review & editing, Writing – original draft, Supervision, Investigation, Data curation. **Armin Afshar:** Writing – review & editing, Supervision, Formal analysis, Data curation. **Nisha Acharya:** Writing – review & editing, Investigation, Formal analysis, Data curation. **John A. Gonzales:** Writing – review & editing, Writing – original draft, Supervision, Project administration, Methodology, Investigation, Formal analysis, Data curation, Conceptualization.

Declaration of competing interest

The authors have no conflict of interest.

References

- Aylward GW, Chang TS, Pautler SE, Gass JDM. A long-term follow-up of choroidal osteoma. *Arch Ophthalmol*. 1998;116(10):1337–1341. <https://doi.org/10.1001/archophth.116.10.1337>.
- Shields CL, Sun H, Demirci H, Shields JA. Factors predictive of tumor growth, tumor decalcification, choroidal neovascularization, and visual outcome in 74 eyes with choroidal osteoma. *Arch Ophthalmol*. 2005;123(12):1658–1666. <https://doi.org/10.1001/archophth.123.12.1658>.
- Seong HJ, Kim YJ, Choi EY, et al. Complications, treatments, and visual prognosis of choroidal osteomas. *Graefes Arch Clin Exp Ophthalmol*. 2022;260(5):1713–1721. <https://doi.org/10.1007/s00417-021-05487-4>.
- Shields CL, Materin MA, Mehta S, Foxman BT, Shields JA. Regression of extrafoveal choroidal osteoma following photodynamic therapy. *Arch Ophthalmol*. 2008;126(1):135–137. <https://doi.org/10.1001/archophth.126.1.135>.
- Shields CL, Perez B, Materin MA, Mehta S, Shields JA. Optical coherence tomography of choroidal osteoma in 22 cases: evidence for photoreceptor atrophy over the decalcified portion of the tumor. *Ophthalmology*. 2007;114(12):e53–e58. <https://doi.org/10.1016/j.ophtha.2007.07.037>.
- Hasanreisoglu M, Shields JA, Mashayekhi A, Shields CL. Bilateral choroidal osteoma: visual acuity at 45-year follow-up. *Retin Cases Brief Rep*. 2015;9(3):239. <https://doi.org/10.1097/ICB.0000000000000148>.
- Shields CL, Arepalli S, Atalay HT, Ferenczy SR, Fulco E, Shields JA. Choroidal osteoma shows bone lamella and vascular channels on enhanced depth imaging optical coherence tomography in 15 eyes. *Retina*. 2015;35(4):750. <https://doi.org/10.1097/IAE.0000000000000376>.
- Cummings SR, Ferrari S, Eastell R, et al. Vertebral fractures after discontinuation of denosumab: a post hoc analysis of the randomized placebo-controlled freedom trial and its extension. *J Bone Miner Res*. 2018;33(2):190–198. <https://doi.org/10.1002/jbmr.3337>.
- Ilias I, Millionis C, Zoumakis E. An overview of glucocorticoid-induced osteoporosis. In: Feingold KR, Anawalt B, Blackman MR, et al., eds. *Endotext*. MDText.com, Inc.; 2000. <http://www.ncbi.nlm.nih.gov/books/NBK278968/>. Accessed August 4, 2024.
- Leitão Guerra RL, Arantes RC, Marback EF, Shields CL. Novel OCT findings in choroidal osteoma: brief report. *Int J Retina Vitreous*. 2021;7:46. <https://doi.org/10.1186/s40942-021-00317-5>.
- Shoback DM, Schafer AL, Bikle DD. Metabolic bone disease. In: Gardner DG, Shoback D, eds. *Greenspan's Basic & Clinical Endocrinology*. tenth ed. McGraw-Hill Education; 2017. accessmedicine.mhmedical.com/content.aspx?aid=1144815694. Accessed February 6, 2024.
- Foster BS, Fernandez-Suntay JP, Dryja TP, Jakobiec FA, D'Amico DJ. Surgical removal and histopathologic findings of a subfoveal neovascular membrane associated with choroidal osteoma. *Arch Ophthalmol*. 2003;121(2):273–276. <https://doi.org/10.1001/archophth.121.2.273>.
- Wang M, Wu YF, Giris CM. Bisphosphonate drug holidays: evidence from clinical trials and real-world studies. *JBMR Plus*. 2022;6(6), e10629. <https://doi.org/10.1002/jbmr4.10629>.