



Case report

Unusual longstanding intrabronchial foreign body masquerading as intractable bronchial asthma in an adult: Case report and literature review

Zephania Saitabau Abraham^{a,*}, Faustine Bukanu^b, Olivia Michael Kimario^c,
Aveline Aloyce Kahinga^d

^a Department of Surgery, University of Dodoma, School of Medicine and Dentistry, Dodoma, Tanzania

^b Department of Otorhinolaryngology, The Benjamin Mkapa Hospital, Dodoma, Tanzania

^c Department of Otorhinolaryngology, Catholic University of Health and Allied Sciences, Mwanza, Tanzania

^d Department of Otorhinolaryngology, Muhimbili University of Health and Allied Sciences, Dar es Salaam, Tanzania



ARTICLE INFO

Keywords:

Intrabronchial
Foreign body
Longstanding
Bronchial asthma

ABSTRACT

Introduction and importance: Tracheo-bronchial foreign body inhalation is a very common encounter in clinical practice among pediatric patients and rarely seen among adults. When inhalation of foreign bodies occurs in adults then it tends to lodge within the right bronchial tree but in children it lodges in the central airways.

Case presentation: We present a 58 year old woman, known asthmatic for 20 years and non-smoker who presented to our clinic with history of chronic cough, wheezing and pulmonary infections that did not respond to regular antibiotics and the usual antiasthmatic medications. She reported to have inhaled a foreign body about 18 years earlier. Extraction of the foreign body was performed without complications.

Clinical discussion: A chest x-ray done was found to be normal and computerized tomography scan (CT scan) of the chest was ordered and revealed bronchial wall thickening with a calcified foreign body seen in the right intermediate bronchus.

A combined rigid and flexible endoscopic bronchoscopy was performed and a chicken bone (measuring 2 cm × 1.5 cm) was extracted from the right intermediate bronchus with very minimal bleeding being encountered during and post bronchoscopy. Extraction of the foreign body was performed without complications. Post endoscopic intrabronchial foreign body removal, the patient recovered completely.

Conclusion: An intrabronchial foreign body being masked for more than a decade by co-existent bronchial asthma is a rare encounter. Moreover, adult patients with chronic cough should be handled with caution to rule out the possibility of FB aspiration.

1. Introduction

Tracheo-bronchial foreign bodies (FBs) inhalation is a very common encounter in clinical practice among pediatric patients and rarely seen among adults [1,2]. When inhalation of foreign bodies occurs in adults then it tends to lodge within the right bronchial tree but in children it lodges in the central airways [1,3–6]. In some other circumstances, spontaneous migration from the airways to the gastrointestinal tract may occur though this is a very rare encounter in clinical practice [2].

Children most frequently inhale peanuts as foreign bodies and other inhaled foreign bodies among children include plastic or metallic beads, groundnuts [3,7,8]. Among adults, fish and chicken bones, and the aspiration of inorganic materials (plastic, coins, pins), which often

includes dental devices, are more frequent [1,3,4,6,9–12].

Adults who have inhaled foreign bodies tend to present with a history of cough, wheezes, hemoptysis and dyspnea [1,3,8,12–15]. In order to establish the diagnosis of FB inhalation when clinically suspected, radiological methods such as plain chest radiograph and CT scan are normally used for confirmation [3]. In some other instances, diagnostic bronchoscopy may not be done in some selected foreign bodies that can't be visualized by radiologic methods [3].

Longstanding inhaled foreign bodies often pose challenge to patients in terms of connecting the current presenting symptoms with such history of accidental inhalation of FBs thus masking the exact medical diagnosis and diagnoses such as bronchial asthma may be established due to symptoms such as cough, wheezes, dyspnea and thus

* Corresponding author at: Department of Surgery, University of Dodoma, School of Medicine and Dentistry, Tanzania.

E-mail address: zsaitabau@yahoo.com (Z.S. Abraham).

<https://doi.org/10.1016/j.ijscr.2021.106340>

Received 11 August 2021; Received in revised form 18 August 2021; Accepted 21 August 2021

Available online 24 August 2021

2210-2612/© 2021 The Authors. Published by Elsevier Ltd on behalf of IJS Publishing Group Ltd. This is an open access article under the CC BY-NC-ND license

(<http://creativecommons.org/licenses/by-nc-nd/4.0/>).

masquerading longstanding inhaled FBs [1,3,5,6,9–12,16–18].

Complications may arise when the diagnosis of foreign body (FB) inhalation goes unestablished for quite a long period of time such as lung abscess, intractable pneumonia, atelectasis and later on when attempt is made to extract such foreign bodies then mucosal inflammation and granulation tissues makes it extremely difficult [3–6,9]. The work has been reported in line with the SCARE 2020 criteria [19].

2. Case presentation

A 58-year-old woman, who was a nonsmoker with chronic bronchial asthma diagnosed at the age of 38 years, was first seen at our otorhinolaryngology outpatient clinic with a history of wheezing and chronic cough occasionally productive and non-blood stained for about 18 years.

Her medical history was remarkable for chronic cough, wheezing, recurrent respiratory tract infections, and bronchial asthma that were even poorly controlled despite being on anti-leukotrienes, inhaled steroids and beta-2 agonists.

Physical examination revealed no abnormalities in the respiratory system.

Results of laboratory tests (Full blood picture), HIV serology (negative) and sputum for acid-fast bacilli (negative) were normal except erythrocyte sedimentation rate (36/h) that was elevated.

CT of the chest showed bronchial wall thickening with a calcified foreign body seen in the right intermediate bronchus. (Photograph 1).

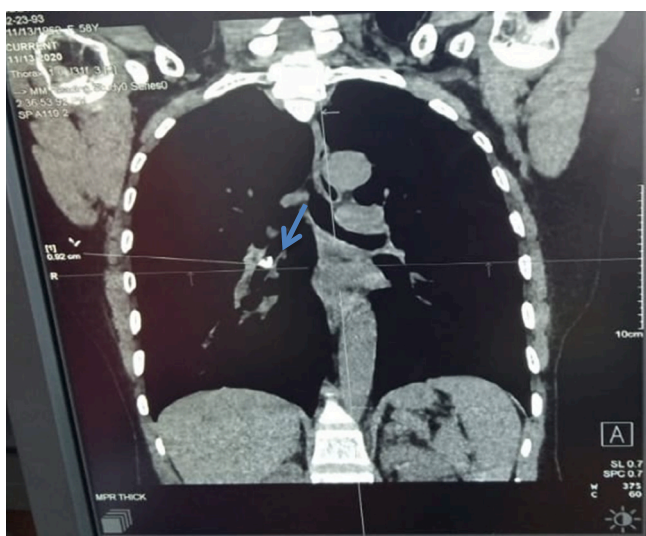
A combined rigid and flexible endoscopic bronchoscopy was performed and a meat bone (measuring 2 cm × 1.5 cm) was extracted from the right lower lobe bronchus. (Photograph 2) Extraction of the foreign body was performed without complications.

Postoperatively, the patient was kept on intravenous ceftriaxone 1 g 12 hourly for 72 h, intravenous dexamethasone 8 mg 8 hourly for 72 h and then she was kept on oral amoxicillin/clavulanate 625 mg 12 hourly for 7 days.

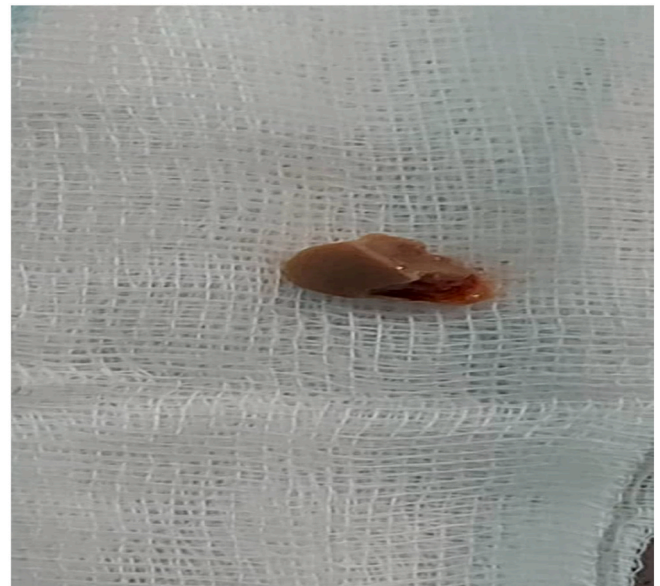Following, intrabronchial foreign body removal, the patient recovered completely from the previous symptoms following the scheduled postoperative follow-ups.

3. Discussion

Though common among the pediatric population, inhalation of foreign bodies can occur at any age and in most cases appears to be accidental [1,3,7].



Photograph 1. CT scan of the chest showing a calcified foreign body in the right intermediate bronchus.



Photograph 2. A piece of chicken bone upon its removal by means of bronchoscopy.

FB inhalation tends to be manifested invariably where children presents with cough where at the scene cough is of sudden onset, choking, and wheezing and may lead to acute respiratory failure and sometimes death [3,20].

Adults with inhaled FBs may present with characteristic features mainly related to an accidental inhalation that takes place during swallowing [1,3].

There are several predisposing factors for foreign bodies inhalation in adults such as advanced age, altered mental state, alcoholism, sedative and also may follow dental procedures such as tooth extraction or placement of dentures though at times may occur among those with no obvious predisposing factors when patients give no clear history of inhaling foreign bodies [3,5]. Such pattern may be seen similarly in the case we are hereby reporting especially when symptoms following FB inhalation may mix up with preexisting bronchial asthma thus delaying the diagnosis.

Several studies have reported adult patients to forget the act of aspirating foreign bodies and others ended up recalling an accidental act of inhaling foreign bodies several years back [13–15]. This appears to be similar to what was found in our case report where the elderly woman reported to have inhaled such a foreign body about 18 years back.

Clinically, in adults with a history of foreign body inhalation, the right lung is commonly affected because of the desirable angle formed by the trachea and the right main bronchus that tends to favor easy passage of the aspirated foreign body [3]. No complete occlusion of an adult bronchus occurs following foreign body aspiration and therefore patients may aspirate foreign bodies and present with symptoms for quite a long period of time before the diagnosis is established because of mimicking other respiratory diseases such as bronchial asthma [1,3] similar to what has been found in our case report. Such pattern of foreign body aspiration appears to be different from what is seen in children where the central airway is commonly obstructed and therefore may present with features of immediate respiratory distress following inhalation of foreign bodies [3,5,10].

If no prompt treatment is executed following aspiration of foreign bodies, they may remain for quite a long period of time within the tracheobronchial tree and this may be more marked in radiopaque foreign bodies where imaging rarely guides towards establishing the diagnosis of foreign body aspiration [1,3]. Such delay in diagnosis leads to chronic symptoms or recurrent pulmonary infections and therefore erroneously establishing the diagnosis of bronchial asthma [3].

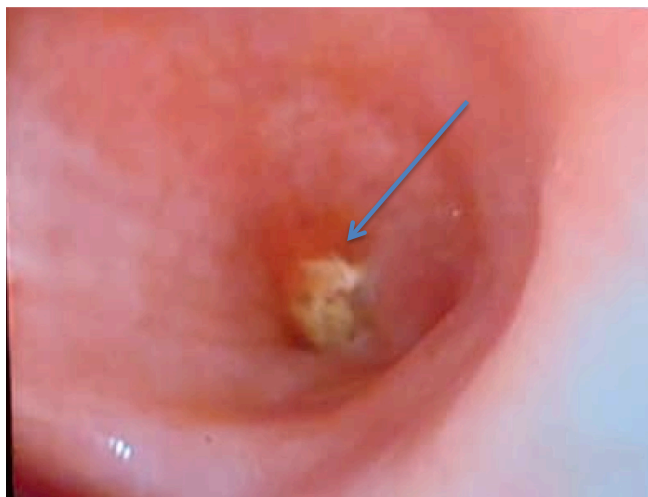Moreover, it has been shown that the diagnosis in the adult population is more frequently delayed compared with the pediatric population, though FB aspiration is a more frequent phenomenon in children than in adult patients [1,3,6,9]. When foreign body aspiration occur, the patient may show features of sudden onset of coughing and shortness of breath which when such episode attenuates then its forgotten [3,5] thus attributing to delay in the diagnosis of foreign body aspiration in adult population.

The clinical picture depicted in our case report was masked by chronic preexisting asthma where the patient presented with symptoms such as longstanding cough and wheezes that did not respond to the executed medical treatment. Such finding appears to be similar to what was reported in a case report from Spain [3].

If no prompt accurate diagnosis of FB aspiration is made, complications may ensue depending on the type of foreign body and the amount of time it has remained lodged inside the airway. Such complications include bronchiectasis, hemoptysis, bronchial stricture, post-obstructive pneumonia, lung abscess, empyema, progressive respiratory failure, inflammatory polyps within airways particularly where the FB has lodged, or diminution of the perfusion in the affected lung [3]. Our case report depicts an interesting finding since the chicken bone remained in the tracheobronchial tree for 18 years with no resultant bronchiectasis, atelectasis, or bronchial stenosis. This may be because of the fact that the chicken bone had no occlusive effect to the tracheobronchial tree as seen in [photograph 3](#) and therefore permitting distal ventilation and almost free movement of tracheobronchial secretions and therefore explaining such history of chronic cough, wheezing and recurrent pulmonary infections in absence of the stated irreversible complications of long standing inhaled FBs.

On the other hand, it may be postulated that the foreign body in this case report did not generate an infectious inflammatory process during this period, as well as the formation of a granuloma or bronchial perforation because the patient was known to have bronchial asthma prior FB inhalation and since the patient was kept on antibiotics and systemic steroids during exacerbations, then this may have hindered the occurrence of such phenomenon.

Imaging techniques are of importance in establishing the diagnosis of FB inhalation especially when it's radiopaque or by showing mere indirect signs of its presence in the tracheobronchial tree and such signs include lung collapse, lung hyperinflation and cystic bronchiectasis though it may be a usual finding to find a normal radiologic evaluation or a non-specific evaluation being not consistent with FB aspiration [1,3,9,14,16]. Such non-consistent findings may be depicted from the study that was conducted in China where radiologic report was found to



Photograph 3. Intraoperative endoscopic view of the foreign body in the right intermediate bronchus.

be normal and alterations seen (21% of patients) were unrelated to the presence of foreign bodies in the tracheobronchial tree [10] similar to what was seen in the chest x-ray of the patient reported in our case report which was normal.

Bronchoscopy remains to be the most useful diagnostic tool in FB aspiration and the findings vary according to the type of FB and the duration of the retention of such FB in the tracheobronchial tree. If such procedure is performed early after aspiration, then the only finding intraoperatively may be minimal erythema but inflammatory polyps within the tracheobronchial tree at the site where it has lodged may be seen following longstanding inhaled FBs [1,3,6].

Regarding the modality for removal of foreign bodies in the tracheobronchial tree, there has been a debate over the role of rigid bronchoscopy versus flexible bronchoscopy and such controversy has existed since 1970 when the clinical use of flexible bronchoscopes was introduced [3,5]. Our suggestion as authors of this case report regarding the ideal modality for removal of FBs from the tracheobronchial tree appears to be in line with what was suggested by some authors who concluded that rigid and flexible bronchoscopes are complementary tools and the choice of the removal technique should be individualized though rigid bronchoscopy is the treatment of choice in FB aspirations in the pediatric population [3]. In the adult population, flexible bronchoscopy should be performed first to establish the diagnosis of FB inhalation and then further decision should be made on how to proceed with such procedure though small, uncomplicated FBs are easily removed by flexible bronchoscopy, whereas large are safely removed by means of rigid bronchoscopy [3,5]. In our case, we utilized both rigid and flexible bronchoscopy techniques to remove the chicken bone from the right intermediate bronchus of the elderly woman and it was successful without any complications.

4. Conclusion

We present an unusual case of long standing left sided intrabronchial foreign body being masked for more than a decade by co-existent bronchial asthma and no irreversible complications reported despite such foreign body being aspirated 18 years earlier. Thus adult patients with chronic cough should be handled with caution to rule out the possibility of FB aspiration similar to non-specific recurrent pulmonary infections.

Sources of funding

None.

Ethical approval

Ethical standards were reviewed and approved by the Head of Department of Otorhinolaryngology at the Zonal Referral Hospital.

Consent

Written informed consent was obtained from the patient for publication of this case report and accompanying images. A copy of the written consent is available for review by the Editor-in-Chief of this journal on request.

Registration of research studies

N/A.

Guarantor

Dr. Zephania Saitabau Abraham takes full responsibility of the work.

Provenance and peer review

Not commissioned, externally-peer reviewed.

CRedit authorship contribution statement

ZSA-Conceptualization, methodology, writing original draft.

FB-Conceptualization and reviewing the prepared original draft of the manuscript.

OMK- Conceptualization and reviewing the prepared original draft of the manuscript.

AAK- Conceptualization, methodology and reviewing the prepared original draft of the manuscript.

Declaration of competing interest

The authors report no conflict of interest.

References

- [1] D. Weissberg, I. Schwartz, Foreign bodies in the tracheobronchial tree, *Chest* 91 (5) (1987) 730–733.
- [2] Z.S. Abraham, A.A. Kahinga, K.B. Mapondella, E.R. Massawe, D. Ntunaguzi, Spontaneous expulsion of an intrabronchial sharp metallic foreign body and migration to the gastrointestinal tract at Muhimbili National Hospital: case report and literature review, *Int. J. Surg. Case Rep.* 1 (72) (2020) 423–425. Jan.
- [3] F.R. Villegas, M. Zuñil, M.J. Chillón, J.P. Díaz-Jiménez, J. Jareño, A.N. Rodríguez, F. J. Gómez-Terreros, L.M. Callol, Longstanding intrabronchial foreign body in an adult, *J. Bronchol. Interv. Pulmonol.* 8 (4) (2001 Oct 1) 289–293.
- [4] J.C. Hewlett, O.B. Rickman, R.J. Lentz, U.B. Prakash, F. Maldonado, Foreign body aspiration in adult airways: therapeutic approach, *J. Thorac. Dis.* 9 (9) (2017 Sep) 3398.
- [5] A.H. Limper, U.B. Prakash, Tracheobronchial foreign bodies in adults, *Ann. Intern. Med.* 112 (8) (1990) 604–609.
- [6] T.H. Wu, Y.L. Cheng, C. Tzao, H. Chang, C.M. Hsieh, S.C. Lee, Longstanding tracheobronchial foreign body in an adult, *Respir. Care* 57 (5) (2012) 808–810.
- [7] Z. Saitabau, B.E. Mrisho, H. Swai, D. Ntunaguzi, E.R. Massawe, An unusual long standing tracheal foreign body in a paediatric patient removed via tracheostome: a case report, *Indian J. Case Rep.* (2019) 268–270.
- [8] D. Mehta, C. Mehta, S. Bansal, S. Singla, N. Tangri, Flexible bronchoscopic removal of a three piece foreign body from a child's bronchus, *Australas Med J* 5 (4) (2012) 227.
- [9] H. Benjelloun, N. Zaghba, A. Bakhtar, N. Yassine, A. Bahlaoui, Tracheobronchial foreign bodies in adults, *Pan Afr. Med. J* 19 (2014) 220. Oct 28.
- [10] C.H. Chen, C.L. Lai, T.T. Tsai, Y.C. Lee, R.P. Perng, Foreign body aspiration into the lower airway in Chinese adults, *Chest* 112 (1) (1997) 129–133.
- [11] A.S. Abdel-Salam, A.G. Gibb, Undiagnosed bronchial foreign body—golf tee, *J. Laryngol. Otol.* 94 (6) (1980) 671–675. Jun.
- [12] A. Philip, V. Rajan Sundaresan, P. George, S. Dash, R. Thomas, A. Job, V.K. Anand, A reclusive foreign body in the airway: a case report and a literature review, *Case Rep. Otolaryngol.* 7 (2013) 1–4.
- [13] M. Boyd, F. Watkins, S. Singh, E. Haponik, A. Chatterjee, J. Conforti, R. Chin Jr., Prevalence of flexible bronchoscopic removal of foreign bodies in the advanced elderly, *Age Ageing* 38 (4) (2009) 396–400.
- [14] K. Acharya, Rigid bronchoscopy in airway foreign bodies: value of the clinical and radiological signs, *Int. Arch. Otorhinolaryngol.* 20 (2016) 196–201.
- [15] W.C. Hsu, T.S. Sheen, C.D. Lin, C.T. Tan, T.H. Yeh, S.Y. Lee, Clinical experiences of removing foreign bodies in the airway and esophagus with a rigid endoscope: a series of 3217 cases from 1970 to 1996, *J. Otolaryngol. Head Neck Surg.* 122 (3) (2000) 450–454.
- [16] W.B. Yan, G.M. Zhang, An iron nail in the right inferior lobe bronchus in an adult retrieved by bronchoscopic cryotherapy technique, *J. Coll. Physicians Surg. Pak.* 30 (7) (2020) 768.
- [17] L. Wang, B. Pudasaini, X.F. Wang, Diagnose of occult bronchial foreign body: a rare case report of undetected Chinese medicine aspiration for 10 long years, *Medicine* 95 (31) (2016).
- [18] Y.H. Kim, C.W. Choi, H.S. Choi, M.J. Park, H.M. Kang, J.H. Yoo, Clinical features of tracheobronchial foreign bodies in adults according to the risk of aspiration, *Tuberc. Respir. Dis.* 64 (5) (2008 May 1) 356–361.
- [19] for the SCARE Group, R.A. Agha, T. Franchi, C. Sohrabi, G. Mathew, The SCARE 2020 guideline: updating consensus Surgical CAse REport (SCARE) guidelines, *Int. J. Surg.* 84 (2020) 226–230.
- [20] R.E. Black, K.J. Choi, W.C. Syme, D.G. Johnson, M.E. Matlak, Bronchoscopic removal of aspirated foreign bodies in children, *Am. J. Surg.* 148 (6) (1984 Dec 1) 778–781.