



Case report

Atypical presentation of Coats' Syndrome in facioscapulohumeral dystrophy - Reflecting the variation in phenotypic manifestations



Rashmi Akshikar^{a,*}, Rui Feng^b, Kiranpreet Gill^a, Luke Chehade^c, Edward Hughes^c

^a Imperial College Healthcare NHS Trust, The Bays, South Wharf Road, St Mary's Hospital, London, W2 1NY, United Kingdom

^b Imperial College London, Exhibition Road, London, SW7 2AZ, United Kingdom

^c Brighton and Sussex University Hospitals NHS Trust, Sussex Eye Hospital, Eastern Road, Brighton, BN2 5BF, United Kingdom

ARTICLE INFO

Keywords:

Atypical Coats' Syndrome
Exudative retinopathy with telangiectasia
Facioscapulohumeral dystrophy

ABSTRACT

Purpose: To report a unique case of atypical Coats' Syndrome in an 80 year old female with facioscapulohumeral dystrophy.

Observations: An 80 years old female was diagnosed clinically of retinal telangiectasia with exudation threatening the fovea. She received a successful macular laser photocoagulation with subsequent cessation of leakage. **Conclusions and importance:** This case is in keeping with Coats' syndrome in facioscapulohumeral dystrophy, which classically affects young male subjects - making this patient an obvious outlier. This once again reflects the variation in phenotypic manifestations of inherited disorders.

1. Introduction

Facioscapulohumeral dystrophy (FSHD) is a rare autosomal dominant hereditary muscular dystrophy affecting the facial, shoulder and upper arm muscles, with an estimated prevalence of 5 in 100,000.¹ The association of peripheral retinal capillary abnormalities with FSHD is well-known as approximately 0.8% of FSHD patients develop exudative retinopathy with telangiectasia² – a condition mimicking Coats' Disease which is commonly referred to as Coats' Syndrome.³ The mean age of presentation is 10 years, with 76% of patients being male and 95% being unilateral.¹ We report an unusual case of Coats' Syndrome in an 80 year old female with FSHD.

2. Case report

An 80 year old lady was referred to the eye clinic by her optician, having presented with symptoms of blurred vision in the left eye over the past 2 months. She was diagnosed with FSHD at the age of 20, and has a strong family history of the condition which extends to her sister, paternal uncle and two cousins. She has been using a wheelchair for over 10 years due to limb girdle weakness. Her past ophthalmological history is remarkable for mild ptosis and lower lid ectropion bilaterally. She was not a known vasculopath and relevant investigations for hypertension and diabetes initiated by her GP following optician referral were negative.

Visual acuity (VA) was 6/12 in the affected left eye, and 6/9 in the

right eye. Early cataract was visible bilaterally on examination. The right fundus was unremarkable, while the left eye demonstrated telangiectatic lesions with a circinate formation of exudates (Fig. 1a). Spectral domain OCT scanning/Topcon 3D 2000 (SD-OCT) revealed exudative and intraretinal fluid threatening the fovea (Fig. 1b). Fluorescein angiography (FA) showed 3 areas of hyper fluorescence temporal to the left macula indicative of leaking telangiectatic lesions (Fig. 1c). There was no evidence of a choroidal neovascular membrane or vascular occlusions. Consequently, a diagnosis of Coats' Syndrome stage 2A was confirmed based on the classification devised from Shields et al.¹ Laser photocoagulation was applied to the leaking telangiectasia using a Pascal laser.

The most recent follow up was one year after the initial presentation. The patient had a stable VA of 6/12. A repeated SD-OCT scan demonstrated no leakage and a near complete resolution of the exudates (Fig. 2).

3. Discussion

Our 80 year old female patient with FSHD presented with an unusual case of Coats' Syndrome, which is classically observed in the male adolescent population.^{1,3} Although an exceedingly rare occurrence in adults, such cases have been reported in the literature. To the best of our knowledge, the oldest reported age of Coats' Syndrome occurring in association with FSHD in a female patient is 55 years old.⁴ However, this is the first time it has been detected in an 80 year old female

* Corresponding author.

E-mail address: rakshikar@doctors.org.uk (R. Akshikar).

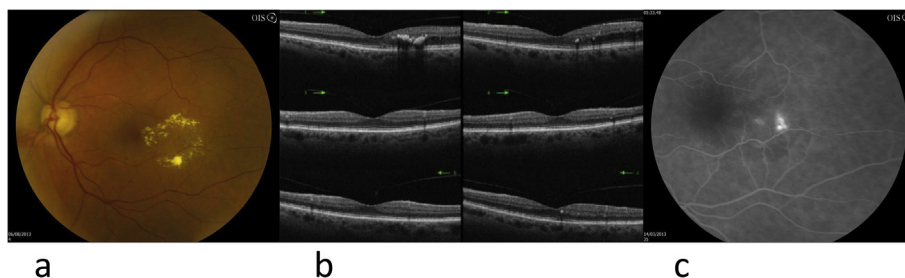


Fig. 1. (a) Telangiectatic lesions with a circinate formation of exudates temporal to the left macula. (b) SD-OCT scan revealed exudates and intraretinal fluid threatening of the fovea. (c) FA showed three areas of hyper-fluorescence temporal to left macula indicative of leaking telangiectatic lesions.

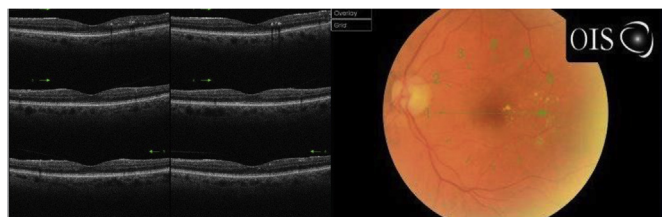


Fig. 2. One year follow-up revealed no leakage and a near complete resolution of exudates.

patient. We believe this is due to a phenotypic variation of the disease.

The current hypothesis of the underlining mechanism between FSHD and Coats' Syndrome is based on the potential mutation of a yet unidentified component in the Wnt signalling cascade, which may results in the interference of retinal angiogenesis, cochlear vasculature development, myogenesis, and muscle regeneration.⁵ FSHD associated with Coat's Syndrome commonly affects young men in the second decade of life - making our patient an obvious outlier, which once again reflects the variation in phenotypic manifestation of inherited disorders.

Patient consent

Patient consent was not obtained as all personal information that could lead to identification has been removed.

Funding

Imperial College London Open Access Fund, an unrestricted grant,

was provided by Imperial College London to publish this work.

Conflicts of interest

None.

Authorship

All authors attest that they meet the current ICMJE criteria for Authorship.

Acknowledgements

None.

References

1. Shields JA, Shields CL, Honavar SG, Demirci H, Cater J. Classification and management of coats disease: the 2000 proctor lecture. *Am J Ophthalmol.* 2001;131:572–583.
2. Statland JM, Sacconi S, Farmakidis C, Donlin-Smith CM, Chung M, Tawil R. Coats syndrome in facioscapulohumeral dystrophy type 1: frequency and D4Z4 contraction size. *Neurology.* 2013;80:1247–1250.
3. Shields CL, Zahler J, Falk N, et al. Neovascular glaucoma from advanced coats disease as the initial manifestation of facioscapulohumeral dystrophy in a 2-year-old child. *Arch Ophthalmol.* 2007;125:840–842.
4. Smithen LM, Brown GC, Brucker AJ, Yannuzzi LA, Klais CM, Spaide RF. Coats' disease diagnosed in adulthood. *Ophthalmology.* 2005;112:1072–1078.
5. Fitzsimons RB. Retinal vascular disease and the pathogenesis of facioscapulohumeral muscular dystrophy. A signalling message from wnt? *Neuromuscul Disord.* 2011;21:263–271.