

Multiple lumbar vertebral fractures following a single idiopathic seizure in an otherwise healthy patient; a case report

Ebrahim Ghayem Hasankhani¹, Farzad Omid-Kashani²

Orthopedics Research Center, Imam Reza Hospital, Mashhad University of Medical Sciences, Mashhad, Iran.

Received: 30 Dec 2012

Revised: 28 Apr 2013

Accepted: 13 May 2013

Abstract

It has been reported that fractures are more common in epileptic patients relative to the general population. Seizures by repeated muscular contractions can increase fracture risk throughout the skeleton, but the reported papers about non-traumatic vertebral fractures following a single episode of seizure are rare and mostly located in thoracic spine with only one or two vertebral fracture. The case we reported here was a 42 year old otherwise healthy man who had three vertebral fractures due to a single idiopathic seizure affected the lumbar region with no previous history of underlying disease, trauma, or drug use.

Keywords: Seizure, Vertebral fracture, Non-traumatic fracture.

Introduction

Seizures increase fracture risk throughout the skeleton even without any direct trauma by the muscular contractions (1). There are numerous reports in the literature about the seizure induced fracture or dislocation in shoulder, femur, acetabulum or even spinal column that mostly reported in thoracic or thoracolumbar region (2).

It has been reported that fractures are 2–6 times more common in epileptic patients relative to the general population (3, 4). Vertebral compression fractures are common in patients with epilepsy and not related to the osteomalacia secondary to antiepileptic drugs. Vertebral fractures in epilepsy generally involve the vertebral bodies of the thoracic portion of the spine and the affected vertebra is usually single one (2).

We report one case of vertebral fractures due to a single idiopathic seizure that affected three lumbar vertebrae with no previous illness, trauma, or drug use.

Case study

A 42-year-old man with a history of seizures (at the time of driving) and back pain for three days was referred to the orthopedic clinic with severe pain in dorsolumbar area and inability to walk. While driving in the street, he got a single seizure and then without any occurrence of a traffic accident, he was driven out of the car by medical emergency team. The patient was the only passenger in the car and consciousness was not impaired. At presentation, the neurological examination of upper and lower limbs was completely intact. He complained of pain in the dorsolumbar area without any significant posterior point tenderness. Laboratory findings, brain CT, MRI and electroencephalography were normal, while plain radiography of the dorsolumbar region revealed the L2-L3-L4 vertebral fractures (Fig. 1). The spiral computerized tomography scanning confirmed three levels lumbar vertebral fracture and

1. Associate Professor of Orthopedic, Orthopedic Research Center, Orthopedic department, Imam Reza Hospital, Mashhad University of Medical science, Mashhad, Iran.

2. (**Corresponding author**) Associate Professor of Orthopedic, Orthopedic Research Center, Orthopedic department, Imam Reza Hospital, Mashhad University of Medical science, Mashhad, Iran. omidif@mums.ac.ir

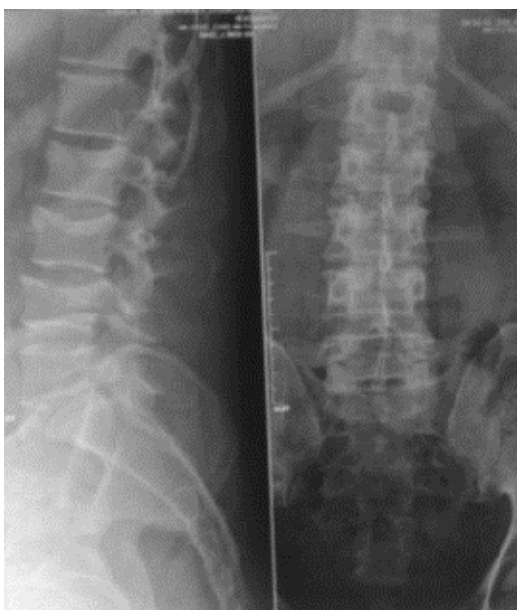


Fig. 1. Plain anteroposterior and lateral radiographs of the lumbosacral spine. Superior end-plate fracture of the L2, L3 and L4 are evident.

the extent of injury (Fig. 2).

The patient treated conservatively with a lumbosacral orthosis. Ambulation was started two days later, but a comprehensive study comprised of a thorough internal medical work up to rule out underlying causes like osteoporosis was carried out. Bone mineral densities of the hip and lumbar spine were determined by dual-energy x-ray absorptiometry scan. T scores for hip and lumbar area were 0.4 and 0.2, while Z

scores for these regions were 0.6 and 0.3, respectively. These scores according to World Health Organization (WHO) completely rule out underlying osteoporotic disorders (5). 3 months after the accident, the brace was removed and physiotherapy started. One year later at the latest follow up visit, the patient had no problem and returned to his previous level of activity and work.

Discussion

The fractures and dislocations of the shoulder and hip, and fractures of the femur acetabulum and vertebrae following seizure have been reported previously (6, 7). Shoulder dislocation is the most common injury reported and the vertebral fracture is the rarest.

Fracture is relatively common in epileptic patients, but this usually occurs after generalized tonic and clonic seizures and is unusual in idiopathic seizures (8). Pathologic fractures are also more commonly observed in epileptic patients and these are usually related to the associated osteopenia (secondary to epileptic drugs), insulin-dependent diabetes mellitus, and corticotherapy (9-11). Our case had no underlying bony pathology or osteopenia.

In the case we reported here, the patient had no previous history of epilepsy and

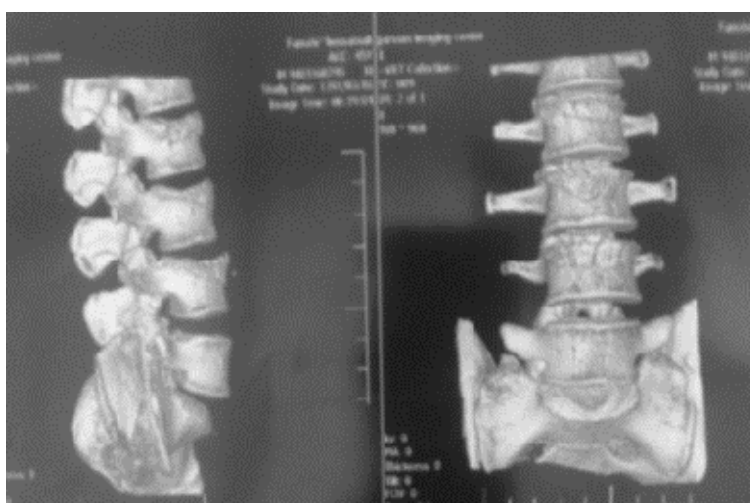


Fig. 2. Three dimensional computerized tomography of the lumbar spine. The three consecutive fractured vertebrae are easily detected. Lumbar lordosis was relatively maintained and middle column was intact.

other diseases. Usually intense muscle contractions that occur during seizures may lead to extension of the cervical and lumbar spine and flexion and angulation of the thoracic spine, therefore the vertebral fracture is more common at thoracic region (4). The position of the patient during the seizure can alter the fracture pattern and location. In our patient, the seizure occurred while the patient was driving with his lumbar spine in a flexed position.

The number of fractured vertebra reported in associate with epileptic seizures is usually one or two (4) while in this case, three adjacent lumbar vertebrae were injured and according to our knowledge, this is the first case that has been reported with three consecutive lumbar vertebral fractures that occurred after a non-epileptic seizure in an otherwise healthy patient.

Conclusion

In the convulsive patients presented with refractory significant pain and localized tenderness on the spinal column, the physician has to consider the probability of spinal fractures even if no history of a direct trauma existed. Moreover in these cases, more imaging pictures should be requested.

References

1. O'connor-Read L, Bloch B, Brownlow H. A missed orthopaedic injury following a seizure: a case report. *J Med Case Rep* 2007; 1: 20.
2. Takahashi T, Tominaga T, Shamoto H, Shimizu H, Yoshimoto T. Seizure-induced thoracic spine compression fracture: case report. *Surg Neurol* 2002; 58(3-4): 214-6.
3. Nicodemus KK, Folsom AR. Iowa Women's Health Study. Type 1 and type 2 diabetes and incident hip fractures in postmenopausal women. *Diabetes Care* 2001; 24(7): 1192-7.
4. Ach K, Slim I, Ajmi ST, Chaieb MC, Bezig AM, Chaieb L. Non-traumatic fractures following seizures: two case reports. *Ach et al. Cases J* 2010; 3: 30.
5. Lu Y, Genant HK, Shepherd J, Zhao S, Mathur A, Fuerst TP, Cummings SR. Classification of osteoporosis based on bone mineral densities. *J Bone Miner Res* 2001; 16(5): 901-10.
6. Marsh JP, Leiter JR, Macdonald P. Bilateral femoral neck fractures resulting from a grand mal seizure in an elderly man with Down syndrome. *Orthop Rev (Pavia)* 2010; 2(1): e10.
7. Grimaldi M, Vouaillat H, Tonetti J, Merloz P. Simultaneous bilateral femoral neck fractures secondary to epileptic seizures: treatment by bilateral total hip arthroplasty. *Orthop Traumatol Surg Res* 2009; 95(7): 555-7.
8. Persson HB, Alberts KA, Farahmand BY, Tomson T. Risk of extremity fractures in adult outpatients with epilepsy. *Epilepsia* 2002; 43(7): 768-72.
9. Alomran AS. Osteoporosis-related simultaneous four joints fractures and dislocation after a seizure: a case report. *J Osteoporos* 2010; 2010: 808341.
10. De Vries F, Bracke M, Leufkens HG, Lammers JW, Cooper C, Van Staa TP. Fracture risk with intermittent high-dose oral glucocorticoid therapy. *Arthritis Rheum* 2007; 56(1): 208-14.
11. Steinbuch M, Youket TE, Cohen S. Oral glucocorticoid use is associated with an increased risk of fracture. *Osteoporos Int* 2004; 15(4): 323-8.