

Single Case

A Case of Dermatomyositis Coexisting with Both Anti-Mi-2 and Anti-NXP-2 Antibodies

Mitsuru Ito^a Chie Moriya^a Kanako Matsuyama^a En Shu^a
Yasuhito Hamaguchi^b Mariko Seishima^a

^aDepartment of Dermatology, Gifu University Graduate School of Medicine, Gifu, Japan;

^bDepartment of Molecular Pathology of Skin, Kanazawa University Graduate School of Medicine, Kanazawa, Japan

Keywords

Anti-Mi-2 antibody · Anti-NXP-2 antibody · Dermatomyositis · Myositis-specific autoantibody

Abstract

Myositis-specific autoantibodies (MSAs) including anti-Mi-2 and anti-nuclear matrix protein 2 (NXP-2) antibodies have been detected in the patients with dermatomyositis (DM), and are useful tools for identifying clinical subsets of DM. MSAs are exclusively found in DM patients. Anti-Mi-2 antibody-positive DM patients show the typical skin lesions and myositis and are rarely associated with internal malignancy and interstitial lung disease (ILD). On the other hand, adult DM patients with anti-NXP-2 antibody often show calcinosis and internal malignancy, but rarely ILD. In addition, anti-NXP-2 antibody-positive DM patients have severe phenotype with myalgia, peripheral edema, and significant dysphagia, but with mild skin lesions. Herein, we report a rare case of classic DM coexisting with both anti-Mi-2 and anti-NXP-2 antibodies, clinically, without ILD or internal malignancy. Our patient had typical skin manifestations, muscle weakness, muscle pain, and general fatigue without calcinosis, peripheral edema, or dysphagia. Thus, the clinical phenotype was similar to anti-Mi-2 antibody-positive DM.

© 2020 The Author(s)
Published by S. Karger AG, Basel

Introduction

Dermatomyositis (DM) is an idiopathic systemic inflammatory myopathy with characteristic cutaneous manifestations, including heliotrope rash, Gottron's papules, V-neck sign, shawl sign, paronychia erythema, and nailfold bleeding [1]. It is also often associated with interstitial lung disease (ILD) and/or internal malignancy. Myositis-specific autoantibodies (MSAs), including anti-aminoacyl-tRNA synthetases (ARS), anti-Mi-2, anti-melanoma differentiation-associated gene 5 product (MDA5), anti-transcriptional intermediary factor 1 gamma (TIF1- γ), and anti-nuclear matrix protein 2 (NXP-2) antibodies, have been detected in patients with DM. MSAs are almost exclusively found in DM [2]. These autoantibody-positive subgroups of DM have different clinical phenotypes. DM with anti-Mi-2 antibody shows the typical aforementioned skin symptoms [3]. It responds well to corticosteroid therapy and is rarely associated with internal malignancy and ILD. Conversely, anti-NXP-2 antibody-positive adult DM is often associated with calcinosis and internal malignancy [4]. Herein, we report a rare case of classic DM coexisting both anti-Mi-2 and anti-NXP-2 antibodies, clinically, without ILD or internal malignancy.

Case Report

A 33-year-old Japanese woman had noticed erythema on the posterior cervical region 2 months earlier. Afterwards, she experienced muscle pain in her arms and thighs with erythema on the fingers and lower extremities. On the first consultation, she had erythema on the eyelids, posterior cervical region, dorsum of distal interphalangeal joints, proximal interphalangeal joints, metacarpophalangeal joints (Fig. 1a), knees (Fig. 1b), and thighs, but not calcinosis.

Blood examination revealed elevated levels of lactate dehydrogenase (402 IU/L), creatine kinase (CK; 1052 IU/L), myoglobin (122 ng/mL), aldolase (10.7 U/L) and normal KL-6 level (177 U/mL). Antinuclear antibody was positive (speckled and homogeneous patterns; titer: $\times 160$), but antibodies to Mi-2 (titer: 17; threshold: < 53) [3], MDA5 [5], ARS [6], and TIF1- γ [3] were negative by enzyme-linked immunosorbent assay (ELISA). Immunoprecipitation (IP) assays using ^{35}S -labeled extracts of K562 cells were performed to identify MSAs [5, 7]. The patient's serum precipitated polypeptides of 200–240, 150, and 65–75 kDa that were identical to those precipitated by anti-Mi-2-positive pilot serum (Fig. 1c). Patients' sera containing antibodies to Mi-2 or NXP-2 were used as reference sera in Figure 1c. The patient's serum also precipitated 140 kDa protein. Since there were several MSAs that precipitate 140 kDa protein, such as anti-TIF1- α , anti-MDA5, and anti-NXP-2 antibodies, further IP-Western assays were conducted to identify antigen of the 140-kDa protein [8]. Immunoprecipitated materials were fractionated by SDS-PAGE and electrotransferred onto nitrocellulose membranes for the IP-Western assay. After blocking, membranes were incubated with a mixture of commercially available antibodies to human SAE, Ku, Mi-2, NXP-2, and TIF1- γ . The IP-Western assay revealed that the patient's serum was positive for both anti-Mi-2 and anti-NXP-2 antibodies (Fig. 1d). The patients' sera containing antibodies to SAE, Ku, NXP-2 or Mi-2 were used as reference sera. In addition, by the IP-Western assay using a commercially available polyclonal antibody to NXP-2 as the second antibody, antibody to NXP-2 was shown in the patient's serum (Fig. 1e).

Biopsy specimens were obtained from the itchy erythema on the upper back and left deltoid muscle. The skin biopsy showed liquefaction degeneration at the dermo-epidermal

junction and slight lymphocytic infiltration in the upper dermis. Muscle biopsy showed interstitial lymphocytic infiltration around the muscle fiber bundles. The infiltrates consisted of many CD3⁺CD4⁺ lymphocytes and few CD8⁺ lymphocytes, and CD163⁺ macrophages were also detected around the muscle fiber bundles. The muscle fibers showed necrotic changes, irregularities and reduced staining intensity.

Based on the clinical and pathological findings, we diagnosed this patient with DM according to Bohan and Peter's criteria [9]. No malignancy was found. The patient was treated with oral prednisolone 40 mg/day (0.8 mg/kg/day). Because the serum CK level rapidly declined and her muscle weakness improved after treatment, the prednisolone dose was gradually tapered. Subsequently, she had no recurrence despite prednisolone dose reduction to 10 mg/day.

Discussion

Recent studies on MSAs such as anti-Mi-2, anti-ARS, anti-MDA5, and anti-TIF1- γ antibodies have clarified that these MSAs are useful tools for identifying clinical subsets of DM [1, 2]. Anti-Mi-2 antibody was originally reported as the first marker of DM by Targoff and Reichlin [10], and DM patients with positive for this MSA are reported to have typical skin lesions (Gottron's papules, heliotrope rash, shawl sign, and V-sign) and myositis. Patients with anti-Mi-2 antibody are also reported to respond well to steroid therapy and have good prognosis. Anti-Mi-2 antibody-positive patients have a low risk of developing clinically relevant ILD and are rarely associated with cancer [2, 3, 11].

Conversely, anti-NXP-2 antibody, which was initially termed anti-MJ antibody, has been detected in both children and adult DM patients. In adults, anti-NXP-2 antibody is associated with calcinosis and possibly with internal malignancy [12]. Rogers et al. [13] showed that DM with anti-NXP-2 antibody has a distinct and often severe systemic phenotype that includes myalgia, peripheral edema, and significant dysphagia despite having milder skin lesions. Patients with anti-NXP-2 antibody also possess a lower risk of ILD, but some reports showed cancer-associated DM [12, 13].

Our patient had typical skin manifestations, muscle weakness, muscle pain, and general fatigue without calcinosis, peripheral edema, or dysphagia. Thus, the clinical phenotype was similar to anti-Mi-2 antibody-positive DM. Regarding identification of anti-Mi-2 antibody in our patient, there was a discrepancy between ELISA assay and IP assay. We presume that this discrepancy is derived from a different epitope of Mi-2 β in our patient from the antigen for the ELISA kit.

MSAs are exclusively found in DM patients. This is a rare case coexisting with both anti-Mi-2 and anti-NXP-2 antibodies. A few patients with DM [14] or polymyositis [15] coexisting with anti-Jo-1 and anti-signal recognition particle antibodies, and a patient with polymyositis coexisting with anti-signal recognition particle and anti-Mi-2 antibodies [16] have been reported. These patients showed different phenotypes such as severe symptoms [14] and both symptoms characteristic of two antibodies [15]. Further accumulation of such cases is needed to clarify the overall features of patients who have two or more MSAs.

Statement of Ethics

The patient provided written informed consent to publish her case. The study adhered to the tenets of the Declaration of Helsinki.

Disclosure Statement

The authors have no conflicts of interest to disclose.

Author Contributions

M.I. collected the data and wrote the initial manuscript draft, C.M., K.M., and E.S. gave him the advice about the diagnosis and treatment, Y.H. performed the immunoprecipitation assay, and M.S. revised the manuscript and acts as the corresponding author. All authors provided critical feedback and contributed to the final version of the manuscript.

References

- 1 Muro Y, Sugiura K, Akiyama M. Cutaneous Manifestations in Dermatomyositis: Key Clinical and Serological Features-a Comprehensive Review. *Clin Rev Allergy Immunol*. 2016 Dec;51(3):293–302.
- 2 Satoh M, Tanaka S, Ceribelli A, Calise SJ, Chan EK. A comprehensive overview on myositis-specific antibodies: new and old biomarkers in idiopathic inflammatory myopathy. *Clin Rev Allergy Immunol*. 2017 Feb;52(1):1–19.
- 3 Fujimoto M, Murakami A, Kurei S, Okiyama N, Kawakami A, Mishima M, et al. Enzyme-linked immunosorbent assays for detection of anti-transcriptional intermediary factor-1 gamma and anti-Mi-2 autoantibodies in dermatomyositis. *J Dermatol Sci*. 2016 Dec;84(3):272–81.
- 4 Ichimura Y, Matsushita T, Hamaguchi Y, Kaji K, Hasegawa M, Tanino Y, et al. Anti-NXP2 autoantibodies in adult patients with idiopathic inflammatory myopathies: possible association with malignancy. *Ann Rheum Dis*. 2012 May;71(5):710–3.
- 5 Sato S, Murakami A, Kuwajima A, Takehara K, Mimori T, Kawakami A, et al. Clinical utility of an enzyme-linked immunosorbent assay for detecting anti-melanoma differentiation-associated gene 5 autoantibodies. *PLoS One*. 2016 Apr;11(4):e0154285.
- 6 Nakashima R, Imura Y, Hosono Y, Seto M, Murakami A, Watanabe K, et al. The multicenter study of a new assay for simultaneous detection of multiple anti-aminoacyl-tRNA synthetases in myositis and interstitial pneumonia. *PLoS One*. 2014 Jan;9(1):e85062.
- 7 Komura K, Fujimoto M, Matsushita T, Kaji K, Kondo M, Hirano T, et al. Prevalence and clinical characteristics of anti-Mi-2 antibodies in Japanese patients with dermatomyositis. *J Dermatol Sci*. 2005 Dec;40(3):215–7.
- 8 Kang EH, Kuwana M, Okazaki Y, Lee EY, Lee YJ, Lee EB, et al. Comparison of radioimmunoprecipitation versus antigen-specific assays for identification of myositis-specific autoantibodies in dermatomyositis patients. *Mod Rheumatol*. 2014 Nov;24(6):945–8.
- 9 Bohan A, Peter JB. Polymyositis and dermatomyositis (first of two parts). *N Engl J Med*. 1975 Feb;292(7):344–7.
- 10 Targoff IN, Reichlin M. The association between Mi-2 antibodies and dermatomyositis. *Arthritis Rheum*. 1985 Jul;28(7):796–803.
- 11 Matsuda T, Ueda-Hayakawa I, Kambe N, Son Y, Ozaki Y, Hamaguchi Y, et al. Four cases of anti-Mi-2 antibody-positive dermatomyositis: relationship between anti-Mi-2 antibody titre and disease severity and activity. *J Eur Acad Dermatol Venereol*. 2018 Jun;32(6):e233–4.
- 12 Fiorentino DF, Chung LS, Christopher-Stine L, Zaba L, Li S, Mammen AL, et al. Most patients with cancer-associated dermatomyositis have antibodies to nuclear matrix protein NXP-2 or transcription intermediary factor 1γ. *Arthritis Rheum*. 2013 Nov;65(11):2954–62.
- 13 Rogers A, Chung L, Li S, Casciola-Rosen L, Fiorentino DF. Cutaneous and systemic findings associated with nuclear matrix protein 2 antibodies in adult dermatomyositis patients. *Arthritis Care Res (Hoboken)*. 2017 Dec;69(12):1909–14.

Ito et al.: A Case of Dermatomyositis Coexisting with Both Anti-Mi-2 and Anti-NXP-2 Antibodies

- 14 Sugie K, Tonomura Y, Ueno S. Characterization of dermatomyositis with coexistence of anti-Jo-1 and anti-SRP antibodies. *Intern Med.* 2012;51(7):799–802.
- 15 Vincze M, Molnár PA, Tumpek J, Szollosi L, Gyetvai A, Kapitány A, et al. An unusual association: anti-Jo1 and anti-SRP antibodies in the serum of a patient with polymyositis. *Clin Rheumatol.* 2010 Jul;29(7):811–4.
- 16 Akintayo RO, Agbola OF, Adeyemo AW, Adelowo O. Hyperacute muscle weakness in an unusual coexistence of antisignal recognition particle and anti-Mi-2 antibodies. *BMJ Case Rep.* 2017 Jul;2017:219221.

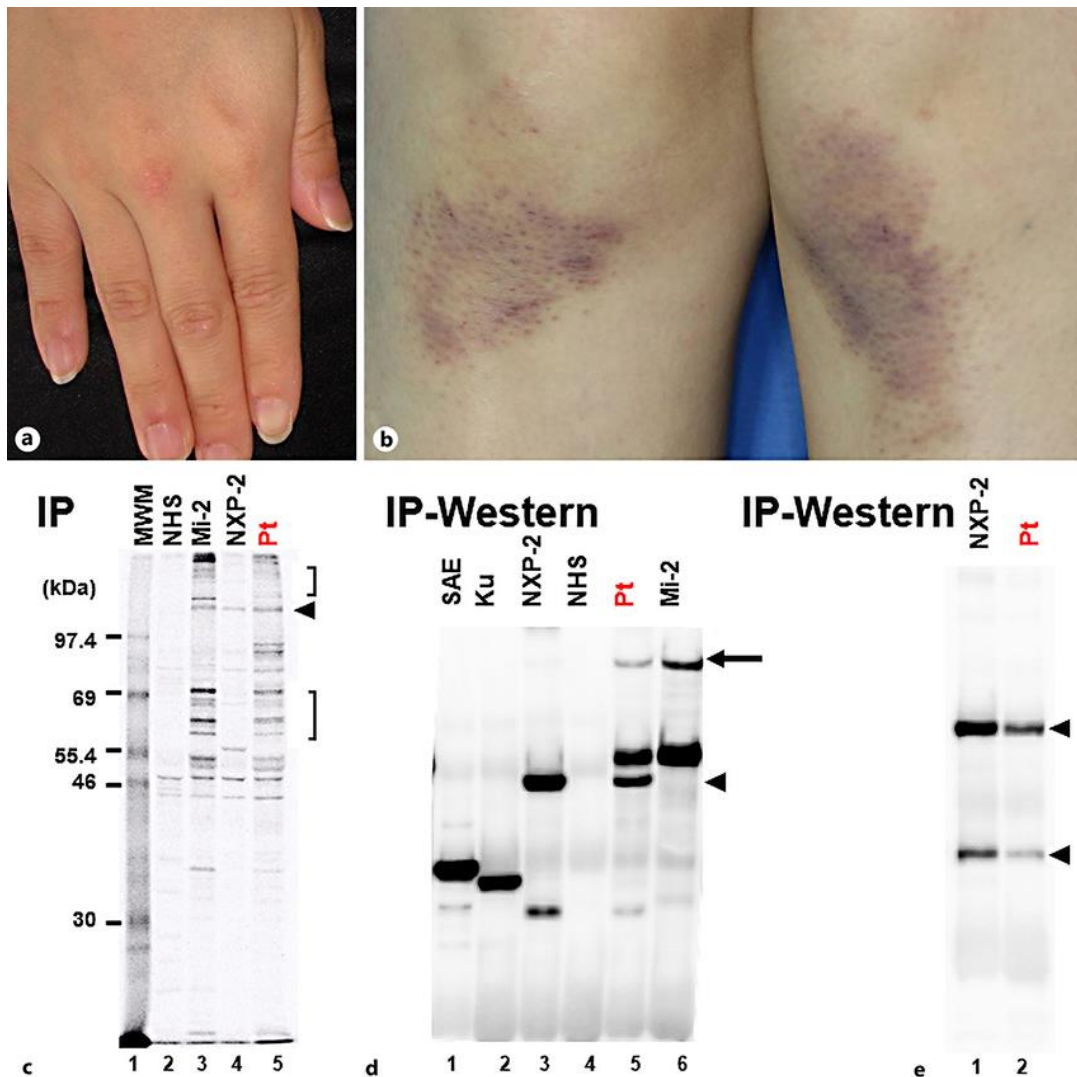


Fig. 1. Clinical features on the first consultation (**a**: dorsum of the right hand, **b**: bilateral knees), results of immunoprecipitation (IP) (**c**) and IP-Western assay (**d**, **e**). IP assays using ^{35}S -labeled extracts of K562 cells were performed. The patients' sera containing antibodies to Mi-2 or NXP-2 were used as reference sera. The patient's serum precipitated polypeptides of 200–240, 150, and 65–75 kDa that were identical to those precipitated by anti-Mi-2-positive reference serum. The patients' serum reacted with a 140-kDa protein, which corresponded to NXP-2 (arrowhead), and with 63- to 65-kDa proteins, which are presumed to correspond to Mi-2 (angle brackets). MWM, molecular weight markers; NHS, normal healthy serum; Pt, our patient's serum (**c**). Further IP-Western assays were conducted to identify the antigen of the 140-kDa protein. Immunoprecipitated materials were fractionated by SDS-PAGE and electrotransferred onto nitrocellulose membranes. After blocking, membranes were incubated with a mixture of commercially available polyclonal antibodies to human SAE, Ku, Mi-2, NXP-2, and TIF1- γ . The patients' sera containing antibodies to SAE, Ku, NXP-2 or Mi-2 were used as reference sera. Our patient's serum was positive for both anti-Mi-2 (arrow) and anti-NXP-2 (arrowhead) antibodies. SAE and Ku: patients' sera positive for anti-SAE and anti-Ku antibodies, respectively (**d**). IP-Western assay using commercially available polyclonal antibody to NXP-2 as the second antibody showed antibody to NXP-2 (arrowhead) in the patient's serum (**e**).