



Since January 2020 Elsevier has created a COVID-19 resource centre with free information in English and Mandarin on the novel coronavirus COVID-19. The COVID-19 resource centre is hosted on Elsevier Connect, the company's public news and information website.

Elsevier hereby grants permission to make all its COVID-19-related research that is available on the COVID-19 resource centre - including this research content - immediately available in PubMed Central and other publicly funded repositories, such as the WHO COVID database with rights for unrestricted research re-use and analyses in any form or by any means with acknowledgement of the original source. These permissions are granted for free by Elsevier for as long as the COVID-19 resource centre remains active.

Infections and foreign bodies in the ear, nose and throat

Andrew Norris

Julian Rowe-Jones

Infections of the ear, nose and throat are common and may threaten life. Intracranial complications may arise from infections of the ear and paranasal sinuses. Orbital complications (loss of vision) may arise from infection of the paranasal sinus. Respiratory embarrassment may result from infections of the upper aerodigestive tract.

The clinical presentation, implications and management of foreign bodies in the ear, nose and throat depend on the nature of the foreign body and the site at which it becomes lodged.

Infections

Ear

Perichondritis: infections of the soft tissues overlying the auricular cartilage occur as a result of:

- abrasions or lacerations
- inoculation after ear piercing
- local extension of poorly controlled otitis externa
- spontaneously in diabetic patients.
- an infective complication of an auricular haematoma caused by blunt trauma.

Patients with auricular perichondritis present with pain, erythema, induration and oedema of the auricle. Implicated organisms include *Pseudomonas aeruginosa*, *Staphylococcus aureus* and *Streptococcus pyogenes*.

Inflammation or separation of the perichondrium from the underlying cartilage can compromise its blood supply, resulting in cartilage necrosis and long-term auricular deformity unless prompt treatment is implemented.

Management – broad-spectrum antibiotic coverage (p.o., i.v.), usually incorporating fluoroquinolones for Gram-negative and Gram-positive bacteria, is essential. Pus or haematoma requires surgical drainage and obliteration of dead space with splinting to prevent cartilage necrosis.

Otitis externa: infections of the soft tissues of the ear canal are acute or chronic; they may be:

- bacterial; which is the most common (*Staphylococcus aureus*, *Pseudomonas aeruginosa*, *Proteus*, *Escherichia coli*)
- fungal (*Aspergillus niger*, *Candida albicans*, *Actinomyces*)
- viral (*Herpes simplex*, *Herpes zoster*).

Andrew Norris FRCS is a Specialist Registrar in Surgery of the Ear, Nose and Throat at St George's Hospital, London, UK.

Julian Rowe-Jones FRCS FRCS(Orl) is a Consultant Rhinologist and Ear, Nose and Throat Surgeon at Royal Surrey County Hospital, Guildford, UK.

Processes that breach the integrity of the skin of the ear canal are likely to cause otitis externa e.g. eczematous skin conditions, trauma (e.g. insertion of cotton buds, fingernails, earplugs, hearing aids). Moisture in the ear canal from swimming or humid environments provides excellent conditions for infection to become established. Patients with otitis externa may present with:

- pruritus
- pain (otalgia)
- reduced patency of the ear canal due to oedema
- ear discharge (otorrhoea)
- conductive hearing loss
- pre- or post-auricular enlargement of the lymph nodes
- fever.

Signs and symptoms vary depending on the class of causal pathogen and the nature of presentation (acute or chronic).

Management – analgesia is indicated. Microbiology of ear discharge should be taken; serial aural toilet with suction under direct vision with a microscope should be done and the tympanic membrane should be seen. If the ear canal is closed, dressings that facilitate the passage of topical medications from lateral to medial canal across the narrowed segment (e.g. otowick) can be inserted. Topical antibiotics (aminoglycoside or quinolone preparations with or without corticosteroid) or antifungal drops (clotrimazole) should be used according to the suspected pathogen. The choice of preparation may be revised after information from microbiology swabs is obtained. Adjuvant antibiotic/antifungal treatment (p.o., i.v.) should be started in patients with severe otitis externa with associated auricular perichondritis, employing agents suitable for eradication of Gram-negative and Gram-positive bacteria (e.g. augmentin, cephalosporin, fluoroquinolone).

Necrotizing otitis externa: elderly, immunocompromised or diabetic patients may occasionally develop this potentially lethal condition as a complication of otitis externa. They present with persistent, deep-seated continuous otalgia and symptoms of refractory otitis externa. It is usually due to by infection by *Pseudomonas aeruginosa*, causing a necrotizing vasculitis and subsequent destructive osteomyelitis of bone adjacent to the external auditory canal. Unchecked, the infection may pass through Santorini's fissures to the temporal bone, leading to a facial nerve palsy. The disease may progress across the bone of the skull base to the jugular foramen and hypoglossal canal, resulting in palsies of the ninth, tenth, eleventh and twelfth cranial nerves.

Management is identical to treatment of otitis externa, but high-dose antibiotics (i.v.), including gentamicin, metronidazole or fluoroquinolones, are used. Aggressive control of diabetes is required. Additional hyperbaric oxygen therapy may be utilized and surgical debridement should be considered. Despite treatment, mortality associated with this condition is 23–37%, but rises to 60% if multiple cranial nerve palsies are present.

Otitis media and mastoiditis: otitis media predominantly occurs in children aged ≥ 5 years, particularly in those with craniofacial abnormalities (e.g. cleft palate; see [Mosahebi](#), [CROSS REFERENCE](#)). There is usually a history of an antecedent viral infection of the upper respiratory tract that causes congestion of the respiratory mucosa and obstruction of the isthmus of the Eustachian

tube. Negative middle-ear pressure results and an effusion develops in the middle ear. The effusion may become colonized with bacteria (*Streptococcus pneumoniae*, *Haemophilus influenzae*, *Moraxella catarrhalis*, group A β -haemolytic streptococcus, *Staphylococcus aureus*) from local or haematogenous spread, resulting in acute otitis media. Increased hydrostatic pressure in the middle ear and enzymatic activity may cause rupture of the tympanic membrane and mucopurulent otorrhoea. Infection may extend from the middle ear through the aditus into the mastoid antrum (resulting in mastoiditis), or into the inner ear (resulting in labyrinthitis). In mastoiditis, bony septa of the mastoid air cells are destroyed and an abscess forms. Osteomyelitis of the temporal bone may occur via emissary vessels or direct local spread. Laterally, this may result in a subperiosteal abscess of the mastoid bone which occasionally spreads to the zygomatic arch or along the fascia of muscles attached to the mastoid, resulting in a lateral neck abscess ('Bezold's mastoiditis'). Occasionally, medial/superior spread of a temporal bone osteomyelitis results in intracranial complications such as:

- sigmoid sinus thrombosis
- subdural empyema
- meningitis
- brain abscess (Figure 1).

Bacterial labyrinthitis may result in a complete loss of hearing or 'dead' ear. The clinical symptoms and signs of otitis media are otalgia, pyrexia, hearing loss (conductive) and otorrhoea. Mastoiditis causes a fluctuant, erythematous retroauricular mass that arises over the mastoid creating a protuberant auricle; labyrinthitis results in vertigo.

Management - uncomplicated otitis media is treated with insertion of ventilation tubes. Bacterial infections are treated with antibiotics (p.o.), topical antibiotic ear drops and nasal decongestants in the early stages. Prolonged use of aminoglycoside drops in a tympanic perforation should be avoided because of the risks of ototoxicity; topical fluoroquinolones are safe. Otitis media complicated by mastoiditis requires hospital admission,

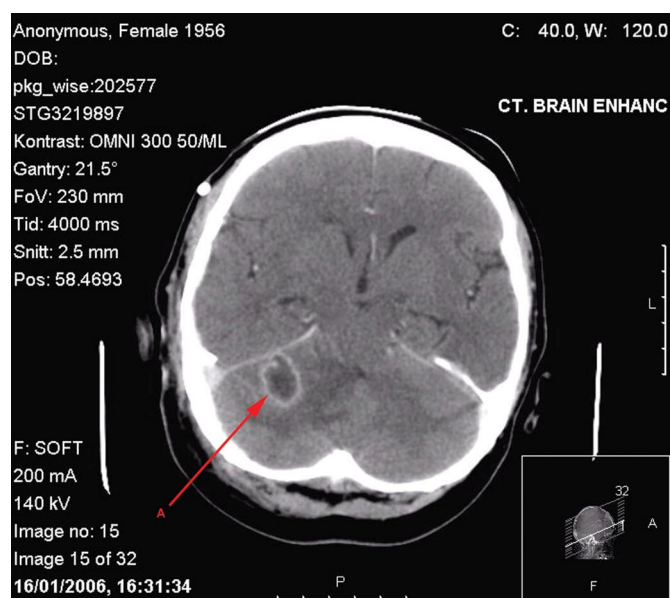


Figure 1 Intracerebellar abscess (marked A) secondary to mastoid infection.

broad-spectrum antibiotics (i.v.) and incision and drainage of a mastoid abscess with a cortical mastoidectomy and tympanic insertion of a ventilation tube if a tympanic membrane perforation is absent.

Nose

Nasal furunculosis: infection of a hair follicle with *Staphylococcus aureus* results in a painful, throbbing, erythematous swelling of the nasal tip and alar margins. Patients' attempts at squeezing the swelling can result in cavernous sinus thrombosis via a spreading thrombophlebitis of the angular and ophthalmic veins. Other complications include abscess formation and chondritis of nasal cartilages.

Management is administration of anti-staphylococcal antibiotics (p.o., i.v.) depending on severity. Surgical incision and drainage may be required.

Rhinosinusitis: in a typical coryzal illness, the nose and sinuses become infected with viral pathogens such as rhinovirus, coronavirus, parainfluenza virus or adenovirus. This infection results in inflammation, oedema of the nasal and sinus mucosa and impaired nasociliary function. The sinus ostia can be regarded as rigid, fixed diameter drainage/ventilation tubes with an inner lining of mucosa. Swelling of this mucosa causes reduced patency of the ostia and results in impaired ventilation and mucous drainage from the maxillary, ethmoid, frontal and sphenoid sinuses. Stasis of mucus in the sinuses provides the opportunity for secondary bacterial colonization. In acute bacterial sinusitis, the usual causal pathogens are *Streptococcus pneumoniae*, *Haemophilus influenzae*, *Moraxella catarrhalis* and *Streptococcus pyogenes*. Other pathogens (e.g. anaerobic bacteria and fungi) may be implicated in chronic sinusitis or in immunocompromised or allergic patients. Secondary infection and attendant mucosal inflammation compound impaired ventilation or drainage of sinuses. The symptoms of rhinosinusitis include:

- pyrexia
- mucopurulent nasal discharge
- headaches
- sinus pressure.

As with a mastoid abscess, a wave of inflammation and infection may spread from the infected sinus directly into adjacent bone (creating an osteomyelitis) through fissures or vasculature into adjacent structures and tissues.

Orbital cellulitis: the ethmoid and frontal sinuses have close anatomical relationships to the orbit and brain; thus infection of the ethmoidal sinus may breach the thin lamina papyracea (particularly in children), giving rise to a subperiosteal orbital abscess i.e. orbital cellulitis. A puffy erythematous upper eyelid may be present in the initial clinical stages. As the inflammation spreads through the orbit, the orbital tissues become oedematous, resulting in:

- ocular proptosis
- pain
- ophthalmoplegia
- conjunctival oedema
- changes in the lower lid (Figure 2).

The increased intra-orbital pressure may stretch the optic nerve and, directly from pressure or by vasculitis, the blood supply

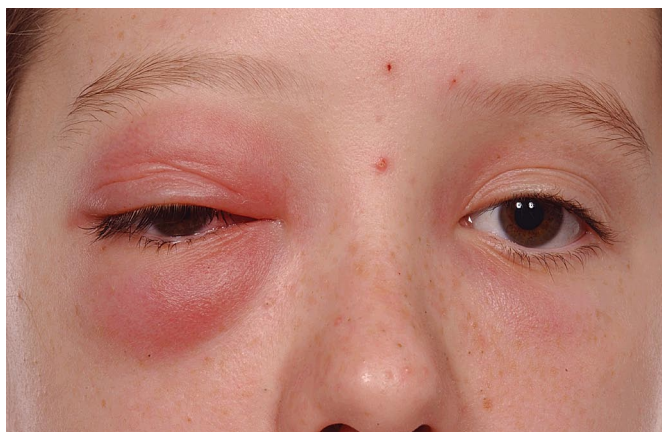

Figure 2 Right orbital cellulitis secondary to sinus infection.

to the nerve may be compromised, resulting in blindness. A loss of colour vision is an ominous portent. The risk of blindness increases dramatically if pus breaches the periosteum and becomes intra-orbital.

Pus in the frontal sinus may result in abscess formation in adjacent tissues. In most cases, osteomyelitis of the anterior table of the frontal sinus may occur, resulting in a subperiosteal forehead abscess ('Pott's puffy tumour'). Osteomyelitis of the posterior table of the frontal sinus may occur and result in intracranial complications (e.g. extradural abscess, meningitis, abscess of the frontal lobe of the brain). Apart from the general symptoms of sinusitis, such patients may initially present with signs of meningism, hemiparesis or fits.

Management – patients with clinical signs of orbital cellulitis or frontal sinus complications require high-dose, broad-spectrum antibiotics (e.g. cefotaxime i.v.) and nasal decongestants. Controversy surrounds the administration of corticosteroids (i.v.) to reduce intra-orbital swelling, with critics citing risk of infection exacerbation as a contraindication. In both instances, urgent CT with coronal and axial views (cuts must be sufficiently rostral to display intracranial disease) is required. Incipient visual loss is arrested by relief of intra-orbital pressure through remedial procedures (e.g. lateral canthotomy) and should not be delayed by CT acquisition (Figure 3). CT findings:

- confirm diagnosis
- display local anatomy and extension of disease
- permit planning of surgery.

The aim of surgery is to drain collections of pus from intra- and extra-sinus locations and to restore patency of the sinus ostia, allowing restoration of ventilation and drainage. These aims may be achieved through endoscopic endonasal, external transfacial or a combination of the two approaches.

Throat

Infections of the oral cavity, pharyngeal and neck space: the mucosal surfaces of the oropharynx are anatomically related to myriad complex neck structures (e.g. muscles, nerves, blood vessels, bone). These structures are contained in compartments encased by fascia. Potential spaces exist between these compartments and these are named according to their anatomical sites (e.g. sublingual, submandibular, parapharyngeal, pretracheal, carotid and retropharyngeal spaces). They are known collectively

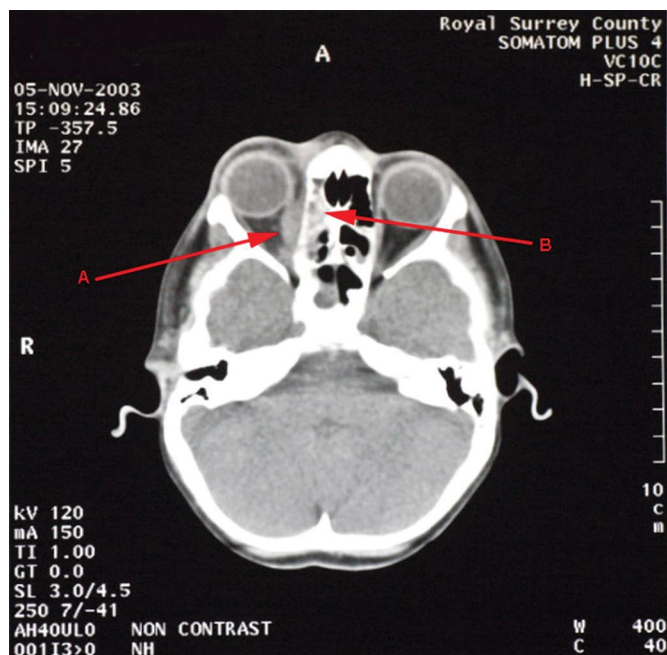


Figure 3 CT (axial view) through orbit and paranasal sinuses. **A** shows subperiosteal abscess of medial right orbit secondary to infection in **B** the adjacent ethmoid sinus.

as the 'deep neck spaces', and they are contiguous, having real and potential avenues of communication with one another. Infection in one space may spread to an adjacent space, gaining access to enlarging portions of the neck and eventually extending distally into areas outside the neck (e.g. mediastinum), resulting in considerable morbidity or potential mortality.

The following may result in infection that spreads directly from the mucosa of the upper aerodigestive tract into the neck spaces:

- dental infections
- acute tonsillitis
- peritonsillar abscess
- pharyngeal infection
- salivary gland infections (see 'Pathology and treatment of salivary gland conditions', page 304)
- oral surgical procedures
- ingested sharp foreign bodies (e.g. animal bones).

Suppuration of enlarged nodes found in these spaces, as part of a generalized cervical lymphadenopathy, is an alternative route for infection of deep neck spaces. The organisms responsible for upper aerodigestive infections are aerobic and anaerobic, Gram-positive and Gram-negative. They include:

- group A β -haemolytic streptococcal species (*Streptococcus pyogenes*)
- α -haemolytic streptococcal species (*Streptococcus pneumoniae*, *Streptococcus viridans*)
- mixed oral flora (*Staphylococcus aureus*, *Haemophilus influenzae*, *Neisseria* spp, *Fusobacterium* spp, bacteroides).

The clinical symptoms and signs of infections of the upper aerodigestive tract depend on site of origin, and the extent and path taken by the spreading infection. Initial features are pain, fever and dysphagia. Inflammation in muscles may result in trismus (pterygoids) or torticollis (paraspinal muscles). Patients

who develop neck space infections may have a palpable, tender, brawny swelling of the neck with erythema of the overlying skin. Neural deficits may occur as inflammation spreads into the contents of neighbouring fascial compartments (e.g. hoarse voice from true vocal cord palsy indicating involvement of the carotid sheath; vagal inflammation or Horner's syndrome indicating involvement of the cervical sympathetic chain). A regular spiking fever may suggest internal jugular thrombophlebitis. Neck space infection mass effect creates oropharyngeal asymmetry, while the associated inflammation creates significant oropharyngeal mucosal oedema. The combination of mass effect and oedema can lead to a reduction in airway patency. Respiratory difficulty may ensue: tachypnoea, drooling and stertor are signs of impending airway obstruction and respiratory arrest.

Management – patients unable to maintain oral hydration require analgesia, intravenous fluid resuscitation and broad-spectrum antibiotics (i.v.; to cover Gram-positive and Gram-negative, aerobic and anaerobic bacteria). The airway must be addressed immediately if signs of compromise are present. Examination may precipitate an airway crisis and staff competent to secure an airway should be present. Endotracheal and nasotracheal intubation may not be possible and tracheostomy under local anaesthesia may be essential before further assessment and treatment is implemented. Patients with suspected neck space infections should undergo CT with contrast once a secure airway has been established. Abscesses are seen as low-density lesions with rim enhancement (Figure 4).

Small infections of the deep neck space without respiratory compromise may respond to a trial of antibiotics (i.v.). Incision and drainage remains the cornerstone of treatment of larger abscesses and may be done transorally (e.g. peritonsillar, retropharyngeal) or, in most cases, transcervically. There are many transcervical approaches to the deep neck spaces, the description of which is beyond the scope of this review. All require adequate exposure to facilitate identification and protection of neurovascular structures. Drained pus should be cultured; the

cavity should be debrided, irrigated and a drain left *in situ* to prevent reaccumulation.

Laryngeal infections can be defined in terms of their relationship to the vocal cords (glottis) as supraglottic, glottic and subglottic; they are called epiglottitis, laryngitis and laryngo-tracheobronchitis (croup), respectively. Apart from epiglottitis, all are primarily caused by viral pathogens (parainfluenza virus, rhinovirus, adenovirus, respiratory syncytial virus). Epiglottitis is primarily caused by *Haemophilus influenzae* type B. The clinical presentation of laryngeal infections is determined by the degree and level of mucosal oedema. All present with fever. Patients with epiglottitis present with inspiratory stridor, dysphagia and drooling. Those with laryngitis have hoarseness or aphonia; patients with laryngo-tracheobronchitis have a barking cough, biphasic stridor and evidence of use of accessory respiratory musculature. The symptoms of laryngo-tracheobronchitis may rapidly worsen due to secondary bacterial infection.

Management – an assessment of the airway with a flexible nasendoscope can be made, but extreme caution is required in suspected epiglottitis. Examination may precipitate complete obstruction of the airway and should not be undertaken unless specialists competent to secure an airway (endotracheal or surgical) are present. Humidified oxygen, racemic (nebulized) adrenaline, intravenous fluid resuscitation, broad-spectrum antibiotics and corticosteroids are the mainstays of treatment.

Foreign bodies

Foreign bodies may be purposefully or inadvertently inserted into the ear and nose, or aspirated or ingested into the aerodigestive tract. Most foreign bodies are found in children, but oesophageal foreign bodies (animal bones, dental prosthetics) commonly occur in adults.

Foreign bodies can be divided into organic (vegetable matter such as seeds, nuts, raisins; fomites such as tissue paper, cotton buds, pieces of sponge) and inorganic (e.g. beads, parts of toys, coins, batteries). Organic foreign bodies can produce intense inflammatory reactions in mucosal surfaces; they are often associated with a secondary infection when found in the ear. In contrast to inorganic foreign bodies, organic foreign bodies in the ear, nose and throat may require more treatment than simple removal. Batteries deserve special mention; contact with moisture on mucosal surfaces creates the potential for current leakage and hydroxide formation that can result in significant damage to tissue. They therefore require emergency removal.

Ear

Patients may present acutely due to irritation (e.g. insects), pain associated with trauma (to canal wall or tympanic membrane) or in children because the parents have witnessed the insertion. Late presentations are because of hearing loss, otorrhoea or an incidental finding on otoscopy.

Management – insects should be drowned in olive oil or surgical spirit. Foreign bodies should be removed under direct vision with a microscope using crocodile forceps, wax hooks, Zoellner suction or a combination of the above. The tympanic membrane should be inspected for damage after the object has been removed. Associated discharge should be cultured and empirical treatment is with antibiotic drops. In general, removal procedures may be

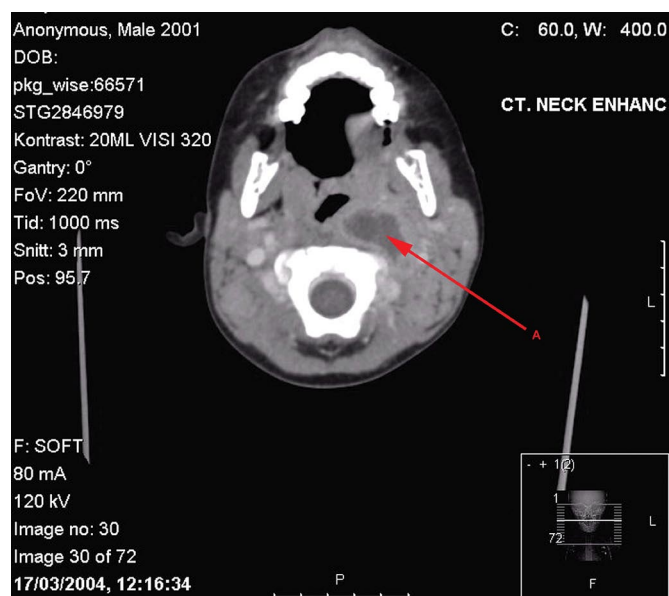

Figure 4 CT (axial view) of A para/retropharyngeal abscess secondary to dental infection.

done electively if infection is present. Removal may necessitate general anaesthesia in children.

Nose

Children typically present soon after insertion is witnessed. Delayed presentation may be due to a unilateral nasal discharge that occurs if a foreign body has been present for a few days. Late presentation may occur in adults, many years after insertion. In these cases, calcium becomes deposited around the foreign body, forming a rhinolith that may produce sinusitis or nasal obstruction. Intranasal foreign bodies may be found anywhere in the nose, but typically lodge at the nasal valve between the septum and the anterior edge of the inferior turbinate.

Management – timely removal is required because of the risk of tracheobronchial aspiration. Removal requires a cooperative child, an excellent headlight, appropriate equipment and topical vasoconstrictive anaesthesia (e.g. cocaine). Objects may be removed with wax hooks, crocodile forceps, suction or balloon catheters. Instruments are passed beyond the object, which is then swept forward out of the nose. In general, children tolerate only one attempt at removal, general anaesthesia may be required after this. Batteries require urgent removal to prevent septal perforation. Patients with a history of discharge or battery insertion should be given antibiotic nasal creams (e.g. naseptin) to use after removal of the foreign body.

Airway

Aspirated foreign bodies come to rest in the larynx, trachea or bronchi and can result in considerable morbidity and mortality. Clinical presentation occurs in three phases: an acute choking phase, an asymptomatic phase and a complication phase. The presentation depends on the size, shape and level at which the object comes to rest:

- large objects impact proximally
- round or expandable objects tend to result in complete obstruction
- irregular objects may permit airflow around them, creating partial obstruction.

Also:

- laryngeal foreign bodies produce airway obstruction and hoarseness
- tracheal foreign bodies produce airway obstruction without hoarseness
- irregular objects may permit airflow around them, creating partial obstruction of the airway.

Management – patients with complete obstruction of the airway require immediate attention (e.g. Heimlich manoeuvre). Most who reach hospital are beyond the acute stage, but may benefit from supportive oxygen therapy. Nasendoscopy and anteroposterior and lateral radiographs of the chest may aid diagnosis with respect to level of impaction. Removal of the

foreign body is facilitated by a flexible bronchoscope under sedation or, more commonly, with the rigid ventilating bronchoscope under general anaesthesia. With the latter, objects and secretions are removed with a combination of forceps and suction using techniques to minimize mucosal trauma. Tracheostomy or thoracotomy may be required (rare).

Pharynx and oesophagus

Sharp foreign bodies (e.g. animal bones) may penetrate and become lodged anywhere in the mucosa of the oropharynx and oesophagus. Most large foreign bodies such as coins (in children) and soft food boluses or dental prostheses lodge in the proximal oesophagus at the level of the C6 vertebra, a narrow area created by the cricopharyngeus muscle. They may also lodge more distally at sites of abnormal narrowing (e.g. strictures). Sharp objects result in pain, dysphagia and drooling. Large foreign bodies in the oesophagus present with dysphagia and discomfort, and may result in varying degrees of respiratory compromise due to mass effect.

Management – oropharyngeal and nasendoscopic examination reveals the location of foreign bodies above the level of cricopharyngeus and evidence of salivary pooling indicates more distal impaction. The most common oesophageal foreign bodies, coins, are shown readily on chest radiographs. Not all bones are radio-opaque, but certain signs on lateral neck soft tissue radiographs are indicative of foreign bodies (e.g. loss of cervical lordosis, thickening of prevertebral tissues, air in oesophagus). Bones lodged proximally in the mucosa of the tonsil, pharyngeal wall or tongue base may be removed under topical anaesthesia using a tongue depressor or laryngoscope blade and grasping forceps. Those lodged in cricopharyngeus or the oesophagus require removal under general anaesthesia with a rigid oesophagoscope; coins or dental prosthetics require the same method of removal. Sharp objects are drawn into the lumen of an advancing endoscope, and endoscope and foreign body are removed together to prevent mucosal trauma. Oral intake may be restricted to sterile fluids initially if small mucosal lacerations are present. More significant trauma may necessitate the placement of a nasogastric tube and a 'drip and suck' approach. Oesophageal perforation is a serious complication that carries a risk of mediastinitis.

In general, soft food boluses will pass with conservative management i.e. muscle relaxants (e.g. buscopan) and fizzy drinks. A persistent proximal soft food bolus or one that is causing respiratory symptoms may be removed or pushed distally under general anaesthesia using a rigid oesophagoscope. Distal boluses should be referred to a gastroenterologist for flexible endoscopy. ◆

CROSS REFERENCE

Mosahebi A, Kangesu L. Cleft lip and palate. *Surgery* 2006; **24(1)**: 33–7.