

## Ocular manifestation of rickettsial disease in South Indian population

Sunil Ganekal, Kruthika Singnal, Suresha Rajappa, Sharat Hegde<sup>1</sup>

**Purpose:** The aim of this work was to study the ocular manifestations and its management in spotted fever and typhus group of rickettsial disease. **Methods:** A retrospective analysis of 50 patients with serologically confirmed Rickettsial disease. In all patients, relevant history, investigations and treatment details were collected and they underwent complete ophthalmic evaluation including measurement of best-corrected visual acuity, anterior segment examination and dilated fundus examination. **Results:** Mean age was  $12.5 \pm 8.99$  years. Of the 50 patients, 40 patients were  $\leq 18$  years of age and 27 (54%) had ocular involvement. Out of 27 patients, bilateral involvement was seen in 10 patients. Most of the patients had no ocular symptoms. Ocular findings included, Retinal vasculitis 6 (22.22%); macular edema 4 (14.81%); vasculitis with macular edema 1 (3.7%); Retinitis 7 (25.92%); Papilloedema 6 (22.22%); Papilloedema with 6<sup>th</sup> cranial nerve palsy 1 (3.7%); Isolated 6<sup>th</sup> cranial nerve palsy 1 (3.7%) and optic neuritis 1 (3.7%). Ocular involvement was more common in double antigen group (68%) than spotted fever group (50%) or Scrub typhus group (21%) ( $P = 0.01$ ). Ocular involvement was seen in 94% of the patients with CNS involvement. Cases with bilateral involvement ( $P = 0.01$ ), pediatric age group ( $P = 0.01$ ) and CNS involvement ( $P = 0.02$ ) had poor visual outcome. **Conclusion:** Rickettsioses patients can have ocular manifestations with predominant posterior segment involvement during acute phase of illness. Ocular involvement was more common in the double antigen group. For any patient who presents with fever and rash living in endemic area, ophthalmic evaluation should be part of routine checkup during the acute phase of illness associated with less frequent ocular symptoms.

**Key words:** Ocular manifestations, rickettsial disease

Rickettsial zoonoses are infections caused by obligate intracellular gram-negative bacteria. Most of these infections are transmitted by the bite of infected arthropods, such as ticks and mites. Rickettsial organisms are known to invade small blood vessels causing endothelial injury and tissue necrosis, with subsequent development of host mononuclear-cell tissue response and stimulation of coagulation process, resulting in a systemic edematous and occlusive vasculitis.<sup>[1]</sup>

Three major categories of rickettsial agents are as follows the spotted fever group, the typhus group and the scrub typhus.<sup>[1]</sup> In early course of rickettsial disease treatment is highly effective, but diagnosis is extremely difficult due to non-specificity of signs and symptoms, low index of suspicion and absence of rapid, low cost and widely available diagnostic test. Usually diagnosis of rickettsial disease is based on clinical features and confirmation by positive serologic testing. Polymerase chain reaction (PCR) and Immunofluorescence assay (IFA) are not commonly available in countries like India, so properly performed paired serological tests like Weil–Felix and ELISA have high positive predictive value. Weil–Felix test is useful and it's a cheap diagnostic tool for laboratory diagnosis of rickettsial disease.<sup>[2]</sup>

Systemic involvement is characterized by triad of high fever, skin rash and general malaise associated with headache. At

Department of Ophthalmology, JJM Medical College, Davanagere, Prasad Netralaya, Udupi, Karnataka, India

**Correspondence to:** Dr. Sunil Ganekal, Department of Ophthalmology, JJM Medical College, Davanagere - 577 004, Karnataka, India. E-mail: drgsunil@yahoo.com

Received: 23-Aug-2020

Revision: 20-Oct-2020

Accepted: 25-Oct-2020

Published: 30-Apr-2021

the site of tick or mite bite, many rickettsioses are associated with maculopapular, vesicular or petechial rash or sometimes an eschar. Common symptoms develop within 1-2 weeks of infection; however, clinical presentations may vary with the causative agent and patient. Most of the patients with rickettsioses are commonly associated with ocular involvement and they will be asymptomatic with self-limited course, hence may be easily overlooked.<sup>[3,4]</sup> But many patients with ocular disease may have associated ocular complaints, such as decreased vision, redness, floaters or scotomas. Ocular findings in rickettsial disease include conjunctivitis, keratitis, anterior uveitis, panuveitis, retinal vascular changes, retinitis and optic nerve involvement. But the posterior segment findings like retinitis, retinal vascular involvement and optic disc changes are the most common ocular findings. Even though ocular involvement associated with rickettsial infection has a self-limited course, but can result in persistent visual impairment.

Though rickettsial disease is common, there is paucity of reports of ocular manifestations in rickettsia. Moreover, rickettsial sub-types and their ocular involvement have not been studied. We report ocular manifestations, treatment

This is an open access journal, and articles are distributed under the terms of the Creative Commons Attribution-NonCommercial-ShareAlike 4.0 License, which allows others to remix, tweak, and build upon the work non-commercially, as long as appropriate credit is given and the new creations are licensed under the identical terms.

**For reprints contact:** WKHLRPMedknow\_reprints@wolterskluwer.com

**Cite this article as:** Ganekal S, Singnal K, Rajappa S, Hegde S. Ocular manifestation of rickettsial disease in South Indian population. Indian J Ophthalmol 2021;69:1167-71.

Access this article online

Website:

www.ijo.in

DOI:

10.4103/ijo.IJO\_2748\_20

Quick Response Code:



given, and visual outcome in patients with systemic rickettsial disease who attended our tertiary eye care center. To the best of our knowledge, this is the first incidence of study on ocular manifestations in various subtypes of rickettsiosis involving large pediatric population (40/50; 80%) being reported as a cluster from south India.

## Methods

A retrospective analysis of 50 patients with Rickettsial disease, screened in the pediatric and adult emergency medical wards of general hospital from June 2016 to June 2019. Study was approved by the Institutional review board. All patients with the clinical signs suggestive of rickettsial disease with Weil–Felix test positive (titer > 1:80) were included in the study. Serologically negative cases were excluded from the study. The demographic profile of serologically proven cases of rickettsial disease was collected. In all patients' detailed history, details of systemic examination, investigations and treatment details were collected. All patients had a negative serology for parasitic (Toxoplasmosis, Toxocariasis, DUSN), bacterial (Typhoid, Bartonellosis, Brucellosis, Borreliosis, Syphilis) and viral disease (HSV, VZV, CMV, Epstein Barr Virus, Chikungunya, Dengue, Measles, HIV, Rubella) simulating retinitis. Rickettsial sub-classification and Weil–Felix test interpretation was done according to Table 1.

Visual acuity was assessed at bedside for bedridden patients. For ambulatory patients, visual acuity was assessed with and without correction using Snellen's chart. Thorough pupillary examination was carried out for pupillary reactions. Patient was assessed for ocular alignment and extraocular movements. Extraocular movements assessed were ductions, versions, convergence, saccades and pursuits. Anterior segment examination was done by bright flash light or slit lamp depending upon the status of the patient. Dilated fundus examination was done using slit-lamp biomicroscopy and indirect ophthalmoscopy. Serial follow-up examination was performed in patients with posterior segment eye changes. Intraocular pressure was recorded using Goldmann applanation tonometer/Rebound tonometer wherever necessary. FFA and OCT examination was done in relevant cases and cooperative children. Diplopia charting was done whenever the patient complains of diplopia. Any ocular manifestation which required treatment was treated as per standard medical practices.

Statistical analysis was done using IBM SPSS version 20 for Windows. Qualitative data was represented in the form of frequency and percentage. Age as quantitative data was represented using mean & SD. Multifactorial logistic regression

was done for associated risk factors. Association between qualitative variables was assessed by Chi-square test with continuity correction for 2 × 2 tables and Fisher's exact test for all 2 × 2 tables where *P* value of Chi-square test was not valid due to small counts. Adjacent row data of more than 2 × 2 tables was pooled and Chi-square test reapplied in case of more than 20% cells having expected count less than 5.

## Results

Mean age was 12.5 ± 8.99 years (range 6–48 years). The total number of patients studied was 50. Of which, 27 were males (54%) and 23 were females (46%). Forty patients (80%) were ≤18 years of age. Among 50 patients, 26 patients had systemic findings. Among them 6 (23.07%) had hepatomegaly; 3 (11.53%) had hepatosplenomegaly; 1 (3.85%) had splenomegaly; 8 (30.77%) had encephalitis; 6 (23.07%) had meningitis; 1 (3.85%) had meningoencephalitis and 1 (3.85%) had multiple organ involvement.

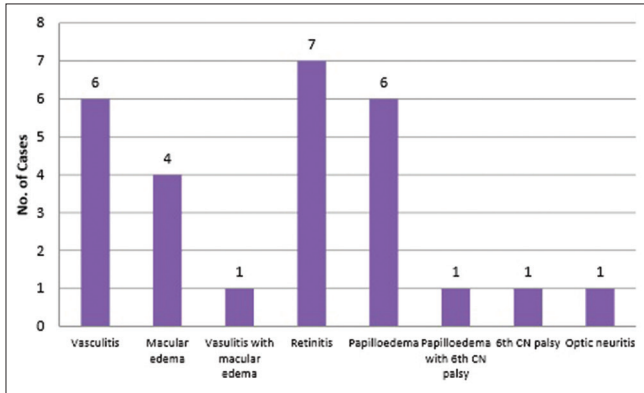
Two patients (4%) were positive to OX 2 only; 14 (28%) patients were positive for OX K only; 29 (58%) patients were positive for OX 19 and OX 2; 4 (8%) patients were positive for both OX 2 and OX K, and 1 (2%) patient was positive for both OXK and OX19. Single antigen positivity was seen in 16 (32%) patients and the remaining 34 (68%) patients were positive for two antigens (Double antigen group). Best-corrected visual acuity (BCVA) ranged from 1/60 to 6/6. On presentation those with CNS involvement, pediatric age group and bilateral involvement had poor vision, but was not statistically significant (*p* > 0.05). Thirty-nine patients (78%) had normal vision, 6 (12%) had decreased vision and for 5 (10%) patients vision could not be assessed due to poor systemic status and CNS involvement. Thirty-seven eyes of twenty-seven patients (54%) had ocular manifestations. Seventeen (63%) patients had unilateral ocular involvement and 10 patients (37%) had bilateral involvement. Ocular findings in these patients included, retinal vasculitis in 6 (22.22%); macular edema in 4 (14.81%); vasculitis with macular edema in 1 (3.7%); Retinitis in 7 (25.92%); papilloedema in 6 (22.22%); papilloedema with 6<sup>th</sup> cranial nerve palsy in 1 (3.7%); Isolated 6<sup>th</sup> cranial nerve palsy in 1 (3.7%) and optic neuritis in 1 (3.7%) [Fig. 1]. Central nervous system involvement was seen in 16 cases, out of which 15 (94%) had ocular findings. Other systems were involved in 10 cases, out of which 5 (50%) had ocular findings. Final visual outcome in cases with bilateral involvement (*P* = 0.011, OR = 0.48979), CNS involvement (*P* = 0.019, OR = 0.61342), pediatric age group (*P* = 0.021, OR = 0.67854) and Double antigen (*P* = 0.02, OR = 0.71234) had poor visual outcome. Sub analysis of final visual outcome in the pediatric age group showed that age group ≤10 years (54%) had poor visual outcome compared to those between 10–18 years (46%), but was not statistically significant (*P* > 0.05).

Two cases of spotted fever group and 14 cases of scrub typhus group had normal vision. In Double antigen group, out of 34 cases; 23 (68%) had normal vision; 6 (17%) had decreased vision and 5 (15%) cases vision could not assess due to poor systemic status. Ocular manifestations were seen in 1 spotted fever, 3 scrub typhus and 23 double antigen group patients [Fig. 2]. Ocular involvement was more common in double antigen group (68%) than spotted fever group (50%) or Scrub typhus group (21%) (*P* = 0.011). Among the patients

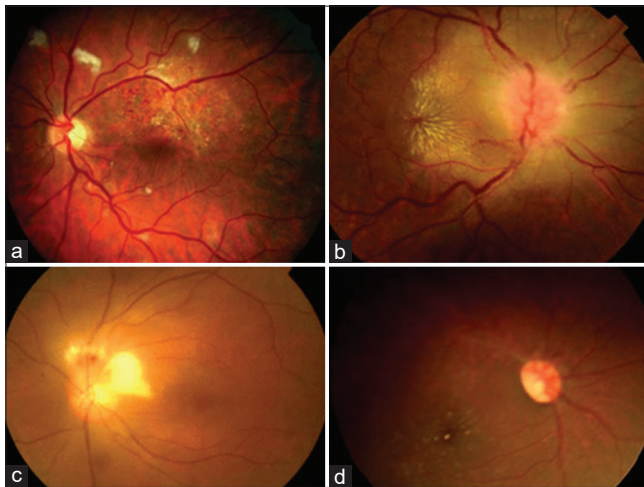
**Table 1: Weil-Felix test (WFT) interpretation**

	OX 19	OX 2	OX K
Epidemic typhus	++++	+	0
Brill Zinsser disease	++++	+	0
Murine typhus	++++	+	0
Scrub typhus	0	0	+++
Rocky mountain spotted fever	++++	+	0
Other tick borne typhus	+	++++	0
Indian tick typhus	+	++++	0

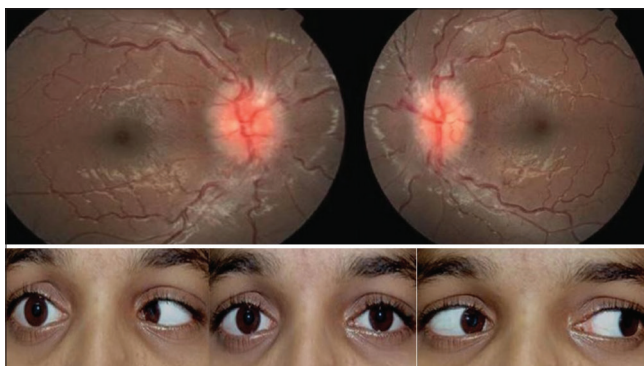
who had ocular manifestations, in spotted fever group, 1 patient (100%) had papilloedema .In Scrub typhus group, 1 patient (33.33%) had retinal vasculitis; 1 (33.33%) patient had Retinitis; 1 (33.33%) patient had 6<sup>th</sup> CN palsy. In double antigen group, 23 patients had ocular manifestations, among them 5 (22%) patients had vasculitis; 4 (18%) had macular edema; 1 (4%) had vasculitis with macular edema; 6 (26%) had retinitis; 5 (22%) had papilloedema; 1 (4%) had papilloedema with 6<sup>th</sup> CN palsy [Fig. 3]; 1 (4%) had 6<sup>th</sup> CN palsy and 1 (4%) had optic



**Figure 1:** Distribution of patients according to ocular manifestations



**Figure 2:** Posterior segment manifestations of Rickettsia; (a) Multifocal Retinitis; (b) Neuroretinitis with macular edema; (c) Juxtapapillary retinitis with hemorrhage, (d) Retinal vasculitis with macular edema



**Figure 3:** Papilloedema with sixth cranial nerve palsy

neuritis. In patients with CNS involvement, neuroimaging in the form of CT scan or MRI was done and it showed features of encephalitis in eight patients, meningitis in six patients and meningoencephalitis in one patient. Fundus fluorescein angiography (FFA) in posterior segment cases showed early hypo fluorescence corresponding to retinitis patches. These turned gradually hyperfluorescent at the border of the retinitis lesions. Leakage was seen in late phase. Macula showed no leakage. OCT was done in cases of retinitis and retinal vasculitis with macular edema, OCT through the patches of retinitis revealed significant inner retinal hyperreflectivity with multiple hyperreflective dots in the retina and vitreous. Patients aged more than eight were treated with tablet Doxycycline (100 mg or 2.2 mg/kg/dose every 12 hours apart for at least 5 to 7 days or until afebrile for at least 3 days.) and children less than eight years were treated with intravenous azithromycin (2 mg/mL over 1 hr). Topical steroids (prednisolone acetate 1%) along with cycloplegic (Homatropine 2%) eye drops were used in case of AC flare/cells. Those with CNS involvement were treated with Intravenous antibiotics. Patients were followed up after their recovery from intensive care unit or emergency wards in ophthalmic outpatient department. Visual acuity improved in all patients with final follow up at 6 months (range 6/6 to 6/18). Optic neuritis case received systemic steroids (Intravenous methylprednisolone 1g for initial 3 days followed by tapering dose of oral prednisolone 1mg/kg) along with antibiotics and they were monitored for recurrence. Antibiotics were discontinued after recovery from acute illness under physician supervision.

**Discussion**

Rickettsial disease is endemic in many parts of India. In a 10-year study by Dasari *et al.*,<sup>[5]</sup> ten out of eleven outbreaks were due to scrub typhus and one was due to spotted fever. All patients in this study had positive Weil–Felix serology with titer value of  $\geq 1:80$ . As per Issac *et al.* titer value of 1:80 has sensitivity of 30% but with 100% specificity and positive predictive value.<sup>[6]</sup> Thus to avoid false-positive Weil–Felix Test, cutoff value of titer 1:80 was considered in this study, but still due to low sensitivity the cases might be missed.

Out of 50 patients, 2 (4%) patients were positive to OX 2 antigen only suggestive of Spotted fever group; 14 (28%) patients were positive for OX K antigen only suggestive of Scrub typhus 0.34 (68%) patients were positive for two antigens and they were included in double antigen group. These 34 patients cannot be included in any particular subtype of rickettsia, unless newer molecular methods were used. Twenty-nine (58%) patients were positive for OX 19 and OX 2 antigen; 4 (8%) patients were positive for both OX 2 and OX K antigen, and 1 (2%) patient was positive for both OX 19 and OX K antigen. Ocular manifestations were more common in double antigen group than single antigen group ( $P = 0.011$ ).

In our study, most of the patients were asymptomatic which might be due to 80% of pediatric age group of the affected patients and associated predominant systemic illness. Alio J *et al.*<sup>[3]</sup> and Khairallah M *et al.*<sup>[4]</sup> reported that ocular involvement in rickettsioses is frequently asymptomatic which is similar to our observation. In our study 27 patients (54%) had ocular manifestations. In the study done by Khairallah M *et al.*,<sup>[7]</sup> 68% had ocular involvement which is also almost similar to

our study. In the study done by Khairallah M *et al.*,<sup>[4]</sup> 89% had ocular involvement with 83% posterior segment involvement. In our study, out of 27 patients unilateral ocular involvement was seen in 17 (63%) patients and bilateral in 10 (37%). Double antigen group patients (68%) and pediatric patients (80%) tend to have more bilateral involvement than other group but were not statistically significant ( $P = 0.06$ ). In the study done by Khairallah M *et al.*<sup>[4]</sup> in 2004, 20% had unilateral and 80% bilateral ocular involvement; out of which 48.3% had retinal vasculitis, 30% had retinitis, 1.3% had cystoid macular edema, 1.3% had optic disc edema. In the study done by Khairallah M *et al.* in 2009,<sup>[7]</sup> 22% had unilateral and 78% had bilateral ocular involvement, out of which 42.5% had retinitis, 21.3% had vascular sheathing, 2.1% had macular edema and 4.3% had optic disc edema. Comparative analysis of ocular manifestations in different studies in relation to our study is shown in Table 2. Most of the retinal changes are detected during 10<sup>th</sup> to 17<sup>th</sup> day of the illness. In our study we did single examination during the acute illness of the disease in the emergency wards and subsequent follow-up was done in ophthalmology department. FFA could not be done in few children due to poor systemic status which might be the reason for less fundus findings and less bilateral ocular involvement as compared to other studies.

In our study, 16 patients had CNS involvement, out of which 15 (94%) had ocular findings. Other systems were involved in 10 cases, out of which 5 (50%) had ocular findings its comparable to other studies.<sup>[8]</sup> In double antigen group, which we were not able to classify patients into any particular rickettsial subtype that is spotted fever group or typhus fever group, ocular involvement was more common in this group (74%) than scrub typhus (21%) ( $P = 0.011$ ). Our study noted that rickettsial retinitis was more common with Indian tick typhus and epidemic typhus compared to scrub typhus, similar findings were noted by Kawali A *et al.*<sup>[9]</sup>

In our study, all cases received systemic Doxycycline and supportive treatment accordingly. Optic neuritis case received systemic steroids along with antibiotics. The role of steroids and antibiotics on the course of posterior segment disease is unknown. All cases showed good systemic clinical response to Doxycycline which is similar to other studies. Kumar *et al.*<sup>[10]</sup> has demonstrated a remarkable response to doxycycline and this response has been used as a diagnostic test. Reddy *et al.*<sup>[11]</sup> reported complete recovery on treatment with Doxycycline and Azithromycin.

**Table 2: Comparative analysis of ocular manifestation in different studies**

Ocular manifestations	Our study	Khairallah M <i>et al.</i> <sup>[4]</sup>	Khairallah M <i>et al.</i> <sup>[7]</sup>
Ocular Involvement	54%	89%	68%
Laterality (Unilateral:Bilateral)	63:37	20:80	22:78
Retinitis	26%	30%	42.5%
Retinal vasculitis	22%	48.3%	21.3%
Cystoid macular edema	11%	1.3%	2.1%
Unilateral Optic disc edema	4%	1.3%	4.3%
Papilloedema	22%	-	-
Sixth Cranial nerve palsy	4%	-	-
Optic neuritis	4%	-	-

External examination findings showed no eschar or nystagmus as compared to finding by Scheie *et al.*<sup>[12]</sup> Rest of the external examination findings was similar. The posterior segment finding in our patient showed multifocal retinitis serous macular detachment with macular star exudates and optic disc involvement in the form of disc edema and disc leakage. These posterior segment findings were similar to a study by Balasundaram *et al.*<sup>[13]</sup> that showed all 12 patients (21 eyes) presented with visual impairment ranging between (20/2000–20/30), multifocal retinitis, and 16/21 eyes had serous macular detachment with macular star exudates and optic disc involvement as evidenced by disc edema, and disc leakage on FFA was seen in 7/21 eyes. Retinal vascular sheathing adjacent to the lesions was noted in 7/21 eyes.

In another similar study by Kahloun *et al.*,<sup>[14]</sup> rickettsial disease leading to visual loss was seen in 16 eyes of 14 patients. Retinitis was observed in 14/16 eyes, serous macular detachment in 11/16 eyes and optic neuropathy in 7/16 eyes. A study by Khairallah *et al.*,<sup>[4]</sup> showed less profound finding with white retinal lesions seen in 18/60 patients, focal vessel sheathing in 5/60 patients, serous retinal detachment in 3/60 patients, macular star in 2/60 patients, and optic disc edema in one patient. Rickettsial disease changes are due to vasculitis leading to microvascular leakage, edema, tissue hypoperfusion, and end-organ ischemic injury.<sup>[3]</sup> Retinal injury is predominantly immune mediated with deposition of immune complexes and inflammatory cells in the retina may lead formation of white infiltrates. Diagnosis of Rickettsial disease is difficult and high index of suspicion is needed. Our study has certain limitations, sample size was small and cases were probable rickettsial disease based upon Weil–Felix test. Confirmatory tests like immunofluorescence assay (IFA) or immunoperoxidase assay (IPA) could not be done due to non-availability, confirmatory tests like Weil–Felix have low sensitivity and some cases were two antigens positive which we could not classify into rickettsial subtypes.

In conclusion, more than half of the patients with Rickettsioses can have ocular manifestations with predominant posterior segment involvement during acute illness. Ocular involvement was more common in double antigen-positive group than scrub typhus. CNS involvement will invariably have ocular involvement. Double antigen-positive, pediatric patients, bilateral involvement and those with CNS involvement did poorly compare to other patients. All cases showed good clinical response to treatment. A systematic ophthalmic evaluation should be a part of the routine evaluation of any patient who presents with fever and/rash living in endemic area. In rickettsioses, early initiation of appropriate treatment is possible in patients with pending serological report by looking at some of the typical ocular findings (focal/multifocal retinitis) and post febrile illness associated with dermatological features. Unlike other postviral retinitis, Rickettsial retinitis initially worsens with oral steroids and antiviral therapy, followed by a dramatic response to oral antibiotics.

Even though enough published data is available on ocular rickettsial disease, our study population contains 80% of children (mean age  $12.5 \pm 8.99$  years) and not much-published data available on pediatric rickettsial disease from other studies. We describe many ocular features like cranial nerve palsy, optic neuritis, papilloedema, which are not described earlier.

We are mainly highlighting the systemic and ocular course of the disease during acute phase of illness rather than long-term outcome. Patients may not be accessible for an eye examination during the acute phase of the disease as they will be under the care of either physician or pediatrician. So one must consider ophthalmic evaluation during acute phase of rickettsial disease to prevent vision threatening complications.

## Conclusion

Patients with rickettsial disease may have ocular manifestations with predominant posterior segment involvement during the acute phase of illness. Ophthalmic evaluation should be part of the routine examination in patients with fever and rash in endemic areas.

## Financial support and sponsorship

Nil.

## Conflicts of interest

There are no conflicts of interest.

## References

1. Parola P, Raoult D. Rickettsioses eruptives. EMC (Elsevier Paris) Maladies infectieuses 1998; 8-037-I-20: 24P.
2. Batra HV. Spotted fevers and typhus fever in Tamil Nadu commentary. Indian J Med Res 2007;126:101-3.
3. Alió J, Ruiz-Beltran R, Herrero-Herrero JI, Hernandez E, Guinaldo V. Retinal manifestations of Mediterranean spotted fever. Ophthalmologica 1987;195:31-7.
4. Khairallah M, Ladjimi A, Chakroun M, Messaoud R, Yahia S. Posterior segment manifestations of Rickettsia conorii infection. Ophthalmology 2004;111:529-34.
5. Dasari V, Kaur P, Murhekar MV. Rickettsial disease outbreaks in India: A Review. Ann Trop Med Public Health 2014;7:249-54.
6. Issac R, Varghese GM, Mathai E, J M, Joseph I. Scrub typhus: Prevalence and diagnostic issues in rural southern India. Clin Infect Dis 2004;39:1395-6.
7. Khairallah M, Yahia SB, Jelliti B, Ben Romdhane F, Loussaief C, Attia S, *et al.* Diagnostic value of ocular examination in Mediterranean spotted fever. Clin Microbiol Infect 2009;1:273-4.
8. Khairallah M, Ben Yahia S, Toumi A, Jelliti B, Loussaief C. Ocular manifestations associated with murine typhus. Br J Ophthalmol 2009;93:938-42.
9. Kawali A, Mahendradas P, Srinivasan P, *et al.* Rickettsial retinitis—an Indian perspective. J Ophthalmic Inflamm Infect 2015;5:37-8.
10. Kumar M, Krishnamurthy S, Delhikumar CG, Narayanan P, Biswal N, Srinivas S. Scrub typhus in children at a tertiary hospital in southern India: Clinical profile and complications. J Infect Public Health 2012;5:82-8.
11. Reddy BK, Basavaraj GV. Rickettsial Meningoencephalitis: An underdiagnosed entity in developing countries. J Pediatr Sci 2013;5:1193.
12. Scheie HG. Ocular changes in scrub typhus; a study of 451 patients. Bull U S Army Med Dep 1946;5:423-7.
13. Balasundaram MB, Manjunath M, Baliga G, Kapadi F. Ocular manifestations of Rickettsia conorii in South India. Indian J Ophthalmol 2018;66:1840-4.
14. Kahloun R, Gargouri S, Abroug N, Sellami D, Ben Yahia S, Feki J, *et al.* Visual loss associated with rickettsial disease. Ocul Immunol Inflamm 2014; 2:373-8.