

# Experimental evaluation of horse hair as a nonabsorbable monofilament suture

Swati R. Yedke, Subhash Y. Raut<sup>1</sup>, C. R. Jangde<sup>2</sup>

Department of Shalyatantra, Yashwant Ayurved College, Kodoli, <sup>1</sup>Department of Shalyatantra, Government Ayurved College, Nagpur,

<sup>2</sup>Department of Pharmacology and Toxicology, Nagpur Veterinary College, Nagpur, Maharashtra, India

## ABSTRACT

**Background:** Success of surgery depends on wound closure and healing. Ancients had coated many suture materials from plant and animal origin. As the quest for natural nonabsorbable, monofilament surgical suture continues, horsehair has been taken for study, which is mentioned in ancient literature. **Objectives:** Aim of the study was to evaluate detail mechanical and biophysical properties of horsehair. **Materials and Methods:** Physical properties, that are diameter, straight pull and knot pull tensile strength, bioburden, sterility tests were performed. Visual and histological wound healing parameters were studied in experimental Wistar rat incision wound model. Two experimental wounds about 5 cm long were created on each side of dorsal midline. Each animal received two sutures-Horsehair 4-0 and Ethilon 4-0. The sutured areas were grossly examined on 3<sup>rd</sup> and 7<sup>th</sup> days for visual observations like congestion, edema, infection, wound disruption, and impression of suture material on healed wound and then subjected for histological study. **Results:** Revealed that horsehair has got diameter of 0.19 mm which complies with the 4-0 size USP standard. Straight pull tensile strength was found  $0.5851 \pm 0.122$  kg and knot pull tensile strength was  $0.3998 \pm 0.078$  kg, which complies with the standards of United State Pharmacopia for class II nonabsorbable suture materials. *In vivo* study revealed that there was no evidence of edema, congestion, and discharge in both the groups. Wounds healed with minimum impressions of suture material with minimum scar mark. Mean histological scoring shows very mild tissue reaction. **Conclusion:** Horsehair has got properties of standard suture material except low tensile strength and hence can be used in reconstructive, plastic surgeries, and ophthalmic surgeries.

**Key words:** Horse hair, suture materials, tensile strength, tissue reaction

## INTRODUCTION

Success of surgery depends on wound closure and wound healing. Early man was aware of the benefits of closing wounds. For the procedure they had used different kinds of suturing materials from natural origin like flax, grass, cotton threads, silk threads, hair, tendons, heads of beetles or ants, animal gut, and so on.<sup>[1,2]</sup>

### Address for correspondence:

Dr. Swati R. Yedke, Plot No. 18, Sant Namdeo Nagar, Near Ladikar Ram Mandir, Manewada Road, Nagpur - 440 024, Maharashtra, India. E-mail: drswati\_ms@yahoo.co.in

Received: 22-Mar-2013

Revised: 19-May-2013

Accepted: 04-Jun-2013

Suturing with horsehair was routinely practiced in ancient India and at various places all over the world.<sup>[1,3-8]</sup> There are many references that mentioned horsehair as a civil war sutures. During war, it has been used as an emergency suture when there was shortage of other suture materials.<sup>[9]</sup>

In 1974, Sinha<sup>[10]</sup> from Patna Medical College had evaluated the horsehair as a tendon suturing material and obtained very encouraging results.

Percival hay used horse hair for closing the conjunctival wound in a Frost-Lang operation and found it extremely useful as it keeps the wound firmly closed and does not bunch up the conjunctiva.<sup>[11]</sup>

In spite of several studies and bearing ideal suture characteristics, this material has not gained popularity; the reason behind this may be its low tensile strength and its biodiversity.

Although suture materials and aspects of the technique have changed substantially over time, the goal remain the same: Closing the dead space, supporting and strengthening

### Access this article online

#### Quick Response Code:



#### Website:

www.jaim.in

#### DOI:

10.4103/0975-9476.123691

wounds until healing increases their tensile strength, approximating skin edges for an esthetically pleasing and functional results and minimizing the risk of bleeding and infection.<sup>[12,13]</sup>

Horsehair has got a strong potential as surgical suture. Though Ayurveda, the most ancient yet living traditions-was using it routinely, it is essential to promote it with more research-based and scientific approach.

Hence the study “*Experimental Evaluation of Horsehair as a nonabsorbable, monofilament suture*” has been undertaken.

## MATERIALS AND METHODS

### Study design

Basic preclinical research.

### Study material

Horsehairs from caudal end were used for the study.

### Physical properties

The parameters for physical properties of the horsehair were carried out at a well-established laboratory of Ethicon – Johnson and Johnson Pvt. Limited. Parameters tested are diameter, straight pull tensile strength, knot pull tensile strength, sterility test, and bioburden of the horsehair strands.<sup>[13-15]</sup>

The tensile strength of horsehair was measured on a special motor driven tensile strength testing machine – Instron tensile tester (Model no.-4464 H/840).<sup>[12]</sup>

The specimen of length 127 mm was inserted in the clamps of the apparatus. Using the principle of constant rate of elongation of specimen, readings were recorded for 10 strands of horsehair.

For knot pull tensile strength test, the test suture was tied into a surgeons knot with one turn of suture around a flexible rubber tubing of 6.5 mm inside diameter. The specimen was placed in the testing device with the knot approximately midway between the clamps. The clamps driven with constant rate of pull and reading were noted for 10 strands of specimen.

The device used for determining the diameter of sutures was the dead weight type Mitutoyo Dial Gauge.

The diameter of the strands was measured at three points corresponding roughly to one fourth, one half, and three fourths of the length. The diameter at the designated points was noted and the average diameter likewise was calculated.

Uniformity and smoothness were calculated by visual observations under compound microscope. The small piece of hair strand was placed over slide and edges of the strand were observed under 40x objective magnification.

The horsehair were sterilized by two methods steam sterilizer (Lab Autoclave) and gaseous ethylene oxide. Bacterostasis and fungistasis test was performed.

Bioburden is a population of viable microorganisms on a product. A total of 10 samples were used to perform bioburden test by Pour plate method. Gram staining of typical colony was performed.

All the results were documented.

### *In vivo* study

The *in vivo* study has been designed to assess the efficacy of horsehair as a suture material and tissue reaction elicited by it in adult albino rats. Autoclaved caudal end horsehairs were used for the experiment. The visual observations like swelling, congestion, discharge, wound dehiscence, and impressions of suture over scar and histological parameters like rate of cellular infiltration, rate of fibroblastic proliferation, rate of angioblastic proliferation were carried out.<sup>[16-18]</sup> The study was conducted for the period of seven days.

The institutional animal ethical committee approved the experimental protocol. The experimental protocol met the national guidelines as per the guidelines of the (CPCSEA), ministry of social justice and empowerment, Government of India.

The present research work carried out on six Wistar albino rats.

### Design of experiment

Total six adult Wistar albino rats were used to evaluate tissue reaction to horsehair. The rats were weighed between 275 and 300 gm.

Anesthesia – rats were anesthetized by IM administration of 3 mg of xylazine HCl given in triceps brachii region. Disappearance of palpebral and pedal reflexes was taken as a guideline for adequate anesthesia.

Hairs over the lumbodorsal region were removed and the skin was prepared for aseptic wounding.

After induction of anesthesia, the animal was held in a dorsal recumbency. Two experimental wounds about 5 cm long were created through skin, subcutaneous tissue and musculature, on each side of dorsal midline with a sharp 15 number scalpel blade fitted on a BP handle.

Each animal received two sutures-Horsehair 4-0 and ethilon 4-0 [Figure 1a].

The wound over right side of dorsum was sutured with horsehair and considered as Group I and left-sided wound was sutured with ethilon 4-0 was considered as Group II.

The wounds closed with five simple interrupted stitches with a 1 cm interval between each stitch. The same surgeon and assistant performed all operations. The same skin preparation, same sterile precautions, and same suturing technique were used in every wound closure.

The sutured areas were grossly examined on 3<sup>rd</sup> and 7<sup>th</sup> days for visual observations like congestion, edema, infection, wound disruption, and impression of suture material on healed wound.

### Visual observations

Each incision was graded according to following scale:

- Grade 1: No visible reaction
- Grade 2: Minimal swelling at the site of incision
- Grade 3: Suture line inflammation at least 1 cm thick with pain or redness
- Grade 4: Seroma or abscess formation
- Grade 5: Wound dehiscence.

### Histological study

Tissue suture specimen collection:

- After 7 days, the rats were anesthetized and a 2-5 cm section of the skin, subcutaneous tissue and body wall that include 1cm margin around the entire stitch were removed from the dorsal area
- The samples were excised and collected in neutral buffered 10% formalin solution
- The wounds were sutured and the rats were allowed to recover
- The samples were then processed for paraffin embedding with standard procedure
- Paraffin section were cut at 6 microns thickness and stained with hematoxyline and eosin stains for histological analysis
- The healing process and tissue reaction around

the suture materials were studied under the light microscope and compared.

### Histological data

The tissue response to suture material was assessed with a crude grading system based on severity of cellular infiltration, rate of fibroblastic proliferation, and rate of angioblastic proliferation were scored as follows:

- 0: None
- 1: Mild
- 2: Moderate
- 3: Severe.

The overall reaction was estimated as follows:

- 0.5-1.4 : Very mild reaction
- 1.5-2.4 : Mild reaction
- 2.5-3.4 : Moderate reaction
- 3.5-4.4 : Severe reaction.

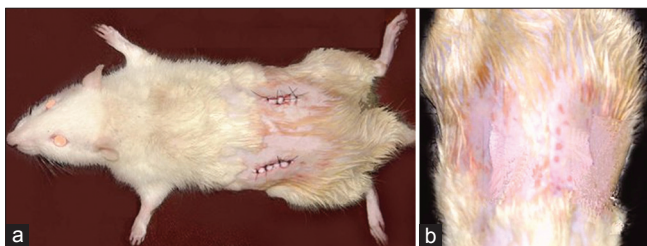
### RESULTS

Diameter of horsehair was calculated and found to be 0.192 mm, which complies with the 4-0 sizes of USP standards. Straight pull tensile strength of horsehair was found to be  $0.585 \pm 0.122$  kg and the average knot pull tensile strength was  $0.399 \pm 0.078$  kg. Straight pull tensile strength and knot pull tensile strength of autoclaved sample was  $0.493 \pm 0.09$  kg and  $0.405 \pm 0.06$  kg, respectively. The average bioburden was found to be 17.9 cfu/product. All samples (horsehair) of both the types (steam and ethylene oxide sterilized samples) inoculated in SCDM (Soyabean Casein Digest Medium) and FTM (Fluid Thioglycollate) were found to be sterile after 14 days of incubation. Visual parameters of *in vivo* study shows excellent healing in both the groups on seventh postoperative day. There was no evidence of edema, congestion, and discharge in both the groups. Scar mark was minimum in both the groups. There were minimum impressions of suture material on healed up wounds [Figure 1b]. Mean histological scoring shows very mild tissue reaction in both the groups. It revealed healthy granulation completely covered with proliferative dermoid epithelium.

### DISCUSSION

In spite of lack of manufacturing and synthetic development of suture materials, ancients were well-known about how to utilize natural materials for wound closure, which are available anytime around us.

In India, about 68.8% population reside in rural areas and they get treated at local healthcare centers, the



**Figure 1:** (a) Experimental wounds sutured with horse hair (right side) and ethilon (left side). (b) Healed wounds on 7<sup>th</sup> postoperative day

availability of expensive suture materials is not possible and the multifilament sutures like cotton or silk are most common cause of infecting the sutured wound in those conditions.<sup>[19-21]</sup>

The general performance of suture material is based on its physical characteristics, handling characteristics, and biological properties.<sup>[22]</sup>

As mentioned before, suture size also affects the wound healing. Smaller the size of suture lesser will be the trauma and inflammatory reaction.

The horsehair has got diameter 0.19 mm. As per USP standards, this diameter complies with the 4-0 size standard suture material.<sup>[12]</sup> Therefore, it can be stated that horsehair is a 4-0-sized suture material. The diameter after autoclaving the sample was measured as 0.18 mm. Therefore, it can be concluded that horsehair does not show too much alteration in the diameter after boiling or autoclaving the sample.

The perusal of literature reveals that boiling was the most accepted method of sterilization for horsehair to make it more pliable and then it can be left any number of days without causing suppuration and can be removed without pain.<sup>[4,8,9]</sup>


Straight pull tensile strength of the horsehair was found  $0.5851 \pm 0.122$  kg and knot pull tensile strength was  $0.3998 \pm 0.078$  kg, which complies with the class II of nonabsorbable suture material of USP standards.

The average straight pull tensile strength of autoclaved sample is  $0.493 \pm 0.09$  kg and % elongation is  $203.9 \pm 23.4\%$ . The average knot pull tensile strength of autoclaved sample is  $0.405 \pm 0.06$  kg and % elongation is  $146.8 \pm 31.4\%$ . If hair keratins are stretched in steam, then they develop a  $\beta$ -sheet configuration. It is observed that the knot pull tensile strength is increased after autoclaving the sample of horsehair. It means the strands become more pliable when boiled or autoclaved. Boiling the samples can reduce the stiffness of horsehair.

A bothersome tendency to attract adjacent tissue is known as tissue drag of the suture material.

If the suture is of a rough morphology (e.g. braided), the tissue will swell more and is more susceptible to infection than if a smooth suture (e.g. monofilament) is used.<sup>[19]</sup>

The structure of horsehair is very smooth as seen under high power of light microscope and the passage through tissue, that is, tissue drag of the material is smooth and harmless to injured tissue [Figure 2].



**Figure 2:** Smooth structure of horse hair under light microscope

An evaluation of handling characteristics of the suture was subjective and found to be good. But the disadvantage with the strand of horsehair is that it slips out from the eye of eyed needle; therefore, the handling characteristic should be improved with needle attachment with eyeless needle.

The inflammatory reaction associated with a suture material is attributed to a combination of the trauma of the implantation process and the physical and chemical properties of the suture material.<sup>[17]</sup> Trauma associated with insertion of any suture will cause aseptic inflammation lasting approximately five days.<sup>[19,20]</sup> The results of tissue reaction of horsehair were dramatically encouraging.

Wound healing with horsehair was complete without suppuration. Histologically, the slides of horsehair have shown very mild exudative and foreign body reaction [Figure 3a and b].

The observation of 7<sup>th</sup> day of wound healing revealed progressive normal healing of both the wounds without any complication and hence appeared to be comparable.

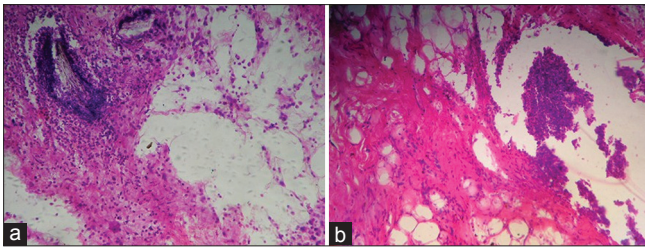
## CONCLUSION

Horsehair is a natural material, easily available and very cost-effective. It will cut off the cost of surgery to a great extent.

Monofilament sutures are always superior to multifilament sutures with regard to the incidence of wound infection.<sup>[21]</sup> As the horsehair is monofilament; it will not provide a medium for bacterial growth and thus reduce chances of infection.

Considering the diameter and tensile strength of the material, it is useful in external suturing especially cosmetically important areas like face, neck, extremities,





**Figure 3:** (a) Tissue reaction to ethilon (b) Tissue reaction to horse hair

and so on where delicacy is the need while suturing and the wound healing is expected with minimum scar.

No allergic reaction was noted with the experimental suture.

Thus, it can be concluded that horsehair can be used as suture material in plastic surgery and in ophthalmic surgeries and will prove beneficial to society.

### ACKNOWLEDGMENT

With deep sense of gratitude, we are extremely thankful to Mr. Yateen Shah, R and D Manager, Ethicon, Johnson and Johnson Pvt. Ltd., Aurangabad; for allowing us to undertake this work at their research and quality assurance laboratory and providing all the facilities at their establishment. We are obliged to Dr. A. G. Bhandarkar, Associate Professor and Head, Department of Pathology, Nagpur Veterinary College, Nagpur for his immense help in working out the histological study. We also express our sincere gratitude and regards towards Central Council for Research in Ayurveda & Siddha, New Delhi for providing financial support in the form of contingent grant.

### REFERENCES

1. Solanki YG, Lavekar GS. Evaluation of Human Hair as suturing material. M.D. Thesis: Ayurveda Faculty, Mumbai University; May 2000.
2. Yadavji Trikamji. Sushruta Samhita of Sushruta with Nibandha Sangraha Commentary of Shri Dalhanacharya. Vol. 25. Varanasi: Chaukhambha Surbharti Prakashan. Sutrasthana; 2003. p. 20-1.
3. Black JJ. A stitch in time: The history of sutures. Nurs Times 1982;78:619-23.
4. Chari PS. Sushruta and our heritage. Indian J Plast Surg 2003;36:4-13.
5. Brigham, Charles B. Some remarks on the operation for

- hare-lip, with two cases and photographs. West Lancet 1883;2:129-34.
6. Dubois J. Immediate perineorrhaphy in two planes with horsehair figure of eight sutures. Gynecol Obstet (Paris) 1958;57:212-6.
7. Minckler DS. Glaucoma drainage devices-horse hair to silicone. In: 100 Years of Progress in Glaucoma. Philadelphia: Lippincott-Raven; 1997. p. 287-92.
8. Kravetz RE. A look back to horse hair sutures. Am J Gastroenterol 2003;98:691.
9. Fitts D. Medicine and the Battle of Gettysburg. The Civil War News, TSR; June 1996.
10. Sinha HN. Evaluation of horse hair as a tendon suturing material an experimental study. Indian J Orthop 1974;8:149-56.
11. Hay PJ. A note on the use of horse hair sutures for the Conjunctiva. Br J Ophthalmol 1939;23:43-4.
12. Gennaro AR. Remington: The science and practice of pharmacy. 19<sup>th</sup> ed., vol. 2. Philadelphia: Lippincott Williams and Wilkins; 1995. p. 1878-82.
13. Taylor B, Bayat A. Basic plastic surgery techniques and principles: Choosing the right suture material. Stud BMJ 2003;11:131-74.
14. Levy AJ. Testing a new suture material. Point of View 1982;19:14-5.
15. Scott F. Suture Lab Guide in conjunction with Ethicon Wound Closure Manual and Basic Knot Tying. Somerville NJ: Ethicon Inc. Johnson and Johnson Pvt. Ltd.; 2005.
16. Freeman LJ, Pettit GD, Robinette JD, Lincoln JD, Person MW. Tissue reaction to suture material in the feline linea alba. A retrospective, prospective and histologic study. Vet Surg 1987;16:440-5.
17. Bohling MW, Henderson RA, Swaim SF, Kincaid SA, Wright JC. Cutaneous wound healing in the cat: A macroscopic description and comparison with cutaneous wound healing in the dog. Vet Surg 2004;33:579-87.
18. Gadgil US, Sardeshpande PD. Biological Response to Suture Materials, Ph.D. Thesis: Konkan Krishi Vidyapeeth; 1983.
19. Van Winkle W Jr, Hastings JC, Barker E, Hines D, Nichols W. Effect of Suture Materials on healing skin wounds. Surg Gynecol Obstet 1975;140:7-12.
20. Van Winkle W, Salthouse TN. Biological response to sutures and Principles of suture selection. Scientific exhibit, American college of surgeons, Clinical congress, San Fransisco; 1975.
21. Tan RH, Bell RJ, Dowling BA, Dart AJ. Suture materials: Composition and applications in veterinary wound repair. Aust Vet J 2003;81:140-5.
22. Certosimo FJ, Nicoll BK, Nelson RR, Wolfgang M. Wound healing and repair: A review of the art and science. Gen Dent 1998;46:362-9.

**How to cite this article:** Yedke SR, Raut SY, Jangde CR. Experimental evaluation of horse hair as a nonabsorbable monofilament suture. J Ayurveda Integr Med 2013;4:206-10.

**Source of Support:** Contingent grant from CCRAS, New Delhi, for Minor Research Project, **Conflict of Interest:** None declared.

### Dispatch and return notification by E-mail

The journal now sends email notification to its members on dispatch of a print issue. The notification is sent to those members who have provided their email address to the association/journal office. The email alerts you about an outdated address and return of issue due to incomplete/incorrect address.

If you wish to receive such email notification, please send your email along with the membership number and full mailing address to the editorial office by email.