

Teaching Point (Section Editor: F.P. Schena)

Pre-eclampsia before 20-week gestation: diagnosis, investigation and management

William Thomas¹, Meryl Griffiths², Catherine Nelson-Piercy³ and Kim Sinnamoni¹

¹Department of Renal Medicine, Colchester Hospital, Colchester, UK, ²Department of Histopathology, Addenbrooke's Hospital, Cambridge, UK and ³Department of Obstetric Medicine, Guy's and St Thomas' Hospital, London, UK

Correspondence and offprint requests to: William Thomas; E-mail: whcthamas@gmail.com

Keywords: early pregnancy; kidney biopsy; pre-eclampsia; proteinuria

Introduction

Pre-eclampsia (PET) is a hypertensive disorder of pregnancy predominantly occurring after 20-week gestation. Proteinuria, which is of variable magnitude, is required to make the diagnosis. Maternal clinical manifestations are variable and may result in renal impairment, liver dysfunction and haematological abnormalities. The foetus may be growth restricted with oligohydramnios. Risk factors include a history of hypertension, previous history of PET, primiparity and advanced maternal age. We report the case of very early-onset PET and advise that it should always be considered in the differential diagnosis of proteinuria and hypertension prior to 20-week gestation. We also discuss the role of kidney biopsy in such situations, the dilemmas faced in patient management and the need for long-term follow-up for these patients.

Case report

A 44-year-old Zimbabwean woman booked at 14-week gestation with asymptomatic hypertension with a blood pressure (BP) of 160/98 mmHg and normal urinalysis. She had an 8-year history of hypertension which may have been essential in nature or secondary to her previous pregnancy-related BP issues as outlined below. She had no clinical features in keeping with other causes of secondary hypertension. Her BP had been controlled with ramipril and bendroflumethiazide until 6 months previously when they had been replaced with labetalol at the time of a pregnancy that subsequently resulted in a miscarriage at 8⁺⁵-week gestation. She remained on labetalol at booking of this current pregnancy. At 16 weeks, BP was 150/100 mmHg with +++ proteinuria. She was asymptomatic. Fundoscopy demonstrated arteriovenous nicking. Examination was otherwise normal. Her weight was 95.4 kg with a body mass index of 34.

Her obstetric history included delivery of a live infant, when she was aged 20, via Caesarean section (CS) at

39-week gestation for failure to progress. Aged 24, she had a stillbirth at 20-week gestation following pre-term spontaneous rupture of membranes. There were no hypertensive issues during these first two pregnancies. Between the ages of 24 and 26, she had two more pregnancies in Zimbabwe complicated by hypertension and proteinuria with resulting intrauterine death or miscarriage. Aged 26, she was treated for hypertension from 16-week gestation, admitted to hospital from 24-week gestation with a CS at 32-week gestation for fulminating PET with a healthy baby delivered. Aged 35, she had a CS for fulminating PET at 32-week gestation with intrauterine death. Aged 43 (6 months prior to this episode), she had a completed miscarriage at 8⁺⁵ weeks where BP was 130/80 mmHg. She had no history of autoimmune disease, sickle cell disease, malaria or diabetes mellitus. She had a cholecystectomy aged 40 for calculi. The only family history was that of hypertension.

During this pregnancy, proteinuria was 1.04 g/day at 16-week gestation. Renal function was normal (estimated glomerular filtration rate >90 mL/min, creatinine 64 µmol/L). Kidney tract ultrasound was unremarkable. Electrocardiogram was normal. Twenty-four-hour urinary catecholamines were within the normal range. Antinuclear antibody, anti-neutrophil cytoplasmic antibody, lupus anticoagulant, anti-cardiolipin antibodies, Protein C and S, sickle cell testing and serology for hepatitis B, C and HIV were negative or normal. Alanine aminotransferase (ALT) was elevated at 63 (0–34 IU/L). The labetalol was upwardly titrated to 1200 mg/day and then replaced with nifedipine 40 mg daily as no improvement in BP had been noted. At 17-week gestation, the nifedipine was titrated to 80 mg/day. Methyldopa was added. Low-molecular-weight heparin was commenced and aspirin 75 mg daily added. At 17⁺⁵-week gestation, labetalol was recommenced. From 18-week gestation, BP was between 125/85 and 155/95 mmHg.

By 20-week gestation, she developed uncontrolled hypertension. Creatinine increased to 101 µmol/L with a urinary protein/creatinine ratio (PCR) of 482 mg/mmol. ALT increased to 114 (0–34 IU/L). The peak PCR was

962 mg/mmol. Blood film showed fragmented red cells. She remained asymptomatic apart from increasing oedema of the legs, hands and face. As the aetiology of her renal diagnosis was unclear, we proceeded to a kidney biopsy, which confirmed the diagnosis of PET (Figures 1 and 2).

At 22-week gestation, she had severe intrauterine growth restriction (IUGR), absent diastolic flow in the cord Doppler study and decreased foetal movements. Uterine artery Doppler, to evaluate placental vasculature further, had been planned for 24 weeks [1]. Medical termination of pregnancy was undertaken at 22⁺⁴, with one vaginal and four oral doses of misoprostol. She then had a normal vaginal delivery, with a resulting stillborn foetus, complicated by the need for evacuation of retained placental products. BP, renal and liver function improved. Foetal cytogenetic testing was normal. At 4-week post-delivery, BP was 140/90 mmHg and urinary PCR 125 mg/mmol. Methyldopa was stopped, nifedipine 40 mg daily continued and labetalol replaced with bisoprolol 10 mg daily. At

14-week post-delivery, BP was 120/70 mmHg with a urinary PCR of 82.4 mg/mmol. At 26-week post-delivery, PCR had fallen further to 40.2 mg/mmol with well-controlled BP on two agents. She remains under review and has been counselled regarding future risk of cardiovascular disease and to avoid further pregnancy.

Discussion

Different hypertensive disorders can occur in pregnancy (Table 1). Traditionally, PET is the new onset of hypertension (BP ≥ 140 mmHg systolic, ≥ 90 mmHg diastolic measured on two separate occasions) and proteinuria (≥ 0.3 g/day) after 20-week gestation in a previously normotensive patient. Clinical features include oedema, visual disturbances, epigastric pain, headache, brisk reflexes and progression to fitting ('eclampsia'). Case reports have reported very early PET (before 20 weeks gestation) in association with molar pregnancy, triploidy, Cushing syndrome and antiphospholipid syndrome [2–7]. There have been two case reports of very early PET occurring in the absence of these conditions, which are dubbed 'pure', thereby challenging the traditional diagnostic criteria for PET [8, 9]. These cases have been described as atypical pre-eclampsia–eclampsia at <20 weeks of gestation [10]. The case we have described is very early PET superimposed on a background history of hypertension and previous PET. There were no other risk factors for developing PET at such an early gestation as there was no evidence of gestational trophoblastic disease and the foetus was cytogenetically normal.

The mechanisms of PET remain incompletely understood. The condition appears to be caused by the abnormal placental invasion of the uterus leading to placental ischaemia and widespread maternal endothelial dysfunction. Research has demonstrated that this endothelial dysfunction is likely contributed to by the inhibition of the endothelial growth factors vascular endothelial growth factor and placental growth factor 1 by the molecule soluble fms-like tyrosine kinase-1 as well as by the up-regulation of soluble endoglin (an anti-angiogenic factor) [11]. It is possible that in the future, these growth factors will become useful biochemical markers to aid in the diagnosis of PET.

One of the difficulties faced in this case was the consideration of a disease that fell out of conventional diagnostic criteria, where the clinician could be led into thinking that PET 'cannot' occur prior to 20 weeks. The differential diagnosis for hypertension and proteinuria in early pregnancy in our patient included PET (given the presence of several risk factors for PET including late

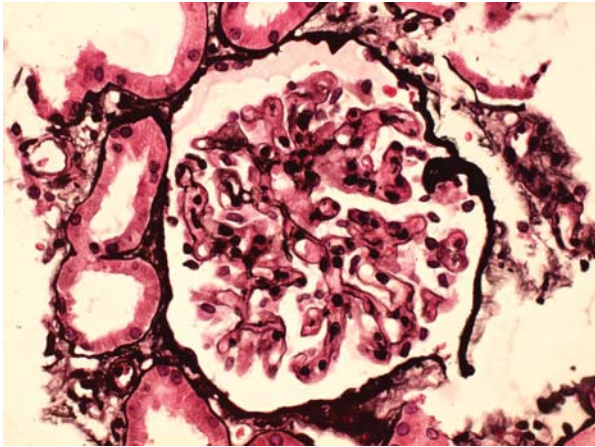


Fig. 1. Light microscopy of the renal biopsy at $\times 400$ magnification using a silver stain. The glomerulus is bloodless. The capillary lumina is obliterated by the endothelial cell swelling with foci of reduplication of the capillary walls (at 9 O'clock) with mesangial interposition. This is consistent with pre-eclamptic nephropathy.

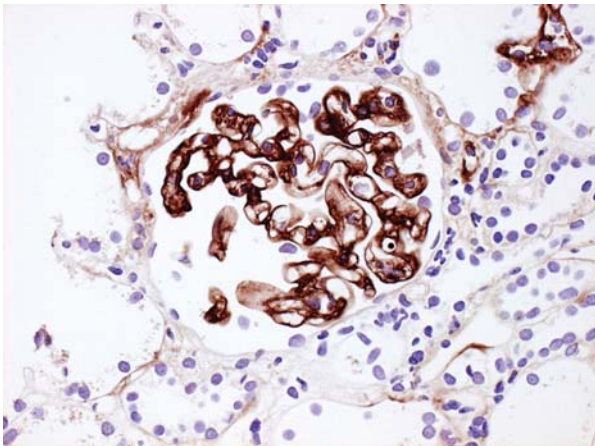


Fig. 2. Immunoperoxidase stain at $\times 400$ magnification light microscopy. It is positive for IgG, IgM and C1q in a diffuse pattern on capillary walls and in the mesangium. There is minimal staining for C3. IgA is negative. The significance of this staining is uncertain.

Table 1. Hypertensive disorders found in pregnancy

PET—occurring after 20-week gestation with proteinuria as per traditional criteria
Pre-eclampsia–eclampsia at <20 weeks of gestation—occurring usually in conjunction with another medical condition (e.g. triploidy).
Late PET—occurring from 48 h to 4 weeks after delivery
Chronic hypertension—occurring pre-pregnancy and persists post-delivery. PET may be superimposed upon this in the pregnancy
Gestational hypertension—develops after mid-pregnancy, absent proteinuria but may develop into PET
Gestational proteinuria—normotension with ≥ 0.3 g/day proteinuria occurring in pregnancy. Renal disease and ensuing PET should be considered

maternal age, essential hypertension and previous PET) or an underlying glomerulopathy. As PET and some glomerulopathies may have similar clinical and laboratory findings, and given that the patient was only 16 weeks pregnant and fell out of the conventional time frame for PET, a kidney biopsy was important to clearly identify the diagnosis and to direct management. Kidney biopsy may be an important and safe investigation in pregnancy and has been shown to demonstrate a wide range of different renal pathologies in pregnancy [12]. In later stages of pregnancy, there is more certainty that new-onset hypertension and proteinuria, possibly with other supportive clinical features, is likely to represent PET and therefore kidney biopsy could potentially be delayed until after delivery. Kidney biopsy therefore is reserved for cases where there is diagnostic dilemma and when biopsy findings are likely to affect patient management.

Investigations for PET include urinalysis, full blood count, blood film, renal function and electrolytes, liver function, clotting studies and foetal/placental Doppler studies to monitor foetal well-being. These may aid in diagnosis but also monitor disease progression and aid in decision-making. They may also indicate other diseases developing such as the HELLP syndrome (haemolysis, elevated liver function tests, low platelets) or disseminated intravascular coagulation. In most cases of PET, the BP can be managed with oral anti-hypertensives but intravenous agents can be used. Control of hypertension will help reduce complications such as haemorrhagic stroke, stop progression to eclampsia and allow the pregnancy to progress to a viable gestation. Prior to 34-week gestation, steroids can be considered to aid foetal lung maturity, but the overall strategy is to delay the need for delivery as long as it is safe. After 34 weeks, delivery is generally safer for the foetus.

Our patient required multiple oral anti-hypertensives to control her hypertension and was prescribed low-dose molecular-weight heparin given her risk factors for venous thromboembolism along with low-dose aspirin. The usage of low-dose aspirin is recommended by the National Institute of Clinical Excellence and a recent meta-analysis has indicated benefit in preventing PET in high-risk women [13, 14]. In spite of these medical interventions, our patient developed a worsening clinical picture with deteriorating renal and liver function tests which, along with severe foetal IUGR, resulting in the decision to terminate the pregnancy. Given her obstetric history, it is unlikely that any future pregnancy would result in a favourable outcome for our patient and she was counselled with regard to this and has recently had a contraceptive implant placed. As PET has been identified as a risk factor for future cardiovascular events, long-term follow-up to modify BP and cholesterol is advisable [15].

In conclusion, this report adds further to the medical knowledge of very early PET. Reporting of cases of PET that occur prior to 20 weeks may help identify exemplar features demonstrated by these patients which has led to the development of this disease at such an early gestation. Our case is a cautionary warning to physicians to think laterally and challenge traditional criteria and guidelines.

Teaching points

- (i) PET can occur before 20-week gestation and should be considered in the differential diagnosis of any

pregnant woman with new-onset hypertension and proteinuria, irrespective of gestation.

- (ii) Kidney biopsy is safe in pregnancy and may be crucial in distinguishing PET from other glomerulopathies.
- (iii) Women with PET should be counselled about the long-term risk of cardiovascular disease and appropriately followed up for this.

Conflict of interest statement. C.N.-P. is a trustee for the charity APEC (Action on pre-eclampsia).

References

1. Kalache KD, Duckelmann AM. Doppler in obstetrics: beyond the umbilical artery. *Clin Obstet Gynecol* 2012; 55: 288–295
2. Rahimpanah F, Smoleniec L. Partial mole, triploidy and proteinuric hypertension: two case reports. *Aust N Z J Obstet Gynaecol* 2000; 40: 215–218
3. Brittain PC, Bayliss P. Partial hydatidiform molar pregnancy presenting with severe pre-eclampsia prior to twenty weeks gestation: a case report and review of the literature. *Mil Med* 1995; 160: 42–44
4. Alsulyman OM, Castro MA, Zuckerman E et al. Preeclampsia and liver infarction in early pregnancy associated with antiphospholipid syndrome. *Obstet Gynecol* 1996; 88: 644–646
5. Craig K, Pinette MG, Blackstone J et al. Highly abnormal maternal inhibin and beta-human chorionic gonadotrophin levels along with severe HELLP syndrome at 17 weeks gestation with triploidy. *Am J Obstet Gynecol* 2000; 182: 737–739
6. Nugent CE, Punch MR, Barr M. Persistence of partial molar placenta and severe preeclampsia after selective termination in a twin pregnancy. *Obstet Gynecol* 1996; 87: 829–831
7. Delibasi T, Ustun I, Aydin Y et al. Early severe pre-eclamptic findings in a patient with Cushing's syndrome. *Gynecol Endocrinol* 2006; 22: 710–712
8. Hazra S, Waugh J, Bosio P. 'Pure' pre-eclampsia before 20 weeks of gestation. *Br J Obstet Gynaecol* 2003; 110: 1034–1035
9. Imasawa T, Nishiwaki T, Nishimura M et al. A case of 'pure' preeclampsia with nephrotic syndrome before 15 weeks of gestation in a patient whose renal biopsy showed glomerular capillary endotheliosis. *Am J Kidney Dis* 2006; 48: 405–501
10. Sibai BM, Stella CL. Diagnosis and management of atypical preeclampsia-eclampsia. *Am J Obstet Gynecol* 2009; 200: 481.e1–481.e7
11. Maynard SE, Karumanchi SE. Angiogenic factors and preeclampsia. *Semin Nephrol* 2011; 31: 33–46
12. Packham D, Fairley KF. Renal biopsy: indications and complications in pregnancy. *Br J Obstet Gynaecol* 1987; 94: 935–939
13. NHS National Institute for Health and Clinical Excellence. Hypertension in pregnancy: the management of hypertensive disorders during pregnancy (NICE Clinical Guideline 107). Issued August 2010. Available from: <http://www.nice.org.uk/nicemedia/live/13098/50418/50418.pdf> (8 October 2012, date last accessed)
14. Trivedi NA. A meta-analysis of low-dose aspirin for prevention of preeclampsia. *J Postgrad Med* 2011; 57: 91–95
15. Bellamy L, Casas JP, Hingorani HD et al. Pre-eclampsia and risk of cardiovascular disease and cancer in later life: systematic review and meta-analysis. *Br Med J* 2007; 335: 974

Received for publication: 22.2.12; Accepted in revised form: 13.7.12