



Video-Assisted Thoracic Surgery Lobectomy

Hong Kwan Kim, M.D., Ph.D.

Department of Thoracic and Cardiovascular Surgery, Samsung Medical Center, Sungkyunkwan University School of Medicine, Seoul, Korea

ARTICLE INFO

Received June 9, 2021

Revised July 8, 2021

Accepted July 16, 2021

Corresponding author

Hong Kwan Kim

Tel 82-2-3410-1687

Fax 82-2-3410-6986

E-mail hkkimts@gmail.com

ORCID

<https://orcid.org/0000-0002-7815-3336>

Video-assisted thoracoscopic surgery (VATS) has been established as the surgical approach of choice for lobectomy in patients with early-stage non-small cell lung cancer (NSCLC). Patients with clinical stage I NSCLC with no lymph node metastasis are considered candidates for VATS lobectomy. To rule out the presence of metastasis to lymph nodes or distant organs, patients should undergo meticulous clinical staging. Assessing patients' functional status is required to ensure that there are no medical contraindications, such as impaired pulmonary function or cardiac comorbidities. Although various combinations of the number, size, and location of ports are available, finding the best method of port placement for each surgeon is fundamental to maximize the efficiency of the surgical procedure. When conducting VATS lobectomy, it is always necessary to comply with the following oncological principles: (1) the vessels and bronchus of the target lobe should be individually divided, (2) systematic lymph node dissection is mandatory, and (3) touching the lymph node itself and rupturing the capsule of the lymph node should be minimized. Most surgeons conduct the procedure in the following sequence: (1) dissection along the hilar structure, (2) fissure division, (3) perivascular and peribronchial dissection, (4) individual division of the vessels and bronchus, (5) specimen retrieval, and (6) mediastinal lymph node dissection. Surgeons should obtain experience in enhancing the exposure of the dissection target and facilitating dissection. This review article provides the basic principles of the surgical techniques and practical maneuvers for performing VATS lobectomy easily, safely, and efficiently.

Keywords: Lung neoplasms, Video-assisted thoracic surgery, Lobectomy

Introduction

During the past 3 decades, video-assisted thoracoscopic surgery (VATS) has been established as the gold-standard surgical approach for lobectomy in patients with early-stage non-small cell lung cancer (NSCLC). Due to the tremendous efforts of pioneers in this field [1-7], thoracic surgeons have been increasingly adopting VATS lobectomy [8,9]. Evidence has accumulated that the early and late outcomes of VATS are comparable or even superior to those of open thoracotomy [1-17]. Several recent large-scale database analyses have shown that VATS lobectomy can be conducted with improved short-term outcomes [18-25] and favorable long-term survival compared with open thoracotomy lobectomy [26]. Therefore, VATS lobectomy is now strongly recommended for patients without surgical and medical contraindications unless the oncological principles

of surgery are compromised. This review article provides the basic principles of the surgical techniques and practical maneuvers for performing VATS lobectomy easily, safely, and efficiently.

Definition and indications

Despite various modifications in the surgical techniques of VATS lobectomy, the most widely accepted definition was established by the CALGB 39082 trial as a procedure including a 4- to 8-cm access incision and a totally endoscopic approach, without rib spreading and individual anatomical dissection and division of the pulmonary vein, artery, and bronchus [7].

The most important prerequisite of successful VATS lobectomy is to select optimal patients with tumor features suitable for a minimally invasive surgical approach. Con-



ventionally, most patients with clinical stage I NSCLC without lymph node metastasis can be considered candidates for VATS lobectomy. However, the tumor/node/metastasis classification system by the American Joint Committee on Cancer has been updated to the eighth edition, where tumors larger than 4 cm and 5 cm without nodal involvement are classified as stage IIA and IIB, respectively. Therefore, even clinical stage IIA or IIB NSCLC tumors classified using the tumor size criterion can be considered as candidates for VATS lobectomy as long as no nodal or distant organ metastases are present. Nonetheless, debate continues regarding the size barrier at which the VATS approach is discouraged. Although some surgeons argue that tumors larger than 7 cm, which are classified as stage T4 or IIIA, can be safely and effectively removed using the VATS approach, an issue exists regarding whether oncological principles can be satisfied with this minimally invasive approach for such large tumors that show biological aggressiveness [27]. The most commonly used size limit is 6–7 cm. Alternatively, many investigators have attempted to expand the indication of VATS lobectomy. Some adopted the VATS approach for node-positive NSCLC, and others have tried it after neoadjuvant therapy [28–37]. We should be cautious when extending the indications of the VATS approach since it could lead to an increased risk of procedure-related recurrence due to the possibility of cancer dissemination during VATS manipulation, the risk of leaving residual tumors at the surgical margin, and the apprehension of performing insufficient lymph node dissection [11].

Patient assessment and preparation

To rule out metastasis to lymph nodes or distant organs, patients should undergo meticulous clinical staging. Staging workups include computed tomography (CT) of the chest and upper abdomen and positron emission tomography–CT with 18F-fluorodeoxyglucose. When these tests suggest mediastinal nodal metastasis, patients should be evaluated using mediastinoscopy. However, mediastinoscopy has recently been replaced with less invasive procedures, such as endobronchial and/or endoscopic ultrasonography, and then transbronchial or transesophageal needle aspiration biopsy is performed for histological confirmation. Brain magnetic resonance imaging is needed to assess the presence of brain metastasis, especially if patients have headaches or neurological symptoms. Bronchoscopy should be performed to evaluate the presence of endobronchial lesions in patients with centrally located tu-

mors.

Apart from the tumor characteristics, assessing patients' functional status is required to ensure that no medical contraindications exist, such as impaired pulmonary function or cardiac comorbidities. Baseline pulmonary function is assessed using spirometry, and echocardiography can be performed to assess baseline cardiac function. The essential component for predicting preoperative and postoperative pulmonary function is forced expiratory volume in 1 second (FEV1). More importantly, the diffusing capacity of carbon monoxide (DLco) is critical for predicting the risk of postoperative pulmonary complications. When the postoperative FEV1 or DLco measurement is less than 40% of the predicted value, surgery should be declined, regardless of whether the VATS approach is used [38]. When the predicted postoperative FEV1 or DLco value is marginal (i.e., 40%–60%), suggesting a moderate risk of postoperative pulmonary complications, patients should be further evaluated using exercise tests, such as the 6-minute walk test or oxygen consumption test [38,39].

General anesthesia and positioning

Single-lung ventilation using a double-lumen endotracheal tube is mandatory to achieve an excellent surgical exposure and operative view. The anesthesiologist should ensure that the double-lumen endotracheal tube is in the correct position, and then ventilation can be maintained only in the contralateral lung to optimize deflation of the ipsilateral lung. If the lung does not effectively deflate, suction is occasionally applied. The respiratory rate can be increased to 20 breaths/min or more to achieve a more stable operative view since a decrease in the tidal volume by increasing the respiratory rate could reduce the degree of mediastinal deviation due to ventilation. During single-lung ventilation, maintaining adequate oxygenation is difficult even in patients with preserved pulmonary function because a ventilation–perfusion mismatch intrinsically occurs due to continuous perfusion to the non-ventilated lung. Whenever hypoxia occurs, temporarily pausing the procedure and then permitting double-lung ventilation until the hypoxic state is corrected would be better. Otherwise, anesthesiologists tend to apply high-pressure ventilation to the contralateral lung under single-lung ventilation, which would in turn put the patient at a higher risk of postoperative lung injury.

Following the induction of single-lung ventilation and general anesthesia, the patient is placed in the lateral decubitus position. The hands are placed unsupported in the

“prayer” position in front of the face. The operating table is adjusted to flex the patient adequately to maximize intercostal space widening. During this maneuver, care should be taken not to overextend the shoulder and elbow, which could result in brachial plexus injury. Since changing the patient’s position could cause the double-lumen endotracheal tube to deviate from the proper position, the anesthesiologist should recheck the placement of the endotracheal tube immediately after the patient is rotated into the lateral decubitus position. The position of the surgeon depends on the surgeon’s preferences for the surgical approach and port placement.

Port placement

Various port placement options have been devised and modified by several surgeons. With adequate port placement, the surgical procedure can be smooth and easy. However, if port placement is inadequate, easy cases might become technically challenging, which might adversely affect the degree to which the procedure follows oncological principles. Therefore, finding an effective method of port placement that best fits and is comfortable for each surgeon is fundamental to maximize the efficiency of the surgical procedure. Various combinations of the number, size, and location of ports are available. Conventionally, a 4- to 5-cm utility incision accompanied by a 5- to 10-mm port for the thoracoscope and a 5-mm additional port for left-hand instruments is made [12]. The location of the ports depends on the surgical approach (anterior versus posterior) and thoracoscopic view (conventional panoramic view versus direct hilar view) (Fig. 1). Some pioneers in the field have recently attempted to reduce the number of ports, and uniportal or biportal VATS lobectomy is now widely adopted by several surgeons [40,41].

Main procedure

Despite these technical variations, especially in port placement, the following oncological principles should always be complied with: (1) the vessels and bronchus of the target lobe should be individually divided, (2) systematic lymph node dissection is mandatory, and (3) touching the lymph node itself and rupturing the capsule of the lymph node should be minimized. Although there could be modifications, most surgeons conduct the procedure in the following sequence: (1) dissection along the hilar structure, (2) fissure division, (3) perivascular and peribronchial dissection, (4) individual division of the vessels and bronchus, (5) specimen retrieval, and (6) mediastinal lymph node dissection. Although some anatomical variations could exist according to the target lobe to be resected in VATS lobectomy, the general principles of dissection techniques along the hilar structure and perivascular/peribronchial space are the same across the target lobes. In principle, surgeons should obtain experience in enhancing the exposure of the dissection target and facilitating the dissection.

The anterior surface of the vessel is usually easy to dissect since we can see it directly, whereas the posterior surface of the vessel is difficult to dissect because achieving direct exposure is difficult. Therefore, to enhance the exposure, especially in the posterior surface of the vascular structure, critical maneuvers should be kept in mind. For example, gently grasping the target vessel with soft-surfaced endoscopic forceps or graspers could provide better exposure of the area behind the structure (Fig. 2). Considering that the pulmonary artery is easier to tear or injure than the pulmonary vein, special care should be taken when grasping the pulmonary artery. For this maneuver, we can imagine how a lioness never hurts her cub if she gently holds it with her sharp teeth. Another method to enhance the exposure of the posterior area is to lift the ves-

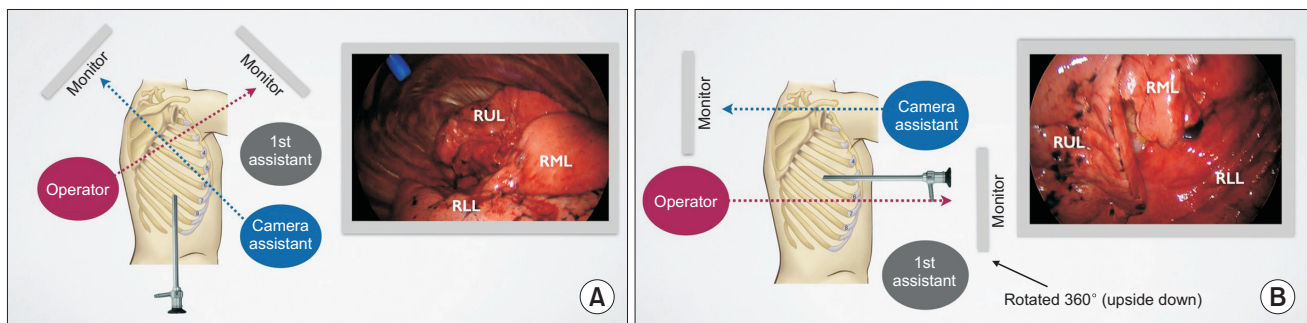


Fig. 1. The location of the ports depends on the thoracoscopic view. (A) Conventional panoramic view. (B) Direct hilar view. RUL, right upper lobe; RML, right middle lobe.

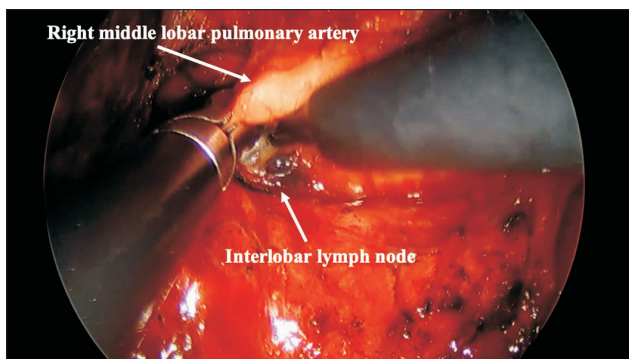


Fig. 2. Gentle grasping of the pulmonary artery using an instrument. Gently grasping the target vessel with soft-surfaced endoscopic forceps or graspers could provide better exposure of the area behind the structure.

sel using various instruments, such as graspers, an electrocautery tip, and a suction device. After clearing the soft tissue around the anterior and posterior surfaces of the target vessel, instruments (e.g., a right-angled clamp and endoscopic stapler) can be easily and safely passed along.

Several useful methods exist to facilitate hilar and perivascular dissection, including bimanual dissection, holding the shaft of the instruments short, digging or tunneling, and spreading. First, for effective dissection, coordinating 2 hands is crucial. If the surgeon uses only 1 hand, dissection will become more difficult and unsafe. Unless the surgeon has only 1 hand, the dissection will be more effective if the surgeon takes advantage of the non-dominant hand (the left hand if one is right-handed and vice versa). Constant practice in daily life is necessary to get used to using one's non-dominant hand. Second, it feels unexpectedly effective if one holds the shaft of every instrument, not its handle. In the VATS procedure, a fulcrum effect always occurs since there is a long distance between the port entrance and the target structure. If one holds the instrument rather short or even in the middle, the fulcrum is shortened, and then the dissection process becomes much easier (Fig. 3). Third, if the surgeon identifies the appropriate plane after the initial dissection, further dissection can be easily conducted, as if he or she is digging or tunneling using 2 instruments of both hands. In the same context, one can make the dissection safer and more effective by spreading out the jaws of the graspers. Finally, it is crucial to keep in mind the principle that one should conduct peribronchial dissection rather than perivascular dissection every time one dissects a vessel. If one focuses on perivascular dissection too much, dissection could be more difficult and dangerous since it is possible to denude the




Fig. 3. One should hold the shaft of the instrument short to reduce the fulcrum effect. If one holds the instrument rather short or even in the middle, the fulcrum is also shortened, and the dissection process then becomes much easier.

surface of the vessel, especially in elderly patients with fragile vascular walls. Alternatively, if one simply focuses on peribronchial dissection, not perivascular dissection, and then assesses the lymph nodes around the bronchus, one might eventually realize that perivascular dissection is conducted after completing the peribronchial dissection.

Although VATS lobectomy is easy to perform in cases of complete interlobar fissure, partially complete or totally incomplete fissures are often identified. For partially complete fissures, bidirectionally dissecting the plane is helpful. Imagine the situation of playing around the seashore as a child making a sand tunnel. During this activity, we carefully dissect the sand in one way first and then in the opposite way, not to destroy the tunnel. As with the sand tunnel, it will be much safer if one completely dissects around the surrounding structure bidirectionally before encircling the fissure and even any vital structures. However, for totally incomplete fissures, adopting a completely different approach is necessary, such as the fissureless technique or the hilar-first technique [42]. In this situation, one must dissect the hilar structure first and then divide the pulmonary vein and arteries, followed by the bronchus, and divide the fissure last. Before one attempts this technique, it is crucial to gain experience through practice and to reach a complete understanding of the anatomy.

Conventionally, the sequence of the division of bronchovascular structures is as follows: pulmonary vein, pulmonary artery, and then the lobar bronchus. Theoretically, the pulmonary-vein-first technique prevents tumor cells from spreading into the systemic circulation, which could result from surgical manipulation, whereas the pulmonary-artery-first technique can cause tumor cells to spread into the systemic circulation via the intact pulmonary vein [43]. Some investigators have shown that the ligation of the pulmonary vein first during surgery may help prevent blood

micro-metastases [44]. However, in another randomized controlled trial comparing long-term survival according to the sequence of pulmonary vessel ligation, no significant differences were found between the 2 groups [45]. Conversely, early division of the pulmonary vein can cause venous congestion of the target lobe, leading to difficulties in exposure, manipulation, and specimen removal after the main procedure. However, there is still no consensus regarding the sequence of the division of the vascular structures, and further studies should be conducted before drawing firm conclusions.

Conclusion

As minimally invasive techniques, such as the VATS approach, have been introduced into the field of surgical treatment of lung cancer, patients have been able to benefit from less invasive surgical approaches with lower morbidity and higher recovery, without compromising oncological outcomes. Nonetheless, the VATS approach is only a method for surgically treating patients, not a purpose per se. Assessing the indications for VATS lobectomy and preparing patients before surgery are crucial for obtaining excellent outcomes. To conduct VATS lobectomy safely and effectively, it is of fundamental importance to keep in mind the principles of the procedure and to practice the procedure regularly.

Conflict of interest

No potential conflict of interest relevant to this article was reported.

ORCID

Hong Kwan Kim: <https://orcid.org/0000-0002-7815-3336>

References

- Kirby TJ, Mack MJ, Landreneau RJ, Rice TW. *Lobectomy: video-assisted thoracic surgery versus muscle-sparing thoracotomy: a randomized trial.* J Thorac Cardiovasc Surg 1995;109:997-1002.
- Sugi K, Kaneda Y, Esato K. *Video-assisted thoracoscopic lobectomy achieves a satisfactory long-term prognosis in patients with clinical stage IA lung cancer.* World J Surg 2000;24:27-31.
- McKenna RJ Jr, Houck W, Fuller CB. *Video-assisted thoracic surgery lobectomy: experience with 1,100 cases.* Ann Thorac Surg 2006;81:421-6.
- Onaitis MW, Petersen RP, Balderson SS, et al. *Thoracoscopic lobectomy is a safe and versatile procedure: experience with 500 consecutive patients.* Ann Surg 2006;244:420-5.
- Shigemura N, Akashi A, Funaki S, et al. *Long-term outcomes after a variety of video-assisted thoracoscopic lobectomy approaches for clinical stage IA lung cancer: a multi-institutional study.* J Thorac Cardiovasc Surg 2006;132:507-12.
- Mun M, Kohno T. *Efficacy of thoracoscopic resection for multifocal bronchioloalveolar carcinoma showing pure ground-glass opacities of 20 mm or less in diameter.* J Thorac Cardiovasc Surg 2007;134:877-82.
- Swanson SJ, Herndon JE 2nd, D'Amico TA, et al. *Video-assisted thoracic surgery lobectomy: report of CALGB 39802: a prospective, multi-institution feasibility study.* J Clin Oncol 2007;25:4993-7.
- Whitson BA, Andrade RS, Boettcher A, et al. *Video-assisted thoracoscopic surgery is more favorable than thoracotomy for resection of clinical stage I non-small cell lung cancer.* Ann Thorac Surg 2007;83:1965-70.
- Flores RM, Park BJ, Dycoco J, et al. *Lobectomy by video-assisted thoracic surgery (VATS) versus thoracotomy for lung cancer.* J Thorac Cardiovasc Surg 2009;138:11-8.
- Villamizar NR, Darrabie MD, Burfeind WR, et al. *Thoracoscopic lobectomy is associated with lower morbidity compared with thoracotomy.* J Thorac Cardiovasc Surg 2009;138:419-25.
- Yan TD, Black D, Bannon PG, McCaughan BC. *Systematic review and meta-analysis of randomized and nonrandomized trials on safety and efficacy of video-assisted thoracic surgery lobectomy for early-stage non-small-cell lung cancer.* J Clin Oncol 2009;27:2553-62.
- Kim K, Kim HK, Park JS, et al. *Video-assisted thoracic surgery lobectomy: single institutional experience with 704 cases.* Ann Thorac Surg 2010;89:S2118-22.
- Scott WJ, Allen MS, Darling G, et al. *Video-assisted thoracic surgery versus open lobectomy for lung cancer: a secondary analysis of data from the American College of Surgeons Oncology Group Z0030 randomized clinical trial.* J Thorac Cardiovasc Surg 2010;139:976-83.
- D'Amico TA, Niland J, Mamet R, Zornosa C, Dexter EU, Onaitis MW. *Efficacy of mediastinal lymph node dissection during lobectomy for lung cancer by thoracoscopy and thoracotomy.* Ann Thorac Surg 2011;92:226-32.
- Hanna WC, de Valence M, Atenafu EG, et al. *Is video-assisted lobectomy for non-small-cell lung cancer oncologically equivalent to open lobectomy?* Eur J Cardiothorac Surg 2013;43:1121-5.
- Kuritzky AM, Aswad BI, Jones RN, Ng T. *Lobectomy by video-assisted thoracic surgery vs muscle-sparing thoracotomy for stage I lung cancer: a critical evaluation of short- and long-term outcomes.* J Am Coll Surg 2015;220:1044-53.
- Mei J, Guo C, Xia L, et al. *Long-term survival outcomes of video-assisted thoracic surgery lobectomy for stage I-II non-small cell lung cancer are more favorable than thoracotomy: a propensity score-matched analysis from a high-volume center in China.* Transl Lung

- Cancer Res 2019;8:155-66.
18. Paul S, Altorki NK, Sheng S, et al. *Thoracoscopic lobectomy is associated with lower morbidity than open lobectomy: a propensity-matched analysis from the STS database.* J Thorac Cardiovasc Surg 2010;139:366-78.
 19. Paul S, Sedrakyan A, Chiu YL, et al. *Outcomes after lobectomy using thoracoscopy vs thoracotomy: a comparative effectiveness analysis utilizing the Nationwide Inpatient Sample database.* Eur J Cardiothorac Surg 2013;43:813-7.
 20. Boffa DJ, Dhamija A, Kosinski AS, et al. *Fewer complications result from a video-assisted approach to anatomic resection of clinical stage I lung cancer.* J Thorac Cardiovasc Surg 2014;148:637-43.
 21. Paul S, Isaacs AJ, Treasure T, Altorki NK, Sedrakyan A. *Long term survival with thoracoscopic versus open lobectomy: propensity matched comparative analysis using SEER-Medicare database.* BMJ 2014;349:g5575.
 22. Falcoz PE, Puyraveau M, Thomas PA, et al. *Video-assisted thoracoscopic surgery versus open lobectomy for primary non-small-cell lung cancer: a propensity-matched analysis of outcome from the European Society of Thoracic Surgeon database.* Eur J Cardiothorac Surg 2016;49:602-9.
 23. Laursen LO, Petersen RH, Hansen HJ, Jensen TK, Ravn J, Konge L. *Video-assisted thoracoscopic surgery lobectomy for lung cancer is associated with a lower 30-day morbidity compared with lobectomy by thoracotomy.* Eur J Cardiothorac Surg 2016;49:870-5.
 24. Medbery RL, Gillespie TW, Liu Y, et al. *Nodal upstaging is more common with thoracotomy than with VATS during lobectomy for early-stage lung cancer: an analysis from the National Cancer Data Base.* J Thorac Oncol 2016;11:222-33.
 25. Pages PB, Delpy JP, Orsini B, et al. *Propensity score analysis comparing videothoracoscopic lobectomy with thoracotomy: a French nationwide study.* Ann Thorac Surg 2016;101:1370-8.
 26. Yang CJ, Kumar A, Klapper JA, et al. *A national analysis of long-term survival following thoracoscopic versus open lobectomy for stage I non-small-cell lung cancer.* Ann Surg 2019;269:163-71.
 27. Yan TD, Cao C, D'Amico TA, et al. *Video-assisted thoracoscopic surgery lobectomy at 20 years: a consensus statement.* Eur J Cardiothorac Surg 2014;45:633-9.
 28. Dell'Amore A, Lomangino I, Tamburini N, et al. *Video-assisted thoracoscopic lobectomy after neoadjuvant chemotherapy for non-small cell lung cancer: a multicenter propensity-matched study.* Surg Endosc 2021 Mar 19 [Epub]. <https://doi.org/10.1007/s00464-021-08431-z>.
 29. Deng HY, Qiu XM, Zhu DX, Tang X, Zhou Q. *Video-assisted thoracoscopic sleeve lobectomy for centrally located non-small cell lung cancer: a meta-analysis.* World J Surg 2021;45:897-906.
 30. Gao HJ, Jiang ZH, Gong L, et al. *Video-assisted vs thoracotomy sleeve lobectomy for lung cancer: a propensity matched analysis.* Ann Thorac Surg 2019;108:1072-9.
 31. Kamel MK, Nasar A, Stiles BM, Altorki NK, Port JL. *Video-assisted thoracoscopic lobectomy is the preferred approach following induction chemotherapy.* J Laparoendosc Adv Surg Tech A 2017;27:495-500.
 32. Kim HK, Choi YS, Kim J, Shim YM, Kim K. *Outcomes of unexpected pathologic N1 and N2 disease after video-assisted thoracic surgery lobectomy for clinical stage I non-small cell lung cancer.* J Thorac Cardiovasc Surg 2010;140:1288-93.
 33. Romero Roman A, Campo-Canaveral de la Cruz JL, Macia I, et al. *Outcomes of surgical resection after neoadjuvant chemioimmunotherapy in locally advanced stage IIIA non-small-cell lung cancer.* Eur J Cardiothorac Surg 2021;60:81-8.
 34. Xie D, Zhong Y, Deng J, et al. *Comparison of uniportal video-assisted thoracoscopic versus thoracotomy bronchial sleeve lobectomy with pulmonary arterioplasty for centrally located non-small-cell lung cancer.* Eur J Cardiothorac Surg 2021;59:978-86.
 35. Yang CF, Meyerhoff RR, Mayne NR, et al. *Long-term survival following open versus thoracoscopic lobectomy after preoperative chemotherapy for non-small cell lung cancer.* Eur J Cardiothorac Surg 2016;49:1615-23.
 36. Yun JK, Lee GD, Choi S, et al. *Video-assisted thoracoscopic lobectomy is feasible for selected patients with clinical N2 non-small cell lung cancer.* Sci Rep 2020;10:15217.
 37. Yun JK, Park I, Kim HR, et al. *Long-term outcomes of video-assisted thoracoscopic lobectomy for clinical N1 non-small cell lung cancer: a propensity score-weighted comparison with open thoracotomy.* Lung Cancer 2020;150:201-8.
 38. Postmus PE, Kerr KM, Oudkerk M, et al. *Early and locally advanced non-small-cell lung cancer (NSCLC): ESMO Clinical Practice Guidelines for diagnosis, treatment and follow-up.* Ann Oncol 2017; 28(suppl_4):iv1-21.
 39. Lee H, Kim HK, Kang D, et al. *Prognostic value of 6-min walk test to predict postoperative cardiopulmonary complications in patients with non-small cell lung cancer.* Chest 2020;157:1665-73.
 40. Gonzalez-Rivas D, Parabela M, Fieira E, Velasco C. *Single-incision video-assisted thoracoscopic lobectomy: initial results.* J Thorac Cardiovasc Surg 2012;143:745-7.
 41. Rocco G, Martin-Ucar A, Passera E. *Uniportal VATS wedge pulmonary resections.* Ann Thorac Surg 2004;77:726-8.
 42. Decaluwe H, Sokolow Y, Deryck F, et al. *Thoracoscopic tunnel technique for anatomical lung resections: a 'fissure first, hilum last' approach with staplers in the fissureless patient.* Interact Cardiovasc Thorac Surg 2015;21:2-7.
 43. Wei S, Guo C, He J, et al. *Effect of vein-first vs artery-first surgical technique on circulating tumor cells and survival in patients with non-small cell lung cancer: a randomized clinical trial and registry-based propensity score matching analysis.* JAMA Surg 2019;154: e190972.
 44. Song PP, Zhang W, Zhang B, Liu Q, DU J. *Effects of different se-*

quences of pulmonary artery and vein ligations during pulmonary lobectomy on blood micrometastasis of non-small cell lung cancer. Oncol Lett 2013;5:463-8.

45. Kozak A, Alchimowicz J, Safranow K, et al. *The impact of the se-*

quence of pulmonary vessel ligation during anatomic resection for lung cancer on long-term survival: a prospective randomized trial. Adv Med Sci 2013;58:156-63.