



**Case Report**

**Concurrent Diagnosis of Acute Myeloid Leukemia and Symptomatic COVID-19 Infection: a Case Report Successfully Treated with Azacitidine-Venetoclax Combination**

Daniela Taurino<sup>1</sup>, Marco Frigeni<sup>1</sup>, Anna Grassi<sup>1</sup>, Gianluca Cavallaro<sup>1</sup>, Silvia Salmoiraghi<sup>1</sup>, Orietta Spinelli<sup>1</sup>, Alessandro Rambaldi<sup>1,2</sup> and Federico Lussana<sup>1</sup>.

<sup>1</sup> Hematology and Bone Marrow Transplant Unit, ASST Papa Giovanni XXIII, Bergamo, Italy.

<sup>2</sup> Department Oncology and Hematology, Università degli Studi di Milano, Milano, Italy.

**Competing interests:** The authors declare no conflict of Interest.

**Abstract.** SARS-COV2 pandemic has caused profound challenges in health care systems worldwide. Patients affected by hematological neoplasms appear to be particularly at risk of developing COVID-19 complications, with unfavorable outcomes.

Here, we present the case of a 57-years-old woman diagnosed with severe COVID-19 pneumonia and concurrent acute myeloid leukemia (AML). At the time of diagnosis, it was decided to postpone leukemia therapy to enable adequate COVID-19 pneumonia treatment. When her conditions related to pneumonia improved, the combination of Azacitidine-Venetoclax was used as first-line treatment instead of conventional intensive chemotherapy. At the end of the first two cycles, the patient showed complete remission, and a post-remission consolidation with allogeneic hematopoietic stem cell transplantation has been planned.

This case suggests that Azacytidine-Venetoclax induction may represent a valid and safe alternative to intensive chemotherapy in the challenging setting of patients with a concomitant diagnosis of AML and severe COVID-19 infection.

**Keywords:** Acute myeloid leukemia; COVID-19; Venetoclax. Azacitidine; Pneumonia.

**Citation:** Taurino D., Frigeni M., Grassi A., Cavallaro G., Salmoiraghi S., Spinelli O., Rambaldi A., Lussana F. Concurrent diagnosis of acute myeloid leukemia and symptomatic COVID-19 infection: a case report successfully treated with Azacitidine-Venetoclax combination. *Mediterr J Hematol Infect Dis* 2021, 13(1): e2021057, DOI: <http://dx.doi.org/10.4084/MJHID.2021.057>

**Published:** September 1, 2021

**Received:** June 30, 2021

**Accepted:** August 14, 2021

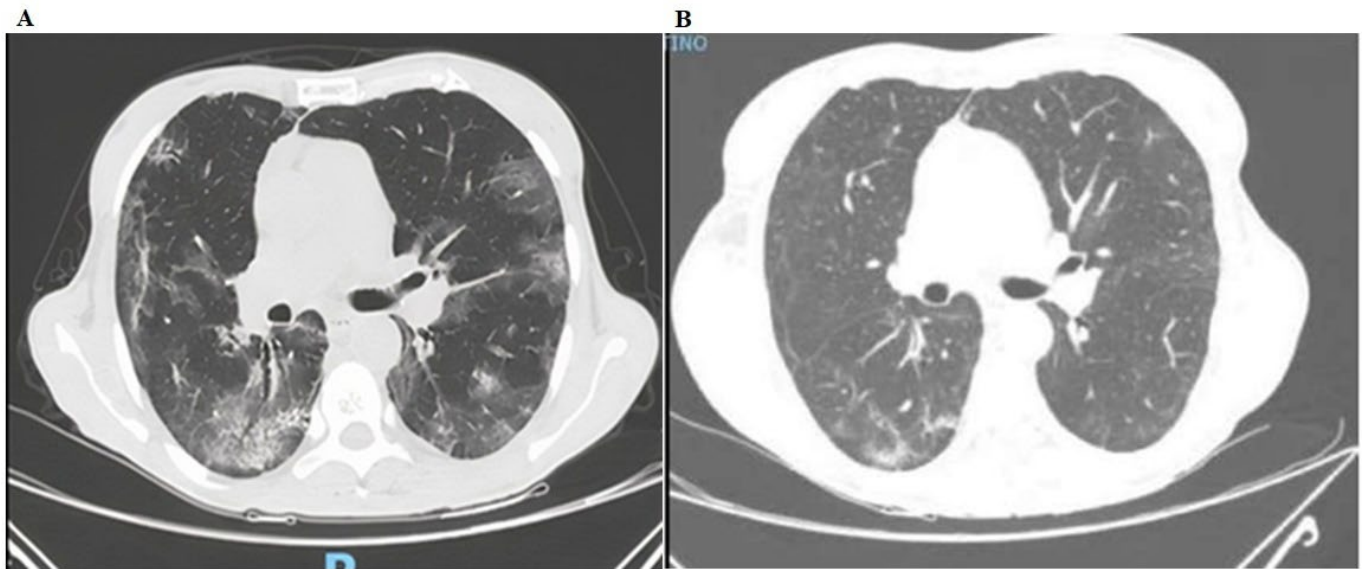
This is an Open Access article distributed under the terms of the Creative Commons Attribution License (<https://creativecommons.org/licenses/by-nc/4.0>), which permits unrestricted use, distribution, and reproduction in any medium, provided the original work is properly cited.

Correspondence to: Daniela Taurino, Hematology and Bone Marrow Transplant Unit, ASST Papa Giovanni XXIII, Piazza OMS, 1, 24127, Bergamo, Italy. Tel. +390352673684 - E-mail: [dtaurino@asst-pg23.it](mailto:dtaurino@asst-pg23.it)

**Introduction.** Since SARS-COV2 infection was declared a pandemic, it has profoundly impacted the health system worldwide, challenging established algorithms to manage many diseases, including hematological malignancies. Older and immunocompromised populations appear to be at a higher risk for severe complications related to COVID-19 than the general population, with a more significant number of patients admitted to intensive care units requiring invasive ventilation or death.<sup>1</sup> As showed by Chinese nationwide analysis, cancer patients are 3.5

times more likely to develop severe SARS-COV2 pneumonia than the cancer-free population.<sup>2</sup> Therefore, the clinical management of cancer patients is complicated by considerable uncertainty about the risks and benefits of treatment while the infection is ongoing.

Acute myeloid leukemia (AML) patients with less than 70 years and without comorbidities are usually candidates to receive induction chemotherapy and often allogeneic transplantation (allo-HSCT) as optimal consolidation therapy.<sup>3</sup> This type of therapy often leads to prolonged cytopenia, making patients more



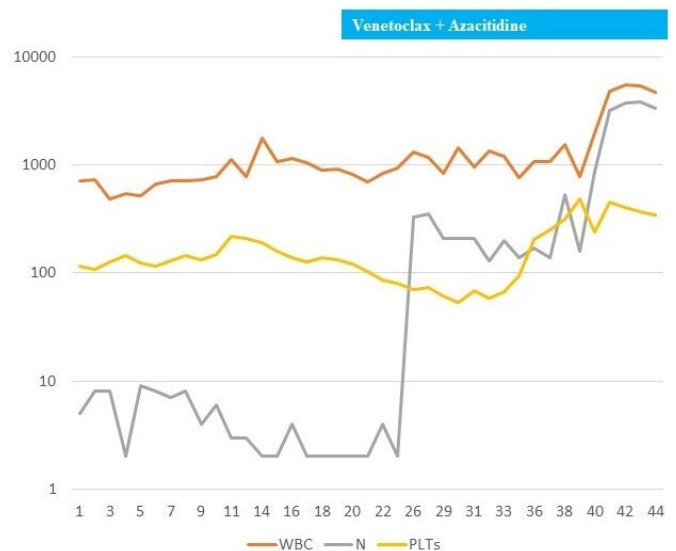
**Figure 1.** (A) Chest computer tomography (CT) showing SARS-COV2 pneumonia with bilateral patchy ground-glass opacities. (B) After four months from the diagnosis, the Chest CT of the same patient shows almost complete resolution of radiological findings.

susceptible to infectious complications.<sup>4</sup>

In the coming months, a sizeable number of AML patients may be expected to experience SARS-COV2 infection either at diagnosis or during the disease course, with a potentially substantial impact on the possibility of receiving the optimal standard chemotherapy. Given the lack of evidence-based algorithms to guide clinicians in choosing the best therapeutic regimen and timing for treatment initiation for newly diagnosed patients with AML and concomitant symptomatic SARSCOV-2 infection, here we report an emblematic case.

**Case Report.** In November 2020, a 57-years-old woman with no significant medical history was referred to the emergency room for cough and dyspnea, prompting a SARS-COV-2 real-time polymerase chain reaction (RT-PCR) test, which resulted in positive results. Chest CT evidenced bilateral patchy ground-glass opacities, consistent with COVID-19 pneumonia (**Figure 1-A**). Blood tests showed severe neutropenia (neutrophils  $0.55 \times 10^9/L$ ), mild thrombocytopenia (platelets  $115 \times 10^9/L$ ), and anemia (Hb 50 g/L) (**Figure 2**). The patient was admitted to the intensive care unit (ICU), where she was immediately treated with piperacillin/tazobactam 4.5 g QID, posaconazole 300 mg QD, and dexamethasone per institutional guidelines for the treatment of COVID-19 pneumonia. Ventilatory support with continuous positive airway pressure (CPAP) and pronation cycles was also started without the need for intubation. Antibiotic therapy was continued for 41 days.

A bone marrow aspirate was performed to investigate the abnormal blood results, which were diagnostic for AML, with 69% blasts. The immunophenotype was positive for CD34, CD117, human leukocyte antigen DR isotype (HLADR), CD33, and weakly positive for CD13. Cytogenetic revealed a 46, XX normal karyotype and



**Figure 2.** Full blood count parameters are shown; white blood cell count (WBC, reference range  $0.49\text{--}5.51 \times 10^9/L$ ), neutrophils ( $0.02\text{--}3.88 \times 10^9/L$ ) and platelets ( $54\text{--}487 \times 10^9/L$ ). Venetoclax + Azacitidine administration, starting from day 20 onwards, is indicated by the blue bar.

molecular characterization by NGS an isocitrate dehydrogenase 2 (*IDH2*) mutation with *FLT3-ITD*, *NPM1*, *CEBPA* wild-type, therefore classifying the disease as AML not-otherwise-specified according to the WHO 2016 classification,<sup>5</sup> with an intermediate risk based on ELN 2017 recommendations.<sup>3</sup>

A contrast chest CT was performed due to a marked D-dimer increase on day two after ICU admission, showing bilateral pulmonary emboli and confirmed the bilateral ground-glass opacities already highlighted in the previous CT. Anticoagulant therapy with low-molecular-weight heparin (LMWH) was therefore added.

Upon multidisciplinary review, it was decided to postpone leukemia therapy to enable adequate COVID-

19 pneumonia treatment. The patient experienced progressive clinical improvement and requiring gradually decreased oxygen consumption. Oxygen weaning was obtained after 15 days after ICU admission. Despite the clinical improvement, the persistent positivity of the nasopharyngeal swab for RT-PCR for SARS-CoV2 was observed. Therefore, we decided to infuse two cycles of convalescent plasma collected from patients who had recovered from SARS-CoV2 disease,<sup>6-7</sup> unfortunately without achieving the clearance of the virus. A plausible explanation for the benefit of hyperimmune plasma is to provide immunity by giving patients virus-specific neutralizing antibodies, which might result in immediate clearance of SARS-CoV-2.<sup>8</sup>

Due to the persistent swab positivity for SARS-CoV-2 and the recent severe pneumonia and pulmonary embolism, the risk of a standard intensive chemotherapy induction was deemed unacceptable for this patient. Thus, based on the current data showing that *IDH1/2* mutations are responsive to venetoclax-based therapy,<sup>9-11</sup> a treatment with Azacytidine-Venetoclax was preferred and started 32 days after diagnosis. 5-Azacytidine was administered subcutaneously at 75 mg/m<sup>2</sup> once daily from day 1 to day 7. Venetoclax was administered orally, 100 mg day 1, 200 mg day 2, 300 mg day 3, 400 mg day 4 to be continued till day 28. Due to the well-known pharmacological interference of Venetoclax with azoles, posaconazole was replaced with micafungin at a dose of 50 mg QD. The patient tolerated the treatment exceptionally well, without hemorrhagic or infectious events. Complete recovery of blood counts was observed 46 days after treatment initiation (**Figure 2**), and antibiotic and antifungal therapy was suspended.

Notably, on day 18 of the cycle (the seventh week since the onset of COVID-19 infection), the nasal swab became finally negative, and the patient was discharged to complete the 28-day course of venetoclax at home. At the end of the cycle, a bone marrow evaluation showed marrow hypoplasia, with residual 6% myeloid blasts detected by immunophenotype.

After 19 days from the end of the first cycle, the patient received a second cycle of Azacytidine-Venetoclax. After seven days from the end of the second cycle, a bone marrow evaluation showed complete remission, and a post-remission consolidation with alloHSCT was planned. A new chest CT scan repeated four months later showed extensive resolution of lung infiltrates (**Figure 1-B**). An unrelated donor was identified, but the patient refused to undergo allogeneic transplantation. We, therefore, planned to continue Azacytidine-Venetoclax therapy until relapse or development of unacceptable toxicity. After the second cycle of treatment, a bone marrow evaluation was also performed, confirming the complete remission of the disease.

**Discussion.** Recent systematic reviews and pooled analysis showed that patients with cancer and COVID-19 have an increased risk of severe disease and mortality.<sup>12,13</sup> Desai et al.<sup>13</sup> found that increasing age, male sex, hematologic malignancy, and current anticancer therapy contributed to the increased mortality. Several studies have shown that T immunity plays a fundamental role in viral clearance.<sup>14</sup> In this regard, defective immunity due to both hematological disorders and chemotherapy may cause a worse prognosis with an increased risk of mortality due to COVID-19.<sup>15</sup>

In the pandemic era, the general recommendation in patients newly diagnosed with AML and concomitant SARS-CoV2 infection is to postpone all treatments that do not require urgent initiation, limiting cytoreductive therapies if necessary.<sup>16</sup> Although AML has always been considered a medical emergency needing prompt treatment intervention; nowadays, this dogma is changing according to the results of a real-world study showing no significant difference in the rate of complete remissions and overall survival after delaying treatment up to 15 days.<sup>17</sup>

Intensive chemotherapy with initial induction «7+3» regimen represents the backbone of upfront AML treatment in young patients intending to eradicate the disease. However, it is noteworthy that treating patients with concomitant COVID-19 requires an individual refinement of the standard therapeutic approach based on the clinical conditions. In this regard, the use of recently approved drugs in AML, such as the combination of hypomethylating agents and venetoclax,<sup>18</sup> should be considered due to their promising results in the incidence of complete remission and favorable safety profile.

Here, we reported the clinical management with venetoclax and azacytidine of a patient with a newly AML diagnosis with an *IDH2* mutation and severe COVID19 pneumonia. In this unique scenario where chemotherapy-induced pancytopenia could adversely affect outcomes, this case confirmed the high efficacy and safety profile of the venetoclax combination therapy. Furthermore, this case report highlights the usefulness of an accurate molecular characterization, especially in complex cases, and the emerging interest for different AML molecular patterns associated with favorable outcomes with venetoclax-based regimens. In this regard, although promising results were obtained in the front-line use of chemotherapy and *IDH1/2* inhibitors,<sup>19</sup> the Azacytidine-Venetoclax combination has been confirmed as a powerful treatment option for this subset of AML.

Of interest, our experience is entirely in keeping with a recent report of a patient with de novo *FLT3-ITD*-positive AML and severe COVID-19, safely treated with single-agent gilteritinib obtaining a complete remission.<sup>20</sup>

**Conclusions.** Treatment of AML in patients with concurrent COVID-19 infection remains challenging and calls a refinement of the standard therapeutic approach

into question. Therefore, the use of novel drugs approved in AML should be considered a valid alternative to standard chemotherapy for these frail patients.

## References:

1. Wu Z, McGoogan JM. Characteristics of and important lessons from the coronavirus disease 2019 (COVID-19) outbreak in china: summary of a report of 72 314 cases from the Chinese center for disease control and prevention. *JAMA* 2020; 323: 1239. <https://doi.org/10.1001/jama.2020.2648>
2. Liang W, Guan W, Chen R, et al. Cancer patients in SARS-CoV-2 infection: a nationwide analysis in China. *The Lancet Oncology* 2020; 21: 335-337. [https://doi.org/10.1016/S1470-2045\(20\)30096-6](https://doi.org/10.1016/S1470-2045(20)30096-6)
3. Döhner H, Estey E, Grimwade D, et al. Diagnosis and management of AML in adults: 2017 ELN recommendations from an international expert panel. *Blood* 2017; 129: 424-447. <https://doi.org/10.1182/blood-2016-08-733196>
4. Ferrara F, Schiffer CA. Acute myeloid leukemia in adults. *The Lancet* 2013; 381: 484-495. [https://doi.org/10.1016/S0140-6736\(12\)61727-9](https://doi.org/10.1016/S0140-6736(12)61727-9)
5. Arber DA, Orazi A, Hasserjian R, et al. The 2016 revision to the World Health Organization classification of myeloid neoplasms and acute leukemia. *Blood* 2016; 127: 2391-2405. <https://doi.org/10.1182/blood-2016-03-643544>
6. Mair-Jenkins J, Saavedra-Campos M, Baillie JK, et al. The Effectiveness of Convalescent Plasma and Hyperimmune Immunoglobulin for the Treatment of Severe Acute Respiratory Infections of Viral Etiology: A Systematic Review and Exploratory Meta-analysis. *J Infect Dis* 2015; 211: 80-90. <https://doi.org/10.1093/infdis/jiu396>
7. Chen L, Xiong J, Bao L, et al. Convalescent plasma as a potential therapy for COVID-19. *The Lancet Infectious Diseases* 2020; 20: 398-400. [https://doi.org/10.1016/S1473-3099\(20\)30141-9](https://doi.org/10.1016/S1473-3099(20)30141-9)
8. Ferrari S, Caprioli C, Weber A, et al. Convalescent hyperimmune plasma for chemo-immunotherapy induced immunodeficiency in COVID-19 patients with hematological malignancies. *Leukemia & Lymphoma* 2021; 62: 1490-1496. <https://doi.org/10.1080/10428194.2021.1872070>
9. DiNardo CD, Pratz KW, Letai A, et al. Safety and preliminary efficacy of venetoclax with decitabine or azacitidine in elderly patients with previously untreated acute myeloid leukemia: a non-randomized, open-label, phase 1b study. *The Lancet Oncology* 2018; 19: 216-228. [https://doi.org/10.1016/S1470-2045\(18\)30010-X](https://doi.org/10.1016/S1470-2045(18)30010-X)
10. Chan SM, Thomas D, Corces-Zimmerman MR, et al. Isocitrate dehydrogenase 1 and 2 mutations induce BCL-2 dependence in acute myeloid leukemia. *Nat Med* 2015; 21: 178-184. <https://doi.org/10.1038/nm.3788>
11. DiNardo CD, Tiong IS, Quaglieri A et al. Molecular patterns of response and treatment failure after front-line venetoclax combinations in older patients with AML. *Blood* 2020; 135: 791-803. <https://doi.org/10.1182/blood.2019003988>
12. Saini KS, Tagliamento M, Lambertini M, et al. mortality in patients with cancer and coronavirus disease 2019: A systematic review and pooled analysis of 52 studies. *European Journal of Cancer* 2020; 139: 43-50. <https://doi.org/10.1016/j.ejca.2020.08.011>
13. Desai A, Gupta R, Advani S, et al. mortality in hospitalized patients with cancer and coronavirus disease 2019: A systematic review and meta-analysis of cohort studies. *Cancer* 2021; 127: 1459-1468. <https://doi.org/10.1002/ncr.33386>
14. Chen Z, John Wherry E. T cell responses in patients with COVID-19. *Nat Rev Immunol* 2020; 20: 529-536. <https://doi.org/10.1038/s41577-020-0402-6>
15. Aries JA, Davies JK, Auer RL, et al. Clinical outcome of coronavirus disease 2019 in haemato-oncology patients. *Br J Haematol*; 190. Epub ahead of print July 2020. DOI: 10.1111/bjh.16852. <https://doi.org/10.1111/bjh.16852>
16. Zeidan AM, Boddu PC, Patnaik MM, et al. Special considerations in the management of adult patients with acute leukemias and myeloid neoplasms in the COVID-19 era: recommendations from a panel of international experts. *The Lancet Haematology* 2020; 7: e601-e612. [https://doi.org/10.1016/S2352-3026\(20\)30205-2](https://doi.org/10.1016/S2352-3026(20)30205-2)
17. Röhlig C, Kramer M, Schliemann C, et al. Does time from diagnosis to treatment affect the prognosis of patients with newly diagnosed acute myeloid leukemia? *Blood* 2020; 136: 823-830.
18. DiNardo CD, Jonas BA, Pullarkat V, et al. Azacitidine and Venetoclax in Previously Untreated Acute Myeloid Leukemia. *N Engl J Med* 2020; 383: 617-629. <https://doi.org/10.1056/NEJMoa2012971>
19. Stein EM, DiNardo CD, Fathi AT, et al. Ivosidenib or enasidenib combined with intensive chemotherapy in patients with newly diagnosed AML: a phase 1 study. *Blood* 2021; 137: 1792-1803. <https://doi.org/10.1182/blood.2020007233>
20. Wilson AJ, Troy-Barnes E, Subhan M, et al. Successful remission induction therapy with gilteritinib in a patient with de novo FLT3 - mutated acute myeloid leukemia and severe COVID-19. *Br J Haematol*; 190. Epub ahead of print August 2020. <https://doi.org/10.1111/bjh.16962>