

U-Fiber Leukoencephalopathy Due to a Novel Mutation in the *TACO1* Gene

Giacomo Sferruzza, MD, Andrea Del Bondio, PhD, Andrea Citterio, PhD, Paolo Vezzulli, MD, Simone Guerrieri, MD, Marta Radaelli, MD, PhD, Filippo Martinelli Boneschi, MD, PhD, Massimo Filippi, MD, PhD, Francesca Maltecca, PhD, Maria Teresa Bassi, PhD, and Marina Scarlato, MD, PhD

Correspondence

Dr. Scarlato
scarlato.marina@hsr.it

Neurol Genet 2021;7:e573. doi:10.1212/NXG.000000000000573

Translational activator of cytochrome c oxidase I (*TACO1*) is a mitochondrial translation factor involved in mitochondria-encoded cytochrome c oxidase subunit I (MT-CO1) synthesis.^{1,2} Loss-of-function mutations in the *TACO1* gene cause respiratory chain complex IV deficiency. Clinically heterogeneous human diseases are due to cytochrome c oxidase (COX) deficiency, ranging from Leigh syndrome to myopathy, deafness, or ataxia. Recently, 2 different *TACO1* mutations have been identified in 3 families with late-onset Leigh syndrome and a leukoencephalopathy involving predominantly basal ganglia and cystic changes.^{3,4} Here, we report a subject carrying a novel homozygous truncating mutation in the *TACO1* gene and presenting an adult-onset slowly progressive spastic paraparesis with cognitive impairment and a subcortical U-fiber leukoencephalopathy.

Case Presentation

The proband is a 50-year-old Italian woman with a 20-year history of slowly progressive spastic gait and mild cognitive impairment. No family history and no clear consanguinity have been reported. She has a daughter, now 24-years-old, healthy. Neurologic examination showed diffuse signs of upper motor neuron involvement and an impairment of executive functions in a context of low cognitive ability setting. Neither involuntary movements nor cerebellar dysfunction signs were present. Optical coherence tomography highlighted a significant bilateral temporal retinal nerve fiber layer thickness reduction. Brain MRI showed a white matter disease with an extensive symmetrical involvement of U-fibers (figure 1A). Laboratory panels (including creatine kinase and lactic acid) and EMG were unremarkable. In a 10-year follow-up, we observed a spastic gait worsening leading to the necessary use of 2 sticks, and a cognitive impairment progression in terms of perseveration and reduced speed in information processing. MRI follow-up displayed a brain atrophy increase.

Genetics and Functional Studies

Whole-exome sequencing was performed on the proband, her healthy sister, and daughter after written informed consent. Two variants in *TACO1* and mitochondrial distribution and morphology regulator 1 (*MSTO1*) were identified in the proband: a novel homozygous truncating change c.676G>T (p.Glu226Ter) in *TACO1* and c.833A>G (p.Tyr278Cys) (rs143029385) in *MSTO1* (freq. 0.04% in ExAC). None of the variants segregated in the sister, whereas the daughter is a carrier of the *TACO1* change (figure 1B). Based on this, we speculated that *TACO1* variant might be the disease-causing mutation. Functional studies demonstrated that the newly identified *TACO1* mutation is highly pathogenic. Indeed, sodium dodecyl sulfate–

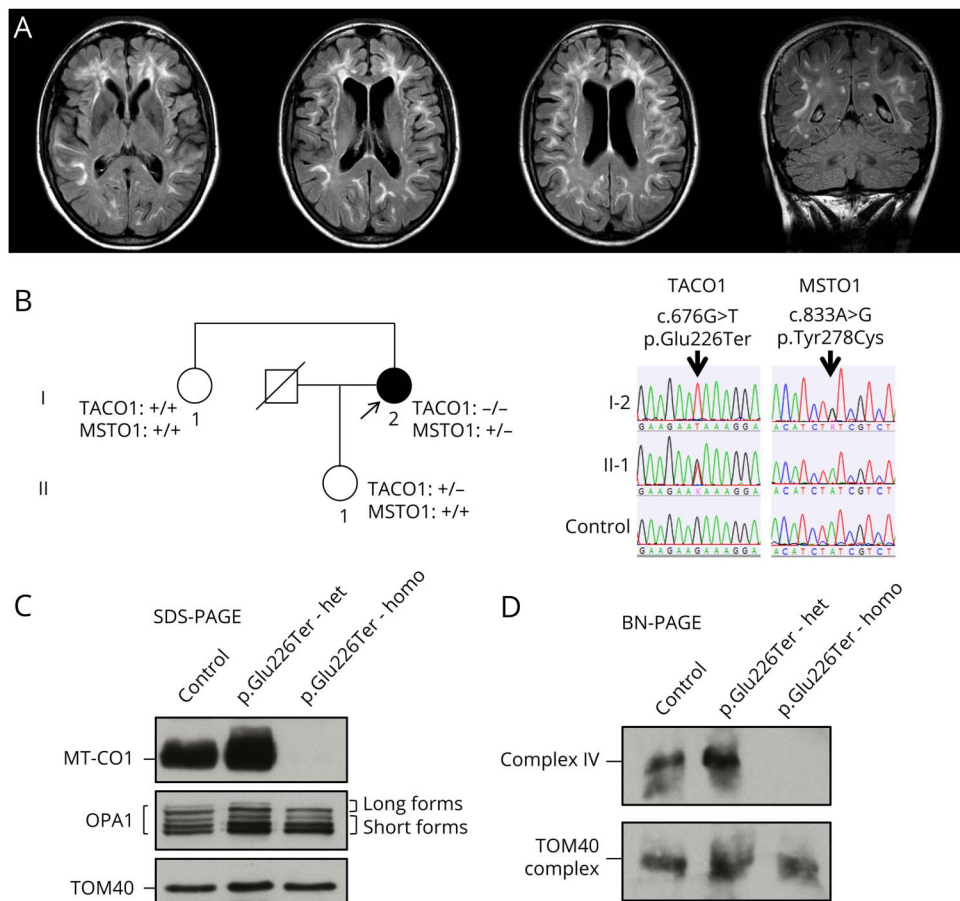
From the Department of Neurology (G.S., S.G., M.F., M.S.), and Mitochondrial Dysfunctions in Neurodegeneration Unit (A.D.B., F.M.), Division of Neuroscience, IRCCS San Raffaele Scientific Institute, Milan; Laboratory of Molecular Biology (A.C., M.T.B.), Scientific Institute IRCCS E. Medea, Bosisio Parini, Lecco; Department of Neuroradiology (P.V.), IRCCS San Raffaele Scientific Institute, Milan; Department of Neurology (M.R.), Papa Giovanni XXIII, Bergamo; Dino Ferrari Centre (F.M.B.), Neuroscience Section, Department of Pathophysiology and Transplantation (DEPT), University of Milan; and Fondazione IRCCS Ca' Granda Ospedale Maggiore Policlinico (F.M.B.), Neurology Unit and Multiple Sclerosis Center, Milan, Italy.

Go to [Neurology.org/NG](https://www.neurology.org/NG) for full disclosures. Funding information is provided at the end of the article.

The Article Processing Charge was funded by the authors.

This is an open access article distributed under the terms of the Creative Commons Attribution-NonCommercial-NoDerivatives License 4.0 (CC BY-NC-ND), which permits downloading and sharing the work provided it is properly cited. The work cannot be changed in any way or used commercially without permission from the journal.

Figure 1 Brain MRI, the Result of Sequence Analysis, SDS-PAGE, and BN-PAGE



(A) Brain MRIs showing multifocal confluent T2/FLAIR hyperintense lesions involving the supratentorial bihemispheric subcortical white matter, mainly located at the cortical-juxtacortical junction involving the U-fibers. Periventricular white matter is involved bilaterally, and the body of the corpus callosum showed few focal lesions. Hyperintense T2/FLAIR putaminal rim could be detected on both sides, involving the external capsule bilaterally. The cortex is preserved. After contrast injection, no area of enhancement could be picked up (not shown). Frontal subcortical lesions were partially necrotic on T1-weighted images. No focal lesions were detected at the level of the basal ganglia, as well as the brainstem and cerebellum. There is evidence of a mild brain atrophy, with a moderate ventricular system enlargement and prominent sulci at the vertex. MR spectroscopy did not show any abnormal findings (data not shown). (B) Family pedigree of the patient. Black and white symbols indicate the proband and healthy family members, respectively. Electropherograms of wild-type and mutated sequences are shown below. (C) SDS-PAGE and WB analysis of MT-CO1 and OPA1 normalized on translocase of outer mitochondrial membrane 40 (TOM40). (D) BN-PAGE and WB analysis of assembled COX (200 kDa) normalized on TOM complex (400 kDa). BN-PAGE = blue native polyacrylamide gel electrophoresis; COX = cytochrome c oxidase; FLAIR = fluid-attenuated inversion recovery; MSTO1 = mitochondrial distribution and morphology regulator 1; MT-CO1 = mitochondria-encoded cytochrome c oxidase subunit I; OPA1 = optic atrophy gene 1; SDS-PAGE = sodium dodecyl sulfate-polyacrylamide gel electrophoresis; TACO1 = translational activator of cytochrome c oxidase I; WB = Western blot.

polyacrylamide gel electrophoresis showed a striking reduction of MT-CO1 in patient fibroblasts compared with the heterozygous daughter and a healthy control (figure 1C). Destabilized MT-CO1 resulted in a fully compromised assembly of COX, as assessed by blue native polyacrylamide gel electrophoresis on isolated mitochondria from proband and control fibroblasts (figure 1D). To determine whether COX dysfunction could cause fragmentation of the mitochondrial network in the proband, we assayed mitochondrial morphology by live imaging microscopy in primary fibroblasts (supplemental data, links.lww.com/NXG/A400). Despite a mild reduction of optic atrophy gene 1 long forms, which are the active mediators of mitochondrial fusion (figure 1C), the proband displayed a mitochondrial network morphology comparable to controls, with the highest percentage of cells showing fused and interconnected organelles (figures e-1 and e-2, links.lww.com/NXG/A397). This finding also demonstrates that the

heterozygous *MSTO1* variant identified is likely not pathogenic, as it does not affect mitochondrial morphology.

Discussion

We reported a novel mutation in the *TACO1* gene causing a striking reduction in the MT-CO1 synthesis and compromised COX assembly in fibroblasts. Complex IV, the last enzyme of the mitochondrial respiratory chain, catalyzes electrons transfer to the final acceptor O₂ for adenosine triphosphate synthesis.⁵ Three of the 14 COX subunits are encoded by mitochondrial DNA (mtDNA), and their synthesis is regulated by different nuclear genes like *TACO1*.² To date, this is the third *TACO1* homozygous mutation reported. In the first and second one,^{3,4} a juvenile-onset Leigh-like disease was described with wide symptom variability also within the same family. We expanded the clinical

and neuroradiologic spectrum associated with *TACO1* mutations, reporting a non-Turkish woman with a novel clinical and neuroradiologic phenotype. Subcortical arcuate U-fibers are among the slowest and latest myelinating fibers, with a reduced rate of myelin turnover; therefore, they are generally spared in other inherited leukodystrophies,⁶ except for Alexander and Canavan disease. In mitochondrial disorders, white matter involvement is a common feature. Usually, lesions caused by mtDNA point mutation predominantly affect deep gray matter with minor peripheral white matter involvement, whereas diffuse necrotic or cystic changes associated with brain atrophy are frequently observed in patients with Leigh disease due to mutation in nuclear genes encoding for complex I or IV and assembly factor. Late-onset and slow progressing neurologic manifestations make the described case an uncommon variant of COX deficiency spectrum disorder⁷ and are apparently in contrast with functional data showing a markedly reduced COX activity in fibroblasts. This discrepancy highlights the complex protein interactions involved in COX synthesis and assembly, which are probably tissue and development specific.

Acknowledgment

The authors thank the patient and her family for participating in the study and Valentina Baderna for the technical support in functional studies.

Study Funding

This work was supported by Italian Ministry of Health, RF-2016-02361610 (F.M.) and RC 2018-2020 (M.T.B.), and by the Fondazione Regionale per la Ricerca Biomedica, grant ID, Care4NeuroRare (M.T.B.).

Disclosure

The authors report no disclosures relevant to the manuscript. Go to Neurology.org/NG for full disclosures.

Publication History

Received by *Neurology: Genetics* September 29, 2020. Accepted in final form January 12, 2021.

Appendix Authors

Name	Location	Contribution
Giacomo Sferuzza, MD	IRCCS San Raffaele Scientific Institute, Milan, Italy	Drafting/revision of the manuscript for content; major role in the acquisition of data; study concept or design; and analysis or interpretation of data

Appendix (continued)

Name	Location	Contribution
Andrea Del Bondio, PhD	IRCCS San Raffaele Scientific Institute, Milan, Italy	Major role in the acquisition of data and revised the manuscript
Andrea Citterio, PhD	Scientific Institute IRCCS E. Medea, Bosisio Parini, Italy	Major role in the acquisition of data and revised the manuscript
Paolo Vezzulli, MD	IRCCS San Raffaele Scientific Institute, Milan, Italy	Major role in the acquisition of data and revised the manuscript
Simone Guerrieri, MD	IRCCS San Raffaele Scientific Institute, Milan, Italy	Major role in the acquisition of data and revised the manuscript
Marta Radaelli, MD, PhD	Papa Giovanni XXIII, Bergamo, Italy	Acquired the data and revised the manuscript
Filippo Martinelli Boneschi, MD, PhD	University of Milan, Milan, Italy Fondazione IRCCS Ca' Granda Ospedale Maggiore Policlinico, Milan, Italy	Acquired the data and revised the manuscript
Massimo Filippi, MD, PhD	IRCCS San Raffaele Scientific Institute, Milan, Italy	Acquired the data and revised the manuscript
Francesca Maltecca, PhD	IRCCS San Raffaele Scientific Institute, Milan, Italy	Drafting/revision of the manuscript for content; major role in the acquisition of data; study concept or design; and analysis or interpretation of data
Maria Teresa Bassi, PhD	Scientific Institute IRCCS E. Medea, Bosisio Parini, Italy	Drafting/revision of the manuscript for content; major role in the acquisition of data; study concept or design; and analysis or interpretation of data
Marina Scarlato, MD, PhD	IRCCS San Raffaele Scientific Institute, Milan, Italy	Drafting/revision of the manuscript for content; major role in the acquisition of data; study concept or design; and analysis or interpretation of data

References

1. Weraarpachai W, Antonicka H, Sasarman F, et al. Mutation in *TACO1*, encoding a translational activator of COX I, results in cytochrome c oxidase deficiency and late-onset Leigh syndrome. *Nat Genet* 2009;41:833–837.
2. Richman TR, Spahr H, Ermer JA, et al. Loss of the RNA-binding protein *TACO1* causes late-onset mitochondrial dysfunction in mice. *Nat Commun* 2016;7:11884.
3. Seeger J, Schrank B, Pyle A, et al. Clinical and neuropathological findings in patients with *TACO1* mutations. *Neuromuscul Disord* 2010;20:720–724.
4. Oktay Y, Gungör S, Zeltner L, et al. Confirmation of *TACO1* as a Leigh syndrome disease gene in two additional families. *J Neuromuscul Dis* 2020;7:301–308.
5. Mansilla N, Racca S, Gras DE, Gonzalez DH, Welchen E. The complexity of mitochondrial complex IV: an update of cytochrome c oxidase biogenesis in plants. *Int J Mol Sci* 2018;19:662.
6. Riley KJ, O'Neill DP, Kralik SF. Subcortical U-fibers: signposts to the diagnosis of white matter disease. *Neurographics* 2018;8:234–243.
7. DiMauro S, Tanji K, Schon EA. The many clinical faces of cytochrome c oxidase deficiency. *Adv Exp Med Biol* 2012;748:341–357.