

Inflammation and infection

Scrotal abscess as a manifestation of posterior duodenal perforation; a very rare presentation

Wan Aldohuky^a, Ayad Ahmad Mohammed^{b,*}^a Duhok Directorate General of Health, Azadi Teaching Hospital, Duhok City, Kurdistan Region, Iraq^b University of Duhok, College of Medicine, Department of Surgery, Duhok City, Kurdistan Region, Iraq

ARTICLE INFO

Keywords:

Peptic ulcer
Abdominal pain
Perforated duodenal ulcer
Scrotal abscess
Posterior duodenal ulcer
Case report

ABSTRACT

Posterior perforation of duodenal ulcers is very rare; the infection may spread from the retroperitoneal space to the scrotum.

A 75-year-old male presented with painful right scrotal swelling for 2 days associated with fever. During abdominal examination there was abdominal tenderness and scrotal swelling and tenderness.

CT scan of the abdomen showed large amount of air collection in the retroperitoneal space extending to the right scrotum with contrast media passing to the retroperitoneum and right scrotum.

Laparotomy done and there was a perforation in the posterior wall of the duodenum, suturing done and right scrotal abscess drained.

Introduction

Perforation is a well known complication of duodenal ulcers, most of them occur in the anterior duodenal wall with intraperitoneal spillage and signs of peritonitis. Pain is the most frequent symptom which is felt in the epigastric region and radiated to the back then the pain become generalized in the abdomen, fever is present in almost all patients, other symptoms include anorexia, nausea, and vomiting. Perforation at the anterior duodenal wall is the commonest, posterior perforation is rare and in such cases the fluid may track through the retroperitoneal tissue planes or the para-colic space causing loin or back pain, retro-colic abscess, retroperitoneal abscess, or the inflammatory fluid may extend along the psoas muscle to the inguinal region or to the scrotum in extremely rare occasions.¹

Rarely in case of large perforations large amount of air may pass to the retroperitoneal space and may pass down to the scrotum resulting in pneumoscrotum or scrotal abscess.²

Case presentation

A 75-year-old male patient presented with painful right scrotal swelling for 2 days. The scrotal swelling and the pain increased gradually over 2 days and was associated with fever and rigor. The patient had

history of diabetes mellitus which was controlled with medications and dietary modifications.

During examination the pulse rate was 110 beats/minute, the blood pressure was 100/60 mmHg, and the temperature was 39° Celsius. During abdominal examination there was central abdominal and suprapubic tenderness and scrotal examination showed redness, tenderness and increased scrotal temperature. The clinical findings were consistent with epididymo-orchitis. The white blood cells count was elevated (20000 cells per microliter) mostly neutrophils. Ultrasound of the scrotum showed normal testis with thick fluid collection around the testis making the diagnosis of infective process the most likely. The patient received parenteral antibiotics with little improvement.

On the 4th day the patient developed anorexia, nausea, severe abdominal pain, backache, and fever and rigor. On abdominal examination there was tenderness and guarding all over the abdomen. Abdominal X-ray in erect position showed mild bilateral pleural effusions and dilated loops of the small bowel. Abdominal ultrasound showed collection of fluid at the pelvic cavity. The serum amylase and lipase were normal.

CT scan of the abdomen showed large amount of air collection in the retroperitoneal space displacing the right kidney toward the midline and extending to the right scrotum. And CT- scan with oral contrast showed tracking of the contrast media to the retroperitoneum and extending to

* Corresponding author. University of Duhok, College of Medicine, Department of Surgery, Azadi Teaching Hospital, 8 Nakhoshkhana Road, 1014 AM, Duhok City, DUHOK, Kurdistan Region, Iraq.

E-mail address: ayad.mohammed@uod.ac (A.A. Mohammed).

<https://doi.org/10.1016/j.eucr.2019.101010>

Received 1 July 2019; Accepted 4 September 2019

Available online 5 September 2019

2214-4420/© 2019 The Authors.

Published by Elsevier Inc.

This is an open access article under the CC BY-NC-ND license

(<http://creativecommons.org/licenses/by-nc-nd/4.0/>).

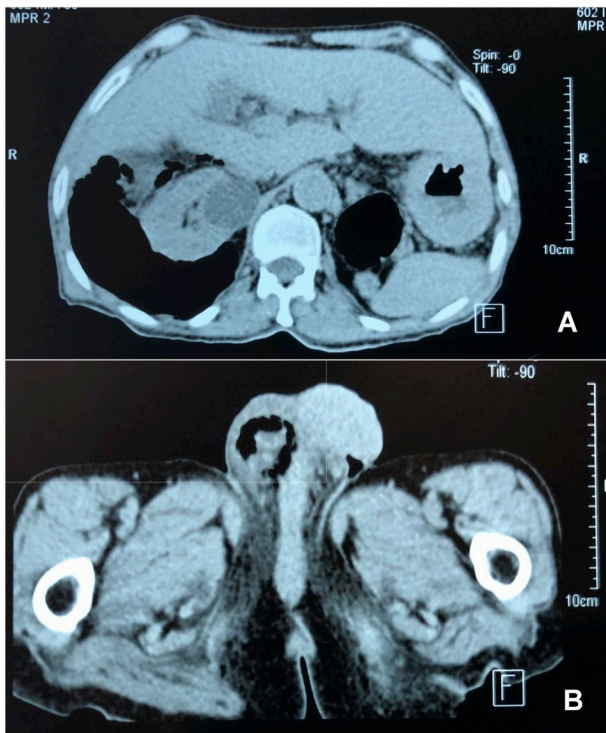


Fig. 1. CT-scan of the abdomen showing large amount of air in the retroperitoneal space extending to the right scrotum.

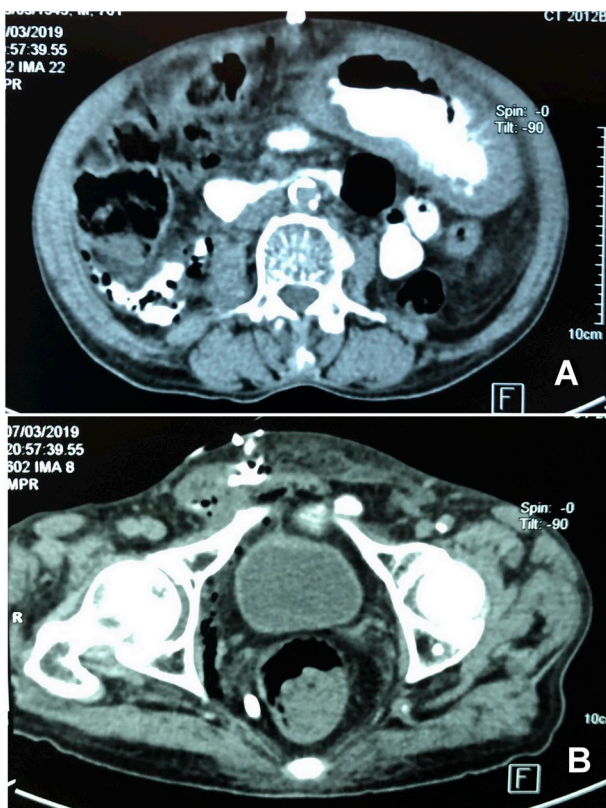


Fig. 2. CT-scan of the abdomen with oral contrast showing the contrast media tracking outside the bowel and passing to the retroperitoneum and the right scrotum.

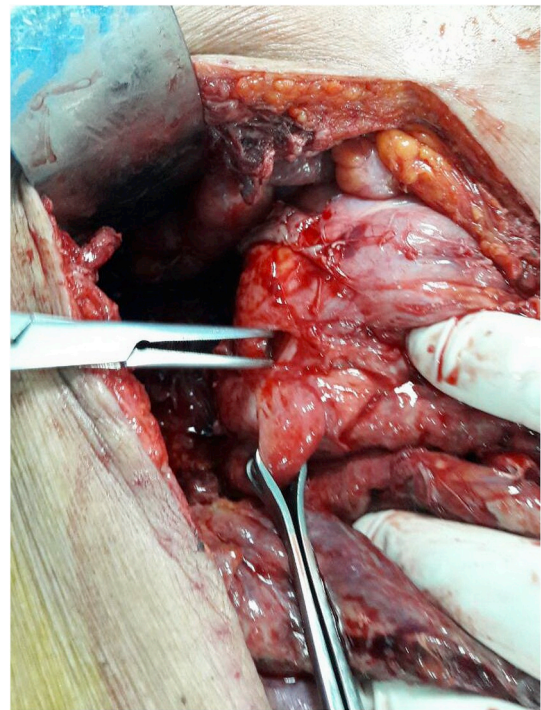


Fig. 3. Intraoperative picture showing the perforation at the posterior wall of the duodenum.

the right scrotum. [Figs. 1 and 2.](#)

Laparotomy done through midline abdominal incision, there was large amount of thin pus in the peritoneal cavity with air and fluid collection in the retroperitoneal space.

Initial intraoperative evaluation of the small bowel and large bowel showed no abnormality, the lesser sac opened and the posterior wall of the stomach was intact.

Mobilization of the duodenum done and there was a perforation in the posterior wall of the duodenum, [Fig. 3](#), suturing done with slowly absorbable suture material, the peritoneal cavity washed with warm normal saline and 2 drains left in the abdomen. The patient admitted to the intensive care unit for 2 days. The clinical condition improved and the drains removed on the 5th day. In the 8th postoperative day the patient developed complete abdominal dehiscence with right scrotal abscess, another surgery done for the patient and the abdomen closed with tension sutures with drainage of the scrotal abscess.

The general clinical situation improved and the patient discharged after 10 days. The tension sutures were removed after 3 weeks with improvement of both the clinical and the imaging studies after that.

Discussion

Perforating posterior duodenal ulcers open to the retroperitoneal space, it causes sever local inflammatory reaction, in cases of small perforations there may be spontaneous sealing of the perforation when the edges of the ulcer become adherent to the local tissues and the fibrin start to close the perforation. The diagnosis of the retroperitoneal duodenal perforation is very challenging to the surgeons and the radiologists due to the hidden location of the retroperitoneal space and the delayed clinical presentation and obscure findings on clinical examination.¹

When the condition diagnosed late it results in serious septic complications and even death, the infection may be very severe specially in the immunocompromised patients which may result in Fournier's gangrene.²

The diagnosis of this rare condition is mostly done during surgery, in

a review of 25 cases with posterior perforation of the duodenum, only one case was diagnosed preoperatively and the rest diagnosed during surgery, most patients have septic complications due to late diagnosis which result in very high mortality rates.³

The best diagnostic tool is CT scan which may be able to diagnose the source of the leak especially when contrast agents are being used, the contrast may track to the retroperitoneal space and extend to the scrotum.⁴

Advances in the medical treatment specially the use of the potent proton pump inhibitors had led to dramatic reduction in the rate of the complications of peptic ulcer diseases, in perforated ulcers the treatment priority is stabilization of the general condition of the patient and control of sepsis. Surgery is the main management option which should include closure of the site of the perforation and removal of the pus and septic fluid. Broad spectrum antibiotics are usually required. Scrotal sepsis may respond to medical treatment but when abscess developed, it should be drained.⁵

Appendix A. Supplementary data

Supplementary data to this article can be found online at <https://doi.org/10.1016/j.eucr.2019.101010>.

References

1. Hashmonai M, et al. Retroperitoneal perforation of duodenal ulcers with abscess formation. Report of four cases and survey of the literature. *Ann Surg.* 1971;173(3): 409.
2. Watson HS, Klugo RC, Coffield KS. Pneumoscrotum: report of two cases and review of mechanisms of its development. *Urology.* 1992;40(6):517–521.
3. Rajasekar A, Macintyre I. Retroperitoneal perforation of duodenal ulcer presenting as scrotal sepsis. *Int J Clin Pract.* 1998;52(1):60–61.
4. Dagur G, et al. Critical manifestations of pneumoscrotum. *Curr Urol.* 2015;9(2): 62–66.
5. Siu WT, et al. Laparoscopic repair for perforated peptic ulcer: a randomized controlled trial. *Ann Surg.* 2002;235(3):313.