



Contents lists available at ScienceDirect

International Journal of Surgery Case Reports

journal homepage: www.casereports.com

Temporary banking of the nipple-areola complex in breast reconstruction following mastectomy for gigantomastia

Yoshihiro Sowa*, Tomoko Hori, Takuya Kodama, Toshiaki Numajiri

Departments of Plastic and Reconstructive Surgery, Kyoto Prefectural University of Medicine, Graduate School of Medical Sciences, Kawaramachi-Hirokoji Kajii-cho 465, Kamigyo-ku, Kyoto, 602-8566, Japan

ARTICLE INFO

Article history:

Received 25 October 2020
Received in revised form 6 November 2020
Accepted 7 November 2020
Available online 12 November 2020

Keywords:

Gigantomastia
Nipple-areola complex
Breast reconstruction
Mastectomy
Medical tattooing

ABSTRACT

INTRODUCTION: Gigantomastia is a breast disorder characterized by exaggerated rapid growth of the breasts, generally bilaterally. In some severe cases, mastectomy is required to ensure safe delivery or control disease progression or recurrence. Subsequently, most patients want to undergo breast reconstruction, including the nipple-areola complex (NAC).

PRESENTATION OF CASE: Here, we report our experience with temporary banking of the NAC in a patient who underwent mastectomy for severe Gigantomastia. Each NAC was temporarily transplanted into the axilla as banking tissue for NAC reconstruction at a later date. Although the color of the NAC was slightly lighter after reconstruction, it mainly kept its original color and texture in addition to medical tattooing technique. At present, there has been no recurrence and the patient is fully satisfied with her appearance.

DISCUSSION: In this case, mastectomy was recommended because of an unbearable breast size that disturb a safety delivery, as well as respiratory and cardiac complications and skin ulcer control. Because the disease is not pathologically malignant, temporary preservation of NAC allows it to be safely used again for later nipple reconstruction.

CONCLUSION: Temporary banking of the nipple-areola complex in breast reconstruction following breast resection including NAC, would be one of good surgical options for benign breast tumors like gigantomastia.

© 2020 Published by Elsevier Ltd on behalf of IJS Publishing Group Ltd. This is an open access article under the CC BY-NC-ND license (<http://creativecommons.org/licenses/by-nc-nd/4.0/>).

1. Introduction

As first reported by Palmuth in 1648 [1], gigantomastia (GGM) is an uncommon clinical condition characterized by fast, unusual, and painful breast growth during pregnancy. Women with GGM can experience extreme discomfort and morbidity. In some severe cases, surgical treatment is required because the condition shows ulceration, infection, and areas of local necrosis, which may cause severe maternal disorder and even mortality [2].

The etiology of GGM is unclear, but endocrine imbalance, hyperprolactinemia, and target organ hypersensitivity have been suggested as causes [3,4]. The choice of treatment varies based on the severity and gestation time [4]. In some severe cases, breast reduction or mastectomy may be required as surgical management to promote safe delivery or control disease progression or recurrence. Subsequently, most patients desire breast reconstruction.

The nipple-areola complex (NAC) in patients with GGM can be preserved because it is not pathologically malignant. Thus, temporary banking of the NAC for use in breast reconstruction following

mastectomy is possible. Here, we report our experience with temporary NAC banking in a patient who underwent mastectomy for severe GGM.

2. Main body

A 27-year-old woman noticed bilateral breast enlargement that gradually increased 3 years before pregnancy. After she became pregnant, further marked enlargement occurred, and she was referred from another hospital (Fig. 1a). Her medical history included asthma and systemic lupus erythematosus (SLE). An evaluation of the patient led to diagnosis of asthma, and she received budesonide. The chest circumference was 109 cm, and a sonography examination was normal except for fibrocystic findings. Stereotactic mammotome biopsy (ST-MMT) was performed for suspected granulomatous mastitis, but no granulomatous inflammation was found. Thus, the patient was diagnosed with GGM. During pregnancy, her breast size continued to increase and gradually caused symptoms such as dyspnea due to hypertrophy of the breast, and breast pain. Breast skin ulceration also developed (Fig. 1b), but a culture test was negative for microorganism growth. Given the risk of infection of skin ulcers and poor control of SLE with steroids, we determined that it was better to control the volume of

* Corresponding author.
E-mail address: sowawan@kpu-m.ac.jp (Y. Sowa).

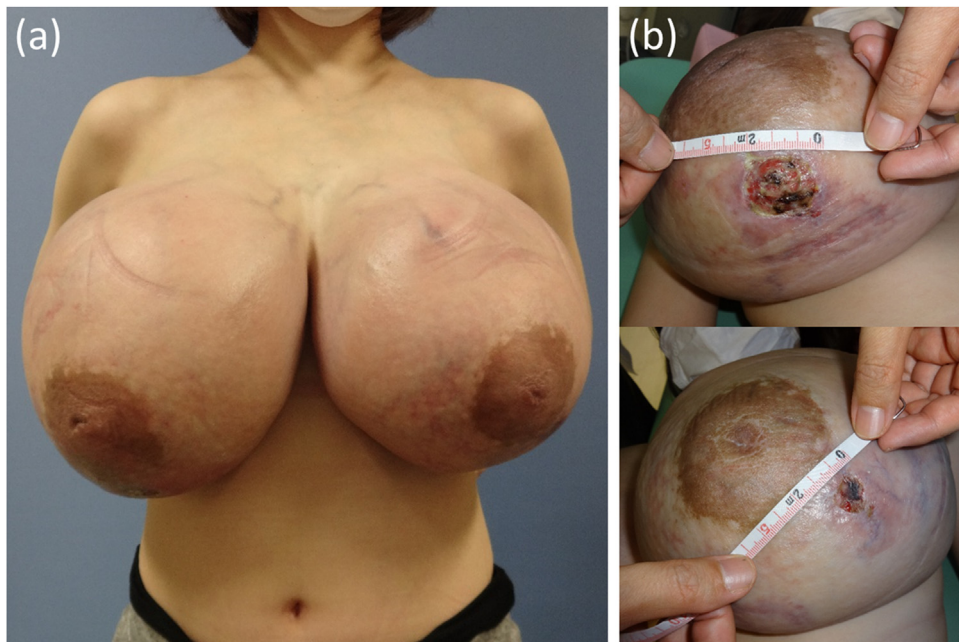


Fig. 1. A 27-year-old woman at 20 weeks' gestation presented with massive breast hypertrophy (a) and ulceration on lower pole of breast (b).

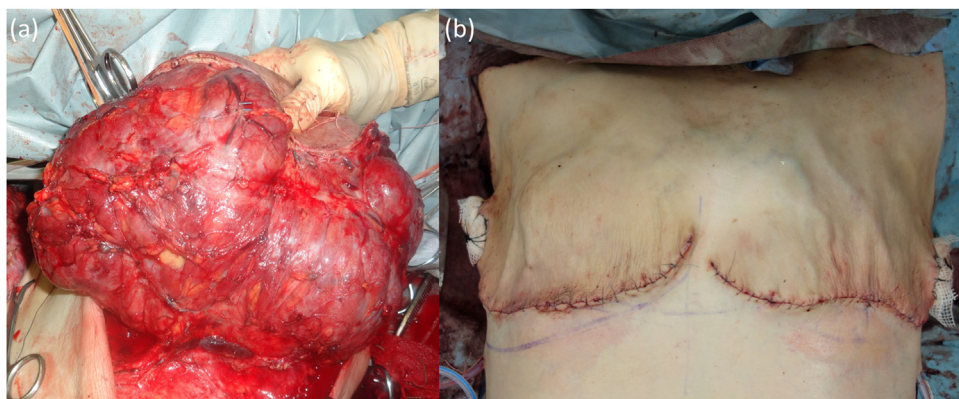


Fig. 2. Intraoperative photographs of tumor resection (a) and subsequent wound closure along the inframammary fold (IMF) (b).

breast tissue before the condition worsened for the safety of both the fetus and mother.

Based on the judgment that mastectomy and two-stage breast reconstruction were safer than breast reduction, which tends to cause bleeding and recurrence, total mastectomy was performed (Fig. 2a). The surgical approach for mastectomy was made with an inframammary fold (IMF) incision. The flap in the upper chest was preserved. The suture was made along the IMF to make the scar less noticeable (Fig. 2b). The veins were inflated and several skin ulcers were found intraoperatively so the breast skin could only be minimally preserved. However, fortunately the NAC was not ulcerated and could be preserved. The NAC was temporarily transplanted into the axilla as banked tissue for subsequent NAC reconstruction.

The postoperative course was uneventful. One week after the operation, venous distension disappeared, and there were no asthma attacks. Control of SLE improved and the steroid dose was reduced. The patient was discharged 12 days after the operation. Pathology findings indicated fibrocystic changes, increased stroma, and CD34-positive cells, which were consistent with the preoperative diagnosis. Within 10 weeks after mastectomy, the patient had an uneventful transvaginal delivery.

Ten months after delivery, delayed two-stage reconstruction with breast implants was performed. A tissue expander was inserted beneath the pectoralis major muscle to dilate the skin of the anterior chest, and nine months later the expander was replaced with a silicone breast implant. At the same time, each NAC banked in the axilla was transplanted into the appropriate location (Fig. 3). The tie-over method was used for tissue fixation of the NAC transplant. The color of each NAC was slightly lighter, but largely the original color and texture were retained (Fig. 4a). Three months later, some medical tattooing was partially added on the region where the color was faded, reducing these problems a bit. In addition, 3D tattooing technique was used on the right nipple (Fig. 4b). At present, there are no findings suggesting recurrence, and the patient is fully satisfied with her appearance.

3. Discussion

The primary palliative treatment for patients with GGM is improving adverse conditions affecting pregnancy and reducing pain and the risk of severe complications to the mother [3]. Effective drug treatment is limited, and surgical procedures including reduc-

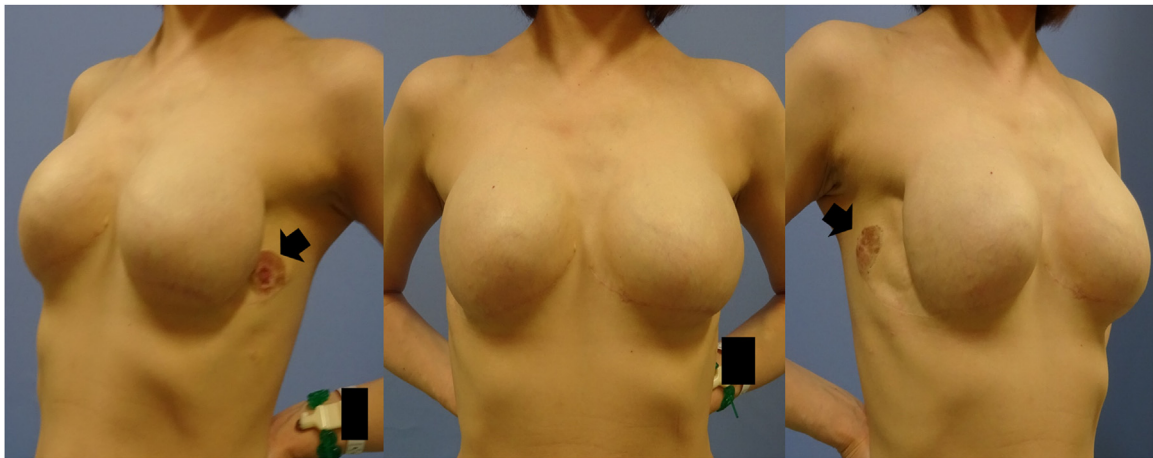


Fig. 3. Postpartum two-stage breast reconstruction with tissue expanders and silicone breast implants. The nipple-areola complex (NAC) is temporarily transplanted into the axilla as banked tissue material. Black colored arrows show temporary banking of the nipple-areola complex.

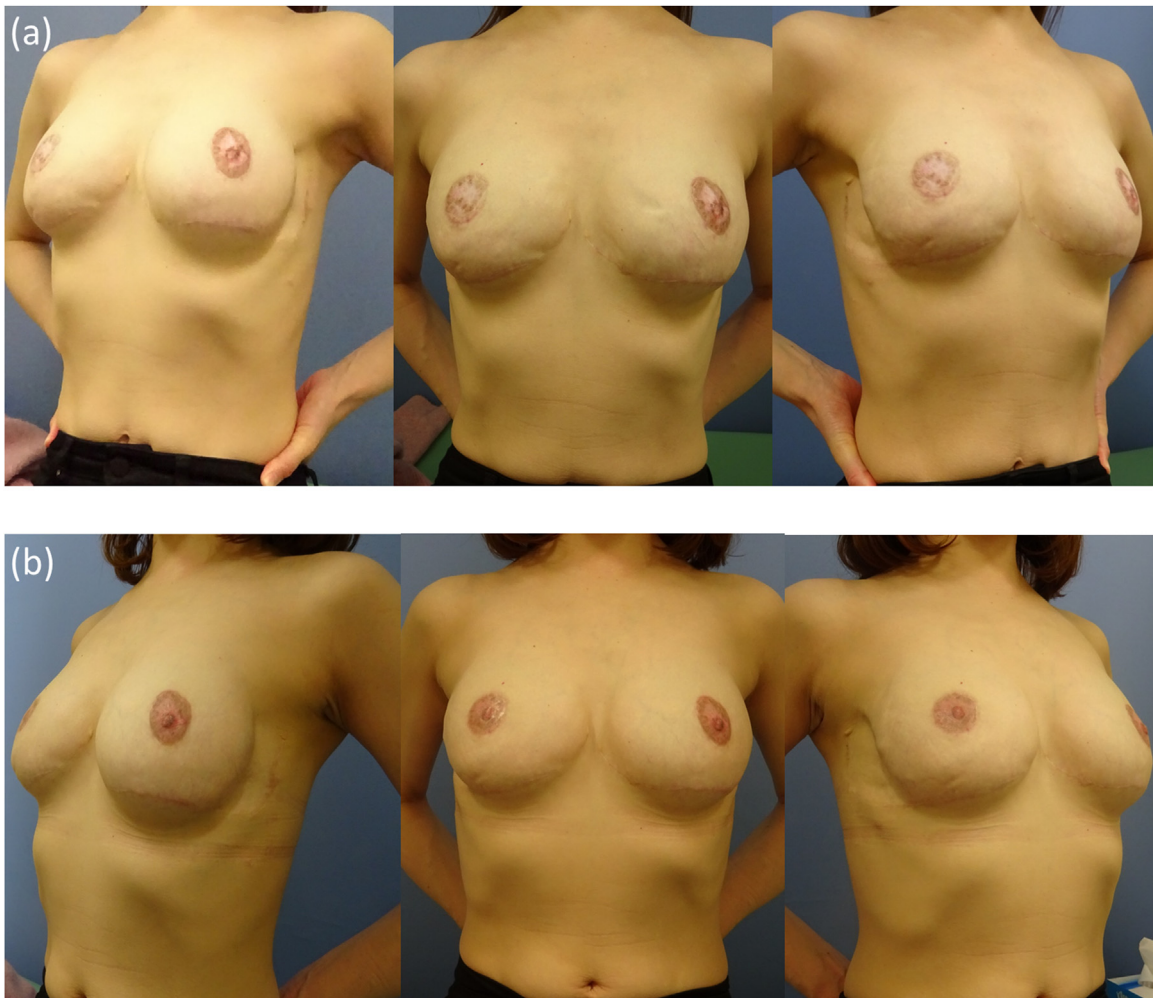


Fig. 4. Postoperative outcome at 6 months (a) and 14 months (b) after NAC reconstruction.

tion mammoplasty and mastectomy remain as the better option [5], although spontaneous involution can occur in some cases. The decision to perform total mastectomy may be based on an unbearable breast size that is not reduced after delivery, as well as respiratory and cardiac complications and skin ulcer control.

Following the increase in size of the breasts, ulcerations, infections, and areas of local necrosis may cause severe maternal morbidity and even mortality [6]. Moreover, considering the high possibility of recurrence during a subsequent pregnancy, total mastectomy may be recommended, rather than reduction

mammoplasty, if the patient desires future pregnancy [5]. However, in surgery for a breast tumor, removal of the NAC can have a negative aesthetic and emotional impact on the patient. Consequently, the appearance of the reconstructed NAC is critical to the overall quality of breast reconstruction.

In our case, ulcerations were found at the first clinical visit. Similar ulceration that caused problems in delivery in cases of gestational GGM has been described by Ezem et al. [6]. We selected mastectomy because it is relatively minimally invasive and allows for safer reconstruction. The patient also had a strong desire for breast reconstruction, including the NAC. Two-stage breast reconstruction followed by NAC reconstruction were chosen to avoid the concern of residual tumor tissue, although this is rarely a problem in a non-malignant case.

Temporary NAC banking has already been used in breast cancer surgery. In skin-sparing mastectomy, Ahmed et al. [7] found that oncologically safe conservation of autologous mammary structures can be achieved using temporary banking of the NAC. It was concluded that this technique is satisfactory for patients in most cases, but might not be favored by physicians [7]. This may be because banking of the NAC sometimes results in partial necrosis and has other obvious disadvantages, such as postoperative fading and difficulty in reconstructing the nipple projection. There are also objections to this method because of the loss of areola pigmentation or nipple projection after replantation.

In contrast, NAC banking has several advantages over areola tattooing combined with nipple reconstruction with local flap techniques. Composite grafts can be made in cases where bilateral NAC must be removed, as in our case. If the same procedure is applied to both sides at the same time, NACs with basically symmetrical colors and textures can be created. This provides a significant positive effect on psychological adjustment to mastectomy, since NAC sparing significantly enhances body image and satisfaction compared with NAC reconstruction with a single procedure, and restores the nipples and areola.

Another advantage is that the position of the NAC can be freely determined without being affected by scars caused by mastectomy. Because the NAC position is a leading factor determining the final reconstructive outcome and patient satisfaction, optimizing the nipple position should be carefully considered. Several studies have attempted to establish an objective template for the ideal position of the NAC [8–10], but all studies to date have had intrinsic design limitations. Therefore, we put a temporary artificial nipple on the reconstructed breast and asked the patient to decide her preferred position in front of a mirror.

Regarding temporary banking sites, the anterior axillary line continuous from the IMF may be the best candidate because its use does not result in an additional scar. Temporary banking in the groin region is the second option because the linear scar that results after replantation can easily be hidden by underclothes or a swimsuit.

This work has been reported in line with the SCARE 2018 criteria [11].

4. Conclusion

Temporary banking of the nipple-areola complex in breast reconstruction following breast resection including NAC, would be an advantageous surgical technique for benign breast tumors.

Declaration of Competing Interest

The authors report no declarations of interest.

Funding

We no use any sources of funding.

Ethical approval

This article type is case report. This article does not contain any studies with human participants or animals performed by any of the authors.

Consent

The authors declare that informed consent is surely obtained for this article. A copy of the written consent is available for review by the Editor-in-Chief of this journal on request.

Author contribution

First author, Yoshihiro Sowa: Design study, writing the paper.

- Takuya Kodama: Writing and revision.
- Tomoko Hori: Writing and revision.
- Toshiaki Numajiri: Revision and supervision.

Registration of research studies

Name of the registry: Temporary banking of the nipple-areola complex in breast reconstruction following mastectomy for gigantomastia.

Unique identifying number or registration ID: Researchregistry6155.

Hyperlink to your specific registration (must be publicly accessible and will be checked): Not a “first in man” case report.

Guarantor

Yoshihiro Sowa (corresponding author and the Guarantor).

Provenance and peer review

Not commissioned, externally peer-reviewed.

Acknowledgement

None.

References

- [1] T. Palmuth, *Observations medicarum centers tres posthumae, Braunschwig Centll, Obstet* 89 (1648) 25.
- [2] B.U. Ezem, C.C. Osuagwu, K.A. Opara, Gestational gigantomastia with complete resolution in a Nigerian woman, *BMJ Case Rep.* (2011), pii: bcr0120102632.
- [3] P. Eler Dos Reis, N.Q. Blunck Santos, F.A. Barbosa Pagio, F. Chambô, D. Chambô, A. Chambô Filho, Management and follow-up of a case of gestational gigantomastia in a brazilian hospital, *Case Rep. Obstet. Gynecol.* (2014), 610363.
- [4] M. Mangla, D. Singla, Gestational gigantomastia: a systematic review of case reports, *J. Midlife Health* 8 (2017) 40–44.
- [5] O. Lapid, Breast reconstruction after mastectomy for gestational gigantomastia, *Aesthetic Plast. Surg.* 37 (2013) 388–391.
- [6] B.U. Ezem, C.C. Osuagwu, K.A. Opara, Gestational gigantomastia with complete resolution in a Nigerian woman, *BMJ Case Rep.* (2011), bcr0120102632.
- [7] A.K. Ahmed, D.E. Hahn, J.J. Hage, E.M. Bleiker, L.A. Woerdeman, Temporary banking of the nipple-areola complex in 97 skin-sparing mastectomies, *Plast. Reconstr. Surg.* 127 (2011) 531–539.
- [8] R. Lewin, M. Amoroso, N. Plate, C. Trogen, G. Selvaggi, The aesthetically ideal position of the nipple-areola complex on the breast, *Aesthetic Plast. Surg.* 40 (2016) 724–732.
- [9] Y. Mukai, S. Watanabe, M. Matsumoto, M. Saiga, Y. Kimata, Reliability and validity of Mamma Balance®: novel software to assess the symmetry of the

- nipple-areola-complex position, *J. Plast. Reconstr. Aesthet. Surg.* 70 (2017) 1147–1149.
- [10] G. Gulyás, Marking the position of the nipple-areola complex for mastopexy and breast reduction surgery, *Plast. Reconstr. Surg.* 113 (2004) 2085–2090.
- [11] R.A. Agha, M.R. Borrelli, R. Farwana, K. Koshy, A. Fowler, D.P. Orgill, For the SCARE Group, The SCARE 2018 statement: updating consensus surgical CAse REport (SCARE) guidelines, *Int. J. Surg.* 60 (2018) 132–136.

Open Access

This article is published Open Access at [sciencedirect.com](https://www.sciencedirect.com). It is distributed under the [IJSCR Supplemental terms and conditions](#), which permits unrestricted non commercial use, distribution, and reproduction in any medium, provided the original authors and source are credited.