

Short-term outcomes in patients with branch retinal vein occlusion who received intravitreal aflibercept with or without intravitreal ranibizumab

Yoshihito Sakanishi
Ayumi Usui-Ouchi
Kazunori Tamaki
Keitaro Mashimo
Rei Ito
Nobuyuki Ebihara

Department of Ophthalmology,
Juntendo University Urayasu Hospital,
Urayasu City, Chiba, Japan

Purpose: The purpose of this study was to determine the short-term outcomes for patients who received intravitreal aflibercept (IVA) with or without intravitreal ranibizumab (IVR) for macular edema (ME) due to branch retinal vein occlusion (BRVO).

Patients and methods: Patients received IVA for ME due to BRVO. Patients who initially received IVA were defined as the treatment-naïve group and those who were switched from IVR to IVA after ME recurrence were defined as the switching group. Patient outcomes were examined at 1 week and 1 month postinjection.

Results: Both groups comprised 27 eyes from 27 patients. There was a significant decrease in central macular thickness (CMT) at 1 week and 1 month postinjection in both groups. There was also a significant improvement in best-corrected visual acuity (BCVA) at 1 week and 1 month postinjection in the treatment-naïve group and 1 month in the switching group. Younger age was associated with a good BCVA at 1 month postinjection in the switching group, and the absence of epiretinal membrane was associated with a reduction in CMT at 1 month postinjection in the switching group.

Conclusion: IVA is temporarily effective for treating ME due to BRVO regardless of a history of IVR use.

Keywords: BRVO, IVR, IVA, switch

Introduction

Retinal vein occlusion (RVO), which can be classified as central retinal vein occlusion (CRVO) or branch retinal vein occlusion (BRVO), is the second most common type of retinal vascular disease after diabetic retinopathy.^{1,2} RVO can induce a loss of visual acuity due to the presence of macular edema (ME),¹⁻³ current treatments including intravitreal dexamethasone implants, laser treatment, and intravitreal injections of anti-vascular endothelial growth factor (anti-VEGF) agents.³⁻²⁶ Anti-VEGF therapy is widely used for ME due to BRVO, and positive clinical outcomes have been reported,^{3-11,27-29} with numerous studies reporting on the successful use of the VEGF antibody ranibizumab (Lucentis; Genentech Inc., South San Francisco, CA, USA), because ranibizumab use is first covered by insurance as anti-VEGF agents for vitreous injection. After ranibizumab, there have been large treatment studies involving the VEGF inhibitor aflibercept (Regeneron Pharmaceuticals Inc., Tarrytown, NY, USA)²⁸, but only one clinical report has described treatment outcomes of intravitreal aflibercept (IVA) for BRVO.²⁹ There have also been few reports of switching from ranibizumab to aflibercept for the treatment of ME due to CRVO,^{24,25} and none for ME due to BRVO. The short-term outcomes of treatments involving aflibercept and

Correspondence: Yoshihito Sakanishi
Department of Ophthalmology,
Juntendo University Urayasu Hospital,
1-2-1 Tomioka, Urayasu City, Chiba
279-0021, Japan
Tel +81 47 353 3111
Fax +81 47 355 5949
Email ysakani@juntendo.ac.jp

switching from ranibizumab to aflibercept for ME due to BRVO were therefore evaluated.

Patients and methods

Ethics

This retrospective study was conducted in accordance with the Declaration of Helsinki. All necessary authorizations were obtained from the Institutional Review Board of the Juntendo University Urayasu Hospital, Urayasu City, Japan. Fully informed written consent was obtained from all study participants.

Patients

Patients were treated with aflibercept for ME due to BRVO between June 2015 and April 2016. The inclusion criteria were as follows: age ≥ 18 years; symptomatic BRVO with retinal edema involving the foveal center; and foveal thicknesses >300 μm at the initial visit (measured by optical coherence tomography). Exclusion criteria included patients who had received intravitreal bevacizumab (IVB) injection, scatter photocoagulation, or grid laser photocoagulation for ME. The patients were classified into two groups, a treatment-naïve group subsequently treated with IVA and a switching group initially treated with intravitreal ranibizumab (IVR) injection and then switched to IVA because of the recurrence of ME.

Visual acuity and central macular thickness (CMT) were measured at preinjection and at 1 week and 1 month after the IVA. The ratio of patients in the treatment-naïve and switching groups in which the CMT was <300 μm at 1 month after the IVA was compared. The best-corrected visual acuity (BCVA) was measured by using a Landolt chart and converted to the logarithm of the minimum angle of resolution (logMAR).

Preinjection parameters in the switching group were correlated with a CMT <300 μm at 1 month after the IVA and a logMAR ≤ 0.15 (Snellen chart 20/28) at 1 month after the IVA. The preinjection parameters included age; sex; the duration from onset; the number of IVR injections before switching to IVA; and presence or absence of hypertension, diabetes, cystoid ME, subretinal fluid, and epiretinal membrane (ERM).

Statistical analysis

Data were analyzed by using StatView software for Windows (SAS, Cary, NC, USA). The repeated measures analysis of variance and Dunnett's test of multiple comparisons were used for comparisons at different time points before and after the injections, as a statistical test for related, not

independent groups, was required. Fisher's exact test was used to compare the ratios between the two groups. The Mann–Whitney *U* test was used to compare the age, the duration from onset, the number of IVR injections before the IVA injection, and CMT at preswitching. Fisher's exact test was used for categorical variables such as sex and the presence or absence of hypertension, diabetes, cystoid ME, subretinal fluid, and ERM. Multivariate logistic regression was used to analyze the preswitch parameters. $P < 0.05$ was accepted as statistically significant.

Results

Baseline characteristics

A total of 27 eyes from 27 patients comprised both the treatment-naïve and switching groups. The mean age was 66.4 ± 11.0 years in the treatment-naïve group and 72.0 ± 8.4 years in the switching group. The preinjection characteristics of the patients in both groups are summarized in Table 1.

Visual acuity and CMT

Changes in the BCVA and CMT from the treatment-naïve and switching groups are shown in Figures 1 and 2, respectively. In the treatment-naïve group, the BCVA improved from a logMAR value of 0.49 (20/62) at preinjection to 0.34 (20/44) at 1 week post-IVA and 0.27 (20/37) at 1 month post-IVA. Compared with the preinjection, there was a significant improvement in BCVA at both 1 week and 1 month post-IVA. In the switching group, the BCVA improved from a logMAR value of 0.48 (20/60) at preinjection to 0.44 (20/55) at 1 week post-IVA and 0.39 (20/49) at 1 month post-IVA. Compared with the preinjection, there was no significant improvement in BCVA at 1 week post-IVA, but there was a significant improvement in BCVA at 1 month post-IVA.

Table 1 Patient demographics and characteristics

Contents	Treatment-naïve group	Switching group
Age, mean (SD), years	66.4 (11.0)	72.0 (8.4)
Sex, male/female	11/16	10/17
Number of IVR	–	2.9 (2.0)
Visual acuity logMAR, Snellen	0.49 (0.38), 20/60	0.48 (0.29), 20/60
Hypertension, +/-	11/16	14/13
Diabetes, +/-	4/23	4/23
CMT, μm	559.0 (161.9)	511.6 (152.5)
CME, +/-	17/10	17/10
SRF, +/-	10/17	5/22
ERM, +/-	1/26	5/22

Note: Both groups comprised 27 eyes of 27 patients.

Abbreviations: SD, standard deviation; IVR, intravitreal ranibizumab; logMAR, logarithm of the minimum angle of resolution; CMT, central macular thickness; CME, cystoid macula edema; SRF, subretinal fluid; ERM, epiretinal membrane.

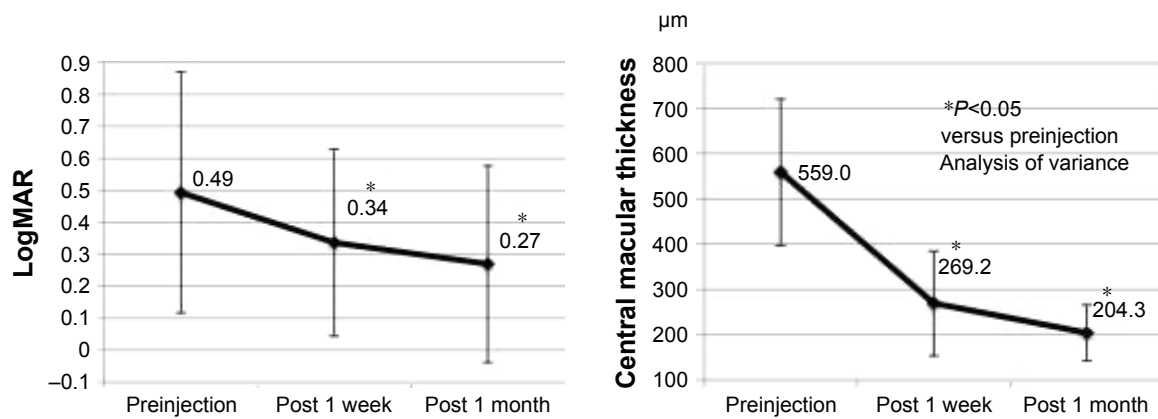


Figure 1 Improvement of BCVA and CMT from preinjection in the treatment-naïve group. There was a significant improvement at 1 week and 1 month post-IVA for both the BCVA and CMT.

Abbreviations: BCVA, best-corrected visual acuity; CMT, central macular thickness; IVA, intravitreal aflibercept.

In the treatment-naïve group, the mean CMT decreased from 559.0 μm at preinjection to 269.2 μm at 1 week post-IVA and 204.2 μm at 1 month post-IVA. In the switching group, the mean CMT decreased from 511.7 μm at preinjection to 265.2 μm at 1 week post-IVA and 238.2 μm at 1 month post-IVA. Compared with the preinjection, there was a significant decrease in the mean CMT at both 1 week and 1 month post-IVA in both the groups.

There were 26 of 27 eyes (96.3%) in the treatment-naïve group and 23 of 27 eyes (85.2%) in the switching group where the CMT was <300 μm at 1 month post-IVA, but there was no significant difference between the two groups ($P=0.35$).

Preswitch parameter associated with a beneficial response

In the switching group, univariate analysis showed that age and duration from onset were preswitch parameters associated with a decreased logMAR of ≤ 0.15 (20/28) at 1 month post-IVA (Table 2). Here, multivariate logistic regression

analysis showed that younger age was an independent preswitch parameter associated with a logMAR ≤ 0.15 (20/28). Univariate analysis also showed that the absence of ERM in the switching group was a preswitch parameter associated with a CMT <300 μm at 1 month post-IVA (Table 3).

Discussion

Numerous studies have reported on the use of anti-VEGF therapies to treat ME due to BRVO.^{3–11,27–29} The BRAVO and HORIZON studies were large-scale studies that evaluated the effectiveness of IVR treatment for ME due to BRVO,^{3,27} while VIBRANT study investigated the efficacy of IVA treatment.²⁸ There are numerous reports describing switch therapy for age-related macular degeneration (AMD),^{30–34} but few reports describe the use of switch therapy for RVO.^{24,25,35} Switching from steroid to anti-VEGF injections for RVO,³⁵ switching from IVR to IVA for CRVO,²⁴ and switching from IVB or IVR to IVA for CRVO have all been previously reported.²⁵ For ischemic CRVO, Lehmann-Clarke et al found

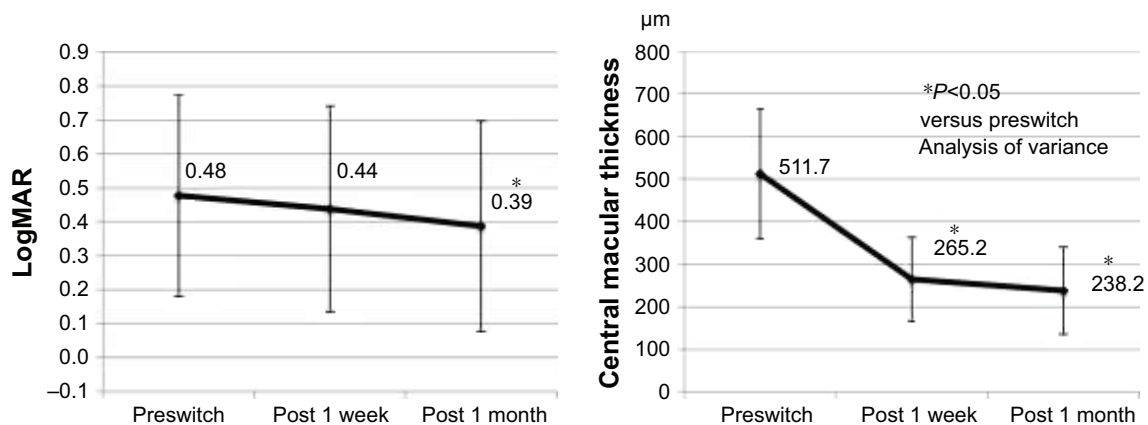


Figure 2 Improvement of BCVA and CMT from preswitch in the switching group. There was a significant improvement in BCVA at 1 month post-IVA and a significant improvement in CMT at 1 week and 1 month post-IVA.

Abbreviations: BCVA, best-corrected visual acuity; CMT, central macular thickness; IVA, intravitreal aflibercept.

Table 2 Preswitching factors associated with visual acuity at 1 month post-IVA

Variable factors	Visual acuity (logMAR)			Logistic regression analysis		
	≤0.15	>0.15	P-value	Crude odds ratio	95% CI	P-value
Age, mean (SD), years	66.0 (8.5)	75.1 (6.7)	0.015	1.201	1.027–1.403	0.02
Sex, male/female	5/4	5/13	0.16			
Duration from onset	16.4 (17.7)	27.2 (19.9)	0.035	1.047	0.983–1.115	0.15
Number of IVR	2.9 (2.8)	2.9 (1.6)	0.44			
Hypertension, +/-	4/5	10/8	0.44			
Diabetes, +/-	1/8	3/15	0.59			
CMT, μm	442.7 (120.7)	546.2 (158.2)	0.09			
CME, +/-	6/3	11/7	0.56			
SRF, +/-	0/9	5/13	0.11			
ERM, +/-	2/7	3/15	0.55			

Note: Younger age was associated with a good BCVA at 1 month postinjection in the switching group.

Abbreviations: logMAR, logarithm of the minimum angle of resolution; CI, confidence interval; SD, standard deviation; IVR, intravitreal ranibizumab; CMT, central macular thickness; CME, cystoid macular edema; SRF, subretinal fluid; ERM, epiretinal membrane; BCVA, best-corrected visual acuity.

that switching from IVR to IVA made the injection interval longer.²⁴ Therefore, this study would benefit from observing longer follow-up periods and consideration of the length of injection intervals.

No studies investigated switching from other anti-VEGF therapies to aflibercept, but switching from IVB to dexamethasone implants for treating ME due to BRVO has been reported.³⁵ By switching from IVB to dexamethasone or from dexamethasone to IVB, both visual acuity and CMT were significantly improved. In this study, switching to IVA from IVR showed both functional and anatomical improvement, as both the visual acuity and CMT significantly improved at 1 month postinjection.

At 1 month post-IVA, there was no significant difference between the treatment-naïve and switching groups for the CMT becoming $\leq 300 \mu\text{m}$. However, the background

characteristics of the two groups were different, so a simple comparison was not suitable. The difference in the durations from disease onset between the two groups was large, which can influence the short-term CMT.

In addition, this study showed that the visual acuity of a younger patient increased to a logMAR of ≤ 0.15 (20/28) at 1 month when switching to post-IVA. It is thought that older patients did not adequately recover their retinal function when the ME disappears. Furthermore, Yasuda et al reported that age is one of the risk factors associated with the onset of RVO,³⁶ so age is also thought to be related to the severity of RVO.

In the switching group, the CMT was rarely $< 300 \mu\text{m}$ at 1 month post-IVA in ME patients with ERM. A previous study reported a case of AMD with vitreomacular adhesion that was insensitive to anti-VEGF treatment.³⁷ This report involved a very short timeframe, but it had similar outcomes for BRVO as the present report. It is thought that pro re nata dosing involving IVA is sufficient for switching patients without ERM because of their sensitivity to IVA, but switching of patients with ERM would likely require multiple injections. However, this study only examined patients until 1 month post-IVA and did not examine whether the ME improved after the second IVA, so in these patients it is necessary to follow the progress of the ME after multiple IVA injections. In addition, in patients with ME due to BRVO with ERM, it might be necessary to perform a vitrectomy.

Limitations

The limitations of this study included the small sample size and the short-term follow-up period of 1 month after switching. To overcome these concerns, future studies should determine the effects of IVA over a longer timeframe.

Table 3 Preswitching parameters associated with CMT at 1 month post-IVA

CMT at 1 month post-IVA	<300 μm	$\geq 300 \mu\text{m}$	P-value
Age, mean (SD), years	71.4 (8.9)	75.5 (3.7)	0.34
Sex, male/female	9/14	1/3	0.52
Duration from onset	20.7 (17.9)	40.3 (23.0)	0.07
Number of IVR	2.8 (2.9)	3.3 (2.1)	0.62
Hypertension, +/-	12/11	2/2	0.67
Diabetes, +/-	3/20	1/3	0.50
CMT, μm	498.8 (493.6)	585.8 (177.6)	0.31
CME, +/-	3/20	2/2	0.48
SRF, +/-	4/19	1/3	0.58
ERM, +/-	2/21	3/1	0.01

Note: Absence of the epiretinal membrane was associated with improvement of the CMT at 1 month postinjection in the switching group.

Abbreviations: IVA, intravitreal aflibercept; SD, standard deviation; IVR, intravitreal ranibizumab; CMT, central macular thickness; CME, cystoid macular edema; SRF, subretinal fluid; ERM, epiretinal membrane.

Conclusion

The treatment outcomes at 1 month post-IVA injection for patients with ME due to BRVO were reported. IVA is temporarily effective for treating ME due to BRVO regardless of a history of IVR use.

Disclosure

The authors report no conflicts of interest in this work.

References

- Klein R, Moss SE, Meuer SM, Klein BE. The 15-year cumulative incidence of retinal vein occlusion. The Beaver Dam eye study. *Arch Ophthalmol*. 2008;126:513–518.
- US Census Bureau. Annual estimates of the population by sex and five-year age groups for the United States: April 1, 2000 to July 1, 2007. NC-EST2007-01. Release Date: May 1, 2008. Available from: <https://www.census.gov/prod/2008pubs/p70-117.pdf>. Accessed February 16, 2010.
- Campochiaro PA, Heier JS, Feiner L, et al; BRAVO Investigators. Ranibizumab for macular edema following branch retinal vein occlusion: six-month primary end point results of a phase III study. *Ophthalmology*. 2010;117:1102–1112.
- Sakanishi Y, Lee A, Usui-Ouchi A, Ito R, Ebihara N. Twelve-month outcomes in patients with retinal vein occlusion treated with low-frequency intravitreal ranibizumab. *Clin Ophthalmol*. 2016;10:1161–1165.
- Campochiaro PA, Wykoff CC, Singer M, et al. Monthly versus as-needed ranibizumab injections in patients with retinal vein occlusion: the SHORE study. *Ophthalmology*. 2014;121:2432–2442.
- Brown DM, Campochiaro PA, Bhisitkul RB, et al. Sustained benefits from ranibizumab for macular edema following branch retinal vein occlusion: 12-month outcomes of a phase III study. *Ophthalmology*. 2011;118:1594–1602.
- Campochiaro PA, Sophie R, Pearlman J, et al; RETAIN Study Group. Long-term outcomes in patients with retinal vein occlusion treated with ranibizumab: the RETAIN Study. *Ophthalmology*. 2014;121:209–219.
- Nghiem-Buffet S, Fajnkuchen F, Buffet M, et al. Intravitreal ranibizumab and/or dexamethasone implant for macular edema secondary to retinal vein occlusion. *Ophthalmologica*. 2014;232:216–222.
- Brynskov T, Kemp H, Sørensen TL. Intravitreal ranibizumab for retinal vein occlusion through 1 year in clinical practice. *Retina*. 2014;34:1637–1643.
- Tan MH, McAllister IL, Gillies ME, et al. Randomized controlled trial of intravitreal ranibizumab versus standard grid laser for macular edema following branch retinal vein occlusion. *Am J Ophthalmol*. 2014;157:237–247.
- Mylonas G, Sacu S, Dunavoelgyi R, et al; Macula Study Group. Response of retinal sensitivity to ranibizumab treatment of macular edema after acute branch retinal vein occlusion. *Retina*. 2013;33:1220–1226.
- Scott IU, Ip MS, VanVeldhuisen PC, et al; SCORE Study Research Group. A randomized trial comparing the efficacy and safety of intravitreal triamcinolone with standard care to treat vision loss associated with macular edema secondary to branch retinal vein occlusion: the Standard Care vs Corticosteroid for Retinal Vein Occlusion (SCORE) study report 6. *Arch Ophthalmol*. 2009;127:1115–1128.
- Ip MS, Scott IU, VanVeldhuisen PC, et al; SCORE Study Research Group. A randomized trial comparing the efficacy and safety of intravitreal triamcinolone with observation to treat vision loss associated with macular edema secondary to central retinal vein occlusion: the Standard Care vs Corticosteroid for Retinal Vein Occlusion (SCORE) study report 5. *Arch Ophthalmol*. 2009;127:1101–1114.
- Korobelnik JF, Kodjikian L, Delcourt C, et al. Two-year, prospective, multicenter study of the use of dexamethasone intravitreal implant for treatment of macular edema secondary to retinal vein occlusion in the clinical setting in France. *Graefes Arch Clin Exp Ophthalmol*. 2016;254:2307–2318.
- [no authors listed]. Argon laser photocoagulation for macular edema in branch vein occlusion. Branch Vein Occlusion Study Group. *Am J Ophthalmol*. 1984;98:271–282.
- Noma H, Funatsu H, Mimura T, Shimada K. Macular sensitivity and morphology after intravitreal injection of triamcinolone acetonide for macular edema with branch retinal vein occlusion. *Retina*. 2012;32:1844–1852.
- Noma H, Mimura T. Macular sensitivity and morphology after intravitreal injection of triamcinolone acetonide for macular edema secondary to central retinal vein occlusion. *Clin Ophthalmol*. 2012;6:1901–1906.
- Brown DM, Campochiaro PA, Singh RP, et al; CRUISE Investigators. Ranibizumab for macular edema following central retinal vein occlusion: six-month primary end point results of a phase III study. *Ophthalmology*. 2010;117:1124–1133.
- Campochiaro PA, Brown DM, Awh CC, et al. Sustained benefits from ranibizumab for macular edema following central retinal vein occlusion: twelve-month outcomes of a phase III study. *Ophthalmology*. 2011;118:2041–2049.
- Berger AR, Cruess AF, Altomare F, et al. Optimal treatment of retinal vein occlusion: Canadian expert consensus. *Ophthalmologica*. 2015;234:6–25.
- Brown DM, Wykoff CC, Wong TP, et al; RAVE Study Group. Ranibizumab in preproliferative (ischemic) central retinal vein occlusion: the rubeosis anti-VEGF (RAVE) trial. *Retina*. 2014;34:1728–1735.
- Ogura Y, Roeder J, Korobelnik JF, et al; GALILEO Study Group. Intravitreal aflibercept for macular edema secondary to central retinal vein occlusion: 18-month results of the phase 3 GALILEO study. *Am J Ophthalmol*. 2014;158:1032–1038.
- Heier JS, Clark WL, Boyer DS, et al. Intravitreal aflibercept injection for macular edema due to central retinal vein occlusion: two-year results from the COPERNICUS study. *Ophthalmology*. 2014;121:1414–1420.
- Lehmann-Clarke L, Dirani A, Mantel I, Ambresin A. The effect of switching ranibizumab to aflibercept in refractory cases of macular edema secondary to ischemic central vein occlusion. *Klin Monbl Augenheilkd*. 2015;232:552–555.
- Papakostas TD, Lim L, van Zyl T, et al. Intravitreal aflibercept for macular oedema secondary to central retinal vein occlusion in patients with prior treatment with bevacizumab or ranibizumab. *Eye (Lond)*. 2016;30:79–84.
- Campochiaro PA, Hafiz G, Mir TA, et al. Scatter photocoagulation does not reduce macular edema or treatment burden in patients with retinal vein occlusion: the RELATE trial. *Ophthalmology*. 2015;122:1426–1437.
- Heier JS, Campochiaro PA, Yau L, et al. Ranibizumab for macular edema due to retinal vein occlusions: long-term follow-up in the HORIZON trial. *Ophthalmology*. 2012;119:802–809.
- Campochiaro PA, Clark WL, Boyer DS, et al. Intravitreal aflibercept for macular edema following branch retinal vein occlusion: the 24-week results of the VIBRANT study. *Ophthalmology*. 2015;122:538–544.
- Wang JK, Huang TL, Su PY, Chang PY, Tseng YY. Intravitreal aflibercept for macular edema secondary to branch retinal vein occlusion in Chinese patients. *Eye Sci*. 2015;30:63–66.
- Pinheiro-Costa J, Costa JM, Beato JN, et al. Switch to aflibercept in the treatment of neovascular AMD: one-year results in clinical practice. *Ophthalmologica*. 2015;233:155–161.
- Michalewski J, Nawrocki J, Trębińska M, Michalewska Z. Switch to a single dose of aflibercept in bevacizumab nonresponders with AMD. *Can J Ophthalmol*. 2014;49:431–435.

32. Ehlken C, Jungmann S, Böhlinger D, Agostini HT, Junker B, Pielen A. Switch of anti-VEGF agents is an option for nonresponders in the treatment of AMD. *Eye (Lond)*. 2014;28:538–545.
33. Ehlers JP, Spirn MJ, Shah CP, et al. Ranibizumab for exudative age-related macular degeneration in eyes previously treated with alternative vascular endothelial growth factor inhibitors. *Ophthalmic Surg Lasers Imaging*. 2010;41:182–189.
34. Massamba N, Dirani A, Butel N, et al. Evaluation of outer retinal tubulations in eyes switched from intravitreal ranibizumab to aflibercept for treatment of exudative age-related macular degeneration. *Graefes Arch Clin Exp Ophthalmol*. 2017;255:61–67.
35. Christophe C, Bron AM, Straub M, et al. Retinal vein occlusions: therapeutic switch in macular oedema treatment with a 12-month follow-up. *Ophthalmic Res*. 2016;55:152–158.
36. Yasuda M, Kiyohara Y, Arakawa S, et al. Prevalence and systemic risk factors for retinal vein occlusion in a general Japanese population: the Hisayama study. *Invest Ophthalmol Vis Sci*. 2010;51:3205–3209.
37. Lee SJ, Koh HJ. Effects of vitreomacular adhesion on anti-vascular endothelial growth factor treatment for exudative age-related macular degeneration. *Ophthalmology*. 2011;118:101–110.

Clinical Ophthalmology

Dovepress

Publish your work in this journal

Clinical Ophthalmology is an international, peer-reviewed journal covering all subspecialties within ophthalmology. Key topics include: Optometry; Visual science; Pharmacology and drug therapy in eye diseases; Basic Sciences; Primary and Secondary eye care; Patient Safety and Quality of Care Improvements. This journal is indexed on

Submit your manuscript here: <http://www.dovepress.com/clinical-ophthalmology-journal>

PubMed Central and CAS, and is the official journal of The Society of Clinical Ophthalmology (SCO). The manuscript management system is completely online and includes a very quick and fair peer-review system, which is all easy to use. Visit <http://www.dovepress.com/testimonials.php> to read real quotes from published authors.