

# Retrograde recanalisation for vertebral artery stump syndrome: a case report

Renjie Ji ,<sup>1</sup> Bing Li,<sup>2</sup> Ziqi Xu <sup>1</sup>

**To cite:** Ji R, Li B, Xu Z. Retrograde recanalisation for vertebral artery stump syndrome: a case report. *Stroke & Vascular Neurology* 2022;**7**:e001407. doi:10.1136/svn-2021-001407

Received 13 November 2021  
Accepted 2 March 2022  
Published Online First  
30 March 2022

## SUMMARY

Vertebral artery stump syndrome (VASS) is a rare disease associated with a posterior circulation stroke after vertebral artery origin occlusion. We have herein presented a case of VASS that was effectively treated with endovascular intervention using retrograde recanalisation and the mechanism of VASS in our patient was thought to be a thrombus formed by stagnating flow.

## INTRODUCTION

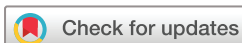Carotid artery stump syndrome is an embolic source for ischaemic stroke.<sup>1</sup> Ischaemic stroke following carotid artery occlusion can be caused by an embolism from the distal limit of the propagated thrombus, an embolism from the carotid bifurcation via the external carotid artery and the contralateral carotid artery via the circle of Willis.<sup>2</sup> Similarly, occlusion of the origin of the vertebral artery (VA) can cause stroke in the posterior circulation, termed vertebral artery stump syndrome (VASS).<sup>3</sup> Furthermore, the mechanism of VASS can also cause by the turbulence of the flow caused by the presence of collateral anatomical pathways which is well described by Suzuki *et al.*<sup>4</sup> However, few reports have addressed the management of VASS, especially endovascular therapy.

Here, we describe a patient who presented with a posterior circulation ischaemic stroke after occlusion of the VA who successfully underwent intravascular intervention using retrograde recanalisation.

## CASE PRESENTATION

A man in his 60s presented with acute-onset vertigo. He had a medical history of hypertension, but no diabetes, hyperlipidaemia or prior stroke. He did not smoke or drink. Diffusion-weighted imaging at admission showed an acute ischaemic stroke in the left cerebellar hemisphere and vermis (**figure 1A**). CT angiography revealed an occlusion at the origin of the left VA and atherosclerotic calcification of V4 segment (**figure 1B,C**). Angiography detected total occlusion, with distal antegrade collateral flow via the ascending cervical artery

originating from the thyrocervical trunk and the deep cervical artery at the C3 level (**figure 1D**). No cardiac embolic sources were revealed by transthoracic echocardiography and Holter monitoring and the results of blood examination, including coagulation tests, were normal. He was treated with aspirin 100 mg and clopidogrel 75 mg per day, together with atorvastatin 20 mg per day to prevent secondary stroke. On day 5, we decided to perform endovascular intervention to recanalise the left VA. An 8 Fr guiding catheter (Mach1, Boston Scientific) was positioned at the origin of the left subclavian artery via access from the right common femoral artery under local anaesthesia. After multiple failed attempts, we switched to retrograde recanalisation. As CTA showed atherosclerotic calcification of the left V4 segment which may be difficult for retrograde recanalisation via the right VA to the left VA. So, we attempted to retrograde recanalisation via the ascending cervical artery with a Synchro-2 microguide wire (0.014 in×300 cm, Stryker, Ireland) and an SL-10 microcatheter (Stryker, Ireland). The wire and microcatheter successfully passed through the ascending cervical artery and reached the left vertebral ostium and then, without difficulty, the left subclavian artery. Using a 0.014-in wire as a marker, we switched to a PT-2 microguide wire (0.014 in×300 cm, Boston Scientific, USA) for a more aggressive approach (**figure 2A**). We found the true lumen of the left VA. Sprinter Legend 2.5×15 mm balloon (Medtronic, USA) angioplasty was performed with good antegrade vertebral blood flow and a filling defect found at the origin of left VA was thought to be a thrombus (**figure 2B**). Along with the PT-2 wire, we used a thrombectomy catheter to aspirated the thrombus, which was confirmed pathologically. Then, the thrombectomy catheter was withdrawn and we implanted a 4.0×15 mm bare-metal stent (Herculink Elite, Abbott Vascular, USA) (**figure 2C**). The patient was treated with



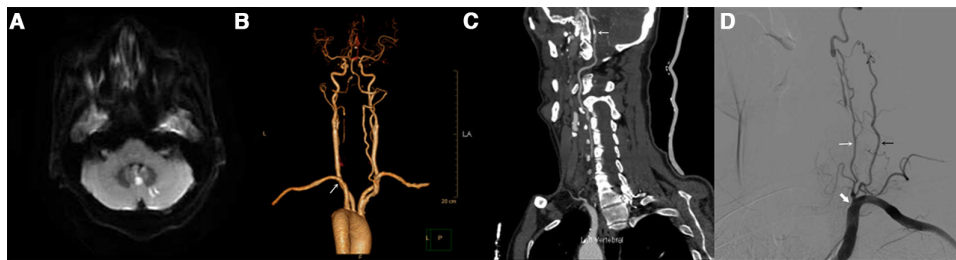
© Author(s) (or their employer(s)) 2022. Re-use permitted under CC BY-NC. No commercial re-use. See rights and permissions. Published by BMJ.

<sup>1</sup>Neurology, Zhejiang University School of Medicine First Affiliated Hospital, Hangzhou, Zhejiang, China

<sup>2</sup>Neurology, Shulan hospital, Hangzhou, Zhejiang, China

## Correspondence to

Dr Ziqi Xu; zyxuziqi@zju.edu.cn



**Figure 1** (A) Diffusion-weighted imaging at admission showed an acute ischaemic stroke in the left cerebellar hemisphere and vermis. (B) CT angiography revealed an occlusion at the origin of the left vertebral artery (VA) (white arrow). (C) CT angiography revealed atherosclerotic calcification of left V4 segment (white arrow). (D) Angiography detected total occlusion at the origin of left VA (white arrowhead), with distal antegrade collateral flow via the ascending cervical artery originating from the thyrocervical trunk (white arrow) and the deep cervical artery (black arrow) at the C3 level (oblique projection).

clopidogrel for 3 months and aspirin. At the 6-month follow-up, we performed the CTA again (figure 2D) and there had been no further events.

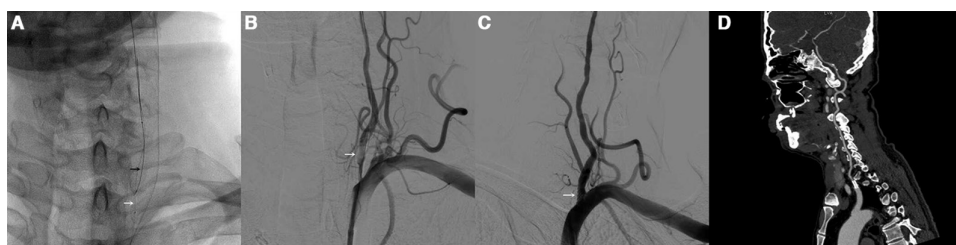
## DISCUSSION

In 2008, Nguyen *et al*<sup>3</sup> first reported two patients with VASS who underwent endovascular treatment after drug treatment failed. In another study, VASS accounted for 1.4% of posterior circulation ischaemic stroke, and 25% of patients had stroke recurrence during drug therapy and 25% had poor prognoses (mRS score 3–5 at discharge).<sup>5</sup> This suggests that this syndrome is not a rare cause of posterior circulation ischaemic stroke and has a high risk of recurrence and a poor prognosis. The possible pathogenesis of VASS is as follows: ipsilateral VA origin occlusion is caused by the distal limit of the propagated thrombus, and the ischaemic events after VA occlusion might be associated with emboli of the stagnating clot fragment and a low-flow state caused by the collateral circulation via the deep cervical arteries. During the retrograde endovascular procedure, our patient had a filling defect at the origin of the left VA; this was thought to be a thrombosis after catheter aspiration, which was confirmed pathologically (figure 3). Therefore, the pathogenesis of VASS in our patient was thought to be a thrombus formed by stagnating flow, which was detached by turbulent flow in the stump and carried intracranially via collaterals. There are

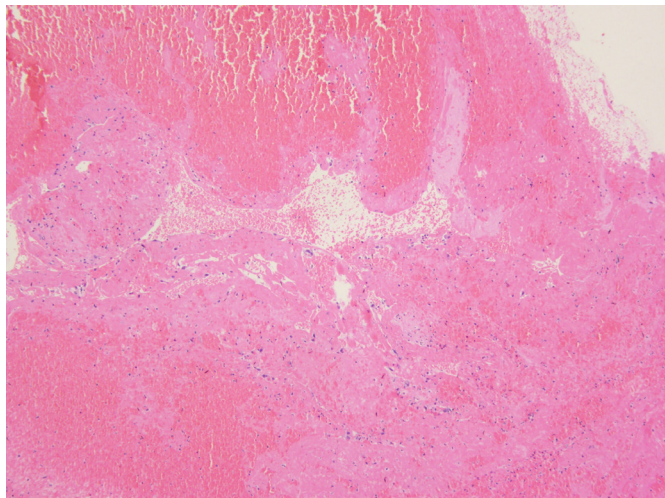
no standard clinical practices or guidelines for the treatment of VASS, due the small number of cases. Antiplatelet therapy failed to prevent embolism in three patients in a previous study<sup>6</sup> and in one patient in another study.<sup>3</sup> The former study reported three cases of VASS after anticoagulation treatment without recurrent stroke, whereas the latter reported that two patients had recurrent stroke during antithrombotic treatment and ultimately underwent endovascular interventional treatment; no stroke recurred during their subsequent follow-up.

To the best of our knowledge, this is the first patient with VASS to undergo retrograde endovascular treatment by opening the origin of the left VA through the thyrocervical trunk. In our case, as the stump in the VA was not obvious, antegrade opening was difficult. Therefore, we opened the origin retrogradely through the thyrocervical trunk and successfully placed a stent. Antiplatelet drugs and statins were given for secondary prevention and the patient has had no stroke recurrence during follow-up.

In conclusion, we have herein presented a case of VASS that was effectively treated with endovascular intervention and the mechanism of VASS in our patient was thought to be a thrombus formed by stagnating flow. Although the most effective treatment cannot be determined because of the insufficient number of published cases, endovascular intervention



**Figure 2** (A) Synchro-2 microwire and SL-10 microcatheter passed through the ascending cervical artery and reached the left vertebral ostium and then to the left subclavian artery (black arrow), using Synchro-2 wire as a marker, a PT-2 microwire (0.014 in×300 cm) successfully found the true lumen of the left VA (white arrow). (B) Filling defect found at the origin of left VA (white arrow). (C) Angiography after the bare-metal stent (white arrow) planted. (D) Follow-up at 6 months, CT angiography (CTA) showed no restenosis in the stent.



**Figure 3** Histopathology of the removed thrombus which contained neutrophils, platelets and red blood cells within a dense laminar fibrin network.

might reduce further embolism events based on past reports.

**Contributors** RJ: manuscript conception, design, writing and editing, and clinical care of the patient. BL: review of the article and clinical care of the patient. ZX: critical review of the manuscript and clinical care of the patient.

**Funding** Zhejiang basic public research program funds (LGF20H090010).

**Competing interests** None declared.

**Patient consent for publication** Consent obtained directly from patient(s)

**Ethics approval** Not applicable.

**Provenance and peer review** Not commissioned; externally peer reviewed.

**Open access** This is an open access article distributed in accordance with the Creative Commons Attribution Non Commercial (CC BY-NC 4.0) license, which permits others to distribute, remix, adapt, build upon this work non-commercially, and license their derivative works on different terms, provided the original work is properly cited, appropriate credit is given, any changes made indicated, and the use is non-commercial. See: <http://creativecommons.org/licenses/by-nc/4.0/>.

#### ORCID iDs

Renjie Ji <http://orcid.org/0000-0002-6918-048X>

Ziqi Xu <http://orcid.org/0000-0002-5516-4817>

#### REFERENCES

- 1 Barnett HJ, Peerless SJ, Kaufmann JC. "Stump" on internal carotid artery--a source for further cerebral embolic ischemia. *Stroke* 1978;9:448-56.
- 2 Quill DS, Colgan MP, Sumner DS. Carotid stump syndrome: a colour-coded Doppler flow study. *Eur J Vasc Surg* 1989;3:78-83.
- 3 Nguyen TN, Raymond J, Mahmoud M, et al. Vertebral artery stump syndrome. *J Neurol Neurosurg Psychiatry* 2008;79:91-2.
- 4 Suzuki M, Dembo T, Hara W, et al. Vertebral artery stump syndrome. *Intern Med* 2018;57:733-6.
- 5 Kawano H, Inatomi Y, Hirano T, et al. Vertebral artery stump syndrome in acute ischemic stroke. *J Neurol Sci* 2013;324:74-9.
- 6 Kawano H, Inatomi Y, Hirano T, et al. Anticoagulation therapy for vertebral artery stump syndrome. *J Neurol Sci* 2010;295:125-7.