


Successful Treatment of Minocycline-Induced Facial Hyperpigmentation with a Combination of Chemical Peels and Intense Pulsed Light

Yuan Li ^{1,2}, Xiaole Zhen¹, Xiaojuan Yao¹, Jiejie Lu¹

¹Dermatology Department, the Fifth People's Hospital of Hainan Province, Haikou, Hainan, People's Republic of China; ²Department of Dermatology, the First Affiliated Hospital of Nanjing Medical University, Nanjing, Jiangsu, People's Republic of China

Correspondence: Jiejie Lu, Dermatology Department, the Fifth People's Hospital of Hainan Province, No. 8 Longhua Road, Longhua District, Haikou, Hainan, 570100, People's Republic of China, Email lujiejie677@163.com

Abstract: Minocycline is a tetracycline derivative antibiotic commonly used to treat acne, rosacea, and other inflammatory skin conditions. Taking minocycline risks inducing skin pigmentation. If minocycline-induced hyperpigmentation is not treated, it may take months to years for the symptoms to subside after discontinuation of the drug, or the hyperpigmentation may never disappear completely, which can lead to cosmetic anxiety and affect people's quality of life. Previous treatment options for hyperpigmentation were mainly q-switched nd: YAG, ruby, and alexandrite lasers. This article reports a case of facial hyperpigmentation caused by minocycline using a combination of chemical peel and intense pulsed light in a patient with eosinophilic cellulitis (Wells syndrome) who was taking oral minocycline. This case suggests combining chemical peel and intense pulsed light is an effective treatment option for minocycline-induced hyperpigmentation.

Keywords: minocycline, pigmentation, chemical peel, intense pulsed light

Introduction

Minocycline is a tetracycline derivative antibiotic commonly used to treat acne, rosacea, and other inflammatory skin conditions. Taking minocycline risks inducing skin pigmentation because the insoluble metabolite in minocycline is a derivative that chelates with iron in the tissue and is deposited in the dermis, manifesting as blue-grey or mud-brown pigmentation.¹ If minocycline-induced hyperpigmentation is not treated, it may take months to years for the symptoms to subside after discontinuation of the drug, or the hyperpigmentation may never disappear completely, which can lead to cosmetic anxiety and affect people's quality of life. Reviewing the reports on minocycline-induced skin pigmentation in the past 10 years showed that the dose of minocycline was 100–200 mg/d, and the onset of pigmentation was 2 weeks to 1 year after taking the drug.² Treatment options for minocycline-induced hyperpigmentation have been reported in the literature focusing on q-switched nd: YAG, ruby, and alexandrite lasers.^{3,4} The typical intervention reported in the literature is using pigmented lasers, considering that pigmented lasers still induce hyperpigmentation in Asian populations. Therefore, a milder treatment option than a pigment laser was chosen for this case: chemical peel with intense pulsed light. The intervention mechanism of chemical peel and intense pulsed light on pigmentation is clear, such as chemical peel is by using chemical peeling agent or etching agent to act directly on the skin surface to degenerate, necrotize and detach the local lesion tissue, decompose and remove the melanin that has been produced, so as to achieve the effect of lightening pigmentation spots,^{5–7} while intense pulsed light by selectively acting on melanin, using selective action on melanin, can use “Photothermal”, “photolysis”, “photo-explosion” and other principles to break up and decompose pigment clusters and pigment cells, to achieve the effect of pigment removal, such as post-burn pigmentation, pigmentation, etc. hyperpigmentation, hyperpigmentation, etc.^{8,9} Although the mechanism of action of the above two interventions in hyperpigmentation is precise, the combined intervention of the two interventions in minocycline-induced

hyperpigmentation has not been reported. Therefore, we report a case of facial hyperpigmentation caused by minocycline and treat this hyperpigmentation using a combination of chemical peel and intense pulsed light. The patient had eosinophilic cellulitis (Wells syndrome) and was given oral minocycline.¹⁰ This case suggests combining chemical peel and intense pulsed light is an effective treatment option for minocycline-induced hyperpigmentation.

Case Presentation

The patient, a female, 29 years old, was diagnosed with Wells syndrome one year ago and had only taken this one drug, minocycline capsules, orally for the treatment of primary skin disease in the 1 month prior to the appearance of hyperpigmentation on the face. In summary, the appearance of hyperpigmentation was caused by minocycline based on the time node of the occurrence of adverse drug reactions and the adverse effects of oral minocycline, including the formation of hyperpigmentation, so the minocycline was stopped, and the patient was advised to avoid light (Figure 1A). First, the patient was treated with a chemical peel using 4 mL of glycolic acid at a concentration of 35%, and the duration of action was 5 min, 7 min, and 10 min for the first and third times, and the endpoint reaction of each treatment was slight skin reddening, but the patient's pigmentation faded slowly after three consecutive chemical peels (35% concentration of fruit acids), and in order to further fade the pigmentation increasing the treatment concentration of fruit acids alone may lead to the development of serious adverse reactions. Therefore, we changed the treatment to intense pulsed light once a month for three consecutive times. The wavelength of intense pulsed light we chose was 560, and the doses before and after three times were 15 MJ, 14 MJ, and 16 MJ, respectively, and the endpoint response was a slight deepening of the

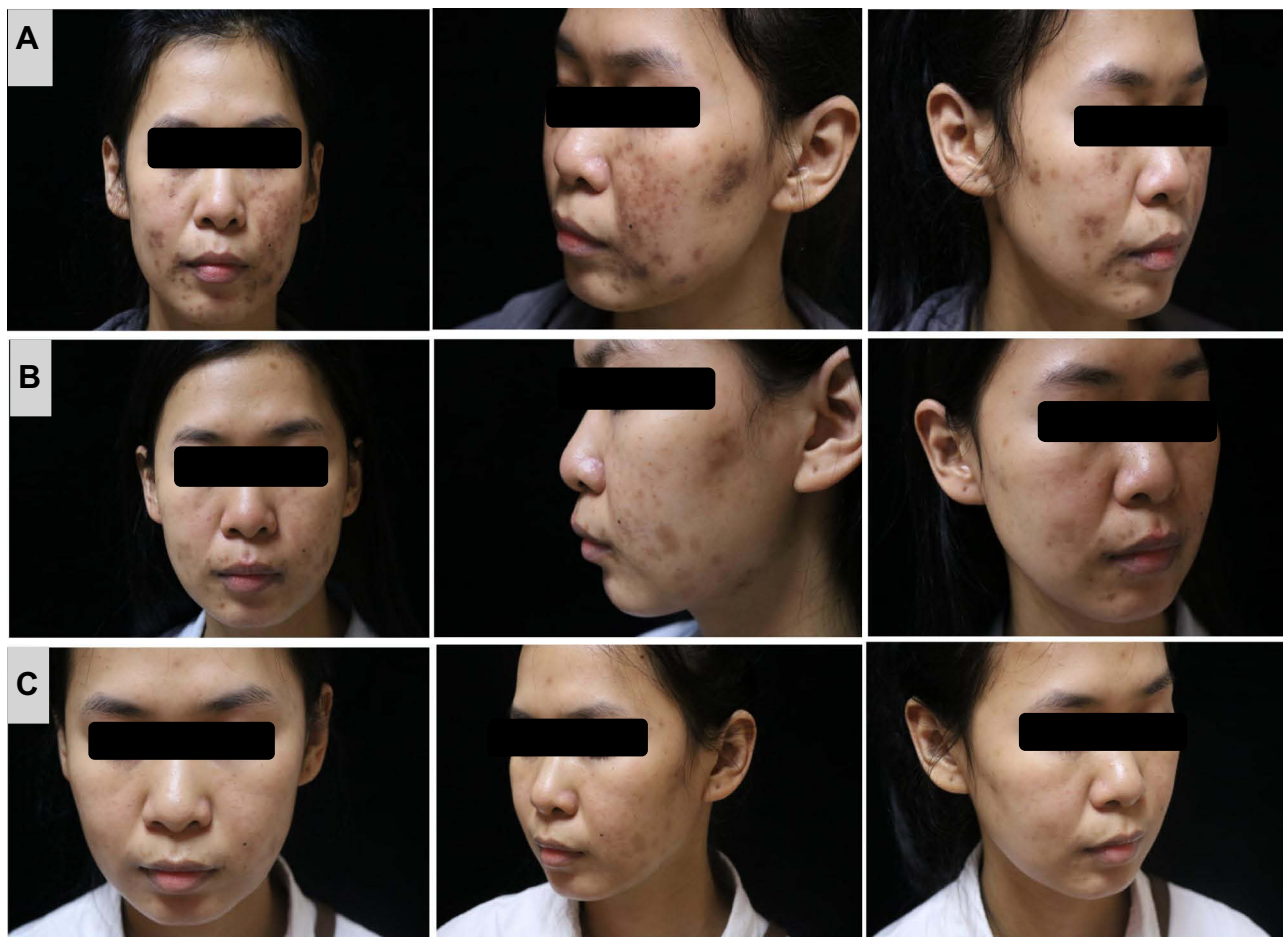

Figure 1 Clinical photograph of a female patient showing improvement in minocycline-induced hyperpigmentation before and after treatment. (A) Before treatment. (B) After three treatments of 35% fruit acids. (C) After three intense pulsed light treatments.

hyperpigmented area (Figure 1B). After the combined treatment of chemical peeling and intense pulsed light, the patient's facial hyperpigmentation largely subsided (Figure 1C).

Discussion

Minocycline-induced hyperpigmentation of the skin can be divided into three types. Type I is the most common and is associated with areas of prior inflammation and scar formation. Type II most commonly affects the lower extremities and is characterized by blue-grey pigmentation on normal skin. Type III is the least common and is characterized by diffuse mud-brown discoloration that occurs primarily on sun-exposed skin.¹¹ In this case, the type of facial hyperpigmentation induced by minocycline was type I.

Chemical peels is by using chemical peeling agent or etching agent to act directly on the skin surface to degenerate, necrotize and detach the local lesion tissue, decompose and remove the melanin that has been produced, so as to achieve the effect of lightening pigmentation spots.⁵⁻⁷ The chemical peeling agent, in this case, is fruit acid, ie, alpha-hydroxy acid, an ingredient extracted from a variety of natural fruits and vegetables. Due to the small relative molecular weight of fruit acids, water solubility, and permeability, especially glycolic acid (glycolic acid), which has the most negligible relative molecular weight, has the strongest skin permeability and is more suitable as a chemical peeling agent. Chemical peels can be performed alone or in combination with other cosmetic modalities.¹²

Intense pulsed light (IPL) is a broad-spectrum light formed by a very high-intensity light source that is focused and filtered, and is a non-coherent general light rather than a laser. IPL is primarily available at wavelengths of 500 to 1200 nm.¹³ The theoretical basis for IPL treatment of skin disorders is the principle of selective photothermal action. Because IPL is a broad spectrum, it can cover multiple absorption peaks of various chromophores, such as melanin, oxidized hemoglobin, water, etc.¹⁴ In the treatment of pigmented dermatoses, melanin selectively absorbs the IPL spectrum, producing an "internal explosion effect" or "selective pyrolysis", resulting in the fragmentation of melanin particles, followed by the body's metabolism of these fragmented pigment particles, thereby improving hyperpigmentation.¹⁵

Conclusions

The mechanism of action of chemical peels and intense pulsed light in the intervention of hyperpigmentation is clear, but single treatment regimens, such as chemical peels with high concentrations of chemical peeling agents and intense pulsed light with high energy, still have the risk of inducing new hyperpigmentation.¹⁶ However, single treatment regimens such as chemical peels with high concentrations of chemical peeling agents and intense pulsed light with high energy still have the risk of inducing hyperpigmentation, so we used a combination of two treatment regimens with low concentrations and low energy to reduce the incidence of these adverse reactions.^{17,18}

In summary, we report a case of facial hyperpigmentation caused by minocycline using a combination of chemical peel and IPL. Although limited, this case supports that the combination of fruit acids with IPL may reduce the use of excessive concentrations of fruit acids and is an effective treatment option for minocycline-induced skin hyperpigmentation.

Ethics Statement

The publications of images were included in the patient's consent for publication of the case. The Hospital Ethics Committees of the Fifth People's Hospital of Hainan Province approved to publish the case details.

Consent Statement

Informed consent was provided by the patient for publication of the case.

Funding

This project supported by Hainan Province Clinical Medical Center.

Disclosure

The authors have no conflicts of interest to declare for this work.

References

1. Valentin S, Morales A, Sánchez JL, Rivera A. Safety and efficacy of doxycycline in the treatment of rosacea. *Clin Cosmet Investig Dermatol*. 2009;2:129–140. doi:10.2147/ccid.s4296
2. Nisar MS, Iyer K, Brodell RT, Lloyd JR, Shin TM, Ahmad A. Minocycline-induced hyperpigmentation: comparison of 3 Q-switched lasers to reverse its effects. *Clin Cosmet Investig Dermatol*. 2013;6:159–162. doi:10.2147/CCID.S42166
3. Barrett T, de Zwaan S. Picosecond alexandrite laser is superior to Q-switched Nd: yAGlaser in treatment of minocycline-induced hyperpigmentation: a case study and review of the literature. *J Cosmet Laser Ther*. 2018;20:387–390. doi:10.1080/14764172.2017.1418514
4. Rivers JK, Zarbafian M, Vestvik B, Kawamura S, Ulmer M, Kuritzky LA. Minocycline-induced hyperpigmentation: rapid resolution after 755nm alexandrite picosecond laser treatment. *J Cosmet Laser Ther*. 2020;22:96–99. doi:10.1080/14764172.2020.1740275
5. Bhardwaj V, Sharma K, Maksimovic S, Fan A, Adams-Woodford A, Mao J. Professional-Grade TCA-lactic acid chemical peel: elucidating mode of action to treat photoaging and hyperpigmentation. *Front Med*. 2021;8:1–9. doi:10.3389/fmed.2021.617068
6. Sarkar R, Ghunawat S, Garg VK. Comparative study of 35% glycolic acid, 20% salicylic-10% mandelic acid, and phytic acid combination peels in the treatment of active acne and postacne pigmentation. *J Cutan Aesthet Surg*. 2019;12:158–163. doi:10.4103/JCAS.JCAS_135_18
7. Ahmed NA, Mohammed SS, Fatani MI. Treatment of periorbital dark circles: comparative study of carboxy therapy vs chemical peeling vs mesotherapy. *J Cosmet Dermatol*. 2019;18:169–175. doi:10.1111/jocd.12536
8. Li N, Han J, Hu D, et al. Intense pulsed light is effective in treating postburn hyperpigmentation and telangiectasia in Chinese patients. *J Cosmet Laser Ther*. 2018;20:436–441. doi:10.1080/14764172.2017.1418517
9. Fritz K, Salavastru C. Laserbehandlung von Pigmentstörungen [Laser treatment of pigmentation disorders]. *Hautarzt*. 2020;71:920–925. doi:10.1007/s00105-020-04716-x
10. Lu J, Wu W, Zhang M, Wang P, Niu M, Yang X. Wells Syndrome Successfully Treated with Tripterygium Glycosides. *Clin Cosmet Investig Dermatol*. 2021;14:1029–1031. doi:10.2147/CCID.S328578
11. Haskes C, Shea M, Imondi D. Minocycline-induced scleral and dermal hyperpigmentation. *Optom Vis Sci*. 2017;94(3):436–442. doi:10.1097/OPX.0000000000001024
12. Sharad J. Glycolic acid peel therapy - A current review. *Clin Cosmet Investig Dermatol*. 2013;6:281–288. doi:10.2147/CCID.S34029
13. Vemula S, Maymone MBC, Secemsky EA, et al. Assessing the safety of superficial chemical peels in darker skin: a retrospective study. *J Am Acad Dermatol*. 2018;79:508–513. doi:10.1016/j.jaad.2018.02.064
14. Starkman SJ, Mangat DS. Chemical peels: deep, medium, and light. *Facial Plast Surg*. 2019;35(3):239–247. doi:10.1055/s-0039-1688944
15. Husain Z, Alster TS. The role of lasers and intense pulsed light technology in dermatology. *Clin Cosmet Investig Dermatol*. 2016;9:29–40. doi:10.2147/CCID.S69106
16. Weinkle AP, Doktor V, Emer J. Update on the management of rosacea. *Clin Cosmet Investig Dermatol*. 2015;8:159–177. doi:10.2147/CCID.S58940
17. El Arabi Y, Hali F, Chiheb S. Laser management and safety in dermatology. *Cureus*. 2022;14:25991. doi:10.7759/cureus.25991
18. Kim J, Lee J, Choi H. Intense pulsed light attenuates UV-induced hyperimmune response and pigmentation in human skin cells. *Int J Mol Sci*. 2021;22:1–13. doi:10.3390/ijms22063173

Clinical, Cosmetic and Investigational Dermatology

Dovepress

Publish your work in this journal

Clinical, Cosmetic and Investigational Dermatology is an international, peer-reviewed, open access, online journal that focuses on the latest clinical and experimental research in all aspects of skin disease and cosmetic interventions. This journal is indexed on CAS. The manuscript management system is completely online and includes a very quick and fair peer-review system, which is all easy to use. Visit <http://www.dovepress.com/testimonials.php> to read real quotes from published authors.

Submit your manuscript here: <https://www.dovepress.com/clinical-cosmetic-and-investigational-dermatology-journal>