

This is an Open Access article licensed under the terms of the Creative Commons Attribution-NonCommercial 3.0 Unported license (CC BY-NC) (www.karger.com/OA-license), applicable to the online version of the article only. Distribution permitted for non-commercial purposes only.

Two Case Reports of Resensitization to Previous Chemotherapy with the Novel Hypoxia-Activated Hypomethylating Anticancer Agent RRx-001 in Metastatic Colorectal Cancer Patients

T. Reid^a S. Dad^a R. Korn^b B. Oronsky^c S. Knox^d J. Scicinski^c

^aMoores Cancer Center, UCSD, La Jolla, Calif., ^bImaging Endpoints, Scottsdale, Ariz.,

^cRadioRx, Inc., Mountain View, Calif., ^dStanford University Medical Center, Stanford, Calif., USA

Key Words

Epigenetic resensitization · Oxidation · Hypoxia activation

Abstract

The development of chemoresistance is a persistent problem during the treatment of cancer. Although reversion or modification of acquired chemoresistance has been previously observed, no systematic exploration has been undertaken. Here, we report a case study of 2 male patients, 62 and 66 years old, both with histologically proven, radiologically progressing, extensively pretreated, metastatic and refractory (≥ 2 conventional regimens and drug therapy) colorectal adenocarcinoma that was previously treated with FOLFIRI. The patients were resensitized to FOLFIRI after exposure to RRx-001 in the context of a phase-1 study. RRx-001 is a novel, hypomethylating and free-radical-inducing anticancer agent that activates nitrite reduction to NO under hypoxia and has an impact on epigenetic pathways. The repression of DNA methyltransferase 1 by RRx-001 may lead to demethylation and reexpression of silenced tumor suppressor genes, leading to resensitization. These examples provide insight into a nascent strategy to improve the prognosis in heavily pretreated cancer patients and suggest routes for further exploration.

© 2014 S. Karger AG, Basel

Jan Scicinski, PhD
RadioRx, Inc.
Mountain View, CA 94040 (USA)
E-Mail jscicinski@radiator.com

Introduction

RRx-001 is a novel, small-molecule, hypomethylating agent with pro-oxidant-induced anticancer activity including the inactivation of DNA methyltransferase 1 (DNMT1) and a favorable toxicity profile compared with standard cytotoxic and targeted agents [1]. RRx-001, sourced from the aerospace industry [2], alters the structure and function of hemoglobin [3], leading to the intensive production of reactive oxygen and nitrogen species within a small subset of red blood cells. The changes in structure and nitrite reductase function of hemoglobin result in increases in the oxidative state of red blood cells through NO production [4] and free radical release that increases tumor levels of reactive oxygen and nitrogen species and changes vascular flow, particularly in the hypoxic milieu of the tumor, leading to epigenetic effects that include the oxidation and inactivation of DNMT1. DNMT1 in cancer is associated with hypermethylation and thereby silencing of CpG islands of tumor suppressor genes such as p53. The viability of tumor cells is highly dependent on the tumor microenvironment for oxygen derived from blood, but also on the supporting cells within this environment. RRx-001 disrupts the blood flow to tumors [1, 5], presumably through NO generation and thereby reactive oxygen and nitrogen species levels, enhancing hypoxic cell death. These effects could also alter critical cell-to-cell signaling within the tumor stroma that can potentiate cancer cell death while minimizing normal tissue toxicity. The changes in tumor blood flow and intercellular signaling patterns caused by RRx-001 put tumor cells under fundamentally different environmental stress than genotoxic chemotherapeutic agents. Consequently, cells adapted to survival after exposure to genotoxic agents may not be well adapted to survival under conditions inducted by altering NO levels within a tumor. During the course of conducting a phase-1 study of patients with various cancers treated with RRx-001, we observed several patients who had enrolled with rapidly progressive disease in whom tumor growth was arrested for periods of 6–9 months while on study. A state of persistent, stable disease is unusual among such patients. The eventual progression of disease in these patients suggested that these tumors adapted to the selective anticancer pressure applied by RRx-001. However, since many months are required for adaption to RRx-001, changes in the gene expression profiles of these tumors are to be expected. Resensitization to genotoxic chemotherapeutic agents indicates that fundamental changes in chemoresistance patterns could have occurred.

The safety of RRx-001 administered once/week i.v. has been demonstrated in a phase-1 dose escalation study where RRx-001 was generally well tolerated, without clinically significant drug-related laboratory abnormalities or systemic toxicity. Moreover, subjects with a broad range of cancer types, including the pancreas, lung, colon, head and neck, brain and ovaries, experienced clinical monotherapeutic benefit as measured by an improvement in tumor-related symptoms in conjunction with shrinkage or stabilization of their tumor using Response Evaluation Criteria in Solid Tumors (RECIST) v1.1.

Treatment options for metastatic colorectal cancer (mCRC) are noncurative. Therefore, the primary objectives of therapy are to extend progression-free and overall survival while maximizing quality of life for the patient [6]. Leucovorin-modulated 5-fluorouracil plus oxaliplatin and/or irinotecan (FOLFOX and FOLFIRI, respectively) with or without antiangiogenics such as bevacizumab, cetuximab or panitumumab has emerged as the standard of care in the first- and second-line setting [7]. However, mCRC is a disease with a dismal prognosis, and progression is sadly inevitable through all lines of therapy. Limited therapeutic options exist due to both diminishing efficacy of repeated courses of therapy and cumulative toxicities in spite of the recent approval of the oral multikinase inhibitor regorafenib as third/fourth-line monotherapy.

The mCRC patient is a ‘ticking clock’, progressing algorithmically from therapy to therapy until resistance to all five active classes of agents develops.

The entrenched clinical dogma in oncology is ‘once refractory always refractory’. Therefore, the ability to overcome prior chemoresistance and resensitize to previously failed agents represents an important and highly desirable strategy to improve clinical outcomes and prolong survival by significantly affecting the natural history of this disease.

Case Presentations

Case 1

A 62-year-old man with a chief complaint of hematochezia was diagnosed with KRAS wild-type cancer of the sigmoid colon in 2007. The patient was initially treated with FOLFIRI+bevacizumab, and when the disease progressed, he received several therapies both alone and in combination: cetuximab, bevacizumab, capecitabine, gemcitabine, oxaliplatin, axitinib and irinotecan. On enrollment in the phase-1 study of the experimental drug RRx-001, a computed tomography (CT) scan revealed multiple metastases in the liver, bone and lungs. The patient received RRx-001 at a dose of 10 mg/m² weekly over a period of approximately 9 months, receiving a total of 39 doses. RRx-001 was well tolerated, with the only treatment-related toxicity being pain on infusion that was readily managed. During this time, the patient had stabilization of his disease and was essentially asymptomatic. In addition, his ECOG performance status improved from 1 to 0, and he not only returned to full-time employment but also began to exercise vigorously.

After nearly 10 months of treatment with RRx-001, he had progressive disease with elevation of the carcinoembryonic antigen (CEA) and increased tumor size, and was therefore discontinued from the trial. During the 2-week period between discontinuation of RRx-001 and resumption of a new therapy, there was a rapid increase in the slope of his CEA levels, suggesting that RRx-001 had suppressed tumor growth even after he met the criteria for progression.

The principal investigator (T.R.) restarted FOLFIRI, and the patient was treated for approximately 5 months, resulting in a sharp decline in the CEA levels from 511 to 162 (fig. 1). After 5 months of therapy, a rise in CEA (table 1) and a CT scan confirmed progression, and the treatment regimen was discontinued.

Case 2

A 66-year-old male with unresectable mCRC was treated with the FOLFOX therapy as first-line chemotherapy and with FOLFIRI combined with cetuximab upon progression after first-line therapy. Although the patient achieved a response to this regimen, the course was complicated by a persistent grade 2/3 skin rash. After 6 months on the second-line regimen, his disease again progressed, and the patient entered into the RRx-001 phase-1 clinical trial, receiving RRx-001 at 83 mg/m² once weekly, which he tolerated well. His disease stabilized for 6 months before progressing again (fig. 2, fig. 3). In the interval between stopping RRx-001 and restarting treatment (approx. 40 days), his disease progressed significantly, suggesting that RRx-001 had suppressed tumor growth even after he met the criteria for progression. Given the lack of other effective options, he was rechallenged with FOLFIRI, resulting in moderate tumor shrinkage after only 4 weeks and improvement of symptoms. The treatment of this patient is currently ongoing.

Discussion

The presumption in medical oncology, which has now acquired almost axiomatic validity, is that retreatment with failed chemotherapy, even if initially efficacious, is futile due to the emergence of acquired resistance. Herein, we report a novel therapeutic approach in which 2 patients who had previously failed FOLFIRI chemotherapy were sensitized to subsequent treatment with FOLFIRI after prolonged disease stabilization on an experimental phase-1 anticancer agent, RRx-001. This treatment modality resulted in tumor regression and improvement of symptoms in one patient and in a significant reduction in CEA and a time to progression of >5 months in the other, exceeding historical response rates in a second-line setting.

This clinically significant tumor resensitization to previously inactive chemotherapy suggests that the tumor adaptation to the novel hypoxia-activated, prooxidant hypomethylating agent RRx-001 oxidatively inactivated critical cysteine residues on enzymes such as DNMT1. This redox modification resulted in epigenetic changes, leading to a window of opportunity for the reintroduction of standard cytotoxic therapies such as FOLFOX or FOLFIRI to which resistance had previously developed. This concept challenges the entrenched clinical dogma of 'once refractory always refractory'.

In summary, RRx-001 holds promise as a paradigm-shifting anticancer agent with the potential to transform one-way chemotherapy-resistant mCRC progression into a pendulum, with conversion of resistance to sensitization and without additive toxicity, to potentially increase both survival and quality of life. At present, this is limited to 2 patients. However, this approach merits further investigation to determine which tumor types and chemotherapies are best suited to this therapeutic maneuver and how to optimize the combination and dosing schedule of RRx-001 with conventional cytotoxic agents for purposes of effective resensitization not only in colorectal cancer, but also in other malignancies that are difficult to treat.

References

1. Ning S, Bednarski M, Oronsky B, Scicinski J, Saul G, Knox SJ: Dinitroazetidines are a novel class of anticancer agents and hypoxia-activated radiation sensitizers developed from highly energetic materials. *Cancer Res* 2012;72:2600–2608.
2. Bednarski M, Oehler L, Knox S, et al: Cyclic nitro compounds, pharmaceutical compositions thereof and uses thereof. US Patent No 7507842B2. 2009.
3. Scicinski J, Oronsky B, Taylor M, et al: Preclinical evaluation of the metabolism and disposition of RRx-001, a novel investigative anticancer agent. *Drug Metab Dispos* 2012;40:1810–1816.
4. Fens M, Larkin S, Morris C, Fitch W, Scicinski J, Oronsky B, Kuypers F: NO or no NO, increased reduction of nitrite to nitric oxide by modified red blood cells. *Blood (ASH Annual Meeting Abstracts)* 2011;118:Abstract 2125.
5. Scicinski J, Oronsky B, Ning S, Minchinton A, Knox S: RRx-001 modulates intratumor blood flow in SCCVII and U87 tumors. *Cancer Res* 2012;72(suppl 1):4371.
6. Haggard FA, Boushey RP: Colorectal cancer epidemiology: incidence, mortality, survival, and risk factors. *Clin Colon Rectal Surg* 2009;22:191–197.
7. Hess GP, Wang PF, Quach D, Barber B, Zhao Z: Systemic therapy for metastatic colorectal cancer: patterns of chemotherapy and biologic therapy use in US medical oncology practice. *J Oncol Pract* 2010;6:301–307.

Table 1. CEA changes in case 1 after RRx-001

Day number	CEA	Treatment
252	419.7	
266	405.3	last dose RRx-001
273	416.1	
280	511.1	first dose FOLFIRI+bevacizumab
308	355.5	
336	311.8	
364	194	
392	162.7	
420	236.6	
434	259.4	last dose FOLFIRI+bevacizumab

Day numbers refer to the days after the first dose of RRx-001. The last dose of RRx-001 was on day 266 and the first dose of FOLFIRI+bevacizumab was 2 weeks later on day 280. Dosing was continued through to day 434.

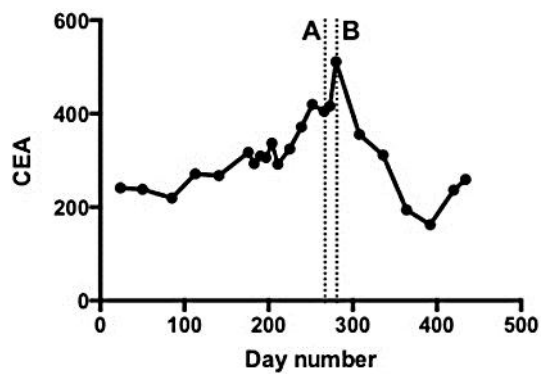


Fig. 1. Case 1: CEA changes demonstrate resensitization to a previously failed therapy. Time is shown as day number after the first dose of RRx-001. A: Last dose of RRx-001. B: First dose of FOLFIRI.

Reid et al.: Resensitization to Previous Chemotherapy with the Novel Hypoxia-Activated Hypomethylating Anticancer Agent RRx-001 in Metastatic Colorectal Cancer

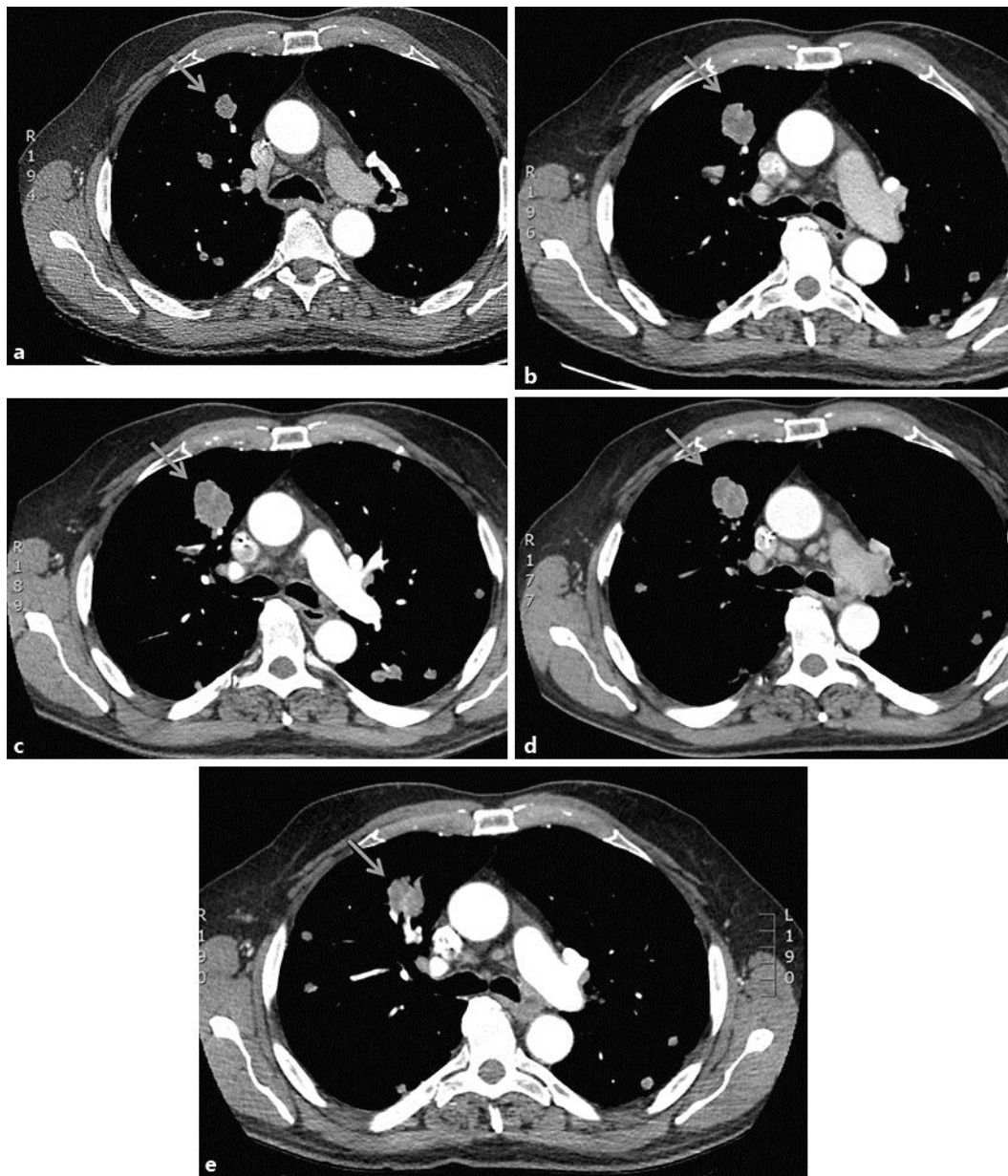


Fig. 2. CT images from case 2. Day numbers refer to the days after the first RRx-001 dose. The arrows indicate the target lesion whose change in longest diameter is shown in Figure 3. **a** Chest CT scan, measured at day 50 and showing stable disease. **b** Chest CT scan on day 186, showing an increased size of the mass in the right lung field. Dosing with RRx-001 was stopped. **c** Chest CT on day 228, 42 days after RRx-001 was stopped, showing a significant enlargement of the right upper lobe mass and interval nodule growth. The patient was not treated during this period. **d** Chest CT scan on day 256, approximately 4 weeks after treatment with FOLFIRI, was commenced, showing a modest reduction in the size of the right upper lobe mass and pulmonary lesions. **e** Chest CT scan on day 294, approximately 8 weeks after treatment with FOLFIRI was started, showing further tumor shrinkage.

Reid et al.: Resensitization to Previous Chemotherapy with the Novel Hypoxia-Activated Hypomethylating Anticancer Agent RRx-001 in Metastatic Colorectal Cancer

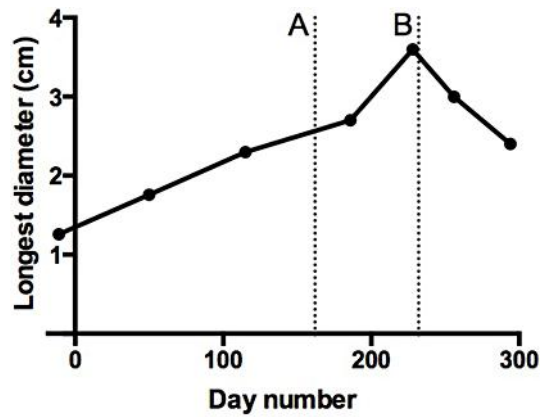


Fig. 3. Case 2: changes over time in the target lesion's longest diameter for the lesion depicted in figure 2 (arrows). Day numbers refer to the days after the first RRx-001 dose. A: Last dose of RRx-001. B: First dose of FOLFIRI.