

MILIARY SARCOIDOSIS: DOES IT EXIST? A CASE SERIES AND SYSTEMATIC REVIEW OF LITERATURE

Srinivas Rajagopala¹, Sakthi Sankari², Roopa Kancherla¹, Ramanathan Palaniappan Ramanathan¹, Devanand Balalakshmoji³

¹Department of Pulmonary Medicine, ²Department of Pathology and ³Radiodiagnosis, PSG Institute of Medical Sciences and Research, Peelamedu, Coimbatore, India

ABSTRACT. *Background and Objectives:* Sarcoidosis typically presents with peribronchovascular and perilymphatic nodules on high-resolution computed tomography (HRCT); a miliary pattern is reported but not well described. *Design, setting:* We describe four patients with miliary sarcoidosis and results of a systematic review of all previously reported cases from 1985 onwards. *Results:* We identified only 27 cases of “miliary” sarcoidosis in the HRCT era. These patients were older (85.2% older than 40 years), had more co-morbidities (72.7%) and were symptomatic compared to “typical” sarcoidosis. Respiratory symptoms were present in 61.9% at diagnosis. Hypercalcemia was seen in 28.5%. On review of HRCT images, only 34.6% (9/26) had a “true miliary” pattern without fissural nodules. In our series, prominent perivascular granulomas were seen on histopathology in all. 44.4% (12/27) had tuberculosis preceding or concurrent to miliary sarcoidosis. Of the eight true associations, tuberculosis preceded sarcoidosis by 52 (median, IQR 36) weeks in six and occurred concurrently in another two. The diagnosis of tuberculosis was clinical in all with concurrent diagnosis of tuberculosis and sarcoidosis. Treatment with steroids had 100% response and 14.2% relapse. *Conclusions:* A true miliary pattern in the HRCT era is very rare in sarcoidosis and subtle perilymphatic pattern is nearly always seen; this should be labeled “pseudo-miliary”. Prominent perivascular granulomas are associated with true miliary pattern. Miliary sarcoidosis patients are older and symptomatic, needing treatment at diagnosis. “Miliary” sarcoidosis may follow treatment for tuberculosis; concurrent cases possibly indicate the difficulty in differentiating both or a “tuberculo-sarcoid” presentation. (*Sarcoidosis Vasc Diffuse Lung Dis* 2020; 37 (1): 53-65)

KEY WORDS: sarcoidosis, miliary, micronodules, miliary tuberculosis

INTRODUCTION

Miliary sarcoidosis has been described as a rare presentation of sarcoidosis and was reported in <1% of all cases in the pre-computed tomography (CT)

era on chest radiography (1). With the advent of high-resolution-CT (HRCT), peribronchovascular and perilymphatic nodules in relation to the secondary pulmonary lobule are recognized as classic of sarcoidosis (2). However, random micronodules (miliary pattern) have been described and sarcoidosis is included in the differential diagnosis of a “miliary” pattern on HRCT (3, 4). There are no well-described series or systematic reviews of “miliary” sarcoidosis in the high-resolution CT (HRCT) era. On the other hand, tuberculosis continues to be a global pandemic with an estimated 10 million cases worldwide in 2016 (5). Miliary tuberculosis accounts for 1-2%

Received: 13 November 2018

Accepted after revision: 24 February 2020

Correspondence: Dr. Srinivas Rajagopala
Professor, Department of Pulmonary Medicine,
PSG Institute of Medical Sciences and Research,
Peelamedu, Coimbatore, India-641004
Tel. 91-422-2570170; 91-422-2598822
Fax 91-422-2594400
E-mail: visitsrinivasan@gmail.com

of all cases of new cases of tuberculosis and 8% of all extra-pulmonary tuberculosis (6). The relationship between tuberculosis and sarcoidosis continues to be enigmatic; tuberculosis can precede, follow or present concurrently with sarcoidosis (7). In patients with miliary tuberculosis, the clinical symptoms of night sweats, weight loss and fatigue are non-specific and overlap markedly with sarcoidosis. Respiratory symptoms are often minimal in either forms of miliary disease and microbiological evidence of *M.tuberculosis* is only present in 20-30% of miliary tuberculosis (8). Sarcoidosis has a characteristic perilymphatic pattern on histopathology and radiology (2); the co-relation of random nodules seen on radiology with pathology in “miliary” sarcoidosis is unclear. We describe a series of patients with miliary sarcoidosis and the results of our systematic review on miliary sarcoidosis in the HRCT era.

MATERIALS AND METHODS

We describe four patients with miliary nodules and proven sarcoidosis that was managed in the authors’ institution over three years and performed a systematic search of literature for miliary sarcoidosis.

Systematic search of literature

Two of the authors (R.S and R.K) conducted a systematic search of literature in PUBMED independently using the MeSH term “miliary” AND “sarcoidosis” limited to title/abstract and restricted the search from the year 1985 onwards (9). The choice of the year was defined by the first description of the current HRCT protocols and detailed description. This was further supplemented by search of IndMed using the same terms, the references of retrieved articles, our personal records and the Internet search engine GOOGLE. These articles were screened without blinding, by title and abstract review to identify relevant studies. Any discrepancy was resolved by consensus. Full texts or abstracts were then retrieved to identify the type of lung involvement in reported cases with miliary sarcoidosis. Only those articles that included patients with HRCT according to established protocols (9), included representative images or detailed descriptions and had a histological diagnosis compatible with sarcoidosis (10)

were included for analysis. For the purpose of this systematic review, we included all descriptions that were accepted as “miliary” in published cases but re-analyzed the images independently. The diagnosis of sarcoidosis was according to previous published guidelines (10).

Data extraction

Data was abstracted from selected cases in a pre-defined data extraction form (Supplementary Table).

Statistical analysis

Continuous data are presented as mean (standard deviation (SD), median [range or Interquartile Range (IQR)] and categorical data as percentages and proportions. All statistical analysis was done using the Statistical software SPSS Version 14.

Ethics

The Human Ethics Committee of PSG IMS&R, Coimbatore, approved the study. All data was anonymized to maintain patient confidentiality.

CASE REPORTS

Case 1

A 65-year-old lady presented with cough, night sweats and exertional breathlessness of two months’ duration. There was no history of weight loss or fever. Her past history was significant for hypertension and non-productive cough two years before that was evaluated at another center. CT had shown right paratracheal and bilateral hilar lymphadenopathy along with upper lobe-predominant micronodules. Tuberculin skin testing was negative and endobronchial ultrasound-guided needle aspiration (EBUS-FNA) and transbronchial lung biopsy (TBLB) were performed. EBUS-FNA showed few non-caseating granulomas and TBLB was non-contributory. A presumptive diagnosis of tuberculosis was made and four-drug anti-tuberculosis treatment (ATT) was administered for six months with improvement in cough. Examination was unremarkable during current evaluation. There was no exposure to pets, drugs

or occupational dusts. Chest radiography was normal. Spirometry was normal and diffusion capacity showed mild reduction. HRCT showed profuse random micronodules without lymphadenopathy and an upper-lobe and peripheral predominance that was visualized better with maximum intensity projection (MIP, Figure 1). Renal function tests, serum calcium and angiotensin-converting enzyme (ACE) levels were normal. Fiberoptic bronchoscopy (FOB) was done with bronchoalveolar lavage (BAL) and

TBLB; BAL Fluid was negative for acid-fast bacilli and Xpert MTB/RIF and TBLB showed interstitial inflammation only. Surgical lung biopsy was performed and showed extensive perivascular non-caseating granulomas (Figure 2). BAL mycobacterial cultures were subsequently reported as negative. She was started on steroids with resolution in cough and breathlessness by second month of treatment. She remains asymptomatic and off steroids after one year of treatment.

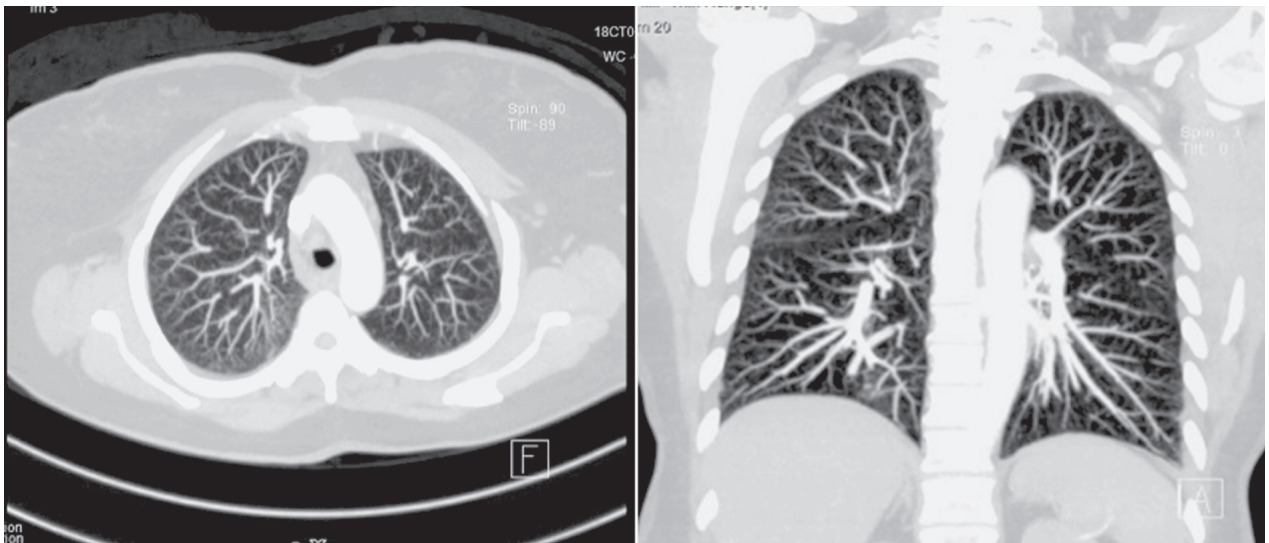


Fig. 1. Composite image of Maximal Intensity Projection images of high-resolution computed tomography (HRCT) of the thorax from patient 1 showing upper-lobe and peripheral-predominant miliary micronodules

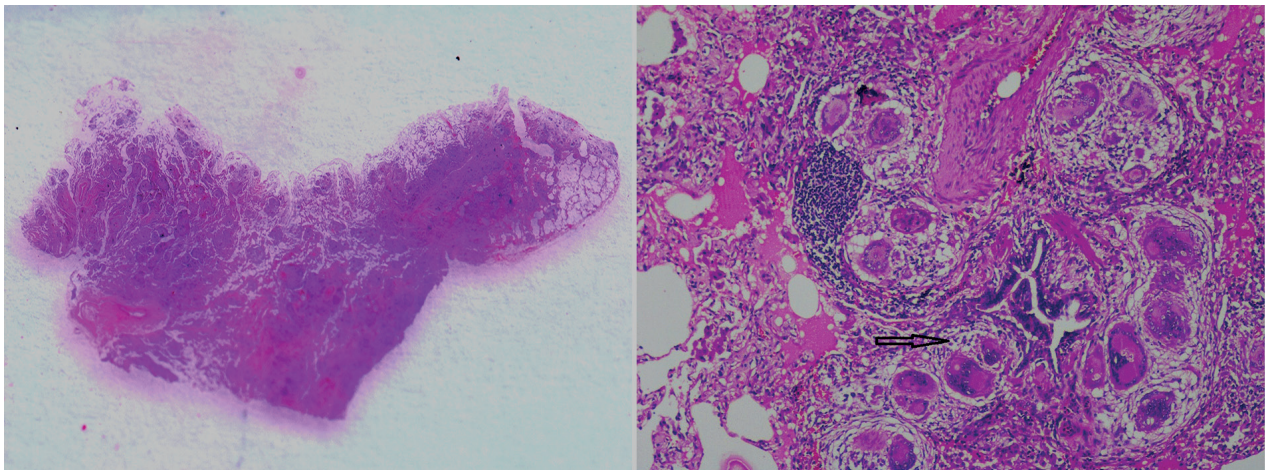


Fig. 2. Composite image of photomicrographs of surgical lung biopsy specimen of Patient 1 with left [Gross Pathological specimen, transverse plane] showing subpleural sparing and (right, Hematoxylin and Eosin stain (H & E), x 4) showing peribronchial and perivascular granulomas (arrow)

Case 2

A 40-year old gentleman presented with polyuria, fatigue and nausea of 20 days duration. There was also history of unquantified weight loss and exertional dyspnea. He did not smoke and did not raise pets, abuse drugs or have exposure to occupational dusts. Physical examination showed raised papulonodular skin lesions over hands and legs. Renal function tests showed serum creatinine of 2.65 mg/dL (normal <0.8 mg/dL); Urine microscopy showed 2+ albumin with bland sediments. Hemoglobin was 10.9 g/dL with normal leukocyte and platelet counts. Ultrasound showed normal kidney size with preserved corticomedullary distinction. Chest radiographs showed miliary nodules. Serum ionized calcium was 1.8 mg/dL (normal 1.1-1.3 mg/dL) with suppressed parathyroid hormone (1.9 pg/mL, normal 15-65) and normal vitamin D levels (23.6 ng/mL). ACE levels were elevated (98 U/mL, normal 8-53). Tuberculin skin testing was negative. CT-Chest showed random micronodules without zonal preponderance and bilateral hilar lymphadenopathy (Figure 3, left). FOB was done with BAL and TBLB; BAL was negative for acid-fast bacilli and Xpert MTB/RIF. TBLB showed perivascular non-caseating granulomas with Schaumann and asteroid bodies (Figure 4). Punch biopsy of the skin also showed non-caseating granu-

lomas in the dermis. He was started on steroids with resolution of hypercalcemia and normalization of renal function. His subsequent course was complicated by steroid-aggravated diabetes presenting with hyperosmolar coma; methotrexate was added and steroids were tapered. He remained asymptomatic with near-complete radiologic clearing (Figure 3, right) after one year of stopping methotrexate but relapsed by 18 months and remains on methotrexate.

Case 3

A 55-year old gentleman with moderately controlled diabetes mellitus presented with exertional breathlessness, cough, right-sided shoulder pain and weight loss of one month's duration. There was no anorexia or expectoration. He was a farmer by occupation and did not have exposure to poultry or occupational dusts and chemicals. Physical examination showed fine bilateral crepitations without clubbing. Renal function tests, serum calcium, urine microscopy, ACE levels and hemogram were normal. Chest radiographs showed miliary nodules (Figure 5, left). Human Immunodeficiency virus was negative by enzyme-linked sorbent assay. Tuberculin skin testing was strongly positive (18 mm, 1 TU). CT-Chest showed random micronodules without lymphadenopathy (Figure 6, left). FOB was done with BAL

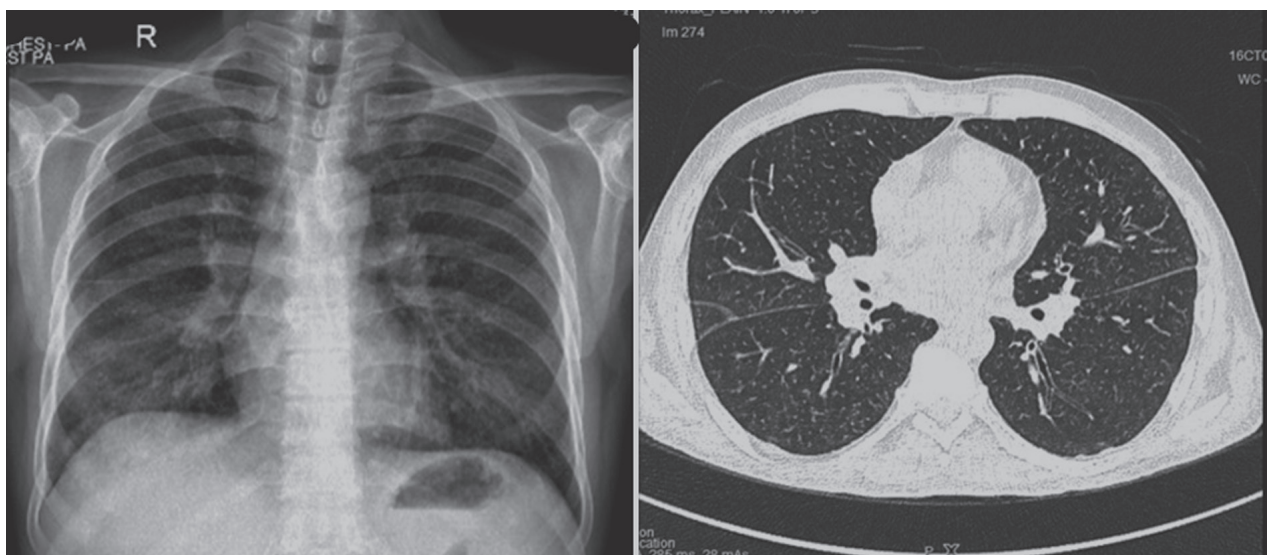


Fig. 3. Composite images of chest radiography of patient 2 showing miliary nodules (left) and HRCT images (major fissure level) showing upper-lobe-predominant random nodules. No involvement of the fissure or “beading” of the fissure is seen

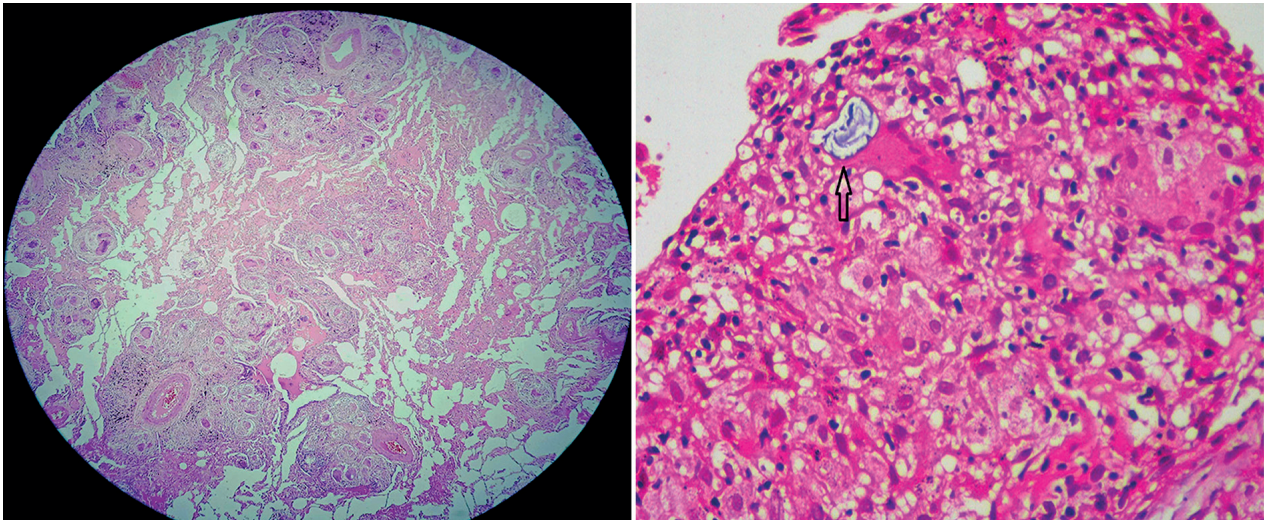


Fig. 4. Composite image of Photomicrographs of lung biopsy sample of Patient 2 with left, [Hematoxylin and Eosin stain (H & E), x scanner power] showing multiple non-necrotizing perivascular granulomas, and right, [H & E stain, x 40] showing a Schaumann body within a giant cell (arrow)

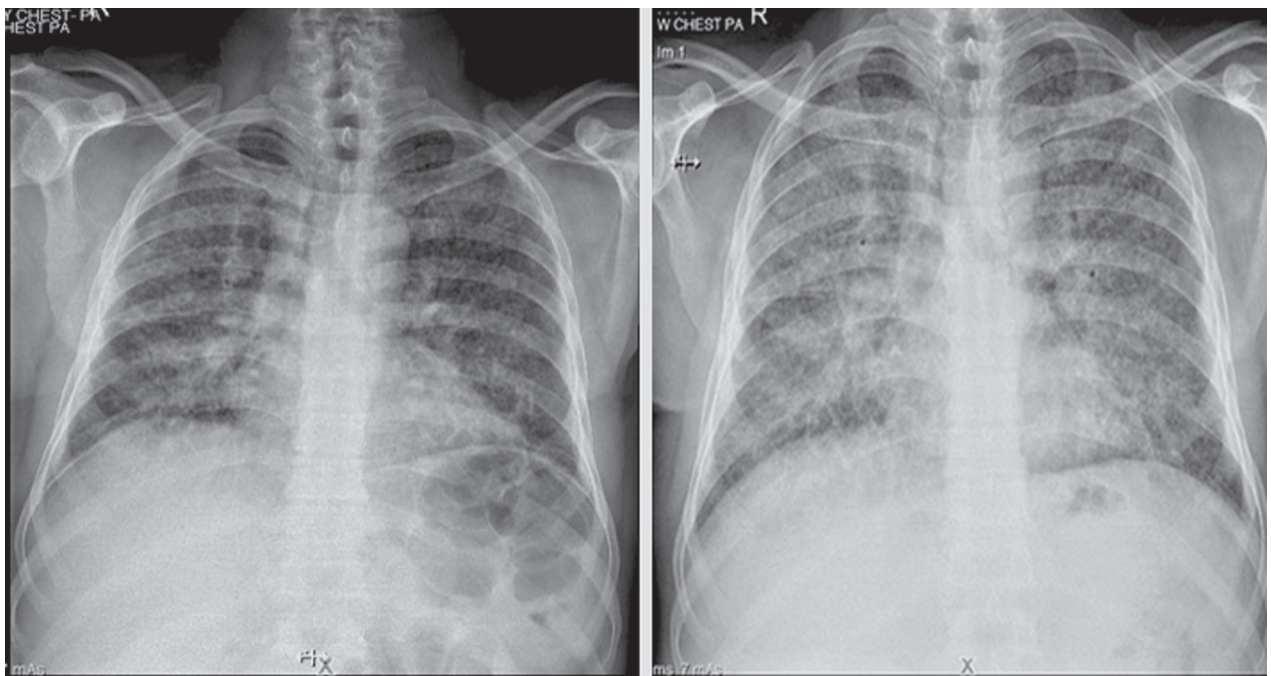


Fig. 5. Composite image of the Chest Radiographs of Patient 3 at initial evaluation (left) showing extensive miliary nodules. Subsequent Chest radiograph (right) after six weeks of anti-tuberculosis treatment alone show profusion of nodules with diffuse ground-glass opacification. Worsening hypoxemia was clinically noted

and TBLB; BAL was negative for acid-fast bacilli and Xpert MTB/RIF. TBLB showed well-formed perivascular granulomas with Langhans' giant cells, occasional fibrinoid necrosis and lymphocytes rim-

ming (Figure 6, right). A diagnosis of miliary tuberculosis was made and four-drug weight-based ATT was started. However, his symptoms continued to worsen with worsening nodules and development

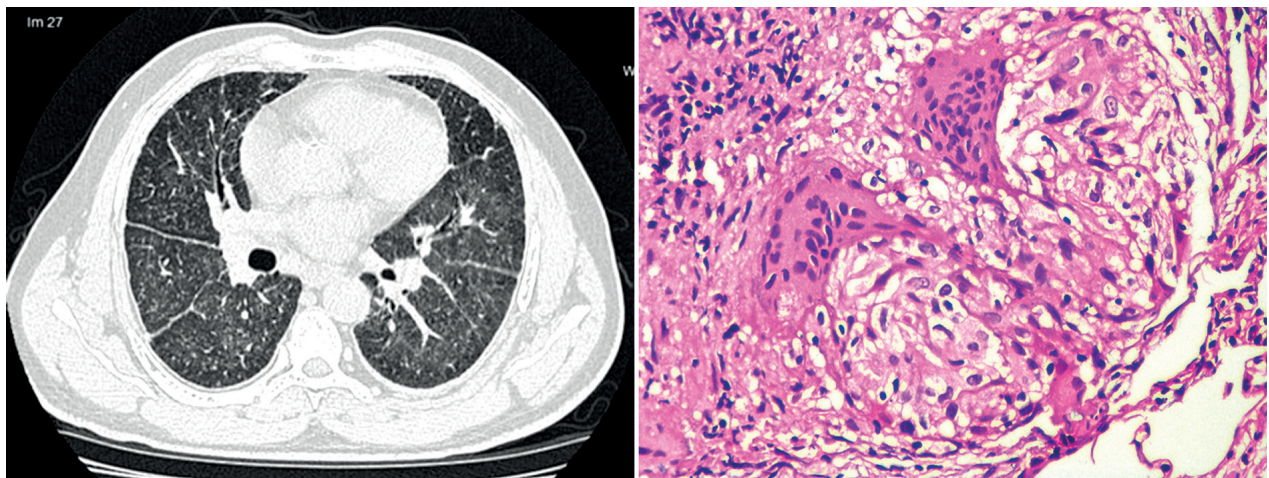


Fig. 6. Composite image of the HRCT image of Patient 3 at the level of major fissure during worsening hypoxemia corresponding to right-side of Figure 5 (left), showing random nodules with fissural prominence, with beading in both oblique fissures; some interlobular septal thickening and diffuse ground glass opacity can be seen and right, (Hematoxylin and Eosin stain, x 40) showing a non-necrotizing granuloma with peripheral lymphocyte cuffing

of hypoxemia needing oxygen at four weeks (Figure 5, right). BAL mycobacterial cultures were negative in the meantime. Steroids were added with a presumptive diagnosis of immune reconstitution syndrome, with resolution of hypoxemia and symptoms. Symptoms recurred after stopping steroids at four weeks; right-sided vision loss due to uveitis occurred. After a clinico-pathological review, a possibility of concurrent miliary tuberculosis with sarcoidosis was considered. ATT was continued and low-dose tapering steroids and methotrexate (in view of poorly controlled diabetes) were added, with complete resolution of symptoms by eight weeks. He remains asymptomatic after two years of cessation of ATT and methotrexate.

Case 4

A 48-year-old gentleman presented with fatigue for two weeks. There was no history of night sweats, weight loss or fever. He did not smoke, did not raise pets, abuse alcohol or drugs and did not report exposure to occupational dusts. Physical examination was normal. Renal function tests, urine microscopy and hemogram were normal. Serum calcium was elevated (1.43 mg/dL, normal 1.1-1.3). Chest radiographs showed miliary nodules (Figure 7, left). ACE levels were elevated (76 U/mL, normal 8-53). Tuberculin skin testing was negative. CT-Chest showed upper

lobe predominant random micronodules and lower-lobe interlobular septal thickening (Figure 8, left & right). FOB was done with BAL and TBLB; BAL was negative for mycobacterial cultures and Xpert MTB/RIF. TBLB showed prominent perivascular non-necrotizing epithelioid granulomas with asteroid bodies (Figure 7, right). A diagnosis of miliary sarcoidosis was made and steroids were initiated. His symptoms and hypercalcemia resolved by four weeks and steroids were tapered over the next nine months. He remains asymptomatic on follow-up.

RESULTS OF THE SYSTEMATIC SEARCH

Our systematic search identified 27 reports of miliary sarcoidosis in 21 reports (3, 11-30); this included 16 men and 9 women (Table 1, supplementary Table). This cohort of "miliary sarcoidosis" was older, was mostly symptomatic and had high co-morbidity burden. The mean age of the included patients was 47.5 ± 13.2 years; 85.2% were older than 40 years. 72.7% reported at least one associated co-morbidity (11, 12, 16, 18, 21, 27, 30).

The median time to presentation was 8 (IQR 12) weeks. The majority had symptoms at the time of presentation (90.9%, 20/22); only two patients recognized by surveillance transbronchial lung biopsies post-lung transplantation were asymptomatic

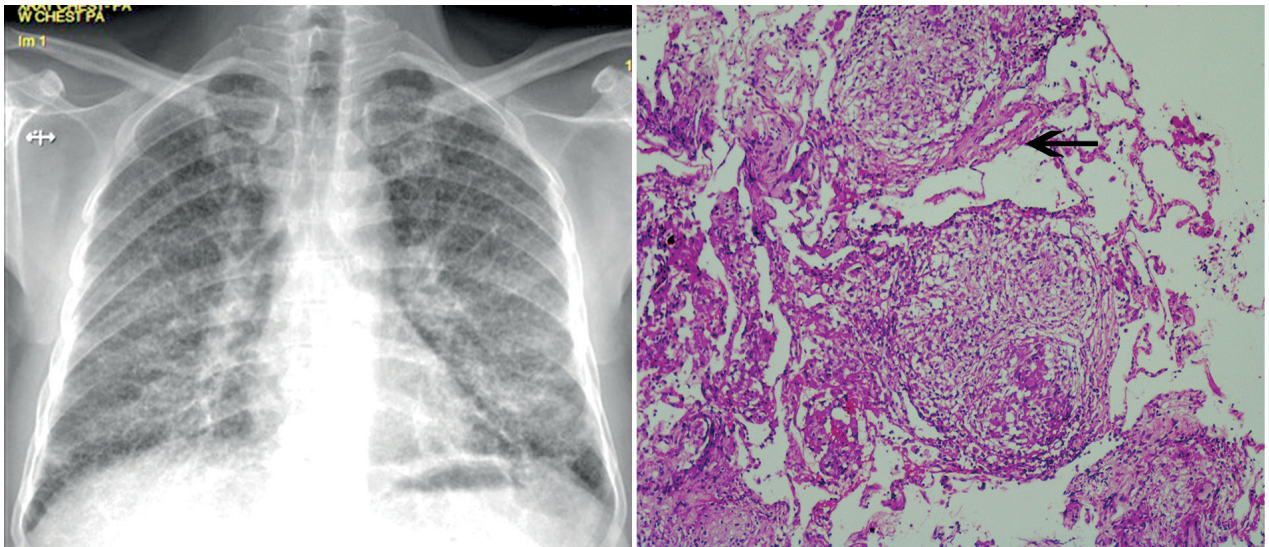


Fig. 7. Composite image of chest radiography images (left) of Patient 4 showing miliary nodules at diagnosis and photomicrographs of the lung biopsy specimen [right, Hematoxylin and Eosin stain (H & E) x4] showing multiple perivascular granulomas (arrow)

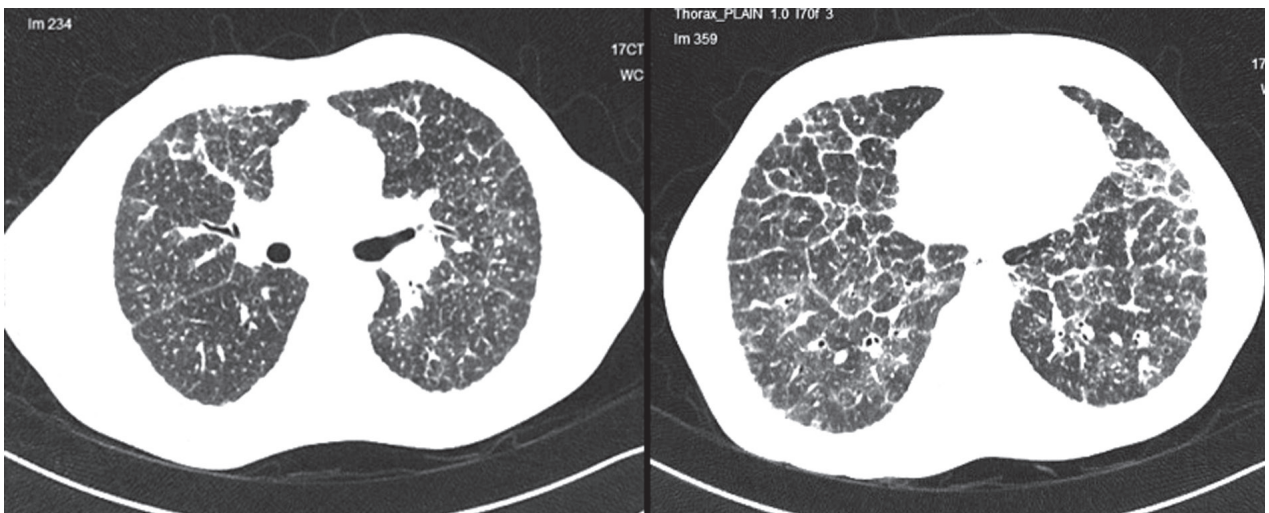


Fig. 8. Composite image of the HRCT image of Patient 4 showing (left, upper lobes) random nodules with perilymphatic predominance, beading of the right oblique fissure and perivascular nodules and (right, lower lobes) marked interlobular septal thickening in the lower lobes associated with random nodules

at diagnosis (11, 12). Respiratory symptoms, however, were present in 63.6% only at diagnosis (13, 14, 16, 20, 21, 23-25, 28-30). In those with respiratory symptoms, breathlessness and cough were present in less than 50% (45.4%). Fever (27.3%) (13, 21-23, 29), night sweats (11.1%) (22, 27) and weight loss (22.7%) (18, 22, 27) were all seen in a significant percentage at diagnosis.

Symptomatic multi-systemic disease in association with miliary sarcoidosis was seen in 36.4% (17, 19, 20, 23, 30). Hypercalcemia was seen in 27.3% (19, 20, 23, 27) and acute kidney injury was seen in 9.1% (19) at diagnosis. None needed dialysis but chronic kidney disease occurred in association with nephrocalcinosis (19). Ocular (13.6%, 3/22) involvement (25), bone (4.5%, 1/22) disease (17), sicca syndrome

Table 1. Summary of clinical features of all reported cases of thoracic sarcoidosis with miliary nodules on High-resolution Computed Tomography (N=27) ^s

Characteristic	Description
Age, Mean \pm S.D, N=24	47.5 \pm 13.2 years; Age >40 years 85.2%
Gender (Male: Female), N=25	16:9
	In those >40 years, Male: Females O.R 0.26, p=1.00 (61.9% vs 75%)
Country of description	India (10/26), United States (7/26), Greece (5/26), Japan (3/26), Germany (1/26)
Symptoms at presentation	
Any symptoms, N=22	None, asymptomatic (9.1%, 2/22)
Symptom duration prior to presentation, Median, IQR N=19	8, (12) weeks
Symptoms	Any respiratory symptom (63.6%, 14/22)
	Dyspnea (45.4%, 10/22), cough (45.4%, 10/22)
	Fatigue (30.4%, 7/23), fever (27.3%, 6/22), weight loss (22.7%, 5/22), night sweats (11.1%, 3/22)
Acute kidney injury	9.1%, 2/22
Hypercalcemia	27.3%, 6/22
Co-morbidities, N=22	Any 72.7% (16/22)
	Smoking (18.2%, 4/22), diabetes (13.6%, 3/22), hypertension (18.2%, 4/22), lung transplantation (9.1%, 2/22), dust exposure (13.6%, 3/22)
Symptomatic disseminated sarcoidosis	8/22 (36.4%)
Other site involvement	Ocular (13.6%, 3/22), pleural effusion (9.1%, 2/22), bone (4.5%, 1/22), sicca syndrome (4.5%, 1/22), pancreas (4.5%, 1/22)
Radiological findings (N=26)	
True miliary pattern on HRCT	17/26 (65.4%) only
Perilymphatic nodules on HRCT in miliary CT	8/17 (47.1%); Truly random nodules total 9/26 (34.6%)
Zonal predominance seen	Upper & middle (7/26, 26.9%), central (7.7%, 2/26), peripheral (19.2%, 5/26)
Fissural nodules	65.4% (17/26)
Peripheral subpleural predominance	69.2% (18/26)
Interlobular septal thickening	23.1% (6/26)
Intralobular septal thickening	11.5% (3/26)
Ground glass opacity	11.5% (3/26)
Mediastinal adenopathy	Yes (50%, 13/26); Right paratracheal (23.1%, 6/23), bilateral hilar (23.1%, 9/23), others (8.7%, 2/23)
Generalized lymphadenopathy	8.7% (2/23)
Steroid treatment	Yes 21/22 (95.2%), Response 100% (21/21)
Relapse	14.2% (3/21)
Tuberculosis and miliary sarcoidosis	
Both tuberculosis and sarcoidosis	Both tuberculosis and sarcoidosis 44.4% (12/27)
	Definite or probable tuberculosis followed by sarcoidosis 29.7% (8/27)
	Probable misdiagnosis of tuberculosis 33.3%, (4/12)
	Microbiologically proven 37.5% (3/8) of all cases only
	Sequential (87.5%, 7/8), concurrent (25%, 2/8) ^{ee}

(continued on next page)

Characteristic	Description
Time to sequential miliary sarcoidosis in those with tuberculosis preceding sarcoidosis, (Median, IQR) N=7	52 (36) weeks
Site of tuberculosis	Pulmonary 87.5% (7/8), spinal 12.5% (1/8)
Yield of TBLB, N=21	85.7% (18/21)
Miliary tuberculosis preceding or concurrent with miliary sarcoidosis	5/8 (62.5%), 2/5 with miliary TB preceding miliary sarcoidosis
ATT-induced hepatitis	2/8 (25%)

Abbreviations: S.D standard deviation, IQR Inter-quartile range, HRCT High-resolution Computed Tomography, TBLB transbronchial lung biopsy, ATT Anti-tuberculosis treatment

@@One patient had both sequential and concurrent diagnosis of tuberculosis and sarcoidosis

(4.5%, 1/22) (20) and pancreatic mass (4.5%, 1/22) (28) were the other manifestations seen. Pleural effusion was seen in association in 9.1% (2/22) (24, 28).

On review of the HRCT images, a “true miliary” pattern was seen in 65.4% (17/26) of the reported cases only. In these cases, fissural nodules and prominence could still be seen in 47.1% (8/17); only 34.6% (9/26) of reported cases could be classified as random micronodules on radiologic review (12-14, 17, 18, 24, 26, 28, 30). An upper and middle lobe distribution of nodules (11-13, 15, 16, 25-27) was seen in 26.9% (7/26) and a peripheral distribution was seen in 69.2% (11, 12, 15, 24, 28). Perilymphatic clustering of nodules (3, 11-18, 22, 24-26, 28) or a perivascular dominance (3, 13, 15, 19, 22, 26-28) of nodules was seen in 65.4% and 42.3% respectively. Interlobular septal thickening, often lower-lobe in distribution, was seen in 23.1% (Table 1) (12, 14, 15, 18). Mediastinal adenopathy was observed in 50% in association with micronodules and generalized systemic lymphadenopathy was seen in 8.7% of patients (19, 20).

44.4% (12/26) of the reported patients had tuberculosis preceding or concurrent to the diagnosis of miliary sarcoidosis (13-17, 20-22, 29). In four of these patients, this was likely a misdiagnosis (13, 14, 30). In eight patients, tuberculosis occurred preceding (15-17, 21, 22) sarcoidosis in six (62.5%), concurrently in one (37.5%) (29) and both in one (23). In those with tuberculosis preceding sarcoidosis, a microbiological confirmation was made in 42.9% (15-17, 22); Others were diagnosed based on pathology and clinical response (21). In patients with concurrent diagnosis of tuberculosis and sarcoidosis,

the diagnosis of tuberculosis was clinical in all; in all these patients, clinical and pathological findings, including caseous necrosis, were consistent with tuberculosis but clinical resolution occurred on initiation of steroids only (23, 29). The time to subsequent diagnosis of miliary sarcoidosis after treatment for tuberculosis was a median of 52 (IQR, 36) weeks. Miliary tuberculosis followed or concurrent with miliary sarcoidosis was reported in four patients (Table 2) (15, 16, 23, 29).

TBLB was the most common modality used for diagnosis and was reported as diagnostic in 85.7%. As most patients were symptomatic, treatment with steroids was offered in 95.2%, with 100% response. Methotrexate was administered in two patients for steroid-related severe adverse effects, with good response in both. Three patients (14.2%) relapsed after steroid taper; prompt response was noted on re-institution without further relapse.(21)

DISCUSSION

The description of “miliary” refers to small, well-defined, 1 to 3 mm nodules on chest radiography and is derived from Latin *miliarius*, meaning millet seed (8). This pattern implies hematogenous dissemination of disease and is classically associated with hematogenous spread of tuberculosis, fungal infections and malignancy (31). However, more than 40 diseases have been associated with this pattern on chest radiography (Table 2). The importance of quickly establishing the diagnosis, especially in high prevalence areas of tuberculosis, is that miliary tuberculo-

Table 2. Reported causes of miliary nodules on High-resolution Computed Tomography

Classification	Cause of miliary Nodules	Site of micronodules in SPL
Infectious	Mycobacterium tuberculosis	Random
	Disseminated Bacillus-Calmette-Guerin infection	Random
	Bacterial: Mycoplasma pneumoniae, Hemophilus influenzae	Centrilobular
	Fungal: Histoplasmosis, Coccidioidomycosis, hematogenous Candida infection	Random
	Viral: Varicella-zoster, cytomegalovirus	Centrilobular
	Parasitic: Tropical pulmonary eosinophilia	Centrilobular
Immunologic	Pneumoconiosis: Silicosis	Perilymphatic
	Pneumoconiosis: Coal worker's pneumoconiosis	Perilymphatic
	Hypersensitivity pneumonitis	Centrilobular
	Sarcoidosis	Perilymphatic
	Idiopathic pulmonary hemosiderosis	Centrilobular
	Pulmonary alveolar microlithiasis	Centrilobular
	Diffuse panbronchiolitis	Centrilobular
	Allergic bronchopulmonary aspergillosis	Centrilobular
	Malignancy	Secondaries from bronchogenic carcinoma
Others: melanoma, papillary thyroid carcinoma, renal, breast, Trophoblastic tumor, osteosarcoma		Random
Pulmonary Langerhans' cell histiocytosis		Random
Metastasizing leiomyoma		Random
Substance abuse	Lymphoma	Perilymphatic
	Excipient lung disease	Centrilobular

Abbreviations: SPL secondary pulmonary lobule

Table 3. High-resolution computed tomography findings in Thoracic Sarcoidosis (Modified from Criado et al)

Typical features	
Lymphadenopathy	Site (hilar, right paratracheal), bilateral, symmetrical, well defined. May show "cluster of black pearls" sign. If calcified, patchy or egg-shell
Nodules	Micronodules 2-4 mm, bilateral, well-defined, upper and middle zone and peri-hilar predominant. Peri-bronchovascular, subpleural, interlobular septal (peri-lymphangitic pattern)
Fibrotic changes	Interlobular septal thickening, Reticular opacities, architectural distortion, traction bronchiectasis
Atypical features	
Lymphadenopathy	Unilateral, isolated, anterior or posterior mediastinal
Nodules	Miliary
	Lower-lobe predominant, unilateral, "Halo" sign or "Atoll" sign
Consolidation	Mass-like opacities, conglomerate masses, solitary pulmonary nodules, confluent alveolar opacities and ground-glass opacities
Linear opacities	Intra-lobular septal thickening
Airway	Mosaic attenuation, trachea-bronchial abnormalities, atelectasis
Pleural	Effusion, chylothorax, pneumothorax, pleural thickening, calcification, plaque-like lesions

sis is the most common cause, has 25-30% mortality in adults and is invariably fatal if untreated (8).

The finding of a miliary pattern on chest radiographs was noted in early roentgenologic series of thoracic sarcoidosis; 1.3% (2/150) had "miliary" disease (1). Thoracic sarcoidosis has been reported to have several typical and atypical findings on HRCT; miliary is classified as an atypical finding (Table 3) (3). The description of micronodules by their distribution in relation to the "secondary pulmonary lobule" on HRCT along with the clarity of margins and attenuation further helps in narrowing the differential diagnosis of diffuse pulmonary micronodules. Micronodules can be accurately classified as having a centrilobular, perilymphatic or random distribution with their characteristic disease associations (Table 2) (4). Miliary nodules have a random distribution and can be seen in relation to pleural surfaces, small vessels and interlobular septa but do not have a consistent or predominant relationship to any of these (31). Given the reported prevalence of sarcoidosis varies from 4.5-36 per 100,000, the very small number of cases of "miliary" sarcoidosis reported in literature in the HRCT era (Table 1) suggests that this is a very rare occurrence. Most series of computed tomographic findings in sarcoidosis and a review on atypical findings in thoracic sarcoidosis did not report "miliary" sarcoidosis (32, 33).

Our systematic review suggests that this small reported number is an overestimate as a true miliary pattern was seen only in 34.6% (9/26) of the published cases of "miliary" sarcoidosis; and subtle perilymphatic pattern is nearly always seen and the term "pseudo-miliary" may be more appropriate. Distinct perilymphatic clustering of nodules or a perivascular dominance of nodules was seen in 65.4% and 42.3%; fissural nodules leading to the "beaded fissure sign" was prominent and seen in 65.4% of cases. Further, unlike true miliary nodules that lack any zonal predominance, an upper lobe and peripheral clustering was seen in 30.8% and 19.2% respectively. In all our patients with random micronodules, we observed a prominent perivascular distribution of micronodules on histopathology (Figures 2, 4, 6 and 8); two of these had associated "beaded fissure sign" on HRCT. Pathologically, sarcoidosis causes perilymphatic clustering of granulomas; hematogenous or airway spread has not been postulated (34). Profuse clustering of micronodules along the centrilobular and peri-

lymphatic compartments gives rise to an appearance of random nodules in the majority with a "pseudo-miliary" appearance. In the few patients with a true random pattern, prominent perivascular granulomas or drainage into the pulmonary lymphatics and subsequent dissemination by hematogenous route could be postulated.

The link between mycobacteria and sarcoidosis continues to be an enigma (7, 35). In the original descriptions, about 5% of sarcoidosis had tuberculosis preceding them. Polymerase chain reaction analyses of lung biopsies of sarcoidosis have shown mycobacterial DNA in 26.4%. (35) Tuberculosis may present concurrently and confound the diagnosis and management of these patients (23, 36, 37). It has been hypothesized that the immunological responses in sarcoidosis are analogous to "tuberculoid" or "pauci-bacillary" leprosy (38); persisting immunological responses to mycobacterial antigen can explain the extraordinarily high rates of tuberculosis preceding the diagnosis of pseudo-miliary sarcoidosis in the present systematic review.

The diagnosis of sarcoidosis rests on a constellation of clinical, radiological, histopathological and laboratory findings (39). Constitutional features including significant weight loss can occur in up to 25% of patients (Table 2). Fibrinoid necrosis and rarely, caseation can occur in sarcoidosis on histopathology (40, 41). Caseation may sometimes be absent in tuberculosis (41). Radiology can help in the differentiation of sarcoidosis from tuberculosis (26). The presence of hypercalcemia, skin involvement, negative tuberculin skin-testing, upper and middle-lobe distribution of nodules, a peripheral distribution of nodules when present and interlobular septal thickening all point to the diagnosis of "pseudo-miliary" sarcoidosis alone (42). However, sarcoidosis can precede, occur concurrent with or follow tuberculosis and differentiating tuberculosis from sarcoidosis remains a major challenge, especially in high prevalence areas of tuberculosis (43, 44). When the constellation of findings are non-conclusive, a trial of anti-tuberculosis treatment is appropriate in high prevalence areas given the very small number of true miliary sarcoidosis reported in literature. Steroids could be added when there is no clear response at 4-6 weeks (39, 43).

CONCLUSION

A true miliary pattern in the HRCT era is very rare in sarcoidosis and subtle perilymphatic pattern is nearly always seen; this pattern should be labeled “pseudo-miliary”. Prominent perivascular granulomas are associated with true miliary pattern. Miliary sarcoidosis patients are older and symptomatic and mostly need treatment at diagnosis. “Miliary” sarcoidosis may follow treatment for tuberculosis; concurrent cases possibly indicate difficulty in diagnosis or a “tuberculo-sarcoid” presentation. Transbronchial lung biopsy had a good yield for diagnosis. Most patients were symptomatic and treated with steroids, with 100% response and 14.4% relapse.

ACKNOWLEDGEMENTS

Dr. R.S, Dr. RM.PL and Dr. R.K were responsible for patient care and initiated the manuscript preparation and performed the systematic review. Dr. S.S reported the histopathologic findings of these patients and provided valuable inputs to the manuscript. Dr.B.D reviewed all the radiology images and the images retrieved from the systematic review for re-reporting.

Drs. R.S and Dr. S.S take responsibility for the content of the manuscript, including the data and analysis

The authors would like to thank Senior Librarian, PSGIMS&R, for his help in procuring manuscripts for the systematic review. No funding was utilized for this manuscript

REFERENCES

- Kirks DR, McCormick VD, Greenspan RH. Pulmonary sarcoidosis. Roentgenologic analysis of 150 patients. *Am J Roentgenol Radium Ther Nucl Med.* 1973;117(4):777-86. PubMed PMID: 4266919.
- Koyama T, Ueda H, Togashi K, Urmeoka S, Kataoka M, Nagai S. Radiologic manifestations of sarcoidosis in various organs. *Radiographics* : a review publication of the Radiological Society of North America, Inc. 2004;24(1):87-104. doi: 10.1148/rg.241035076. PubMed PMID: 14730039.
- Criado E, Sanchez M, Ramirez J, Arguis P, de Caralt TM, Perea RJ, et al. Pulmonary sarcoidosis: typical and atypical manifestations at high-resolution CT with pathologic correlation. *Radiographics* : a review publication of the Radiological Society of North America, Inc. 2010;30(6):1567-86. Epub 2010/11/13. doi: 10.1148/rg.306105512. PubMed PMID: 21071376.
- Raouf S, Amchentsev A, Vlahos I, Goud A, Naidich DP. Pictorial essay: multinodular disease: a high-resolution CT scan diagnostic algorithm. *Chest.* 2006;129(3):805-15. doi: 10.1378/chest.129.3.805. PubMed PMID: 16537886.
- Global tuberculosis report 2018. Geneva: World Health Organization; 2018. Licence: CC BY-NC-SA 3.0 IGO2018 10/11/2018.
- Sharma SK, Mohan A, Sharma A. Challenges in the diagnosis & treatment of miliary tuberculosis. *Indian J Med Res.* 2012;135(5):703-30. PubMed PMID: 22771605; PubMed Central PMCID: PMC3401706.
- Gupta D, Agarwal R, Aggarwal AN, Jindal SK. Sarcoidosis and tuberculosis: the same disease with different manifestations or similar manifestations of different disorders. *Curr Opin Pulm Med.* 2012;18(5):506-16. doi: 10.1097/MCP.0b013e3283560809. PubMed PMID: 22759770.
- Sharma SK, Mohan A, Sharma A, Mitra DK. Miliary tuberculosis: new insights into an old disease. *Lancet Infect Dis.* 2005;5(7):415-30. doi: 10.1016/S1473-3099(05)70163-8. PubMed PMID: 15978528.
- Zerhouni EA, Naidich DP, Stitik FP, Khouri NF, Siegelman SS. Computed tomography of the pulmonary parenchyma. Part 2: Interstitial disease. *Journal of thoracic imaging.* 1985;1(1):54-64. PubMed PMID: 3843414.
- Hunninghake GW, Costabel U, Ando M, Baughman R, Cordier JF, du Bois R, et al. ATS/ERS/WASOG statement on sarcoidosis. American Thoracic Society/European Respiratory Society/World Association of Sarcoidosis and other Granulomatous Disorders. Sarcoidosis, vasculitis, and diffuse lung diseases : official journal of WASOG. 1999;16(2):149-73. PubMed PMID: 10560120.
- Kazerooni EA, Jackson C, Cascade PN. Sarcoidosis: recurrence of primary disease in transplanted lungs. *Radiology.* 1994;192(2):461-4. Epub 1994/08/01. doi: 10.1148/radiology.192.2.8029415. PubMed PMID: 8029415.
- Kazerooni EA, Cascade PN. Recurrent miliary sarcoidosis after lung transplantation. *Radiology.* 1995;194(3):913. Epub 1995/03/01. doi: 10.1148/radiology.194.3.7863002. PubMed PMID: 7863002.
- Gupta D, Kumar S, Jindal SK. Bilateral miliary mottling without hilar lymphadenopathy: A rare presentation of sarcoidosis. *Lung India.* 1996;14(2):87-8.
- Chugh IM, Agarwal AK, Arora VK, Shah A. Bilateral miliary pattern in sarcoidosis. *The Indian journal of chest diseases & allied sciences.* 1997;39(4):245-9. PubMed PMID: 9654821.
- Voloudaki AE, Tritou IN, Magkanas EG, Chalkiadakis GE, Siafakas NM, Gourtsoyiannis NC. HRCT in miliary lung disease. *Acta radiologica (Stockholm, Sweden : 1987).* 1999;40(4):451-6. Epub 1999/07/08. PubMed PMID: 10394878.
- Hatzakis K, Siafakas NM, Bouros D. Miliary sarcoidosis following miliary tuberculosis. *Respiration; international review of thoracic diseases.* 2000;67(2):219-22. Epub 2000/04/25. doi: 10.1159/000029492. PubMed PMID: 10773799.
- Kline MY, Leibert EM. A case of pulmonary tuberculosis and miliary sarcoidosis. *Chest*2005. p. 480S-1S.
- Stroebe K, Haddadin H. Bilateral miliary sarcoidosis. *Chest*2012. p. 1036A.
- Hodges HK, Lee PY, Hausmann JS, Teot LA, Sanford EL, Levin KW. Hypercalcemia and miliary sarcoidosis in a 15-year-old boy. *Arthritis and rheumatism.* 2013;65(8):2112. Epub 2013/05/21. doi: 10.1002/art.38019. PubMed PMID: 23686651.
- Kumar P, Jaco MJ, Pandit AG, Shanmughanandan K, Jain A, Rajeev, et al. Miliary sarcoidosis with secondary Sjogren's syndrome. *The Journal of the Association of Physicians of India.* 2013;61(7):505-7. Epub 2014/04/30. PubMed PMID: 24772762.
- Bostantzoglou C, Samitas K, Gkogkou C, Zervas E, Gaga M. Mediastinal widening and miliary chest radiograph pattern in a middle aged man: could it be sarcoidosis? *BMJ case reports.* 2014;2014. Epub 2014/07/19. doi: 10.1136/bcr-2014-204884. PubMed PMID: 25035447; PubMed Central PMCID: PMC3987564.
- Luetkens JA, Zoghi S, Rockstroh JK, Naehle CP. Pulmonary sarcoidosis shortly after spinal tuberculosis infection: a diagnostic challenge. *BMJ case reports.* 2014;2014. Epub 2014/04/15. doi: 10.1136/bcr-2013-203333. PubMed PMID: 24728896; PubMed Central PMCID: PMC3987564.

23. Mandal SK, Ghosh S, Mondal SS, Chatterjee S. Coexistence of pulmonary tuberculosis and sarcoidosis: a diagnostic dilemma. *BMJ case reports*. 2014;2014. Epub 2014/12/21. doi: 10.1136/bcr-2014-206016. PubMed PMID: 25527682; PubMed Central PMCID: PMC4275725.
24. Enomoto Y, Yokomura K, Suda T. Bilateral pleural effusion associated with miliary sarcoidosis. *American journal of respiratory and critical care medicine*. 2015;191(4):474-5. Epub 2015/02/14. doi: 10.1164/rccm.201411-2022IM. PubMed PMID: 25679105.
25. Taki M, Ikegami N, Konishi C, Nakao S, Funazou T, Ariyasu R, et al. Pulmonary Sarcoidosis Presenting with Miliary Opacities. *Internal medicine (Tokyo, Japan)*. 2015;54(19):2483-6. Epub 2015/10/02. doi: 10.2169/internalmedicine.54.4681. PubMed PMID: 26424308.
26. Bhalla AS, Das A, Naranje P, Goyal A, Guleria R, Khilnani GC. Dilemma of diagnosing thoracic sarcoidosis in tuberculosis endemic regions: An imaging-based approach. Part 1. *Indian J Radiol Imaging*. 2017;27(4):369-79. doi: 10.4103/ijri.IJRI_200_17. PubMed PMID: 29379230; PubMed Central PMCID: PMC5761162.
27. Chaddha U, English R, Daniels J, Walia R, Mehta AC, Panchabhai TS. A 58-Year-Old Man With Fatigue, Weight Loss, and Diffuse Miliary Pulmonary Opacities. *Chest*. 2017;151(6):e131-e4. Epub 2017/06/11. doi: 10.1016/j.chest.2016.11.015. PubMed PMID: 28599946.
28. Matsuura S, Mochizuka Y, Oishi K, Miyashita K, Naoi H, Mochizuki E, et al. Sarcoidosis with Pancreatic Mass, Endobronchial Nodules, and Miliary Opacities in the Lung. *Internal medicine (Tokyo, Japan)*. 2017;56(22):3083-7. Epub 2017/09/26. doi: 10.2169/internalmedicine.8916-17. PubMed PMID: 28943576; PubMed Central PMCID: PMC5725865.
29. Arar O, Boni F, Meschi T, Tana C. Pulmonary sarcoidosis presenting with miliary opacities. *Current Medical Imaging Reviews*. 2018. doi: 10.2174/1573405614666180806141415.
30. Joshi V, S. Jain, V. Sharma, N. Khippal, Chaturvedi A. Granulomatous Hepatitis with Miliary Mottling: A Rare Cause. *Journal of The Association of Physicians of India*. 2018;66:97-8.
31. Andreu J, Mauleon S, Pallisa E, Majo J, Martinez-Rodriguez M, Caceres J. Miliary lung disease revisited. *Current problems in diagnostic radiology*. 2002;31(5):189-97. PubMed PMID: 12419999.
32. Kuhlman JE, Fishman EK, Hamper UM, Knowles M, Siegelman SS. The computed tomographic spectrum of thoracic sarcoidosis. *Radiographics : a review publication of the Radiological Society of North America, Inc*. 1989;9(3):449-66. doi: 10.1148/radiographics.9.3.2727355. PubMed PMID: 2727355.
33. Cozzi D, Bargagli E, Calabro AG, Torricelli E, Giannelli F, Cavigli E, et al. Atypical HRCT manifestations of pulmonary sarcoidosis. *La Radiologia medica*. 2018;123(3):174-84. doi: 10.1007/s11547-017-0830-y. PubMed PMID: 29124658.
34. Spagnolo P, Rossi G, Trisolini R, Sverzellati N, Baughman RP, Wells AU. Pulmonary sarcoidosis. *Lancet Respir Med*. 2018;6(5):389-402. doi: 10.1016/S2213-2600(18)30064-X. PubMed PMID: 29625772.
35. Gupta D, Agarwal R, Aggarwal AN, Jindal SK. Molecular evidence for the role of mycobacteria in sarcoidosis: a meta-analysis. *Eur Respir J*. 2007;30(3):508-16. doi: 10.1183/09031936.00002607. PubMed PMID: 17537780.
36. Smith-Rohrberg D, Sharma SK. Tuberculin skin test among pulmonary sarcoidosis patients with and without tuberculosis: its utility for the screening of the two conditions in tuberculosis-endemic regions. *Sarcoidosis, vasculitis, and diffuse lung diseases : official journal of WASOG*. 2006;23(2):130-4. PubMed PMID: 17937109.
37. Shah JR, Hede J, Mathur RS. Diagnostic criteria of tuberculous sarcoidosis. *Lung India*. 2009;26(3):86-8. doi: 10.4103/0970-2113.53232. PubMed PMID: 20442843; PubMed Central PMCID: PMC2862513.
38. Agarwal R, Gupta D. Tuberculous sarcoidosis: Is it a separate entity? *Lung India*. 2009;26(3):61-2. doi: 10.4103/0970-2113.53225. PubMed PMID: 20442837; PubMed Central PMCID: PMC2862507.
39. Jindal SK, Gupta D, Aggarwal AN. Sarcoidosis in India: practical issues and difficulties in diagnosis and management. *Sarcoidosis, vasculitis, and diffuse lung diseases : official journal of WASOG*. 2002;19(3):176-84. PubMed PMID: 12405486.
40. Karkhanis V, Joshi JM. All that caseate is not TB. *Lung India*. 2007(24):100-1.
41. Danila E, Zurauskas E. Diagnostic value of epithelioid cell granulomas in bronchoscopic biopsies. *Internal medicine (Tokyo, Japan)*. 2008;47(24):2121-6. doi: 10.2169/internalmedicine.47.1452. PubMed PMID: 19075536.
42. Bhalla AS, Das A, Naranje P, Goyal A, Guleria R, Khilnani GC. Dilemma of diagnosing thoracic sarcoidosis in tuberculosis-endemic regions: An imaging-based approach. Part 2. *Indian J Radiol Imaging*. 2017;27(4):380-8. doi: 10.4103/ijri.IJRI_201_17. PubMed PMID: 29379231; PubMed Central PMCID: PMC5761163.
43. Guleria R, Mahashur A, Ghoshal AG, Thomas PK, Raghu G, Baughman RP. Challenges in diagnosing Sarcoidosis in tuberculosis endemic regions: Clinical scenario in India. *Sarcoidosis, vasculitis, and diffuse lung diseases : official journal of WASOG*. 2016;33(4):381-4. PubMed PMID: 28079850.
44. Jain R, Mohan A, Guleria R. Sarcoidosis vs tuberculosis: Diagnostic mystery still unresolved. *Indian J Tuberc*. 2017;64(4):243-5. doi: 10.1016/j.ijtb.2017.09.001. PubMed PMID: 28941846.

Summary of all reported cases of thoracic sarcoidosis with miliary nodules on High-resolution Computed Tomography ^S

Author	Year	Age/ Gender	Symptom duration, Country	Clinical Features					Radiology findings			Histo- patholog y site	Outcome	Comments
				Fever/ Night sweats	Weight loss	Respiratory symptoms	Renal, electrolytes	Others	Miliary	Other distributions seen	Adenopat hy			
Kazerroni et al	1995	43/M	No symptoms, U.S	Asymptomatic; diagnosed on surveillance TBLB post-BLTx and HRCT images. In both cases, granulomas preceded the findings on HRCT (by 1 year in patient 1 and 2 years in patient 2)					No	Y; PL, UL pred	No	TBLB	Better; steroids @ 3 months	15 months post-BLTx
		44/F							No	Y; PL, IL, Peripheral	No	TBLB	No change, asymptomatic	27 months post-HBLTx
Gupta et al	1996	24/M	2 months, India	Fever +	No	Dyspnea, cough	No	Exposure to mines	No	Y, PL, Fissural, vessels	No	TBLB	Steroids; better @2 months	Misdiagnosed at TB. HRCT clear perilymphatic pattern
Chugh IM et al	1997	46/F	4 months, India	No	No	Dyspnea, cough	No	HTN	NA	Could not be assessed ^S	Yes; (R) H, PT	TBLB	Steroids, Better	Misdiagnosed at TB; given ATT
Voloudaki et al	1999	Mean 45/M (2); F(1)	This was a radiological series from Greece; clinical finding are not described. In "miliary" sarcoidosis, a clear subpleural, perilymphatic pattern with Fissural (beaded septum) is seen					No	IL+, Fissural nodules	Yes; all three	TBLB (1), SLBx (2)	3/7 with miliary nodules**, 1/3 miliary TB followed by "miliary" sarcoidosis		
Hatzakis	2000	47/M	NA, Greece	No	No	Cough	No	CAD/MI	Yes	Random nodules	SC nodes	SLBx	Steroids, better	**Miliary TB followed by miliary sarcoidosis (1 yr)
Kline et al	2005	53/F	4 months, U.S	No	No	No	No	Dizziness, Liver, skeletal lesions	No	Yes; PL	No	Calvarial Bx, Liver	Alive, better	%Pulmonary TB followed by multisystem sarcoidosis
Criado et al	2010	One case in a series on atypical findings of sarcoidosis; no clinical findings are reported							Yes	Y, Fissural nodules+, vessels	No	NA	NA	Image alone available
Stroebe et al	2012	53/F	4 months, U.S	Fatigue	27 Kgs	No	No	DM, HTN, COPD	NA	Y; Images not provided	Y; ML, H, HL	TBLB	Better, steroids	No images provided
Hodges et al	2013	15/M	3 months, U.S	Fatigue, nausea	No	No	AKI, Hypercalcemia	Skin, nephrocalcinosis, Gen LNE	Yes	Random	RP LNE	TBLB, Lymph node	Better, steroids @ 4 months	Truly miliary nodules on HRCT
Kumar et al	2013	45/M	3 months, India	Fatigue	No	Cough	Hypercalcemia	Sicca syndrome	Yes	Random	ML, HL, RP LNE	TBLB, Lip Bx	Better, steroids	Hepatic disease, glands
Bostantzoglu et al	2014	48/M	1 month, Greece	Fever	No	Cough, dyspnea	No	Thalassemia	Yes	Random	HL, (R)PT	TBLB, EBBx	Better, relapsed 18 months	#TB (clinical) followed by sarcoidosis
Mandal et al	2014	38/F	1 month, India	Fever	No	Cough, dyspnea	Hypercalcemia	Concurrent TB and sarcoidosis	Yes	Random	No	TBLB, Bone marrow+	Better on ATT & steroids	#TB 1 yr earlier, TB concurrent with sarcoidosis
Luetkens et al	2014	37/M	2 months, Germany	Fever, night sweats	Yes	No	No	INH resistant MTB spinal abscess+	Yes	Random, along vessels, fissures+	No	TBLB	Steroids, better @ 4 months	###TB followed by miliary sarcoidosis (8 weeks)

Author	Year	Age/ Gender	Symptom duration	Clinical Features					Radiology findings			Histo- pathology Site of diagnosis	Outcome	Comments
				Fever/ Night sweats	Weight loss	Respiratory symptoms	Renal, electrolytes	Others	Miliar y	Other distributions seen	Adenop athy			
Taki et al	2015	40/F	6 months, Japan	No	No	Dyspnea	No	Ocular	Yes	Random, upper & mid- zone, Fissural nodules +	HL, ML	TBLB	Better, steroids @1 year	Complete Clearing of nodules on CT at 1 year
Enomoto et al	2015	69/M	2 weeks, Japan	No	No	Dyspnea	No	Bilateral exudative, lymphocytic effusion	No	Upper, mid- zone, sub- pleural nodules+	No	TBLB inconclusive, thoroscopic pleural Bx	Steroids, better	Clear subpleural pattern on CT and Pathology
Bhalla et al	2017	Radiological collection of thoracic sarcoidosis; no clinical information is provided. One image of miliary sarcoidosis included							Yes	Random, Fissure+, along vessels	BHL	NA	NA	Image alone available
Matsuura et al	2017	78/F	2 months, Japan	No	No	Cough	No	Right pleural effusion	Yes	PL, fissural, sub-pleural nodules+	No	EUS-FNA, TBLB, EBBx	No treatment, better @1 year	Pancreatic mass, endobronchial nodules, effusion
Chaddha et al	2017	58/M	6 months	Night sweats, Fatigue, no fever	18 Kgs	None	Hyper- calcemia	Arthralgia, RA, Hypothyroid ism, A,F	Yes	Along vessels, Fissural nodules+	Y; SC, PT R, L	EBUS-FNA, TBLB	Better	Family history of sarcoidosis
Arar et al	2018	55/M	NA, India	Fever	No	Dyspnea	No	None	Yes	Random	No	TBLB, caseating granulomas	NA	?# concurrent TB, sarcoidosis
Joshi et al	2018	40/M	3 months, India	Fever	Anorexia	Cough	Hypercalci uria, normal serum Calcium	Hepatosplen omegaly, Skin; Nausea, vomiting	Yes	Fissural nodules+	BHL	Skin, BMA, TBLB negative; Liver Bx Granulomas	Better at 6 months of steroids	Diabetes, Psoriasis; empiric ATT
Rajagopala et al	2018	65/F	2 months, India	Night sweats	No	Dyspnea	No	Hypertensio n	Yes	Random, Fissural nodules+	No	TBLB negative; SLBx+	Better on steroids @ 1 year	#Prior diagnosis of tuberculosis
		40/M	20 days, India	Fatigue	Yes	Dyspnea	AKI, Hypercalce mia	Polyuria, nausea, skin lesions	Yes	Random	BHL	TBLB, Skin Bx	Better on MTX	Multi-system sarcoidosis, relapse@ 1 year
		55/M	1 month, India	No	Yes	Dyspnea	No	Ocular	Yes	Random	No	TBLB	Better on MTX @ 9 months	#Concurrent TB-sarcoidosis
		48/M	2 weeks, India	Fatigue	No	No	Hypercalce mia	Ocular	Yes	Random, IL+	No	TBLB	Better, steroids @8 months	

[§]Poor quality HRCT images precluded assessment of type of nodules; ^{**}In one miliary sarcoidosis followed miliary tuberculosis; [¶]Concurrent tuberculosis and miliary sarcoidosis with organomegaly, neurologic and bone involvement; [#]Tuberculosis was diagnosed based on pathology, radiology and clinical response; ATT stopped at 5 months due to liver injury; ^{###}Tb was diagnosed microbiologically based on mycobacterial cultures

Abbreviations: M Male, F Female, U.S United States, NA Not available, BLTx Bilateral lung transplantation, HBLTx Heart and lung transplantation, HRCT high resolution computed tomography, UL Upper lobe, PL Peri-lymphatic pattern, IL Interlobular nodules, ILo, Intralobular septal thickening, CAD coronary artery disease, MI Myocardial infarction, TB tuberculosis, DM Diabetes mellitus, HTN hypertension, COPD Chronic obstructive pulmonary disease, AKI acute kidney injury, INH isoniazid, ML Mediastinal, BHL bilateral Hilar lymphadenopathy, RPT Right paratracheal, LNE lymphadenopathy, Y Yes, Kgs kilograms, Bx biopsy, TBLB Transbronchial lung biopsy, SLBx surgical lung biopsy, EBUS-FNA endobronchial ultrasound guided fine needle aspiration, ATT Anti-tuberculosis treatment, MTX-Methotrexate