

# Nonintubated video-assisted thoracic surgery with high-flow oxygen therapy shorten hospital stay

Hui-Hsuan Ke<sup>a</sup>, Po-Kuei Hsu<sup>b,c</sup>, Mei-Yung Tsou<sup>a,c</sup>, Chien-Kun Ting<sup>a,c,\*</sup>

<sup>a</sup>Department of Anesthesiology, Taipei Veterans General Hospital, Taipei, Taiwan, ROC; <sup>b</sup>Department of Surgery, Division of Thoracic Surgery, Taipei Veterans General Hospital, Taipei, Taiwan, ROC; <sup>c</sup>Department of Anesthesiology, National Yang-Ming University, Taipei, Taiwan, ROC

## Abstract

**Background:** Nonintubated video-assisted thoracic surgery (VATS) is widely used due to its acceptable postoperative outcomes. Transnasal humidified rapid-insufflation ventilatory exchange (THRIVE) has been successfully applied in cases of prolonged difficult intubation and intensive respiratory care in patients receiving VATS lobectomy. Thopaz Digital Chest Drainage System (THOPAZ) provides regulated negative pressure close to the patient's chest, optimizing drainage of the pleural and mediastinum. We explored the surgical outcomes of nonintubated VATS lung wedge resection and traditional wedge resection with a double-lumen endotracheal tube.

**Methods:** Patients who received nonintubated VATS lung wedge resection (group A, n = 81) and traditional wedge resection with double-lumen endotracheal tube (group B, n = 79) during the period of November 2015 to April 2018 were enrolled in the study. Demographic data and operation outcomes were obtained and analyzed from review of patient medical charts.

**Results:** Group B had significantly longer mean induction and operative times than group A. Similarly, group B suffered greater intraoperative blood loss, longer postoperative hospital stays, and increased chest tube retention times than group A. Group A had higher partial pressure of carbon dioxide levels in both the pre-one-lung and during one-lung ventilation periods than group B. Furthermore, group A showed lower serum pH levels during one-lung ventilation period. However; group A had significantly higher partial pressure of oxygen levels during one-lung ventilation than group B, although the differences in peripheral oxygen saturation were not statistically significant.

**Conclusion:** Our study demonstrated that nonintubated VATS using THRIVE and THOPAZ in lung wedge resection provides measurable benefits to patients.

**Keywords:** Lung wedge resection surgery; Nonintubated video-assisted thoracic surgery; Thopaz Digital Chest Drainage System; Transnasal humidified rapid-insufflation ventilatory exchange; Transnasal humidified rapid-insufflation ventilatory exchange

## 1. INTRODUCTION

Nonintubated video-assisted thoracic surgery (VATS) is widely used due to its acceptable postoperative outcomes, including preserved respiratory function and lack of residual muscle relaxation or airway trauma.<sup>1,2</sup> Contrary to nonintubated VATS, studies have reported severe trauma associated with trachea intubation,<sup>3</sup> endobronchial catheters,<sup>4</sup> and endobronchial blockers.<sup>5</sup> Postoperative pulmonary complications were reported to be associated with residual muscle relaxation, particularly among elderly patients receiving prolonged surgical procedures.<sup>6</sup> Bronchospasm associated with intraoperative adjustment of lung separation devices through fiberoptic bronchoscopy is also

not uncommon.<sup>7</sup> The main advantage of nonintubated thoracic surgery would be decreasing the risk of prolonged air leak after lung volume reduction surgery.<sup>8</sup>

Transnasal humidified rapid-insufflation ventilatory exchange (THRIVE) has been successfully applied in cases of prolonged, difficult intubation and intensive respiratory care of patients.<sup>9</sup> One-lung ventilation with nonintubated VATS carries the risks of hypoxemia and hypercapnia, whereas THRIVE increases the oxygenation reserve status and efficiency of carbon dioxide (CO<sub>2</sub>) elimination.<sup>10</sup> Increased oxygenation and CO<sub>2</sub> elimination<sup>11,12</sup> reduce the respiratory dead space due to higher flow of oxygen.<sup>13</sup>

The Thopaz Digital Chest Drainage System (THOPAZ) has been widely used in thoracic surgery to provide regulated negative pressure close to the patient's chest, thus optimizing pleural and mediastinum drainage. The system provides real-time and periodic data, allowing for timely and objective decision making both during surgery and postoperatively. The standardization of the management of chest drainage across different surgeons and institutions has important clinical implications. However, no studies have reported the benefits of THOPAZ on postoperative recovery times for one-lung ventilation under spontaneous breathing after nonintubated VATS with thoracic epidural catheterization and thoracoscopic internal intercostal nerve block.

\*Address correspondence: Dr. Chien-Kun Ting, Department of Anesthesiology, Taipei Veterans General Hospital, 201, Section 2, Shi-Pai Road, Taipei 112, Taiwan, ROC. E-mail address: cking2@gmail.com (C.-K. Ting)

Conflicts of interest: The authors declare that they have no conflicts of interest related to the subject matter or materials discussed in this article.

Journal of Chinese Medical Association. (2020) 83: 943-949.

Received September 2, 2019; accepted April 13, 2020.

doi: 10.1097/JCMA.0000000000000408.

Copyright © 2020, the Chinese Medical Association. This is an open access article under the CC BY-NC-ND license (<http://creativecommons.org/licenses/by-nc-nd/4.0/>)

In this study, we explored the surgical outcomes of nonintubated VATS lung wedge resection with epidural anesthesia, THRIVE, internal intercostal nerve block, and the application of THOPAZ. We hypothesized that nonintubated VATS would be associated with earlier chest tube removal and reduced requirements for postoperative hospital stay.

## 2. METHODS

The study protocol was reviewed and approved by the Institutional Review Board of the Taipei Veterans General Hospital in Taiwan (approval number: 2017-01-016AC). Patients' informed consent was obtained for the study. Patients who received nonintubated VATS lung wedge resection (group A,  $n = 81$ ) and traditional wedge resection with double-lumen endotracheal tube (DLT) (group B,  $n = 79$ ) during the period of November 2015 to April 2018 were enrolled in the study. Surgeries were performed by several thoracic surgical teams, who performed either single-incision or multiple-incision thoracoscopic wedge resection surgery, based on team expertise.

### 2.1. Surgical and anesthesia procedures

Candidates for VATS were included in this study according to the following exclusion criteria; patients with lung tumors larger than 6 cm; central lung lesions; evidence of severe adhesions between the lung and the chest wall, diaphragm, or main bronchus; highly suspect or physician-diagnosed airway comorbidities, morbid obesity (body mass index [BMI]  $>35 \text{ kg/m}^2$ ), coagulopathy, or related anatomical deformities. These cases were divided into group A and group B according to their different type of anesthesia.

### 2.2. Group A: protocol for nonintubated video-assisted thoracic surgery maintained with transnasal humidified rapid-insufflation ventilatory exchange

Patients were preoxygenated using THRIVE prior to anesthesia at an initial flow rate of 30 L/min. Pulse oximetry, electrocardiography, and blood pressure and frontal bispectral index (BIS) monitoring (BIS Quatro; Aspect Medical System, Norwood, MA, USA) were performed during surgery. A detector was placed in front of the mouth or inserted into one nostril to monitor end-tidal carbon dioxide (ETCO<sub>2</sub>).

Patients were premedicated with 2 mg of intravenous midazolam and 200 µg of intravenous alfentanil. A thoracic epidural catheter was inserted between T7 and T8, where a testing dose of 2 mL of 2% lidocaine was given.

After preoxygenation and premedication, patients were sedated with intravenous propofol using target-controlled infusion (maintaining the BIS value between 40 and 60). Incremental intravenous injections of fentanyl and midazolam were given as needed. Epidural loading and maintenance doses were also administered according to the patient's blood pressure.

Patients were placed in the lateral decubitus position to perform VATS. Oxygen saturation was controlled and excessive hypercapnia avoided by applying THRIVE at a flow rate of 50 L/min (FiO<sub>2</sub> = 1.0), as well as conducting noninvasive ETCO<sub>2</sub> and invasive radial artery monitoring. Routine intraoperative monitoring was also performed. The incision was covered with a wound protector/retractor. An iatrogenic pneumothorax was created and the lung was collapsed while spontaneous respiration was maintained.

After lung wedge resection was completed, an internal intercostal nerve block was administered by the chief surgeon. Finally, a chest tube was inserted through the thoracoscopic incision wound, and THOPAZ was connected. The chest tube drainage condition was recorded every day. The criteria for chest

tube removed when drainage amount less than 400 mL/day with no air leakage noted for 24 hours. The patient was allowed to discharge 4 hours after chest tube removal.

### 2.3. Group B: protocol for video-assisted thoracic surgery with double-lumen endotracheal tube.

In total, 79 patients received intubated VATS with DLT. In general, patients were preoxygenated using an oxygen mask at a flow of 6 L/min prior to anesthesia. Pulse oximetry, electrocardiography, blood pressure monitoring, and ETCO<sub>2</sub> detection were carried out during surgery. Fentanyl, propofol, and cisatracurium were used for induction of anesthesia, and the inhalation agent sevoflurane was administered via DLT for maintenance of anesthesia. During the operation, the patient was placed in the lateral decubitus position and one-lung ventilation was performed. Single or multiple incisions were made, according to the expertise of the chief surgeon.

After the completion of lung wedge resection, an internal intercostal nerve block was administered. A chest tube was inserted through the thoracoscopic incision wound and THOPAZ was connected. The chest tube drainage condition was recorded every day. The criteria for chest tube removal and hospital discharge was same as group A.

### 2.4. Data collection and statistical analysis

Demographic data and operation outcomes were retrospectively obtained by review of medical charts. Anesthesia data; including oxygen saturation, preoperative, and intraoperative arterial blood gas data (partial pressure of carbon dioxide [PaCO<sub>2</sub>], partial pressure of oxygen [PaO<sub>2</sub>], and peripheral oxygen saturation); were obtained from the anesthetic records. Statistical analysis was performed using SPSS Version 22.0 (IBM Corp., Armonk, NY, USA). Categorical data were analyzed using the independent sample's *t* test and Pearson's chi-square test. Numerical data are presented as means ± SD. A *p* value of  $<0.05$  was considered to represent a statistically significant difference.

## 3. RESULTS

The demographic data of groups A and B are summarized in Table 1. No significant differences in gender, height and weight, BMI, American Society of Anesthesiologists classification, smoking status, preoperative pulmonary function, pathological diagnosis, or comorbidities were observed between the groups. Group B presented a larger mean tumor size ( $1.8 \pm 1.5$  vs  $1.2 \pm 0.8$  cm,  $p < 0.05$ ) than group A.

The perioperative results and treatment outcomes are presented in Table 2. The primary outcome was postoperative hospital stay (days). Group B had a significantly longer mean induction time ( $25.6 \pm 16$  vs  $20.6 \pm 10.5$  minutes,  $p < 0.05$ ) and operative time ( $171.8 \pm 70$  vs  $110.9 \pm 38.4$  minutes,  $p < 0.05$ ) than group A. Similarly, group B suffered greater intraoperative blood loss ( $45.4 \pm 57.2$  vs  $29 \pm 5.1$  mL,  $p < 0.05$ ), longer postoperative hospital stays ( $4.1 \pm 2.5$  vs  $2.8 \pm 1.4$  days,  $p < 0.05$ ), and increased chest tube retention time ( $3 \pm 2.5$  vs  $0.8 \pm 1.4$  days,  $p < 0.05$ ) than group A. The proportion of patients who suffered complications was similar for the two groups. The most common postoperative 30-day complication was subcutaneous emphysema (5% vs 11%,  $p = 0.16$ ). One case of perioperative mortality occurred in group B, caused by acute myocardial infarction one day after surgery.

The effects of arterial oxygenation and gas exchange are presented in Table 2 and Figures 1 and 2. Group A had higher PaCO<sub>2</sub> levels during both pre-one-lung and during one-lung ventilation periods than group B (pre-one-lung:  $37.3 \pm 7.9$  vs  $34.9 \pm 6$  mmHg,  $p < 0.05$ ; during one-lung:  $48.6 \pm 10.1$  vs  $39.3 \pm 6.4$

**Table 1**  
Characteristics of patients undergoing video-assisted thoracic surgery

Variables	Group A (n = 81)	Group B (n = 79)	p
Male	39 (48)	38 (48)	1.00
Female	42 (52)	41 (52)	
Age (y)	56.5 ± 16.8	52.3 ± 16.8	0.11
Height (cm)	161.7 ± 8.3	162 ± 9.6	0.83
Weight (kg)	61.4 ± 10.1	63.2 ± 12	0.32
BMI (kg/m <sup>2</sup> )	23.5 ± 3.3	23.9 ± 3.2	0.41
ASA classification			
I	5 (6)	8 (10)	0.40
II	59 (73)	55 (70)	0.73
III	17 (21)	16 (20)	1.00
Smoker	5 (6)	7 (9)	0.56
Pulmonary function test			
FEV <sub>1</sub> (% of prediction)	98.7 ± 19.9	93.2 ± 17.2	0.06
FEV <sub>1</sub> /FVC (% of prediction)	82.8 ± 7	81 ± 10.6	0.21
DLCO (% of prediction)	69.7 ± 16.6	68.2 ± 15.6	0.58
Airway resistance			
Normal	38 (47)	25 (32)	0.05
Mild increased airway resistance	11 (14)	8 (10)	0.63
Moderate increased airway resistance	8 (10)	9 (11)	0.80
Severe increased airway resistance	10 (12)	10 (13)	1.00
Lack of data	14 (17)	27 (34)	<0.05 <sup>a</sup>
Diagnosis			
Adenocarcinoma in situ	13 (16)	7 (9)	0.23
Minimal invasive adenocarcinoma	7 (9)	5 (6)	0.77
Adenocarcinoma	13 (16)	19 (24)	0.24
Metastatic lung cancer	23 (28)	28 (35)	0.40
Benign lung tumor	2 (2)	0 (0)	0.50
Others	23 (28)	20 (25)	0.72
Comorbidity			
No systemic disease	15 (19)	16 (20)	0.84
Hepatitis carrier	14 (17)	7 (9)	0.16
Extrapulmonary tumor	47 (58)	36 (46)	0.15
Cardiac disease	8 (10)	5 (6)	0.57
Hypertension	23 (28)	18 (23)	0.47
Diabetes mellitus	9 (11)	9 (11)	1.00
Pulmonary disease (COPD, asthma)	4 (5)	6 (8)	0.53
Tumor size (cm)	1.2 ± 0.8	1.8 ± 1.5	<0.05 <sup>a</sup>

Continuous data are presented as mean ± SD, categorical data are presented as n (%).

ASA = American Society of Anesthesiologists; BMI = body mass index; COPD = chronic obstructive pulmonary disease; DLCO = diffusing capacity for carbon monoxide; FEV<sub>1</sub> = forced expiratory volume-one second; FVC = forced vital capacity.

<sup>a</sup>p < 0.05 indicates a significant difference between groups A and B.

mmHg,  $p < 0.05$ ). Furthermore, group A showed lower serum pH values ( $7.3 \pm 0.1$  vs  $7.4 \pm 0$ ,  $p < 0.05$ ) during one-lung ventilation period. However, group A had significantly higher PaO<sub>2</sub> levels during one-lung ventilation period than group B ( $320.4 \pm 150$  vs  $245 \pm 115.6$  mmHg,  $p < 0.05$ ), although the differences in peripheral oxygen saturation were not statistically significant ( $98.5 \pm 2.8$  vs  $99 \pm 1.7$  mmHg,  $p = 0.23$ ).

#### 4. DISCUSSION

This study demonstrates that nonintubated VATS lung wedge resection with epidural anesthesia, THRIVE, internal intercostal nerve block, and THOPAZ (group A) results in more favorable surgical outcomes. The benefits of this procedure include shorter durations of anesthesia induction and surgery, higher intraoperative PaO<sub>2</sub>, reduced intraoperative blood loss, shorter postoperative hospital stays, and reduced chest tube retention

**Table 2**  
Perioperative results and treatment outcomes

Variables	Group A (n = 81)	Group B (n = 79)	p
Primary outcome			
Postoperative hospital stay (d)	2.8 ± 1.4	4.1 ± 2.5	<0.05 <sup>a</sup>
Secondary outcomes			
Anesthetic induction duration (min)	20.6 ± 10.5	25.6 ± 16	<0.05 <sup>a</sup>
Surgical duration (min)	110.9 ± 38.4	171.8 ± 70	<0.05 <sup>a</sup>
In room SpO <sub>2</sub> (%)	97.4 ± 2.1	97.3 ± 1.6	0.69
Arterial blood gas data pre-one lung ventilation			
pH	7.4 ± 0.1	7.4 ± 0.1	0.13
PaO <sub>2</sub> (mmHg)	348.3 ± 132.8	356.6 ± 100.1	0.66
PaO <sub>2</sub> /FiO <sub>2</sub>	1654 ± 635	1697.9 ± 476.7	0.62
PaCO <sub>2</sub> (mmHg)	37.3 ± 7.9	34.9 ± 6	<0.05 <sup>a</sup>
Saturation (%)	99.4 ± 1.2	99.5 ± 1.7	0.62
Arterial blood gas data during one-lung ventilation			
pH	7.3 ± 0.1	7.4 ± 0	<0.05 <sup>a</sup>
PaO <sub>2</sub> (mmHg)	320.4 ± 150	245 ± 115.6	<0.05 <sup>a</sup>
PaO <sub>2</sub> /FiO <sub>2</sub>	320.4 ± 150	245 ± 115.6	<0.05 <sup>a</sup>
PaCO <sub>2</sub> (mmHg)	48.6 ± 10.1	39.3 ± 6.4	<0.05 <sup>a</sup>
Saturation (%)	98.6 ± 2.7	98.9 ± 1.9	0.40
Intraoperative blood loss (mL)	29 ± 5.1	45.4 ± 57.2	<0.05 <sup>a</sup>
Conversion to thoracotomy	0 (0)	0 (0)	1.00
Intraoperative complication	0 (0)	0 (0)	1.00
Postoperative chest tube retention time (d)	0.8 ± 1.4	3 ± 2.5	<0.05 <sup>a</sup>
Postoperative 30-d complications			
Subcutaneous emphysema	4 (5)	9 (11)	0.16
Pneumothorax	2 (2)	0 (0)	0.22
Lung atelectasis after surgery	0 (0)	3 (3)	0.25
Pneumonia	0 (0)	1 (1)	1.00
Air leakage	1 (1)	4 (5)	0.21
Perioperative mortality, n (%)	0 (0)	1 (1)	1.00

Continuous data are presented as mean ± SD, categorical data are presented as n (%).

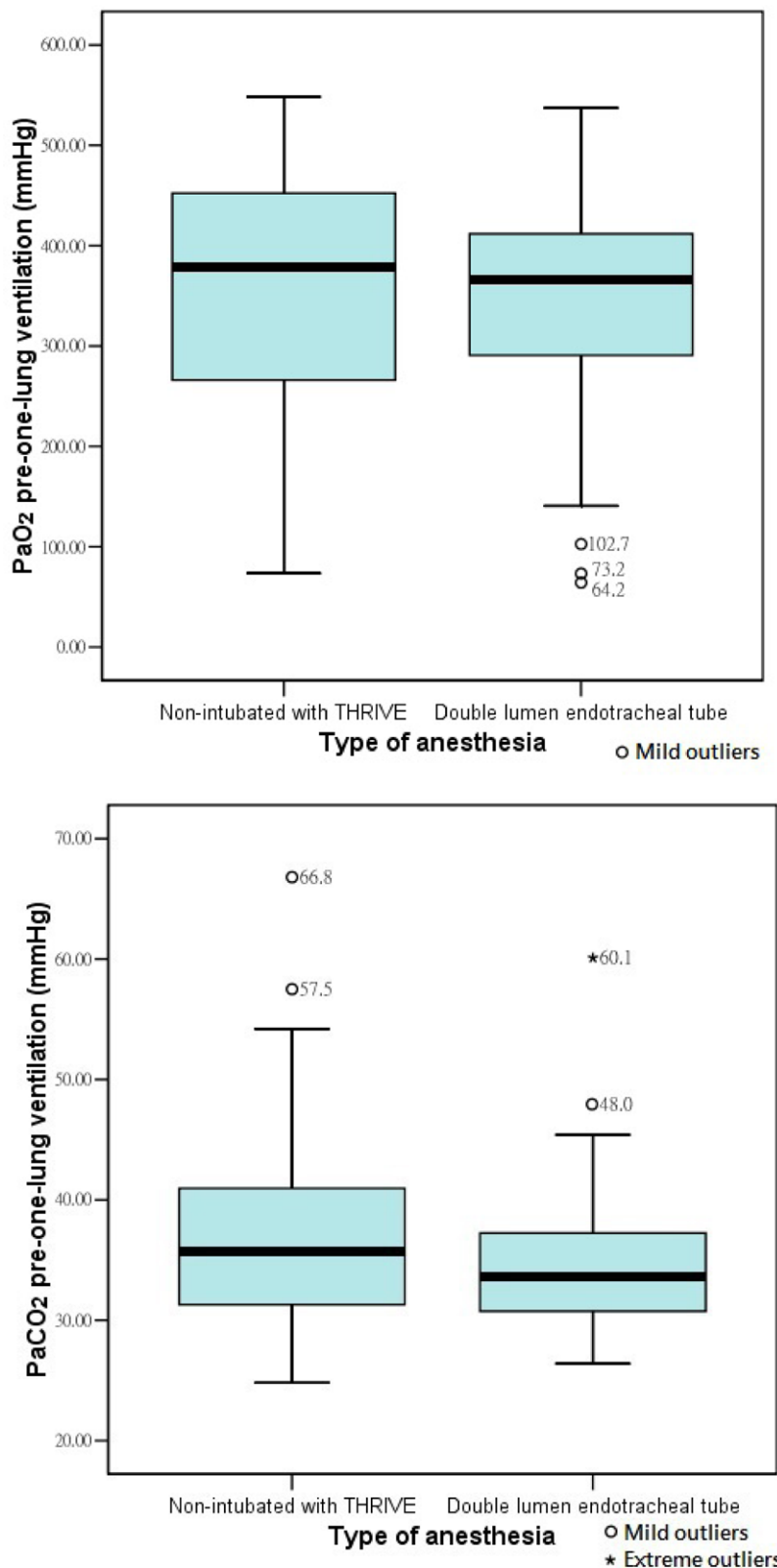
ASA = American Society of Anesthesiologists; BMI = body mass index; COPD = chronic obstructive pulmonary disease; DLCO = diffusing capacity for carbon monoxide; FEV<sub>1</sub> = forced expiratory volume-one second; FVC = forced vital capacity.

<sup>a</sup>p < 0.05 indicates a significant difference between groups A and B.

time compared with VATS wedge resection using DLT, inhalation anesthesia, internal intercostal nerve block, and THOPAZ (group B).

Our results of intraoperative PaO<sub>2</sub> levels indicate that THRIVE provides greater oxygenation and increases the margin of safety in BIS-targeted intravenous anesthesia; outcomes which have been similarly observed in a previous study.<sup>14</sup> The application of THRIVE with a 20L/min oxygen flow is feasible for successful nonintubated VATS, and provides a larger oxygen reserve during one-lung ventilation.<sup>15</sup> Our protocol included the use of THRIVE with a flow rate of 30L/min for induction of anesthesia, and 50L/min during one-lung ventilation, which provided continuous positive airway pressure to both the dependent and the collapsed lung. At the end of the surgical procedure, a chest tube was inserted and THOPAZ was connected, and the lung was recruited by the negative pressure of the THOPAZ system. Compared to a previous study carried out by the National Taiwan University Hospital,<sup>15</sup> which utilized flow rates of 20L/min during one-lung ventilation and 70L/min for recruitment, our protocol achieved higher mean PaO<sub>2</sub> levels during one-lung ventilation (320.4 vs 180 mmHg). Our results may represent very high PaO<sub>2</sub> levels compared with others that are reported in the current literature regarding the application of THRIVE in medical anesthesia.

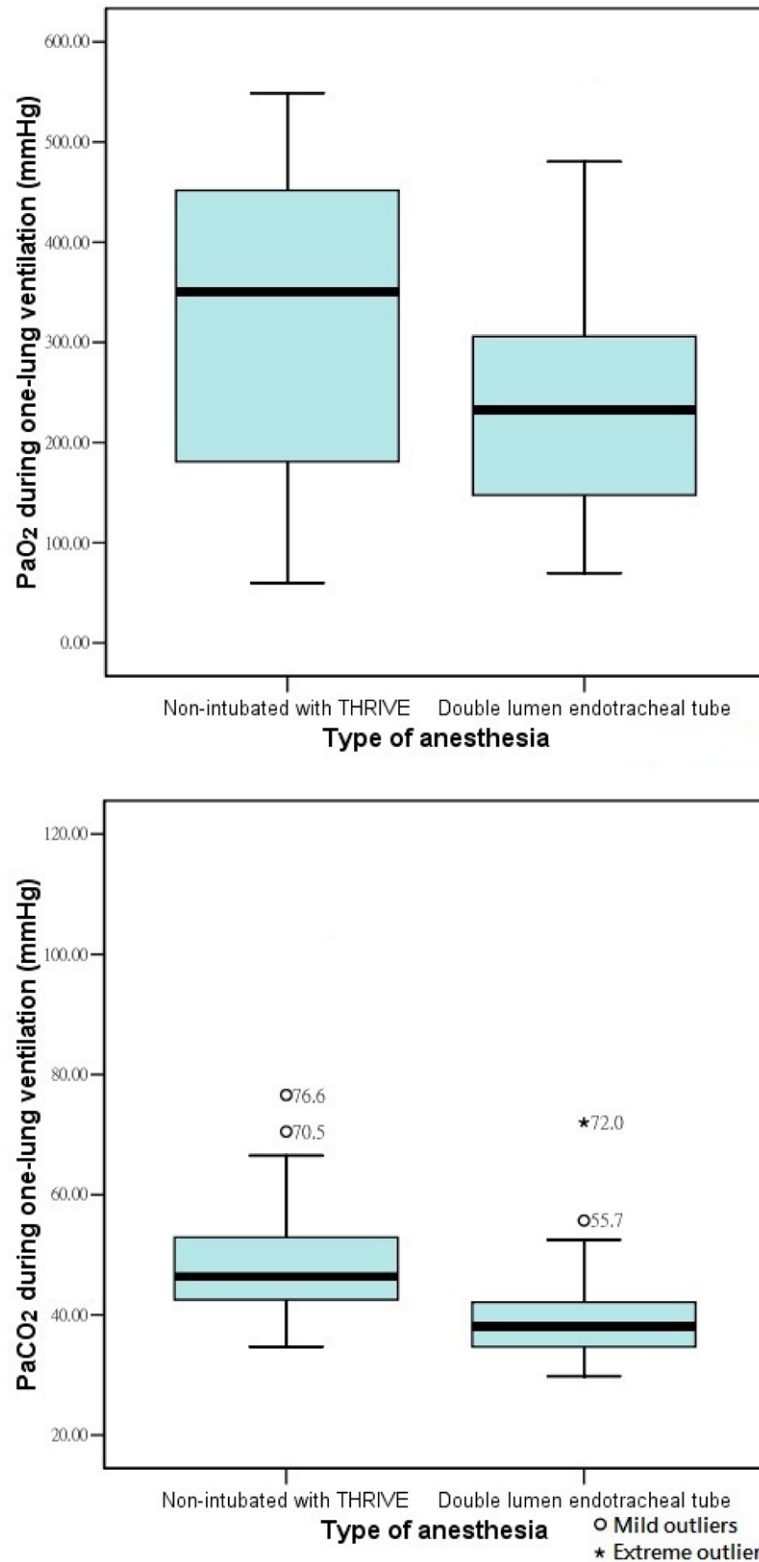
In our study, the pre-one-lung ventilation arterial blood gas data of Groups A and B were nearly identical, with the exception



**Fig. 1.** Preoperative arterial blood gas data. Preoperative arterial blood gas data were obtained from anesthesia records. Error bars indicate 95% CI. PaCO<sub>2</sub> = partial pressure of carbon dioxide; THRIVE = transnasal humidified rapid-insufflation ventilatory exchange.

of PaCO<sub>2</sub> levels. We performed the Jaw-Thrust Maneuver or applied nasopharyngeal airways for patients with slow spontaneous respiration rates or apnea during surgery. However,

CO<sub>2</sub> retention may still occur during spontaneous breathing with THRIVE, in contrast to DLT by ventilator which provides total gas exchange. The study of the National Taiwan University



**Fig. 2.** Intraoperative arterial blood gas data. Intraoperative arterial blood gas data were obtained from anesthesia records. Error bars indicate 95% CI. PaCO<sub>2</sub> = partial pressure of carbon dioxide; THRIVE = transnasal humidified rapid-insufflation ventilatory exchange.

demonstrated that the use of THRIVE with an oxygen flow rate of 20 L/min did not affect CO<sub>2</sub> elimination before or during one-lung ventilation, because the pulmonary dead-space elimination due to positive-pressure oxygen was associated with higher flow

rates.<sup>15</sup> Our PaCO<sub>2</sub> data of nonintubated VATS with THRIVE during one-lung ventilation was similar to this previous study (48.6 vs 48 mmHg).<sup>15</sup> The ETCO<sub>2</sub> data were not recorded in our study due to difficulties in placing the ETCO<sub>2</sub> detector. Placement



in front of the mouth or inserted into one nostril mean that the detector often became obstructed by the nasal oxygen cannula of THRIVE, resulting in inconsistent ET $\text{CO}_2$  detection.

The effects of arterial oxygenation and gas exchange of groups A and B are presented in Figures 1 and 2. In Figure 1, the three lower outliers of 102.7, 73.2, and 64.2 in PaO $_2$  pre-one-lung ventilation in Group B might be associated with the patients' lung quality themselves, such as increased airway pressure, low forced expiratory volume/forced vital capacity value and diffusing capacity for carbon monoxide value. The two higher outliers of 60.1 and 48 in PaCO $_2$  pre-one-lung ventilation in group B might be caused by CO $_2$  accumulation while transient apnea for position adjustment of double-lumen endotracheal tube or difficult airway management. More intra-pulmonary shunt due to larger tumor sizes was also a reason. Apart from lung quality, the higher outliers of in PaCO $_2$  pre-one-lung ventilation in group A were relevant to the depression of spontaneous respiratory rate and tidal volume, even apnea by opioid and propofol, especially happened in young patients. In Figure 2, other reasons for the outliers included longer surgical duration in both groups, deeper anesthesia depth in group A and dislodgement of double-lumen endotracheal tube in group B.

Regarding the surgical outcomes, group A showed significantly reduced intraoperative blood loss, postoperative hospitalization, and chest tube retention time than group B. This may be due to the differences in tumor size and position (predicted from preoperative computed tomography scans), and patient preoperative conditions between the groups. The selection criteria for this study were tumors that: were smaller than 6 cm; were located at the lung periphery; and had no evidence of severe adhesion to or involvement with chest wall, diaphragm, or main bronchus. Additionally, patients who had clinically suspect or physician-diagnosed airway complications, morbid obesity, coagulopathies, anatomical deformities, and complicated comorbidities were excluded.

Nonintubated thoracoscopic lobectomy<sup>16</sup> and segmentectomy<sup>17</sup> were firstly reported in 2011 and 2013 which included the use of the BIS to monitor the targeted level of conscious sedation and the block of the vagus nerve. Awake or sedated non-intubated VATS with epidural anesthesia<sup>18</sup> and THRIVE<sup>15</sup> were then applied.

Our study is unique in its application of THOPAZ in both group A and group B. Jurth et al.<sup>19</sup> suggested that objective measurement of postoperative air leaks and fluid output could lead to earlier removal of chest tubes.<sup>19</sup> The traditional three-bottle underwater seal chest drainage system has recently evolved to use single-chamber devices, with the liquid column acting as a one-way valve to enable fluid and air to escape from the thoracic cavity.<sup>20</sup> A preset, constant, and regulated suction pressure can be maintained. Connecting the THOPAZ system after surgery caused the lung to re-expand due to the negative intrapleural pressure provided by the system, which facilitated lung recruitment. This mechanism was significantly important to nonintubated VATS lung wedge resection (group A), which could not be applied lung recruitment maneuver by endotracheal tube as traditional wedge resection with DLT (group B). In the case of an air leak, the device remains active and produces additional suction to maintain the desired negative intrapleural pressure.<sup>21</sup> Furthermore, THOPAZ provides chest tube drainage data in a digitally retrievable format, which enables effective decision making for the removal of the chest drain. Its design also enables mobility, facilitating improved patient postoperative rehabilitation.<sup>20</sup> It has been suggested that THOPAZ will become mainstream in the postoperative management of general thoracic surgery;<sup>22</sup> however, the use of THOPAZ data for optimizing chest tube removal and postoperative hospital treatment following VATS lung wedge resection surgery requires further

evaluation. In summary, the advantages of the THOPAZ system in lung wedge resection surgery include: (1) digitalized evaluation of air-leaks and the timing for removal of the catheter; (2) constant and steady negative pleural pressure during lung re-expansion, and (3) controllable inflation of the lung without the need for recruitment maneuvers by the anesthesiologist. In our study, THOPAZ was used in both groups simultaneously, which both offered advantages in different aspects.

Both groups A and B had similar incidence rates for 30-day postoperative complications; including subcutaneous emphysema, pneumothorax, lung atelectasis after surgery, pneumonia, and air leakage. We carefully examined postoperative chest x-ray abnormalities to identify radiologic signs of progression and minimize complications requiring subsequent interventions. The mechanisms behind those abnormalities could include residual pleural space, infiltration of air into the subcutaneous layers from continuous air leaks, or inflammation-induced pleural fluid after VATS. One mortality occurred in group B, which was caused by acute myocardial infarction one day after surgery, which is a risk of anesthesia itself.

This was a retrospective study based on anesthesia records from November 2015 to April 2018; therefore, it may include recording and statistical biases. Randomized controlled trials are necessary to confirm the benefits of nonintubated VATS with THOPAZ for lung wedge resection. This study only collected lung wedge resection surgery; however, during major lung resection, accumulation of airway secretions, mucus or blood in the airway were potential causes of interruption of gas flow limiting the applicability of THRIVE. The benefits of utilization of THOPAZ data for determining chest tube removal and postoperative hospital admission periods following lung wedge resection surgery and other thoracic surgery require further study.

In conclusion, our study demonstrates that nonintubated VATS using THRIVE in lung wedge resection provides measurable benefits to patients including higher intraoperative PaO $_2$  levels, reduced intraoperative blood loss, and shorter postoperative chest tube retention times and hospital admission periods. The application of THOPAZ may also improve postoperative lung re-expansion. The extended application of nonintubated VATS with THRIVE and THOPAZ should be encouraged for lung wedge resection surgery.

## ACKNOWLEDGMENTS

This work was supported by the Taipei Veterans General Hospital [Grant numbers: V107C-109 and V107D31-004-MY3-1].

## REFERENCES

1. Fitzmaurice BG, Brodsky JB. Airway rupture from double-lumen tubes. *J Cardiothorac Vasc Anesth* 1999;13:322–9.
2. Stewart PA, Liang SS, Li QS, Huang ML, Bilgin AB, Kim D, et al. The impact of residual neuromuscular blockade, oversedation, and hypothermia on adverse respiratory events in a postanesthetic care unit: a prospective study of prevalence, predictors, and outcomes. *Anesth Analg* 2016;123:859–68.
3. Adriani J, Naraghi M, Ward M. Complications of endotracheal intubation. *South Med J* 1988;81:739–44.
4. Kurihara N, Imai K, Minamiya Y, Saito H, Takashima S, Kudo S, et al. Hoarseness caused by arytenoid dislocation after surgery for lung cancer. *Gen Thorac Cardiovasc Surg* 2014;62:730–3.
5. Namrata N, Priya R, Jigeeshu D. Bronchial blocker for one-lung ventilation: an anticipated complication. *Indian J Anaesth* 2011;55:636–7.
6. Berg H, Roed J, Viby-Mogensen J, Mortensen CR, Engbaek J, Skovgaard LT, et al. Residual neuromuscular block is a risk factor for postoperative pulmonary complications. A prospective, randomised, and blinded study of postoperative pulmonary complications after atracurium, vecuronium and pancuronium. *Acta Anaesthesiol Scand* 1997;41:1095–103.

7. Cheng YJ. Role, benefits and limitations of non-intubated anesthesia in thoracic surgery. *Video-Assisted Thorac Surg* 2017;2:57.
8. Tacconi F, Pompeo E, Mineo TC. Duration of air leak is reduced after awake nonresectional lung volume reduction surgery. *Eur J Cardio-Thoracic Surg* 2009;35:822–8.
9. Patel A, Nouraei SA. Transnasal humidified rapid-insufflation ventilatory exchange (THRIVE): a physiological method of increasing apnoea time in patients with difficult airways. *Anaesthesia* 2015;70:323–9.
10. Nishimura M. High-flow nasal cannula oxygen therapy in adults: physiological benefits, indication, clinical benefits, and adverse effects. *Respir Care* 2016;61:529–41.
11. Groves N, Tobin A. High flow nasal oxygen generates positive airway pressure in adult volunteers. *Aust Crit Care* 2007;20:126–31.
12. Parke RL, McGuinness SP. Pressures delivered by nasal high flow oxygen during all phases of the respiratory cycle. *Respir Care* 2013;58:1621–4.
13. Möller W, Celik G, Feng S, Bartenstein P, Meyer G, Oliver E, et al. Nasal high flow clears anatomical dead space in upper airway models. *J Appl Physiol (1985)* 2015;118:1525–32.
14. Booth AWG, Vidhani K, Lee PK, Thomsett CM. Spontaneous Respiration using IntraVenous anaesthesia and Hi-flow nasal oxygen (STRIVE Hi) maintains oxygenation and airway patency during management of the obstructed airway: an observational study. *Br J Anaesth* 2017;118:444–51.
15. Wang ML, Hung MH, Chen JS, Hsu HH, Cheng YJ. Nasal high-flow oxygen therapy improves arterial oxygenation during one-lung ventilation in non-intubated thoracoscopic surgery. *Eur J Cardiothorac Surg* 2018;53:1001–6.
16. Chen JS, Cheng YJ, Hung MH, Tseng YD, Chen KC, Lee YC. Nonintubated thoracoscopic lobectomy for lung cancer. *Ann Surg* 2011;254:1038–43.
17. Hung MH, Hsu HH, Chen KC, Chan KC, Cheng YJ, Chen JS. Nonintubated thoracoscopic anatomical segmentectomy for lung tumors. *Ann Thorac Surg* 2013;96:1209–15.
18. Pompeo E. Nonintubated video-assisted thoracic surgery under epidural anesthesia – encouraging early results encourage randomized trials. *Chin J Cancer Res* 2014;26:364–7.
19. Timea J, Phillip A, James T. The Thopaz digital chest drain system: an initial experience. *Heart Lung Circ* 2016;25:e101.
20. Sridhar R, Amy B, Teresa C, Pala BR. Thopaz portable suction systems in thoracic surgery: an end user assessment and feedback in a tertiary unit. *J Cardiothorac Surg* 2011;6:59.
21. George RS, Papagiannopoulos K. Advances in chest drain management in thoracic disease. *J Thorac Dis* 2016;8(Suppl 1):S55–64.
22. Arai H, Tajiri M, Kameda Y, Shiino K, Ando K, Okudela K, et al. Evaluation of a digital drainage system (Thopaz) in over 250 cases at a single site: a retrospective case-control study. *Clin Respir J* 2018;12:1454–9.