

A Benign, Mature, Parapharyngeal Teratoma Presenting in an Adult

Gregory E. Punch, Joseph C. Sniezek, Bryan D. Berkey, and Gregory W. Petermann

We present a case of an adult female who presented mildly symptomatic and with a history of having a mass removed from her neck as an infant. Radiographic imaging detected the presence of a heterogeneous, encapsulated mass in the parapharyngeal space that was surgically resected, and subsequently pathologically confirmed to be a benign, mature cystic teratoma

Introduction

The number of teratomas that occur per live birth each year is about one per 4,000, and teratomas in the head and neck region comprise less than 10% of all teratomas in newborns. While there are several reports in the literature of adult parapharyngeal space teratomas, the vast majority of these are malignant in nature and no benign teratomas have been described to recur after surgical treatment. This is a case of an adult female who presented mildly symptomatic and with a history of having a mass removed from her neck as an infant. Radiographic imaging detected the

presence of a heterogeneous, encapsulated mass in the parapharyngeal space that was surgically resected, and subsequently pathologically confirmed to be a benign, mature cystic teratoma

Case Report

A 28-year-old Korean woman presented to the Ear, Nose and Throat clinic complaining of a chronic, progressive history of difficulty swallowing. She denied any other symptoms including shortness of breath, stridor, pain, neurosensory deficit, or headaches. The patient reported having a left neck mass removed as a “young baby” in Korea. No medical records were available. On physical exam the patient presented with a palpable left cervical mass. A coronal computed tomographic angiogram (CTA) demonstrated focal areas of low attenuation representing fat, along with several foci of calcification and soft tissue densities in a left parapharyngeal space mass highly suggestive of a teratoma (Fig. 1A). Axial CTA with contrast demonstrated a grossly heterogeneous mass with fluid, fat, calcification, and soft tissue densities in the left prestyloid parapharyngeal space. A mass effect on the oropharynx was noted as well as a posterolateral displacement of the left internal carotid artery, indicating the mass was arising from the prestyloid parapharyngeal space (Fig 1B). Coronal T1 weighted MR with contrast and fat saturation

Citation: Punch GE, Sniezek JC, Berkey BD, Peterman GW. A Benign, Mature, Parapharyngeal Teratoma Presenting in an Adult. Radiology Case Reports. [Online] 2007;2:46.

Copyright: © Gregory E. Punch. This is an open-access article distributed under the terms of the Creative Commons Attribution-NonCommercial-NoDerivs 2.5 License, which permits reproduction and distribution, provided the original work is properly cited. Commercial use and derivative works are not permitted.

Abbreviations: CT, computed tomography; CTA, computed tomographic angiogram; FRFSE, Fast Recovery Fast Spin Echo; MRI, magnetic resonance imaging

Gregory E. Punch (Email: author@email) is at the Uniformed Services University of the Health Sciences, Bethesda, MD, United States of America.

Joseph C. Sniezek is in the Department of Otolaryngology/Head and Neck Surgery, Tripler Army Medical Center, Honolulu, HI, United States of America.

Bryan D. Berkey and Gregory W. Petermann are in the Department of Radiology, Tripler Army Medical Center, Honolulu, HI, United States of America.

Published: October 24, 2007

DOI: 10.2484/rcr.v2i4.46

A Benign, Mature, Parapharyngeal Teratoma Presenting in an Adult

demonstrated a well-circumscribed, heterogeneous, multiloculated lesion within the left parapharyngeal space. The mass demonstrated areas of high and low intensity signals and was found to be independent of the deep lobe of the parotid gland. These findings were also consistent with a benign teratoma (Fig. 2A). A coronal T2 weighted Fast Recovery Fast Spin Echo (FRFSE) sequence also demonstrated a heterogeneous, multiloculated mass with lobules surrounded by a distinct fat plane (Fig. 2B).

An elective transcervical approach was used to resect the neck mass. A mandibulotomy was not needed to expose the mass lying deep to the stylohyoid muscle and posterior belly of the digastric. A 5 x 4 cm encapsulated mass was demonstrated and removed from the parapharyngeal space. Gross pathological analysis of the surgical specimen revealed a firm, lobulated, encapsulated mass. Sectioning revealed fibrous cut surface with multiple cyst-like structures containing pale tan, gelatinous contents and areas of calcification consistent with a multicystic mature teratoma (Fig. 3). Histologic analysis of the surgical specimen

demonstrated the presence of fat and bone of mesodermal origin and epithelium of ectodermal origin, thus confirming the presence of a benign, mature teratoma.

Discussion

The parapharyngeal space is a potential space located lateral to the upper pharynx and is shaped like an inverted pyramid. The parapharyngeal space extends from the temporal and sphenoid bones of the skull base superiorly to the hyoid bone inferiorly. The medial boundary is the upper pharyngeal constrictors, with the mandibular ramus as the lateral boundary. It is further limited posteriorly by the cervical vertebrae and anteriorly by the pterygomandibular raphe. The styloid fascia further divides the parapharyngeal space into an anterolateral (prestyloid) compartment, and a posteromedial (poststyloid) compartment. This anatomic distinction is significant as the contents of each compartment determine the possible histologic etiologies of lesions in the parapharyngeal space. Additionally, tumors arising

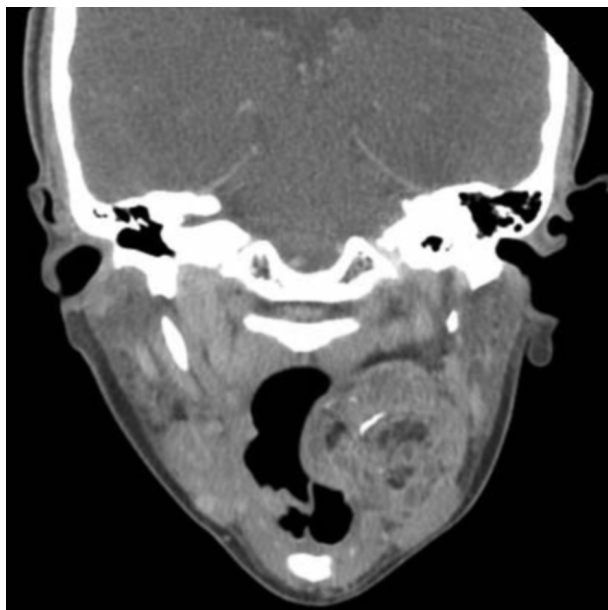


Figure 1A. 28-year-old woman with benign, mature, parapharyngeal teratoma. A reformatted coronal post-contrast CTA image demonstrates focal areas of low attenuation representing fat, along with several foci of calcification and soft tissue densities in a left parapharyngeal space mass highly suggestive of a teratoma. The lesion appears to be submucosal thus arising from the parapharyngeal space and not extending from the nasopharynx.

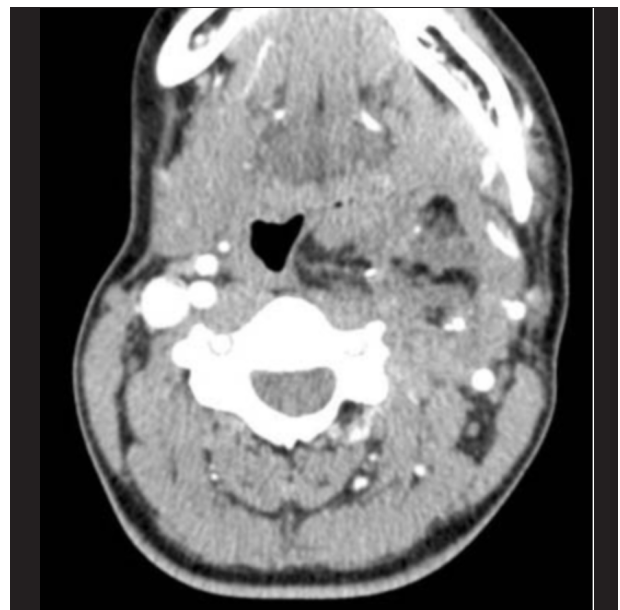


Figure 1B. Axial CTA with contrast demonstrates a grossly heterogeneous mass with fluid, fat, calcification, and soft tissue densities in the left prestyloid parapharyngeal space. Note the mass effect on the oropharynx, the compression of the internal jugular vein, and the posterolateral displacement of the internal carotid artery.

A Benign, Mature, Parapharyngeal Teratoma Presenting in an Adult

in each of the compartments have characteristic mass effects that also provide clues to their histologies, thus guiding the differential diagnosis.

Tumors of the parapharyngeal space are highly uncommon, comprising only 0.5% of head and neck tumors [1]. Common tumors of the parapharyngeal space are divided by their location and include major and minor salivary gland tumors, glomus tumors (paragangliomas), and neuromas [2]. Prestyloid tumors are commonly pleomorphic adenomas of the parotid gland [3]. Salivary gland lesions and other masses in the prestyloid space characteristically displace the internal carotid artery posterior [4]. Poststyloid tumors include three categories: glomus tumors which generally enhance, schwannomas which may have target like appearance and mixed enhancement, or lymph nodes. Schwannomas usually arise from the vagus nerve and the sympathetic chain [2]. Metastatic lesions and a vast assortment of uncommon and rare lesions may also present in this area [5]. Lesions in the poststyloid compartment characteristically displace the internal carotid anteriorly.

Teratomas are true neoplasms that may contain tissues

from all three germ layers and grow independently of the host. They are theorized to develop from misplaced embryonic, pluripotent germ cells that lose influence during embryologic development [6]. The number of teratomas that occur per live birth each year is about one per 4,000 [7]. Review of current medical literature demonstrates that teratomas of the head and neck are rather uncommon, comprising anywhere from 3-10% of all neonatal teratomas [8,9]. The majority of teratomas occur in pediatric populations, are more likely to be found within the pelvis, and are more typically benign in nature. Teratomas of the head and neck presenting in neonates usually cause respiratory distress [10]. Teratomas in adults are more commonly gonadal and malignant. Additionally presentation in the head and neck region is uncommon in adults. Fewer than 40 head and neck teratomas presenting in adults have been described in the medical literature.

Both the radiologic and pathologic diagnosis of a teratoma can be suspected when a complex, heterogeneous lesion contains evidence of fatty regions and calcifications [6]. One must also consider lipoma and liposarcoma with

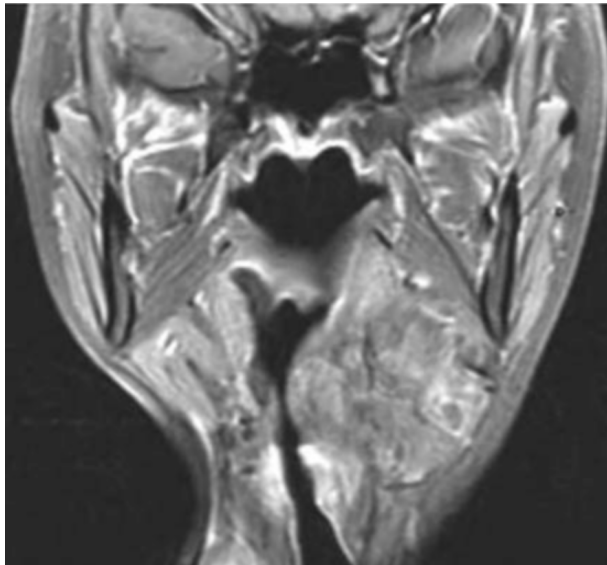


Figure 2A. Coronal T1 weighted MR with contrast and fat saturation demonstrates a well-circumscribed, heterogeneous, multiloculated lesion within the left parapharyngeal space. The mass demonstrates both areas of high and low intensity signals and is independent of the deep lobe of the parotid gland. These findings are consistent with a benign teratoma.

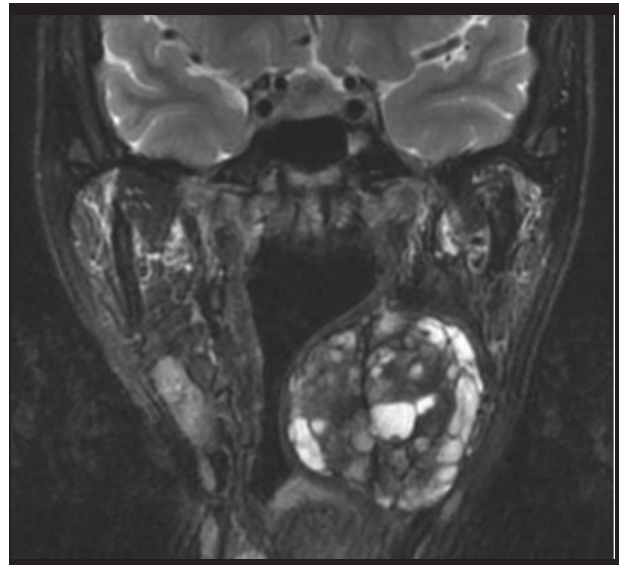


Figure 2B. A coronal T2 weighted FRFSE demonstrates a heterogeneous, multiloculated, mass with lobules in the parapharyngeal space. The mass is surrounded by a distinct fat plane and is indicative of a multicystic teratoma.

radiologic evidence of fat containing lesions. Computed Tomography of the head and neck is useful for detecting the presence of a parapharyngeal space mass and localizing it to the pre- or poststyloid compartments. Intravenous contrast is also frequently used with CT to help demonstrate the displacement of the carotid artery to aid in diagnosing the lesion. Teratomas typically present on CT with focal areas of low attenuation representing fat, foci of high attenuating calcifications, and diffuse heterogeneous areas with soft tissue densities.

MRI of the head and neck is found to be superior to CT as the imaging modality of choice for parapharyngeal space tumors. MRI has superior soft-tissue resolution and incomparable ability to delineate surgical approach for definitive treatment [11]. T1-weighted images are ideal for demonstrating normal anatomy and benign lesions with tumor-fat interfaces. T2-weighted images are selective for demonstrating tumor margins and outlining tumor interface with surrounding muscle tissue. On T1-weighted imaging, teratomas appear as heterogeneous, multiloculated lesions demonstrating both high and low intensity signals. In the parapharyngeal space, MRI is advantageous for demonstrating a high intensity fat plane between the mass and the deep lobe of the parotid as seen in benign, extra-parotid lesions. On T2-weighted images teratomas, also appear as heterogeneous, multilobed lesions with multiple signal intensities consistent with fat and calcifications.

Complete surgical resection is the treatment of choice for benign teratomas, and adjuvant chemotherapy is often used in malignant and metastatic cases. Recurrence is rare with complete resections. Respiratory compromise can be a major issue in infants. At 6-month follow up, our patient had no evidence of recurrence.

Benign teratomas, although rare in the parapharyngeal space, demonstrate classic imaging findings. On CT, a combination of fat, calcification, and soft tissue are present. On MRI, fat is demonstrated as increased T1 signal that is diminished with fat suppression. T2 demonstrates heterogeneous signal throughout the mass. Calcifications may be difficult to demonstrate on MRI however. Knowl-

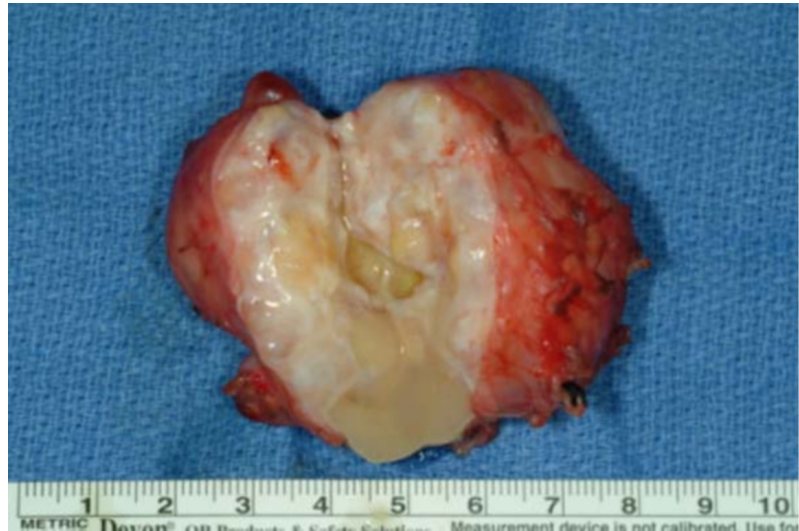

Figure 3. Gross pathologic specimen revealed 5 x 4 cm firm, lobulated, encapsulated mass. Sectioning revealed fibrous cut surface with multiple cyst-like structures containing pale tan, gelatinous contents and areas of calcification consistent with a multicystic mature teratoma.

edge and recognition of this entity is necessary to insure proper diagnosis and subsequent treatment.

References

1. Hughes KV 3rd, Olsen KD, McCaffrey TV. Parapharyngeal Space Neoplasms. *Head Neck*. 1995 Mar-Apr;17(2):124-30. [PubMed]
2. Som PM, Sacher M, Stollman AL, Biller HF, Lawson W. Common Tumors of the Parapharyngeal Space: Refined Imaging Diagnosis. *Radiology*. 1988 Oct;169(1):81-5. [PubMed]
3. Tom BM, Rao VM, Guglielmo F. Imaging of the Parapharyngeal Space: Anatomy and Physiology. *Crit Rev Diagn Imaging*. 1991;31(3-4):315-56. [PubMed]
4. Shin JH, Lee HK, Kim SY, Choi CG, Suh DC. Imaging of Parapharyngeal Space Lesions: Focus on the Prestyloid Compartment. *Am J Roentgenol*. 2001 Dec;177(6):1465-1470. [PubMed]
5. Allison RS, Waal VD, Snow GB. Parapharyngeal Space

A Benign, Mature, Parapharyngeal Teratoma Presenting in an Adult

Tumors: a Review of 23 Cases. Clin Otolaryngol Allied Sci. 1989 Jun;14(3):199-203. [PubMed]

6. Smirniotopoulos JG, Chiechi MV. Teratomas, dermoids, and epidermoids of the Head and Neck. Radiographics. 1995 Nov;15(6):1437-55. [PubMed]

7. Handler SD, Raney RBJ. Management of Neoplasms of the Head and Neck in Children-1. Benign Tumors. Head and Neck Surgery. 1981 May-June;3(5): 395-405. [PubMed]

8. Gullane PJ, Lampe HB, Slinger R. Erosive Parapharyngeal Space Teratoma. J Otolaryngol. 1986 Oct;15(5): 317-21. [PubMed]

9. Holt GR, Holt JE, Weaver RG. Dermoids and Teratomas of the Head and Neck. Ear Nose Throat J. 1979 Dec;58(12): 320-31. [PubMed]

10. Saing H, Lau WF, Chan YF, Chan FL. Parapharyngeal Teratoma in the Newborn. J Pediatr Surg. 1994 Dec;29(12): 1524-5. [PubMed]

11. Miller FR, Wanamaker JR, Lavertu P, Wood BG. Magnetic Resonance Imaging and the Management of Parapharyngeal Space Tumors. Head Neck. 1996 Jan-Feb;18(1):67-77. [PubMed]