

# Wound construction in manual small incision cataract surgery

S S Haldipurkar, Hasanain T Shikari, Vishwanath Gokhale

The basis of manual small incision cataract surgery is the tunnel construction for entry to the anterior chamber. The parameters important for the structural integrity of the tunnel are the self-sealing property of the tunnel, the location of the wound on the sclera with respect to the limbus, and the shape of the wound. Cataract surgery has gone beyond just being a means to get the lens out of the eye. Postoperative astigmatism plays an important role in the evaluation of final outcome of surgery. Astigmatic consideration, hence, forms an integral part of incisional considerations prior to surgery.

**Key words:** Astigmatism, scleral tunnel, self-sealing incision, small incision cataract surgery

*Indian J Ophthalmol*: 2009;57:9-13

In the evolution of cataract surgery, manual small incision cataract surgery (MSICS) was a later addition much after phacoemulsification became a popular technique. It is neither a hi-tech procedure, nor is it practiced in Western countries. For that matter, MSICS remains a foreign technique to a large section of the ophthalmic fraternity in the modern world. MSICS was developed mainly as a cost-effective alternative to phacoemulsification cataract surgery. The Western world graduated from extracapsular cataract extraction (ECCE) to phacoemulsification. In the developing countries where cost is a major issue, MSICS was developed after the advent of phacoemulsification, and hence it is a relatively younger technique than the latter. It is a safe, simple, consistent, stable, and cost-effective way of cataract removal. Small incision is a misnomer as small is always bigger than "smaller."

Wound construction plays a major role in MSICS, which may be more important than its role in phacoemulsification, where the size and shape and type of the wound remain same in most of the cases. In MSICS, everything about the wound has to be carefully planned depending on the type of technique, hardness of the nucleus, amount of astigmatism, and the condition of the endothelium.

Self-sealing cataract incisions were mentioned by Kratz *et al.*<sup>[1]</sup> in 1980 and by Girard in 1984.<sup>[2,3]</sup> Kratz thought of scleral tunnel as an astigmatic neutral way of entering the anterior chamber. In 1984, it was shown by Thrasher *et al.* that a 9.0-mm posterior incision induces less astigmatism than a 6.0-mm limbal incision.<sup>[4]</sup>

In 1990, Michael McFarland developed a sutureless incision,<sup>[5]</sup> and Pallin<sup>[6,7]</sup> described a Chevron shaped incision. During the same period, Singer<sup>[8]</sup> popularized the frown incision.

The aim of this article is to present a description and analysis of the techniques and parameters involved in wound construction in MSICS.

The properties of a reliable self-sealing incision are:

1. Square incisional geometry
2. Relatively short external incision with a tunnel that flares to a larger internal incision
3. Geometric external incision shape that lends itself to stretching.<sup>[9,10]</sup>

Square incisional geometry [Figs. 1 and 2], which means the length of the tunnel must be equal to or exceed the width of the tunnel, is a guideline and not a strict rule for surgical planning. In the real world, self-sealing incisions only strive to approach the square configuration.

The instrumentation required for MSICS tunnel construction consists of a conjunctival spring scissors, Castroviejo's calipers, angled tunnel blade/crescent blade, and angled 45 degree microkeratome. Diamond knives with round-type blade with 4-mm long sharp sides may also be used for external scleral incision and tunnel construction.

The scleral tunnel has six aspects: size (i.e., the length of the tunnel), shape (style), location, depth, width, and entry into the anterior chamber. The scleral groove external incision is initiated by the Bard-Parker knife with number 15 blade. The external configuration of the incision is usually curvilinear but may be oriented straight when a small incision is being made. The anterior limit of the incision is 2–3 mm behind the limbus, and the length of the incision (which is the distance between the two ends, but not along the curvature) varies from 5 to 6 mm for cortical cataract, and from 7 to 8 mm for nuclear sclerotic grade IV cataract. In case of a compromised corneal endothelium, larger incision size would be warranted to facilitate the easy delivery of the nucleus without too much manipulation in the anterior chamber. This should be coupled with adequate use of a dispersive viscoelastic substance. The primary deciding factor in the length of the incision is always the grade of cataract as well as size of nucleus and not the size of the intraocular lens (IOL) to be implanted.<sup>[11]</sup> For instance, if we expect the size of the nucleus to be bigger than the 6.0 mm optic size of the lens to be implanted, we would make a

Laxmi Eye Institute, Uran Road, Panvel, Navi Mumbai - 410 206, Maharashtra, India

Correspondence to Dr. S. S. Haldipurkar, Laxmi Eye Institute, Uran Road, Panvel, Navi Mumbai - 410 206, Maharashtra, India. E-mail: dr.haldipurkar@mtnl.net.in

Manuscript received: 11.07.08; Revision accepted: 29.09.08

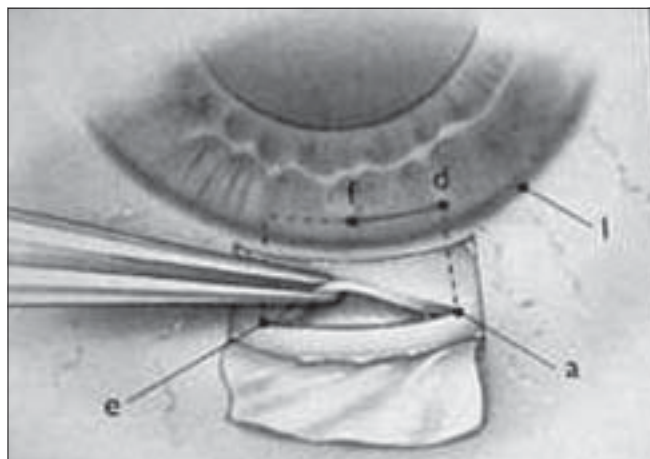
bigger incision to accommodate the nucleus of that size and not a small incision to accommodate the optic size. The incision has to, however, allow the optic diameter to pass through it easily without traumatizing the tunnel created.

The width of the tunnel is the distance between the external scleral incision and the internal corneal entry incision [Fig. 2], which should be at least 4 mm in size.<sup>[3]</sup> The external configuration may either be straight or curved. Paul Koch described the "Incisional Funnel" indicating the astigmatic neutral zone.<sup>[12]</sup> The frown incision is hence best suited for MSICS.<sup>[8]</sup> The tendency of wound-edge separation is also less for this configuration.<sup>[13]</sup>

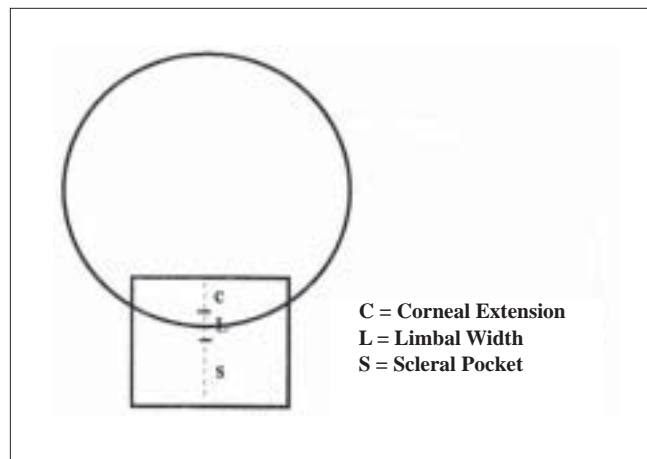
The scleral flap should neither be too thick nor be too thin. A thin flap has a tendency to tear or give way to superior button-hole formation.<sup>[13]</sup> To overcome this unfortunate complication, if the button-hole is on one side, then the other end is dissected further to confirm with the same incision. If the button-hole is

in the center, the original site is abandoned and another area is chosen or dissection is carried out at a deeper plane in the same area. A thick flap usually does not cause any problem unless the scleral spur or ciliary body is damaged. Optimal incision depth is usually one-half to two-thirds the thickness of the sclera or about 0.3 mm.<sup>[13]</sup>

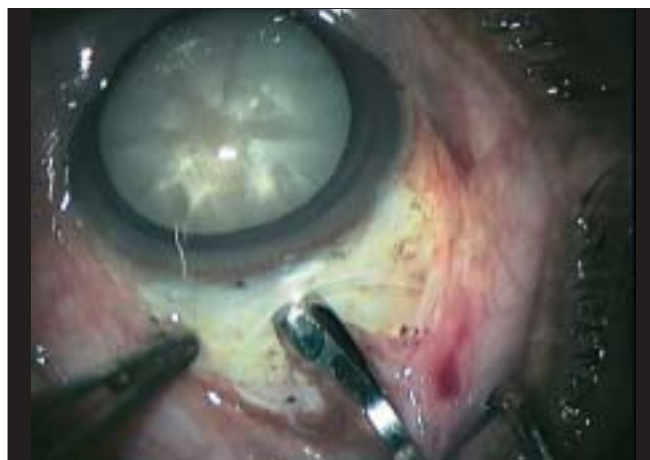The pocket tunnel is dissected with a diamond or metal crescent disposable knife at the bottom of the 0.3-mm deep external cut, and it is propagated anteriorly until it engages the limbal tissue. It should be remembered that the eyeball is a globe and the crescent has to orient in an upward and forward direction to remain parallel to the sclera. Cornea is steeper than the sclera, and therefore, tunnel dissection should be slightly anteriorly directed in the cornea after crossing the limbal area. The limbal tissue resists dissection more than the sclera or corneal tissue. To overcome this extra resistance, care must be taken not to engage extra forward cutting movement, as this might cause uncontrolled forward corneal dissection after



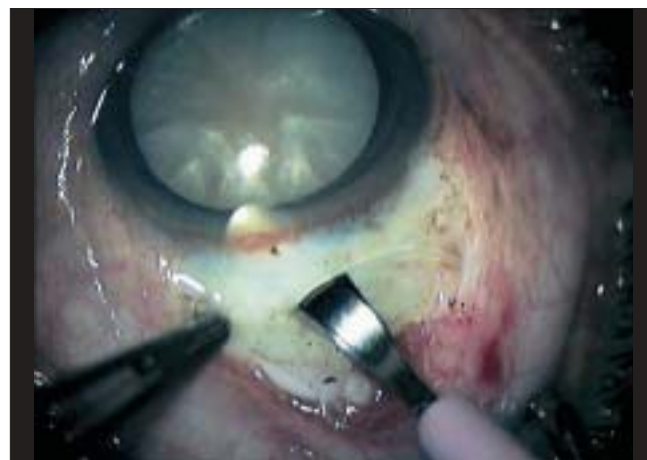**Figure 1:** a to e (length) and a to d (width) should be equal. This demonstrates a square incisional geometry that would ensure that the wound is self-sealing in nature



**Figure 2:** Dimensions of the scleral tunnel. The width of the tunnel is the distance between the internal corneal entry and the external scleral incision. In this diagram, the width of the tunnel is  $C+L+S$  (should be about 4 mm)



**Figure 3:** While dissecting the tunnel, it is imperative to get a proper grip on the eyeball. This is achieved by holding the conjunctival edge with a toothed forceps. The hand holding the forceps should not give a downward pressure on the eyeball but lift it gently. Never during the course of the surgery should the edge of the tunnel be ever held with the forceps as this may compromise its self-sealing capacity



**Figure 4:** To be able to judge the correct thickness of the superficial lip of the scleral tunnel, the visibility of the blade may be used. As in this case the blade is only just visible under the sclera. The flap is neither too thick nor too thin. In case of a thin flap, the blade would be clearly visible under the scleral lip

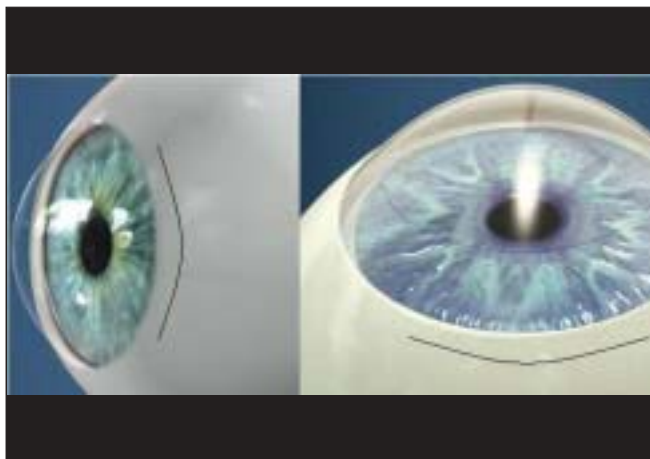
overcoming the sudden resistance during the dissection of the limbus and thus result in a premature entry into the anterior chamber or out of the cornea. As the dissection approaches the lateral end of the tunnel, the knife is tilted sideways while dissection is continued, creating a funnel-shaped tunnel of about 45 degrees. Thus, the internal aspect of the tunnel would be about 25% larger than the external incision. The crescent blade should be cutting while being brought out of the tissue. The pocket tunnel dissection is carried forward 1 mm into the clear cornea in front of the vascular arcade.

After the construction of the tunnel, the crescent is withdrawn, and the microkeratome is introduced into the tunnel in an oscillating movement right and left to avoid premature perforation into the anterior chamber, until the tip of the keratome reaches the end zone of the tunnel dissected. Then, the keratome is tilted downwards to enable perforation into the anterior chamber. After entering the anterior chamber, the keratome is moved laterally and forward causing the

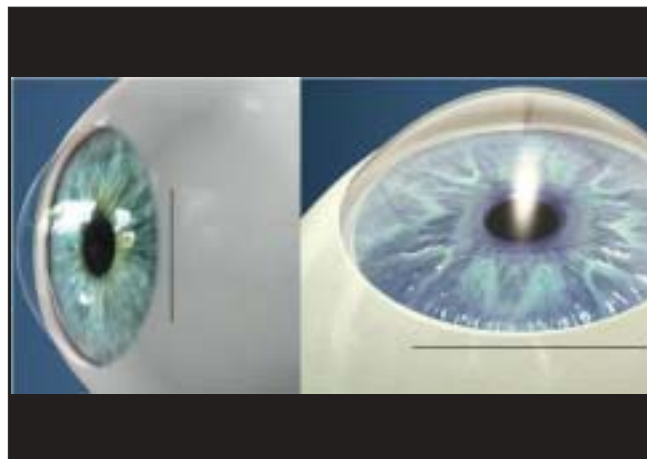
internal incision to direct itself in a curved fashion parallel to the limbus. The direction of movement of the keratome should be lateral and anterior and not lateral and posterior. By moving posteriorly, the internal opening will move towards the limbus, and valve action will be lost leading to leakage.

The salient features of the tunnel construction are listed as follows:

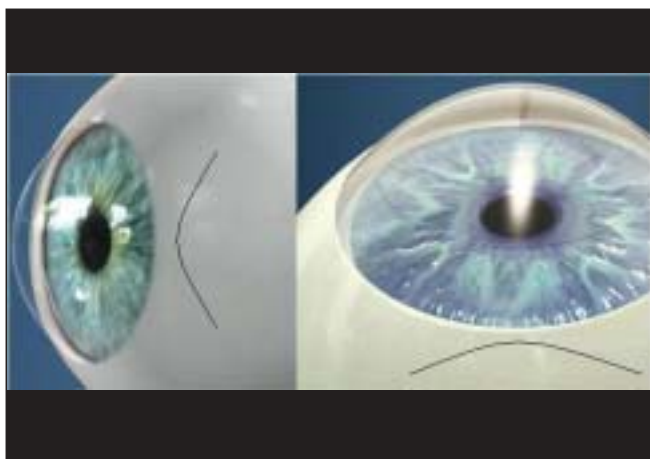
- Only a correct sclerocorneal tunnel incision, at least 1–2 mm into the clear cornea, leads to a self-sealing wound.
- Scleral cauterization before tunnel construction reduces the risk of pre- and postoperative hyphema.
- Sharp tunnel instruments (such as the crescent knife and keratome) should be used to construct the tunnel. A blunt keratome could cause stripping of Descemet's membrane.
- Stabilizing the sclera with toothed forceps makes tunnel construction easier [Fig. 3]. However, to avoid tunnel damage and leakage, the forceps should not be used on



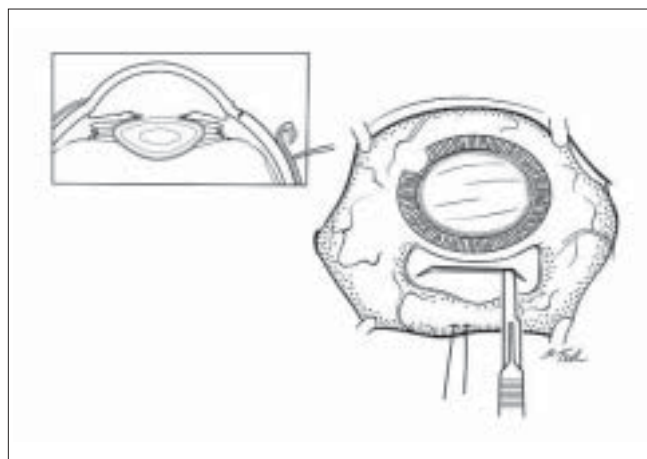
**Figure 5:** Smile incision is a curvilinear incision which runs parallel to the limbus. With this incision, there is an increased chance of corneal flattening after surgery in the vertical meridian with increased induced astigmatism



**Figure 6:** Straight incision, as the name suggests, is a straight line incision about 2 mm away from the limbus. This incision induces moderate flattening and consequently moderate astigmatism after surgery



**Figure 7:** Frown incision is difficult to make for a beginner. The 15-G blade that is used to make the initial groove has to be made with one smooth movement of the hand. The base of the curve is about 2 mm from the limbus. There is minimal induced astigmatism with this wound and is the preferred type for majority of the surgeons



**Figure 8:** Blumenthal side cuts devised by Dr. Michael Blumenthal. This incision has a straight line and two oblique cuts at its two ends. This increases the space in the tunnel for an easy delivery of the nucleus

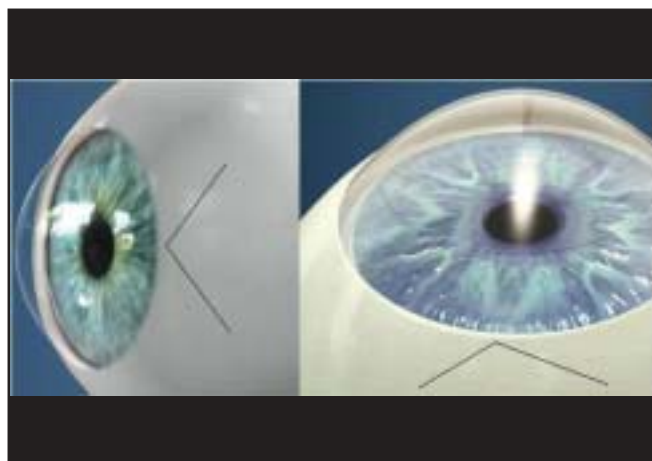


the tunnel flap.

- With a half-thickness sclerocorneal tunnel incision, the direction of the crescent knife should always be parallel to the sclerocorneal plane.
- Judge the depth of half-thickness sclerocorneal tunnel incisions by observing how clearly you can see the crescent knife during the incision [Fig. 4]. If the crescent knife can be seen very clearly, this indicates that the scleral layer is very thin and that the crescent knife might perforate to the outside (causing what is known as a button hole).
- A button hole can be corrected by making a deeper frown incision and dissecting the tunnel in a deeper plane, starting at the opposite side of the button hole.<sup>[14]</sup>
- If the crescent knife is not visible during the incision, this indicates that you are working too deeply inside the sclera; you may perforate towards the anterior chamber's angle (a "premature entry").
- A premature entry could lead to surgical complications, such as iris trauma or iridodialysis, iris prolapse, and a tunnel that is not self-sealing.
- Manage a premature entry by starting a more shallow dissection at the other end of the tunnel. Suturing of the wound is required at the end of surgery.<sup>[14]</sup>

In our opinion, even larger tunnels are self-sealing and do not need suturing if they are prepared correctly. If there is a doubt about the self-sealing effect, the surgeon may apply one or two sutures at the end of surgery. If correctly tied, these will, at the same time, reduce any induced astigmatism.

1. Smile: Easy to make, but results in increased astigmatism [Fig. 5].
2. Straight: Moderate induced astigmatism [Fig. 6].
3. Frown: Difficult to make with minimal induced astigmatism [Fig. 7].
4. Blumenthal side cuts: A straight incision with oblique cuts placed at its either ends. Minimal induced astigmatism, Large tunnel [Fig. 8].
5. Chevron 'v' incision: Difficult to make, difficult maneuverability with least/nil induced astigmatism<sup>[15]</sup> [Fig. 9].



**Figure 9:** Chevron 'v' incision. This incision is quite difficult to make. The tunnel size in this incision is relatively smaller. Hence, maneuvering a large nucleus through this would be difficult. However, this incision has least/nil induced astigmatism

All these incisions induce less astigmatism if placed more posteriorly on the sclera.<sup>[15]</sup>

Apart from being a procedure that restores vision loss due to the lenticular opacity, it is changing into a procedure that aims for postoperative emmetropia. The cataract incision itself may be looked upon as a refractive procedure capable of permanently reducing the astigmatic component of the preoperative refractive error maintaining sphericity in patients without preoperative astigmatism.<sup>[13]</sup>

As the cataract wound heals, the meridian along which the wound is centered tends to progressively flatten.<sup>[13]</sup> This would usually occur till the healing of the tissues is completed and usually would continue for up to 3 weeks after surgery.

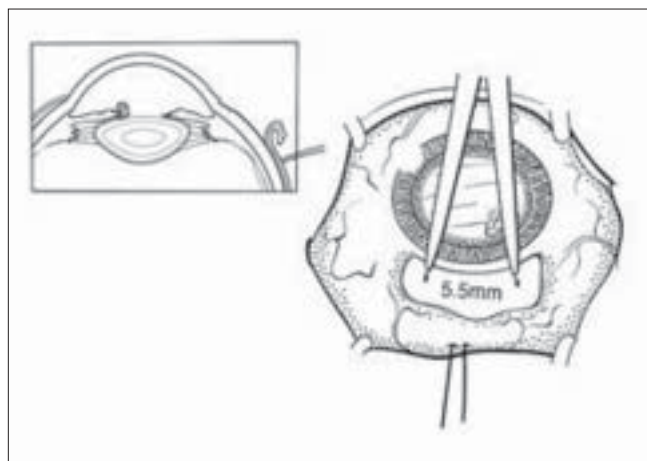
The size and architecture of the incision are important determination of the final against-the-rule shift. Burgansky *et al.* have shown an increase in astigmatism with an increase in the incision size.<sup>[16]</sup> A 3-mm incision is too small to alter the corneal shape appreciably. Such an incision maintains the preoperative cylinder profile. Large incisions cause more cylinder regression.<sup>[13]</sup>

Features of incision architecture that affect regression are location, depth and length, type, density and tension of suture material, depth and length of suture bites, and postoperative steroid dosage.

More the distance from the limbus (on sclera), less is the induced astigmatism although tunnel making and maneuverability are difficult. The ideal distance is around 1–2 mm.<sup>[15]</sup>

This is a most commonly done, easier to construct procedure better for the correction of mild to moderate with-the-rule astigmatism.<sup>[13]</sup>

Kimura *et al.* have shown that surgically induced astigmatism is less with an oblique incision than with a superior incision.<sup>[17]</sup> Arrangement of fibers in the sclera makes this a tight and least astigmatic tunnel.



**Figure 10:** A 5-mm track for scleral wound is measured 1 mm behind the limbus with surgical calipers. In case of the frown or the Chevron incision, the 5.5 mm width should be the distance between the two points of the curve or the inverted V

## Temporal

The temporal location is farthest from the visual axis, and any flattening due to wound is less likely to affect the corneal curvature at the visual axis. When incision is located superiorly, both gravity and eyelid blink tend to create a drag on the incision. These forces are better neutralized with temporal incision because it is parallel to the vector of the forces. With-the-rule astigmatism induced by a temporal incision is advantageous because most elderly patients have preoperative against-the-rule astigmatism.<sup>[18]</sup> Superior temporal incision also is free from effect of gravity and eye lid pressure and tends to induce less astigmatism.<sup>[18]</sup> In a series of 64 cases where we constructed a 5.5-mm superotemporal tunnel in MSICS, the calculated surgically induced astigmatism (SIA) was 0.8 diopter (D) whereas our superior scleral incision always gave us an SIA of 1.2 D when the tunnel length was more than 5.5 mm (unpublished data). In this study, the cases were selected consecutively with a cataract grading of II or III on Lens Opacities Classification System (LOCS), and procedures were performed by the same surgeon under peribulbar block using the same size and type of incision (frown). Nucleus delivery was done by viscoexpression.

The tunnel length was in the range of 5–6 mm measured with calipers. The inner end of the tunnel may be longer (7–7.5 mm), making it like a funnel to accommodate the nucleus. The length can be reduced further using either bisecting/trisecting the nucleus or mininucleus technique by hydrodelineation [Fig. 10].

Hence, with regard to incision, broad guidelines that help the cataract surgeon achieve emmetropia are as follows:

- To center incision along the steep meridian
- Longer incisions produce more flattening
- Posterior incisions decrease against-the-rule wound drift<sup>[13]</sup>
- Straight or frown incisions decrease against-the-rule drift<sup>[13]</sup>
- Scleral tunnel incisions minimize suture-induced astigmatism and provide greater wound-healing surface. Hence, it is more stable from the refractive standpoint.

## References

1. Kratz RP, Colvard DM, Mazzocco TR, *et al.* Clinical evaluation of the terry surgical keratometer. *Am Intraocular Implant Soc J* 1980;6:249-51.
2. Girard LJ, Hofmann RF. Scleral tunnel to prevent induced astigmatism. In: Emery JM, Jacobson AC, editors. *Current concepts in cataract surgery: Proceedings of the eight biennial cataract surgical congress Norwalk*. Appleton-Century-Crofts; 1984. p. 101-2.
3. Girard LJ. Origin of the Scleral tunnel incision. *J Cataract Refract Surg* 1995;21:7.
4. Thrasher BH, Boerner CF: Control of astigmatism by wound placement. *J Am Intraocul Implant Soc* 1984;10:176-9
5. Surgeon Undertakes Phaco, Foldable IOL series sans sutures. *Ocular Surgery News* 1, 1990.
6. Pallin SL. Chevron incision for cataract surgery. *J Cataract Refract Surg* 1990;16:779-81.
7. Pallin SL. Chevron sutureless closure: A preliminary report. *J Cataract Refract Surg* 1991;17:706-9.
8. Singer JA. Frown incision for minimizing induced astigmatism after small incision cataract surgery with rigid optic intraocular lens implantation. *J Cataract Refract Surg* 1991;17:677-88.
9. Gautam AK, Nath R, Kumar D, Saxena S. Early re-establishment of blood aqueous barrier after Phacoemulsification. *Indian J Ophthalmol* 1998;46:173-4.
10. Pallin SL. Self-sealing incision. In: Agarwal S, Bonnett R, Agarwal A, editors. *Phacoemulsification*. London: Taylor and Francis; 2004. p. 199-204.
11. Mishra P. Incision in Non Phaco SICS. *Orissa State Oph J* 2002. p. 30-2.
12. Koch PS. *Mastering phacoemulsification: A simplified manual of strategies for the spring, crack and stop and chop technique*. 4th ed. Thorofare, NJ: Slack; 1994. p. 19.
13. Basti S, Vasavada AR, Thomas R, Padhmanabhan P. Extra capsular cataract extraction: Surgical techniques. *Indian J Ophthalmol* 1993;41:195-210.
14. Schroeder B. Sutureless cataract extraction: complications and management; learning curves. *COMMUNITY Eye Health J* 2003;16:58-60.
15. Haldipurkar SS, Gokhale VN. Astigmatic Considerations in SICS. *J International Soc Manual Small Incision Cataract Surgeons*. 2005 Nov 1;46-8.
16. Burgansky Z, Isakov I, Avizemer H, Bartov E. Minimal astigmatism after sutureless planned extracapsular cataract extraction. *J Cataract Refract Surg* 2002;28:499-503.
17. Kimura H, Kuroda S, Mizoguchi N, Terauchi H, Matsumura M, Nagata M. Extracapsular cataract extraction with a sutureless incision for dense cataracts. *J Cataract Refract Surg* 1999;25:1275-9.
18. Gokhale NS, Sawhney S. Reduction in astigmatism in manual small incision cataract surgery through change of incision site. *Indian J Ophthalmol* 2005;53:201-3.

**Source of Support:** Nil, **Conflict of Interest:** None declared.