

CASE REPORT

Severe neurologic impairment and respiratory failure after fall and hip fracture in an elderly woman

Carlo Rostagno^{1,2}  | Silvia Maiani² | Rosa Di Donato² | Giulia Bandini² | Enrico Grassi³ | Enrico Fainardi⁴

¹Dipartimento Medicina Sperimentale e Clinica, Università di Firenze, Firenze, Italy

²SOD Medicina Interna e post-chirurgica AOU Careggi, Firenze, Italy

³UO Neurologia Ospedale di Prato, Prato, Italy

⁴SOD Neuroradiologia AOU Careggi, Firenze, Italy

Correspondence

Carlo Rostagno, Dipartimento Medicina Sperimentale e Clinica, Università di Firenze, Viale Morgagni 85, 50134—Florence, Italy.
Email: carlo.rostagno@unifi.it

Abstract

Fat embolism syndrome is a rare complication of long bone fractures and orthopedic surgery. We report a case of a 90-year-old woman who developed severe neurologic impairment and respiratory failure few hours after an accidental fall complicated by fracture of the left femur neck and left humerus.

KEYWORDS

elderly, fat embolism, hip fracture, neurologic impairment

1 | INTRODUCTION

Fat embolism syndrome (FES) is a condition associated with trauma, long bone fractures, and orthopedic surgical procedures. The main clinical findings are petechial rash, neurological symptoms, and respiratory impairment. Incidence is unclear since in predisposing clinical conditions fat particles have been demonstrated in the bloodstream by transesophageal echocardiography in 67–95% of patients; nevertheless, clinical manifestations are uncommon.^{1,2}

The first case of pulmonary fat embolism was described in 1862 by Zenker at the necroscopic examination of a patient who died from complications of severe trauma.³ Three years later, Wagner investigated the pathogenetic correlation between fractures and fat embolism, demonstrating the presence of fat particles in 48 patients with bone fractures.⁴ At present, there is still no gold standard for diagnosis of FES and often it is an exclusion

diagnosis, related mainly to clinic manifestations. We present a case report of an elderly woman with long bone fractures complicated by respiratory failure and altered mental status.

2 | CASE PRESENTATION

A 90-year-old woman with a history of Parkinson's and coronary heart disease was admitted to our hospital after a domestic accidental fall, complicated by left proximal femur and humerus fractures. Two hours after the fall, she showed a rapid clinical impairment with altered mental status with palilalia and confusion. Glasgow Coma Scale score (GCS) was 10 (E3-V3-M4). At hospital admission, arterial pressure was 190/90 mmHg, heart rate 100 bpm, and respiratory rate 32 bpm. The arterial blood analysis showed hypoxemia (partial pressure of oxygen of 53 mmHg) and respiratory alkalosis. Laboratory

examinations were normal, except for neutrophilic leukocytosis ($25,000/\text{mm}^3$). She underwent a brain computed tomography (CT) that did not show acute lesions or skull fractures, a lung CT that documented ground glass areas and interlobular septal thickening, and finally a CT pulmonary angiography that confirmed the bilateral lung exudative injury and the pleural effusion without clear perfusion defects.

The patient was transferred to our department. At arrival, she was having tachypnea with oxygen therapy by nasal prongs. Blood pressure was 130/80 mmHg, heart rate 85/min. Neurological conditions showed a further impairment (GCS 7, E3-V1-M3). A second brain CT was inconclusive. Electroencephalography showed left frontal-temporal slow and steep front waves. Cardiac examination confirmed a pre-existing left bundle branch block, while echocardiography showed normal left ventricular ejection fraction without pulmonary hypertension. Left atrium had a normal diameter, and we did not find signs of intracavitary thrombosis or atrial septal defects. Carotid vertebral Doppler examination did not find abnormalities of hemodynamic significance. Empiric antibiotic therapy, artificial enteral nutrition via NG tube, and oxygen support via Venturi mask were started.

Two days later, in absence of improvement of cognitive status, she developed sudden right hemiplegia. Brain magnetic resonance imaging (MRI) was performed with the evidence of diffuse bilateral cerebral and cerebellar abnormalities suggestive of severe multiple embolization.

Based on the clinical findings and brain MRI, the patient was diagnosed with FES (Figure 1). The treatment has been mainly supportive. Sixteen days after trauma, after gradual improvement in consciousness and respiratory function, the left femur fracture was treated surgically. A

cephalic prosthesis was implanted without complications, and two days later, she began physiotherapy sessions.

Both respiratory symptoms and CT lung imaging improved considerably within the next week, and oxygenation was reduced to low flow nasal prongs. Meanwhile, she showed a significant improvement in neurological conditions (GCS = 15) with residual partial disorientation in time and place, mild right hemiparesis, and fluid dysphagia, worsened by her Parkinson's disease.

At discharge, 40 days after trauma, the patient was in spontaneous breathing, with a residual right lower limb paresis and diffuse rigidity; thanks to physiotherapy, she reached the sitting position. Finally, she was transferred to a rehabilitation center.

3 | DISCUSSION

We presented the case of an old patient with hip and humerus fractures who developed FES with cerebral sequelae. FES is a complex syndrome characterized mainly by neurological and respiratory symptoms. Over the years, three pathogenetic theories were described: the mechanical theory proposed by Gauss in 1924, the biochemical theory proposed by Lehman in 1927, and the coagulation one by Gurd and Wilson in 1947.⁴

The first theory states that, during trauma or surgical procedure, there is increased pressure in the intramedullary space that pushes out the yellow fat in the venous circulation system, through the damaged vessels, and form thrombotic fat particles.⁵ The biochemical one describes the inflammatory reaction, evoked by degradation of fatty emboli into free fatty acids, against pneumocytes and capillaries. The coagulation theory is based on platelet aggregation and coagulation cascade activation. According

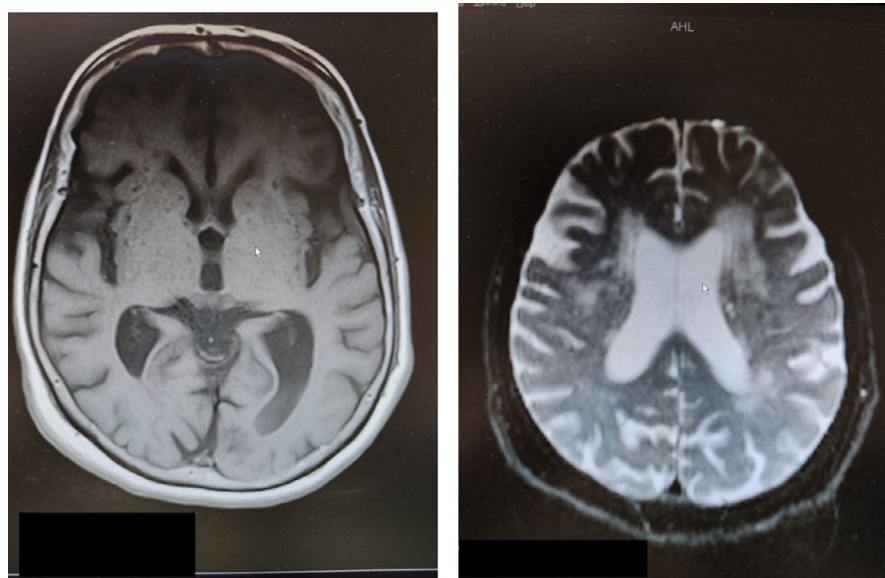


FIGURE 1 MRI showing multiple ischemic bilateral lesions due to fat embolism

to Gurd and Wilson, thromboplastin and marrow issued after trauma and fractures trigger complement system and extrinsic pathway of the blood coagulation cascade with the production of clots, and in addition, the activated platelets adhere to the circulating fatty emboli that derive from marrow expelled, leading to thromboembolic events.

They proposed the criteria that are now considered the gold standard and are used routinely to diagnose FES. The diagnosis of FES requires the presence of 1 major criterion and 4 minor criteria (Table 1).⁴⁻⁶

Schonfeld criteria better classified cutaneous symptoms (Table 2),⁸ and Lindeque underlined the importance of respiratory manifestations (Table 3).⁹

This syndrome more commonly occurs within 12 to 72 hours after traumatic fractures of long bones.⁵ It has been rarely reported in elderly patients suffering from a hip fracture. Our case highlights the multifactorial nature of FES given the early-onset manifestation of the syndrome. The underlying mechanism of FES is likely a combination of the mechanical, biochemical, and coagulation theories.

Early clinical descriptions of the fat embolism syndrome included the major criteria of respiratory insufficiency, cerebral involvement, and petechial rash. However, the analysis of FES cases shows that 34% of patients had neurologic impairment as the earliest clinical sign or symptom, as it was in this patient; 75% of them had respiratory manifestations. A petechial rash was a sign at presentation in only 17% of patients.¹⁰

There is no specific therapy for fat embolism syndrome: Prevention, early diagnosis, and adequate symptomatic treatment are of paramount importance.

Albumin has been recommended for volume resuscitation. The role of albumin is based on its physiological function as a plasma protein transporter of fatty acids (FA).

Fatty acids are a source of energy for cells, a part is stored in the adipose tissue, and a part is located in the vascular and interstitial compartments.¹¹ Due to their low solubility in aqueous solutions, FA need a carrier; they are known for their proinflammatory activity against pneumocytes and capillaries when they are free. The first study about albumin as a carrier of fatty acids was made by Forrest in 1941.¹²

Currently, the use of corticosteroids is not recommended for prophylaxis or treatment. Although many studies have shown beneficial effects of prophylactic steroid use because of their anti-inflammatory effects, there were no significant changes in mortality.⁸

4 | FES AND COVID

The FES hypothesis was also recently proposed to justify the more severe clinical manifestations by SARS-CoV-2,

TABLE 1 Gurd's criteria

Gurd's criteria
Major signs
Hypoxia
Mental state changes
Petechiae
Minor signs
Tachycardia
Thrombocytopenia
Unexplained anemia
Hyperpyrexia
Fat globules in fundus
Fat globules in urine
1 major criterion and 4 minor criteria for FES

TABLE 2 Schonfeld scale clinical sign

Schonfeld scale clinical sign
Petechiae 5
Chest X-ray changes (diffuse alveolar infiltrates) 5
Hypoxemia 3
Tachycardia (>120 b/min) 1
Tachypnea (>30 min acts) 1
Score >5 for FES.

TABLE 3 Lindeque's criteria

Lindeque's criteria
Sustained PaO ₂ < 8 kPa
Sustained PaCO ₂ > 7.3 KPa or pH < 7.3
Sustained respiratory rate >35/min despite sedation
Increase work of breathing, dyspnea, accessory muscle use, tachycardia, and anxiety

which obese people were compared to their normal-weight peers.

The pathogenic mechanism would consist in the increased expression of inflammatory mediators in the adipose tissue of overweight people¹³ and viral infiltration of adipocyte, mediated by the cellular expression of the ACE² receptor,¹⁴ the target of the virus spike protein, followed by the cellular necrosis (as it happens for other cell types), and the release of FA in the interstitial compartment.¹⁵

In addition to the ground glass areas at the lung CT, erythematous rash (Recalcati, 2020) and neurological manifestations¹⁶ were demonstrated during SARS-CoV-2 infection in common with FES. Finally, fat embolism

was found in autoptic lung specimens from two adult COVID-19 patients who were overweight.¹⁷

5 | CONCLUSIONS

These complex multi-organ manifestations could be the result of inflammatory reactions related to the presence of free fatty acids in the bloodstream and the activation of coagulation cascade by vascular damage. Mortality is estimated to be from 5 to 15%. The diagnosis is of exclusion, depending mainly on clinic manifestations, and there is no specific therapy, so early diagnosis and prevention are of paramount importance.

AUTHOR CONTRIBUTIONS

CR contributed to the evaluation and management of the patient, collected information, and was the writer of the manuscript. SM contributed to the evaluation and management of the patient and reviewed the manuscript. RD contributed to the evaluation and management of the patient and reviewed the manuscript. GB contributed to the evaluation and management of the patient. EG contributed to the evaluation of the patients and reviewed the manuscript. EF performed radiological examinations and reviewed the manuscript.

ETHICAL APPROVAL

We hereby confirm that this study conforms to the ethical standards and guidelines of the journal.

DATA AVAILABILITY STATEMENT

Data are available from the electronic clinical record of the patients. No funding was received. Informed consent statement that clinical data might be used for scientific purpose in anonymous form was signed by the legal representant of the patient (she was not able to sign at hospitalization).

ORCID

Carlo Rostagno  <https://orcid.org/0000-0002-7764-8919>

REFERENCES

1. Talbot M, Schemitsch EH. Fat embolism syndrome: history, definition and epidemiology. *Injury*. 2006;37:53-57.
2. Pell AC, Christie J, Keating JF, et al. The detection of fat embolism by transoesophageal echocardiography during reamed intramedullary nailing. A study of 24 patients with femoral and tibial fractures. *J Bone Joint Surg Br*. 1993;75:921-925.
3. Zenker FA. *Beiträge zur normalen und pathologischen Anatomie der Lunge*. J Braunsdorf; 1861.
4. Huffman JS, Humston C, Tobias J. Fat embolism syndrome revisited: a case report and review with new recommendations for the anesthetized patients. *AANA Journal*. 2020;88:222-228.
5. Akoh CC, Schick C, Otero J, Karam M. Fat embolism syndrome after femur fracture fixation: a case report. *Iowa Orthop J*. 2014;34:55-62.
6. Gurd AR, Wilson RI. The fat embolism syndrome. *J Bone Joint Surg Br*. 1947;56-B(3):408-416.
7. Gurd AR, Wilson RI. Fat embolism: an aid to diagnosis. *J Bone Joint Surg Br*. 1970;56:732-737.
8. Schonfeld SA, Ploysongsang Y, DiLisio R. Fat embolism prophylaxis with corticosteroid: a prospective study in high risk patient. *Ann Int Med*. 1983;483-443.
9. Lindeque BG, Schoeman HS, Dommissen GF, et al. Fat embolism syndrome: a double blind therapeutic study. *J Bone Joint Surg Br*. 1987;69:128-131.
10. Chiappa V, Gonzalez RG, Manian FA, et al. Case records of the Massachusetts General Hospital. Case 23-2016. *N Engl J Med*. 2016;375(4):370-378.
11. van der Vusse GJ. Albumin as fatty acid transporter. *Drug Metab Pharmacokinet*. 2009;24:300-307.
12. Kendall FE. Studies on human serum proteins II. Crystallization of human serum albumin. *J Biol Chem*. 1941;138:97-109.
13. Gregor MF, Hotamisligil GS. Inflammatory mechanisms in obesity. *Annu Rev Immunol*. 2011;29(1):415-445.
14. Gupte M, Boustany-Kari CM, Bharadwaj K, et al. ACE2 is expressed in mouse adipocytes and regulated by a high-fat diet. *Am J Physiol Regul Integr Comp Physiol*. 2008;295(3):R781-R788.
15. Tan YJ, Lim SG, Hong W. Regulation of cell death during infection by the severe acute respiratory syndrome coronavirus and other coronaviruses. *Cell Microbiol*. 2007;9(11):2552-2561.
16. Mao L, Jin H, Wang M, et al. Neurologic manifestations of hospitalized patients with coronavirus disease 2019 in Wuhan. *JAMA Neurol*. 2020;77(6):683-690.
17. Cinti S, Graciotti L. COVID-19 and fat embolism: a hypothesis to explain the severe clinical outcome in people with obesity. *Springer Nature Limited*. 2020;44:1800-1802.

How to cite this article: Rostagno C, Maiani S, Di Donato R, Bandini G, Grassi E, Fainardi E. Severe neurologic impairment and respiratory failure after fall and hip fracture in an elderly woman. *Clin Case Rep*. 2021;9:e05145. doi:[10.1002/ccr3.5145](https://doi.org/10.1002/ccr3.5145)