

ORIGINAL PAPER

doi: 10.5455/medarch.2021.75.297-301

MED ARCH. 2021 AUG; 75(4): 297-301

RECEIVED: JUL 29, 2021

ACCEPTED: AUG 19, 2021

¹Department of Colon and Rectal Surgery, 108 Military Central Hospital, Hanoi, Vietnam

²Department of Radiology, Pham Ngoc Thach University of Medicine, Ho Chi Minh City, Vietnam

Corresponding author: Nguyen Minh Duc, MD. Department of Radiology, Pham Ngoc Thach University of Medicine, Ho Chi Minh City, Vietnam. E-mail: bsnguyenminhduc@pnt.edu.vn. ORCID ID: <https://www.orcid.org/0000-0001-5411-1492>.

Laparoscopic Lateral Pelvic Lymph Node Dissection for Advanced Lower Rectal Cancer: a Preliminary Vietnamese Study

Trieu Trieu Duong¹, Ho Huu An¹, Le-Van Quoc¹, Vu Ngoc Son¹, Nguyen Minh Duc^{2,*}

ABSTRACT

Background: Lateral pelvic lymph node dissection (LPLD) in rectal cancer has been carried out in several major centers. However, there are still many controversial issues regarding this method such as feasibility, safety, and oncological outcome. **Objective:** The aim of this study was to evaluate the short-term outcomes, safety, and feasibility of LPLD. **Methods:** This was a retrospective study. A total of 117 patients with lower rectal cancer (clinical stage II/III) below the peritoneal reflection underwent surgery between January 2019 and November 2020 at 108 Military Central Hospital, Hanoi, Vietnam. **Results:** Total amount of 25 patients underwent laparoscopic total mesorectal excision (TME) plus LPLD and 92 patients underwent laparoscopic TME without LPLD. The rate of lateral pelvic lymph node metastasis in the LPLD group was 16% (4/25), of which 12% (3/25) were on the left side and 4% (1/25) were on the right side. The rate of intraoperative complications in the LPLD group was significantly higher at 16.0% (4/25) compared with 3.3% (3/92) in the TME only group ($p = 0.037$). There were no statistically significant differences in the rate of postoperative complications between the two groups (24.0% of patients in the LPLD group compared with 26.1% patients in the no LPLD group, $p = 0.832$). **Conclusion:** Pelvic lymphadenectomy has an important role in the treatment of advanced lower rectal cancer. LPLD is a safe and feasible procedure. However, it is necessary to study a larger number of patients with a longer follow-up period to fully evaluate oncological outcomes.

Keywords: Lower rectal cancer, Laparoscopic lateral pelvic lymph node dissection, Outcome, Vietnam.

1. BACKGROUND

Colorectal cancer is the fourth most common cancer in men and the third most common in women worldwide, with approximately 436,000 cases and 212,000 deaths in 2008 (1). One challenging issue in the treatment of rectal cancer is that the rate of local recurrence is very high, with studies suggesting recurrence rates from 21–46%. (2-4). There are many innovative methods including chemotherapy, radiotherapy, chemoradiotherapy, and surgery to improve the outcome of rectal cancer treatment. In 1982, total mesorectal excision (TME) was introduced by Heald which was a breakthrough in rectal cancer surgery, reducing the local recurrence rate to about 10% (5-7).

Pre-operative adjuvant therapy also plays an important role in reducing the rate of local recurrence. However, according to recent studies, local recurrence caused by lateral pelvic lymph node metastasis is of concern, with rates ranging from 10.6% to 25.5% (8-11). Therefore, removal of the lateral pelvic lymph nodes may be a useful strategy to prevent local recurrence. Since the late 1970s, lateral pelvic lymph node dissection (LPLD) has widely been applied in Japan. In 1975, Koyama et al demonstrated that lateral pelvic lymphadenectomy could significantly reduce local recurrence (12).

In addition, other studies have also reported similar results (12, 13). In Vietnam, LPLD in rectal cancer surgery is still new. Our hospital was one of the first to begin performing this procedure in 2019.

2. OBJECTIVE

The aim of this study is to evaluate the short-term outcomes, safety, and feasibility of laparoscopic LPLD in the treatment of advanced lower rectal cancer.

© 2021 Trieu Trieu Duong, Ho Huu An, Le-Van Quoc, Vu Ngoc Son, Nguyen Minh Duc

This is an Open Access article distributed under the terms of the Creative Commons Attribution Non-Commercial License (<http://creativecommons.org/licenses/by-nc/4.0/>) which permits unrestricted non-commercial use, distribution, and reproduction in any medium, provided the original work is properly cited.

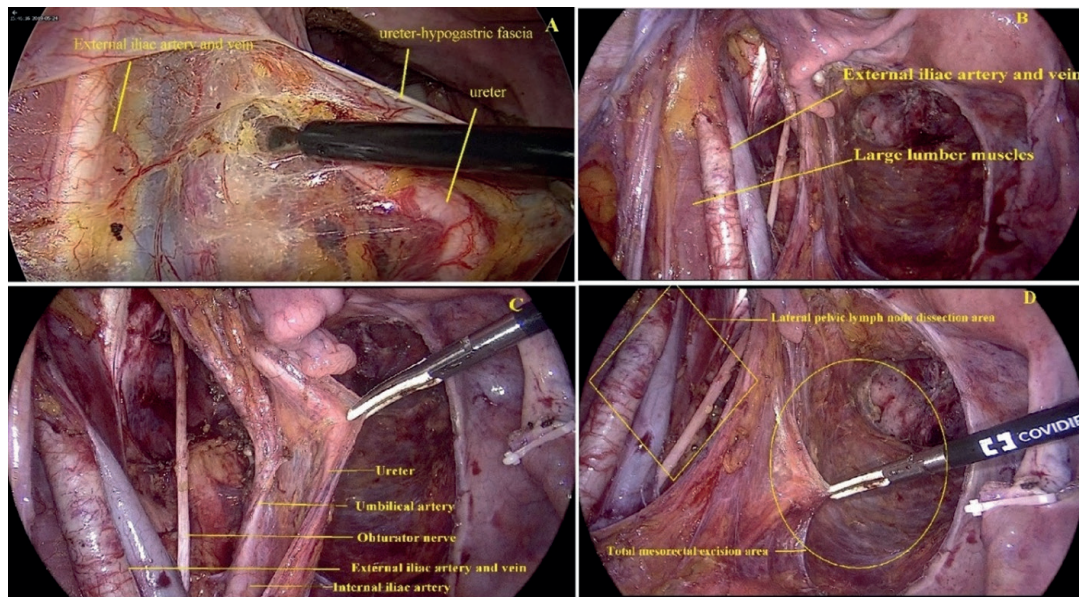


Figure 1. Images showing a 62-year-old woman with lower rectal adenocarcinoma. (A) Exposure of the ureter, (B) dissection of the exterior edge of the external iliac vessels, (C) the obturator hole after removal of the lateral pelvic lymph nodes, (D) the plane of TME and LPLD.

3. MATERIAL AND METHODS

Study design and participants

This is a retrospective study. A total of 117 patients with lower rectal cancer (clinical stage II/III) below the peritoneal reflection underwent surgery between January 2019 and November 2020 at 108 Military Central Hospital, Hanoi, Vietnam. This study was approved by the Scientific Committee in Biomedical Research, 108 Military Central Hospital (Ref: 4468/QĐ-BV108 dated 25 Sep 2020). All patients had rectal cancer diagnosed by endoscopy and biopsy, and underwent chest-abdominal computed tomography scans (Somatom Definition As 64, Siemens Healthineers, Germany) and pelvic magnetic resonance imaging (3.0 Tesla Philips Achieva MRI Scanner, Netherlands) to evaluate clinical staging. The TNM stages in our series were evaluated according to the criteria outlined in the American Joint Committee on Cancer (AJCC) seventh edition. In our hospital, preoperative chemoradiotherapy (CRT) was indicated for patients with cT3-4 and/or N (+) rectal cancer below the peritoneal reflection. In total, 102 patients (87.2%) were treated by long-course CRT based on oral Xeloda (capecitabine; F. Hoffmann-La Roche Ltd, Switzerland) 5 days/week for 5 weeks and a total radiation dose of 50.4 Gy. Patients receiving preoperative CRT underwent surgery 6–8 weeks after the completion of CRT. LPLD was indicated in patients with lateral pelvic lymph nodes either ≥ 7 mm in long-axis diameter before CRT or lateral pelvic lymph nodes ≥ 5 mm in long-axis diameter after CRT. LPLD was performed on the side of the suspected metastasis. The diameter of lymph nodes was measured by magnetic resonance imaging. The following data were collected from all patients: clinical characteristics (age, gender, body mass index, tumor location, tumor length, and clinical stage), surgical results (operative procedure, operative time, blood loss (calculated by the total amount of fluid drawn out compared with the total

amount of fluid used in surgery), intraoperative complications, postoperative complications), and pathological results (pathological stage, harvested lymph node dissection, lateral pelvic lymph node metastases).

Surgical procedure

We performed laparoscopic LPLD after TME (Figure 1). The LPLD was performed as follows:

a) Ureter dissection: the ureter was exposed and dissected along its length. The ureter and hypogastric nerve form a membrane-like structure called the ureter-hypogastric fascia. We dissected along this structure close to the bladder to reveal the lateral pelvic region to avoid pelvic autonomic nerve damage.

b) Dissection of the exterior edge of the external iliac vessels: we opened the peritoneum along the edge of the external iliac vessels close to the deep inguinal ring. Then we dissected along the edge of the large lumbar muscle and the internal obturator muscle to remove the fatty tissue outside the external iliac vessels.

c) Dissection outside of the umbilical artery: we dissected along the outside edge of the umbilical artery to create spaces and then proceeded to the section. We identified the obturator nerve which passes through the obturator fat tissue and can easily be damaged. The inferior vesical artery and the bladder are covered with vesicohypogastric fascia. We dissected along the vesicohypogastric fascia to separate the fatty tissue around the bladder and lateral pelvic space. We exposed the levator ani muscles, the anatomical landmark which indicates the lower limit of the section era. We removed all fat tissue from this region.

d) Dissection around the inferior vesical artery: we dissected the distal internal iliac artery and inferior vesical artery to remove fat tissue from this area.

Statistical analysis

Statistical analysis was performed using SPSS 23.0 (SPSS Inc, IBM, NY, USA). Quantitative data are pres-

ent as median (range). Differences between groups were evaluated using Chi-squared tests and Fisher's tests for categorical variables and Wilcoxon rank sum tests for continuous and ordinal variables. $p < 0.05$ was considered statistically significant.

4. RESULTS

A total of 117 patients with lower rectal cancer (clinical stage II/III) were included in the study, of which 25 underwent laparoscopic TME and LPLD and 92 underwent laparoscopic TME only. There were significant differences between the two groups in age (75.2 for the LPLD group versus 63.0 for the no LPLD group, $p = 0.016$) and tumor length (6.7 cm for LPLD versus 5.0 cm for no LPLD, $p = 0.025$). There were no significant differences in gender, surgical method, tumor location, clinical tumor stage, clinical lymph node stage, or treatment (Table 1).

The rate of intraoperative complications was significantly higher (16.0%, 4/25) in the LPLD group compared with the no LPLD group (3.3%, 3/92, $p = 0.037$). Intraoperative complications included two bladder injuries, one ureter injury, one obturator nerve injury, and one large vessel injury in the LPLD group, and one ureter injury and three large vessel injuries in the no LPLD group. There were no significant differences in the mean blood loss and the rate of conversion to open surgery between groups, whereas the mean operating time was longer in the LPLD group ($p < 0.001$) (Table 2).

There was no statistically significant difference in the rate of postoperative complications between the two groups (24.0% (6/25) in the LPLD group compared with 26.1% (24/92) in the no LPLD, $p = 0.832$, Table 3). Postoperative pathological findings, including pTN classification, tumor differentiation, and circumferential resection margin (CRM) status were similar between the two groups. The rate of lateral pelvic lymph node metastasis in the LPLD group was 16% (4/25), of which 12% (3/25) was on the left side and 4% (1/25) was on the right side. The mean harvested lymph node dissection was 13.5 ± 7.0 in the LPLD group, compared with 8.1 ± 3.5 in the no LPLD group (Table 4).

5. DISCUSSION

LPLD for advanced lower rectal cancer was first described five decades ago, but remains a topic of debate. Nowadays, in Japan, rectal cancer with lateral lymph node metastasis is considered a local progressive disease, and LPLD with pelvic autonomic nerve preservation has become the standard surgery for treatment of

	LPLD group (n=25)(%)	No LPLD group (n=92) (%)	P	
Mean age		57.2	63.0	0.016
Sex ratio (Male/ Female)		17/8	62/30	0.954
BMI (kg/m ²) (min- max)		21.5 (17.2- 32.4)	22.1 (16.4- 35.8)	0.204
Operative procedure, n (%)				0.106
	ISR	14 (56.0)	32 (34.8)	
	LAR	7 (28.0)	46 (50.0)	
	APR	4 (16.0)	14 (15.2)	
Tumor location, n (%)				0.174
	Middle third	10 (40.0)	53 (57.6)	
	Lower third	15 (60.0)	39 (42.4)	
Tumor length (cm)		6.7	5.0	0.025
Treatment, n (%)				0.520
	Preoperative CRT+ Surgery	23 (88.0)	79 (85.9)	
	Surgery alone	2 (8.0)	13 (14.1)	
Clinical tumor stage, n (%)				0.664
	cT2	1 (4.0)	7 (7.6)	
	cT3	15 (60.0)	59 (64.1)	
	cT4	9 (36.0)	26 (28.3)	
Clinical node stage, n (%)				0.176
	cN0	1 (4.0)	13 (14.1)	
	cN1	7 (28.0)	34 (37.0)	
	cN2	17 (68.0)	45 (48.9)	

Table 1. Clinical characteristics. BMI body mass index; ISR, intersphincteric resection; LAR, lower anterior resection; APR, abdominoperineal resection; LPLD, lateral pelvic lymph node dissection; CRT, chemoradiotherapy.

	LPLD group (n=25) (%)	No LPLD group (n=92) (%)	P
Intraoperative complications, n (%)	4 (16.0)	3 (3.3)	0.037
Large vessel injury, n (%)	1 (4.0)	3 (3.3)	
Adjacent structure injury, n (%)	4 (16.0)	1 (1.1)	0.007
Bladder, n (%)	2 (8.0)	0 (0.0)	
Ureter, n (%)	1 (4.0)	1 (1.1)	
Obturator nerve, n (%)	1 (4.0)	0 (0.0)	
Mean blood loss (ml) (min-max)	71.3 (30-200)	61.9 (10-200)	0.290
Mean operative time (minute) (min-max)	181.6 (150-270)	127.0 (60-240)	<0.001
Conversion to open surgery, n (%)	1 (4.0)	2 (2.2)	0.521

Table 2. Intraoperative complications

rectal cancer (14). However, in Western countries, lateral pelvic lymph node metastasis is considered a systemic disease and patients often receive preoperative adjuvant chemoradiotherapy.

In our study, the rate of pelvic lymph node metastasis was 16% (4/25). In a Japanese multicenter retrospective study, including 1,977 patients of whom 930 underwent pelvic sidewall dissection without adjuvant radiotherapy, positive lateral lymph nodes were found in 13.9% (129/930) of patients (15). Similarly, the rate of lateral pelvic lymph node metastasis in other studies was 10.6-25.5% (8-11). This suggests that pelvic lymph node

Complication	LPLD group	No LPLD group	p
Anastomotic bleeding (n)	0	4	
Anastomotic leakage (n)	1	8	
Wound infection (n)	1	7	
Perineal wound infection (n)	1	4	
Intestinal obstruction (n)	2	5	
Abscess in abdomen (n)	0	4	
Urinary dysfunction (n)	2	6	
Other (n) (deep vein thrombosis, tachycardia)	2	1	
Total, n (%)	6 (24.0)	24 (26.1)	0.832

Table 3. Postoperative complications

metastasis in rectal cancer is a significant risk factor for recurrence after surgery. In 1975, Koyama et al. (12) demonstrated that LPLD could significantly reduce local recurrence, with other studies also reporting similar results (9-11).

In our study, there was a significant difference in the rate of intraoperative complications between the LPLD group and the no LPLD group ($p < 0.05$). Intraoperative complications in the LPLD group included bladder injury (2/25, 8%), ureter injury (1/25, 4%), and obturator nerve injury (1/25, 4%). One patient in the LPLD group was converted to open surgery due to bleeding. Our initial experience suggested several ways to limit these complications.

Firstly, the ureter was exposed followed by dissection along the ureter. The ureter and hypogastric nerve form a membrane-like structure called the ureter-hypogastric fascia. We dissect along this structure close to the bladder to reveal the lateral pelvic region to avoid damage to the pelvic autonomic nerves as well as the ureter. Secondly, we identified the obturator nerve which passes through the obturator fat tissue, then dissected along the obturator nerve and removed all fat tissue around it. Nonaka et al. (16) suggest that identification of the vesicohypogastric fascia is important to reduce hemorrhage. The vesicohypogastric fascia includes the internal iliac artery as an important landmark for the dissection border between internal and external areas. Identification of the vesicohypogastric fascia early in the operation may contribute to reducing blood loss and shortening the operating time.

In our study, we found that the rate of postoperative complication was 24% (6/25) in the LPLD group and 26.1% (24/92) in the no LPLD group. The difference was not statistically significant ($p > 0.05$). In other studies, the rate of complication after laparoscopic LPLD was 7–41% (17). Ogura et al. (18) found that 36 patients (33.6%) in the laparoscopic PLND group and 54 patients (24.5%) in the TME group developed

postoperative complications ($p = 0.0839$). Major complications, defined as those higher than grade 3 in the Clavien - Dindo classification, occurred at similar frequencies in both groups (laparoscopic PLND, 9.4%; TME, 5.5%; $p = 0.188$). Similarly, Bae et al. (19) reported that six patients (28.6%) developed postoperative complications; three with anastomotic leakages, two with ileus leakages, and one patient with chyle leakage. Two patients (9.5%) developed urinary incontinence. Sexual and urinary dysfunctions are the main complications after rectal surgery with LPLD. However, the technique of automatic nerve preservation has minimized these functional disorders after surgery. In our study, the rate of urinary dysfunction was 8% (2/25) in the LPLD

	LPLD group (n=25) (%)	No LPLD group (n=92) (%)	p
Pathological tumor stage, n (%)			0.382
pT0	4 (16.0)	20 (21.7)	
pT1	2 (8.0)	6 (6.5)	
pT2	7 (28.0)	29 (31.5)	
pT3	8 (32.0)	33 (35.9)	
pT4	4 (16.0)	4 (4.3)	
Pathological node stage, n (%)			0.262
pN0	15 (60.0)	70 (76.1)	
pN1	8 (32.0)	16 (17.4)	
pN2	2 (8.0)	6 (6.5)	
Mean harvested lymph node dissection (min-max)		13.5 (5–29)	8.1 (2–19) 0.000
Lateral pelvic lymph node metastases, n (%)			
Positive	4 (16.0)	-	
Negative	22 (84.0)	-	
Left	3 (12.0)		
Right	1 (4.0)		
Circumferential resection margin, n (%)			0.065
Positive	3 (12.0)	2 (2.2)	
Negative	22 (88.0)	90 (97.8)	
Tumor differentiation (n)			0.399
Well	0	3	
Moderate	18	64	
Poor or mucinous	5	9	
No tumor cell after CRT	2	16	

Table 4. Pathological results. CRT, chemoradiotherapy.

group and 6.5% (6/92) in the no LPLD group. Recently, a Japanese randomized controlled trial showed similar rates of sexual and urinary dysfunction between open rectal surgery with and without LPLD (male sexual dysfunction was 68% and 79% respectively, $p = 0.37$; urinary dysfunction with residual urine ≥ 50 mL was 59% and

58% respectively, $p > 0.05$) (20, 21). Our study has some limitations. Firstly, we only started performing LPLD in 2019; therefore, the number of patients was small and we could not evaluate long-term outcomes. Secondly, this study was not a randomized clinical trial. In a follow-up study, we will include a larger number of patients as well as a longer follow-up period to evaluate long-term outcomes.

6. CONCLUSION

The present study demonstrated that LPLD has an important role in the treatment of advanced lower rectal cancer. Laparoscopic LPLD is a safe and feasible procedure. However, this was a retrospective study with a limited number of patients, so further evidence is needed to evaluate oncological outcomes.

Abbreviations: BMI: body mass index; ISR: intersphincteric resection; LAR: lower anterior resection; APR: abdominoperineal resection; LPLD: lateral pelvic lymph node dissection; CRT: chemoradiotherapy; CRM: Circumferential resection margin.

Ethics approval and informed consent: *The study was approved by the Ethics Committee of 108 Military Central Hospital (Ref: 4468/QĐ-BV108 dated 25 Sep 2020). Every patient signed an informed consent form before inclusion in the study.*

- **Author's contribution:** Trieu Trieu Duong and Ho Huu An contributed equally to this article as co-first authors. Trieu Trieu Duong and Ho Huu An contributed to the acquisition, analysis, and interpretation of data. Each author had a part in preparing the article and revising it critically for important intellectual content. Each author gave final approval of the version to be published and agreed to be accountable for all aspects of the work to ensure that any questions related to the accuracy or integrity of any part of the work are appropriately investigated and resolved.
- **Conflict of interest:** There are no conflicts of interest to declare.
- **Financial support and sponsorship:** Nil.
- **Acknowledgements:** The authors thank the medical staff of the Department of Colon and Rectal Surgery, 108 Military Central Hospital, Hanoi, Vietnam for their participation in this study. We could not have completed this study without their diligence and support.

REFERENCES

1. Henriques MA, Matos E, Castro FP, et al. Rectal cancer epidemiology. in: Santoro GA, editor. Rectal Cancer - A Multidisciplinary Approach to Management. Croatia: InTech. 2011: 3-18.
2. Dahl O, Horn A, Morild I, Halvorsen JF, Odland G, Reinertsen S, et al. Low-dose preoperative radiation postpones recurrences in operable rectal cancer. Results of a randomized multicenter trial in western Norway. *Cancer*. 1990; 66(11): 2286-2294.
3. Holm T, Rutqvist LE, Johansson H, Cedermark B. Abdominoperineal resection and anterior resection in the treatment of rectal cancer: results in relation to adjuvant preoperative radiotherapy. *Br J Surg*. 1995; 82(9): 1213-1216.
4. Arnaud JP, Nordlinger B, Bosset JF, Boes GH, Sahnoud T, Schlag PM, et al. Radical surgery and postoperative radiotherapy as combined treatment in rectal cancer. Final results of a phase III study of the European Organization for Research and Treatment of Cancer. *Br J Surg*. 1997; 84(3): 352-357.
5. Leo E, Belli F, Andreola S, Gallino G, Bonfanti G, Ferro F, et al. Total rectal resection and complete mesorectum excision followed by coloanoanal anastomosis as the optimal treatment for low rectal cancer: the experience of the National Cancer Institute of Milano. *Ann Surg Oncol*. 2000; 7(2): 125-132.
6. Tocchi A, Mazzoni G, Lepre L, Liotta G, Costa G, Agostini N, et al. Total mesorectal excision and low rectal anastomosis for the treatment of rectal cancer and prevention of pelvic recurrences. *Arch Surg*. 2001; 136(2): 216-220.
7. Law WL, Chu KW. Impact of total mesorectal excision on the results of surgery of distal rectal cancer. *Br J Surg*. 2001; 88(12): 1607-1612.
8. Sugihara K, Moriya Y, Akasu T, Fujita S. Pelvic autonomic nerve preservation for patients with rectal carcinoma. Oncologic and functional outcome. *Cancer*. 1996; 78(9): 1871-1880.
9. Moriya Y, Sugihara K, Akasu T, Fujita S. Importance of extended lymphadenectomy with lateral node dissection for advanced lower rectal cancer. *World J Surg*. 1997; 21(7): 728-732.
10. Shirouzu K, Ogata Y, Araki Y, Sasatomi T, Nozoe Y, Nakagawa M, et al. Total mesorectal excision, lateral lymphadenectomy and autonomic nerve preservation for lower rectal cancer: significance in the long-term follow-up study. *Kurume Med J*. 2001; 48(4): 307-319.
11. Ueno M, Oya M, Azekura K, Yamaguchi T, Muto T. Incidence and prognostic significance of lateral lymph node metastasis in patients with advanced low rectal cancer. *Br J Surg*. 2005; 92(6): 756-763.
12. Koyama Y, Moriya Y, Hojo K. Effects of extended systematic lymphadenectomy for adenocarcinoma of the rectum - significant improvement of survival rate and decrease of local recurrence. *Jpn J Clin Oncol*. 1984; 14(4): 623-632.
13. Hojo K, Koyama Y. The effectiveness of wide anatomical resection and radical lymphadenectomy for patients with rectal cancer. *Jpn J*. 1982; 12(2): 111-116.
14. Watanabe T, Itabashi M, Shimada Y, Tanaka S, Ito Y, Ajioka Y, Japanese Society for Cancer of the Colon and Rectum (JSCCR) Guidelines 2014 for treatment of colorectal cancer. *Int J Clin Oncol*. 2015; 20(2): 207-239.
15. Sugihara K, Kobayashi H, Kato T, Mori T, Mochizuki H, Kameoka S, et al. Indication and benefit of pelvic sidewall dissection for rectal cancer. *Dis Colon Rectum*. 2006; 49(11): 1663-1672.
16. Nonaka T, Fukuda A, Maekawa K, Nagayoshi S, Tokunaga T, Takatsuki M, et al. Clinical and Oncological Outcomes of Laparoscopic Lateral Pelvic Lymph Node Dissection in Advanced Lower Rectal Cancer: Single-institution Experience. *Anticancer Res*. 2017; 37(9): 5095-5100.
17. Nakanishi R, Yamaguchi T, Akiyoshi T, Nagasaki T, Nagayama S, Mukai T. Laparoscopic and robotic lateral lymph node dissection for rectal cancer. *Surg Today*. 2020; 50(3): 209-216.
18. Ogura A, Akiyoshi T, Nagasaki T, Konishi T, Fujimoto Y, Nagayama S, et al. Feasibility of Laparoscopic Total Mesorectal Excision with Extended Lateral Pelvic Lymph Node Dissection for Advanced Lower Rectal Cancer after Preoperative Chemoradiotherapy. *World J Surg*. 2017; 41(3): 868-875.
19. Bae SU, Saklani AP, Hur H, Min BS, Baik SH, Lee KY, et al. Robotic and laparoscopic pelvic lymph node dissection for rectal cancer: short-term outcomes of 21 consecutive series. *Ann Surg Treat Res*. 2014; 86(2): 76-82.
20. Ito M, Kobayashi A, Fujita S, Mizusawa J, Kanemitsu Y, Kinugasa Y, et al. Urinary dysfunction after rectal cancer surgery: Results from a randomized trial comparing mesorectal excision with and without lateral lymph node dissection for clinical stage II or III lower rectal cancer (Japan Clinical Oncology Group Study, JCOG0212). *Eur J Surg Oncol*. 2018; 44(4): 463-468.
21. Saito S, Fujita S, Mizusawa J, Kanemitsu Y, Saito N, Kinugasa Y, et al. Male sexual dysfunction after rectal cancer surgery: Results of a randomized trial comparing mesorectal excision with and without lateral lymph node dissection for patients with lower rectal cancer: Japan Clinical Oncology Group Study JCOG0212. *Eur J Surg Oncol*. 2016; 42(12): 1851-1858.