

Submitted: 07/06/2022

Accepted: 22/08/2022

Published: 21/09/2022

## Morphological study on the skull sutures and their relationships to skull morphology in young camels (*Camelus dromedarius*)

Gamal Mounir Allouch\* , and Fahad Abdullah Alshanbari 

Department of Veterinary Medicine, College of Agriculture and Veterinary Medicine, Qassim University, Saudi Arabia

### Abstract

**Objective:** The sutures are associated with anatomical and physiological differences in skull camels. There is a deficiency in the information regarding the anatomy of dromedary camels, especially on fibrous joints (sutures) of the camels' skull.

**Aim:** The goal of this work was to give a detailed gross anatomical and radiographic description of the sutures in the camels' skull. This description may be of great importance for veterinarians to differentiate between the suture and the fracture of the head in the radiographic photos.

**Methods:** The current study was conducted on 10 skulls of the young (Howar) dromedary camel at 4–10 months old. The skulls were prepared by using the boiling and maceration techniques. The gross and radiographic photos of the sutures were taken using a digital camera and Siemens mobile full-wave X-ray machine (Siemens Medical Solutions, Erlangen, Germany).

**Results:** The skull is made up of nineteen bones -6 single and 13 paired-the majority of which are joined by joints termed as sutures. The sutures of the camel skulls were viewed in dorsal, ventral, lateral-vertical, and inside directions. They were of four types which are the coronal, serrate, plane, and squamosal sutures in different positions of the skull.

**Conclusion:** The current study showed that the fibrous joints of camel skulls (sutures) were similar to those of other domestic animals. This information is critical for supporting veterinarians to differentiate sutures from fractures that may have happened in the skull of the dromedary camel using radiological pictures.

**Keywords:** Morphology, Skull, Sutures, Young camels.

### Introduction

There is a deficiency in the information regarding the anatomy of dromedary camels, especially those involving the fibrous joints (sutures) of the camels' skull (Rice, 2008; Lindsay *et al.*, 2021) mentioned that in horses, craniofacial sutures were fibrous connections between the flat bones of the skull, enabling a limited amount of movement. Sutures are not only used to join adjoining bones; they are the principal sites of osteogenesis in the skull (Rice, 2008).

Smuts and Bezuidenhout (1987) presented early research that explained the bones that form the camels' skull. According to previous studies, the sutures are caused by anatomical structure and functional differences in the camel skull (Wilson, 1984; El-Allali *et al.*, 2013). The shape of the skull relates to the configuration of articulation between the skull bones and related bones such as the frontal, temporal, zygomatic, and parietal bones which have been proven to create a full suture- or fissure-like structure in the zygomatic and parietal bones, in different domestic animals (Getty, 1975; Evans, 1993) and goat (Yi *et al.*, 1998). This work aims to focus on the sutures and outer anatomical landmark points of the camel skull. The results of this study will help clarification of the pattern and shape of sutures. It

might be useful in osteological examinations and give material for future scientific research.

### Materials and Methods

Ten camel skulls of both sexes 4–10 months old, less than one year (Ramadan, 1994), were used in this study. The heads were obtained from Buraidah slaughterhouse, Qassim Region, Qassim, K S A. Camel skulls were pre-processed through the boiling process in water containing 30% sodium hydroxide (NaOH). Then dried at room temperature for two days. Then, they were preserved in 4% in hydrogen peroxide solutions for three days, then dried for three days (Allouch, 2014; Choudhary and Singh, 2016; Choudhary *et al.*, 2021). The form and morphology of the sutures were studied in this paper. Anatomical descriptions included a detailed examination of the skull sutures as a whole. Numerous sutures of the skull were studied by observations of all the skulls by the naked eye, and photographs examinations Also, mediolateral latero-medial, ventrodorsal, and dorsoventral, radiographic power projections of the skull were obtained using a Min X-ray HF 100/30 generator (Toshiba, Tokyo, Japan) at 70 kV, 2.0 mAs, and a focal film distance of 70 cm.

\*Corresponding Author: Gamal Mounir Allouch. College of Agriculture and Veterinary Medicine, Qassim University, Saudi Arabia. Email: [g.allouch@qu.edu.sa](mailto:g.allouch@qu.edu.sa)

### Ethical approval

All the procedures involving sample collection were conducted as per the Institutional Animal Ethics Committee.

### Results

The skull is the osseous structure of the head. It is the most complex bony structure. It has the form of a five-sided pentagon irregularly. The skull consists of 36 separate bones, many of which are paired, some of them single, and most of these bones are held together by joints termed as sutures. The cranial suture consists of adjacent borders of the skull bones. Some sutures do it from the sides and back of the skull to the forehead. From the front of the head to the back, one suture is located in the middle of the skull. The junctions of sutures have morphological changes different from

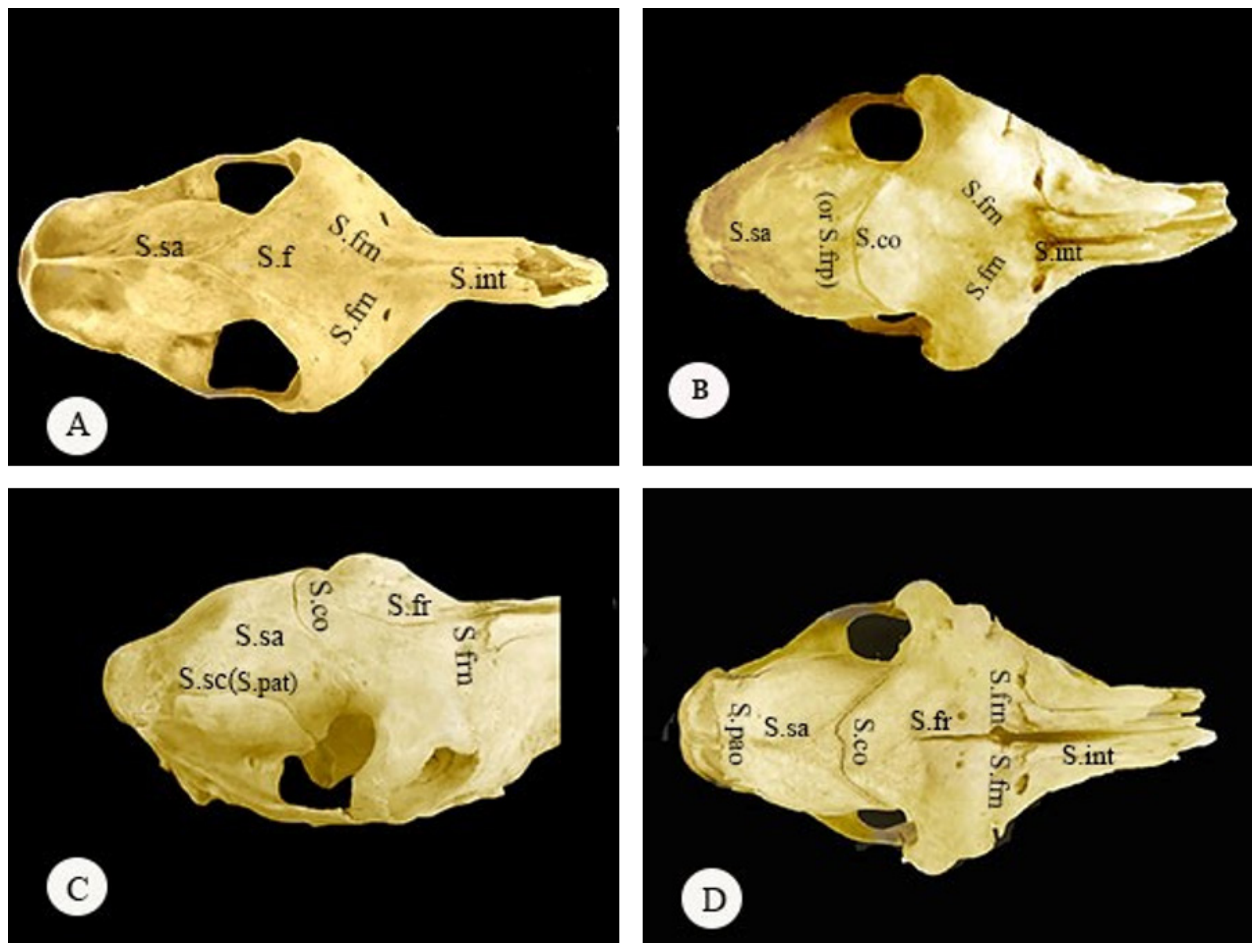
one bone to another. The sutures articulately help in the formation of the face by firmly connecting the surrounding skull bones. Sutures form a tight union that prevents most movement between the bones. Most sutures are named for the bones articulate, but some have special names of their own. The sutures joints of the camel skull are divided into four groups according to the viewer's surface.

#### The dorsal group

This group of sutures is seen from the dorsal surface (Fig. 1). This includes the articulation points of the following nasal, frontal, parietal, interparietal, and lacrimal bones.

#### 1. Sutura plana internasalis (S.int)

It is single, formed between two of the nasal bones of the opposite side, it lies midline rostral to the facial skull (Fig. 1A, a; B, a; and D, a).



**Fig. 1.** Dorsal view of skull showing the site of the skull sutures. (A): (a) S.int: Sutura internasalis, (b) S.fm: Sutura frontonasalis, (c) S.fr: Sutura frontalis and (d) S.sa: Sutura sagittalis. The camel's age is 10 months. (B): (a) S.int: Sutura internasalis, (b) S.fm: Sutura frontonasalis, (c) S.co: Sutura Coronalis Or S.frp: Sutura frontoparietalis, (d) S.sa: Sutura sagittalis. The camel's age is 6 months. (C): (a) S.fm: Sutura frontonasalis, (b) S.fr: Sutura frontalis, (c) S.co: Sutura Coronalis Or S.frp: Sutura frontoparietalis, (d) S.sa: Sutura sagittalis, (e) S.sc: Sutura squamosal cranii or S.pat: Sutura squamosal parieto-temporallis. The camel's age is 6 months. (D): (a) S.int: Sutura internasalis, (b) S.fm: Sutura frontonasalis, (c) S.fr: Sutura frontalis, (d) S.co: Sutura Coronalis or S.frp: Sutura frontoparietalis, (e) S.sa: Sutura sagittalis, (f) S.pao: Sutura Parieto-occipitalis. The camel's age is 4 months.

## 2. Sutura serrata frontonasalis (S.frn)

It is made between the caudal edge of the nasal bones and the cranial border of the frontal bones and has uneven borders; the caudal projection of the nasofrontal suture is more caudal than the maxillary-frontal suture (Fig. 1A, b; B, b; C, a; and D, b). The frontonasal suture has a higher degree of interdigitation than the other sutures.

## 3. Sutura plana frontalis (S.fr)

It is a vertical suture between the right and left frontal halves. but it only often ends up in adults (Fig. 1A, c; C, b; and D, c). In young camels, it was visible in the skull, but following ossification, it vanished altogether.

## 4. Sutura Coronalis (S.co)

It termed as Sutura frontoparietalis—(S.frp). It is formed between the caudal aspect of the frontal and the cranio-ventral aspect of the parietal bones (Figs. 1B, c; C, c; D, d; and 6f). The coronal suture is smooth and not prominent. The coronal suture between the frontal and parietal plate bone transferred to synostosis where the fusion of the parietal and frontal bone.

## 5. Sutura sagittalis (S.sa) or Sutura plana parietalis (S.pa)

It is a single and extends from the parietal plate bone at the coronal suture cranially to the nuchal crest caudally (Figs. 1A, d; B, d; C, d, D, e, 6; and 7a), where the two parietal bones meet in the suture. The sagittal suture between the two parietal bone transfer to synostosis where the fusion of the two parietal bones.

## 6. Sutura serrata Parieto-occipitalis (S.pao)

Each parietal plate bone joins the occipital bone. It extends transversely direction at the back of the skull (Figs. 1D, f and 6g).

### The lateral group

The sutures in this group are paired and can be visible from the lateral side (Figs. 2 and 5). This includes those related to incisive, maxillary, lacrimal, zygomatic, and temporal.

## 1. Sutura Serrata incisiveomaxillaris (S.inm)

The suture has irregular borders in both bones where the incisive bone joins laterally and vertically with the lacrimal bone (Figs. 2A, a and 5a).

## 2. Sutura plana nasomaxillaris (S.nam)

I has plane borders, and the nasal bone articulates laterally and horizontally with the lacrimal bone (Figs. 2A, b and 5b).

## 3. Sutura Serrata frontomaxillaris (S.frm)

They have bilateral long narrow cuts—fissures, like were observed in the area, joined between the frontal and maxillary bones (Fig. 2A, c). There was no continuous articulation of the front maxillary suture where the bones met in some camels, while they were either absent or unilateral in the remaining skulls.

## 4. Sutura Serrata lacrimomaxillaris (S.lam)

This suture has irregular margins at the lacrimal bone and articulates horizontally with the molar bone, it lies rostral to the level of the orbit of the skull (Fig. 2B, a).

## 5. Sutura Serrata frontolacrimalis (S.frl)

The frontal bone articulates laterally with the lacrimal bone, its irregular borders and lies dorsolateral of the skull (Fig. 2B, b and C, b).

## 6. Sutura Serrata zygomaticomaxillaris (S.zym)

The maxillary bone meets vertical with the zygomatic bone, this suture has an irregular border of both bones (Fig. 2A, e; B, c; and C, c).

## 7. Sutura plana zygomaticotemporalis (S.yzt)

It is the overlapping and adhesion of the zygomatic process of the temporal bone and the temporal process of zygomatic bone through the plane edges (Fig. 2C, d).

## 8. Sutura squamosal cranii (S.sc)

It is called Sutura squamosal parieto-temporalis (S. pat) joins the parietal bone and the temporal bone bilaterally (Figs. 1C, e; 2D, a; and 5c). It extends caudally, curves ventrally, and continues as the parietal-occipital suture. The occipitotemporal suture and the parietotemporal suture connect the lateral end of the lambdoid suture.

## 9. Sutura occipital-temporalis(S.oct) or Sutura Squamosal occipitomastoidea (S.oem)

It is the obliquely directed connection of the cranial margin of the squamous occipital bone and the mastoid part of the temporal bone (Fig. 3A, f).

## 10. sutura squamosopetrousalis (S.sq p)

It takes the form of a slight arc representing the union of the external border of the squamous part and petrous portions of the temporal bone (Figs. 2D, b and 5e). The occipitotemporal suture and the parietotemporal suture meet the lateral end of the lambdoid suture at the assertion.

## 11. Sutura lambdoidea(S.la)

It is located at the end of the skull between the two parietal and occipital bones and forms a dens (Λ) shape (Fig. 2D, c). It is continuous with the occipital-mastoid suture, which connects the occipital bone with the mastoid part of the temporal bones.

### The ventral group

It comprises skull sutures that are apparent from the ventral view, which also include those connected to the palatine, pterygoid, sphenoid, temporal, and occipital bone (Figs. 3 and 6).

## 1. Sutura plana incisive (S.inc)

The anterior palatine suture appears as a linear suture in young skulls that extends from the ventral surface of the palatine process of the maxillary bone to the incisive foramen and the space between the lateral incisor and the canine tooth (Fig. 3A, a).

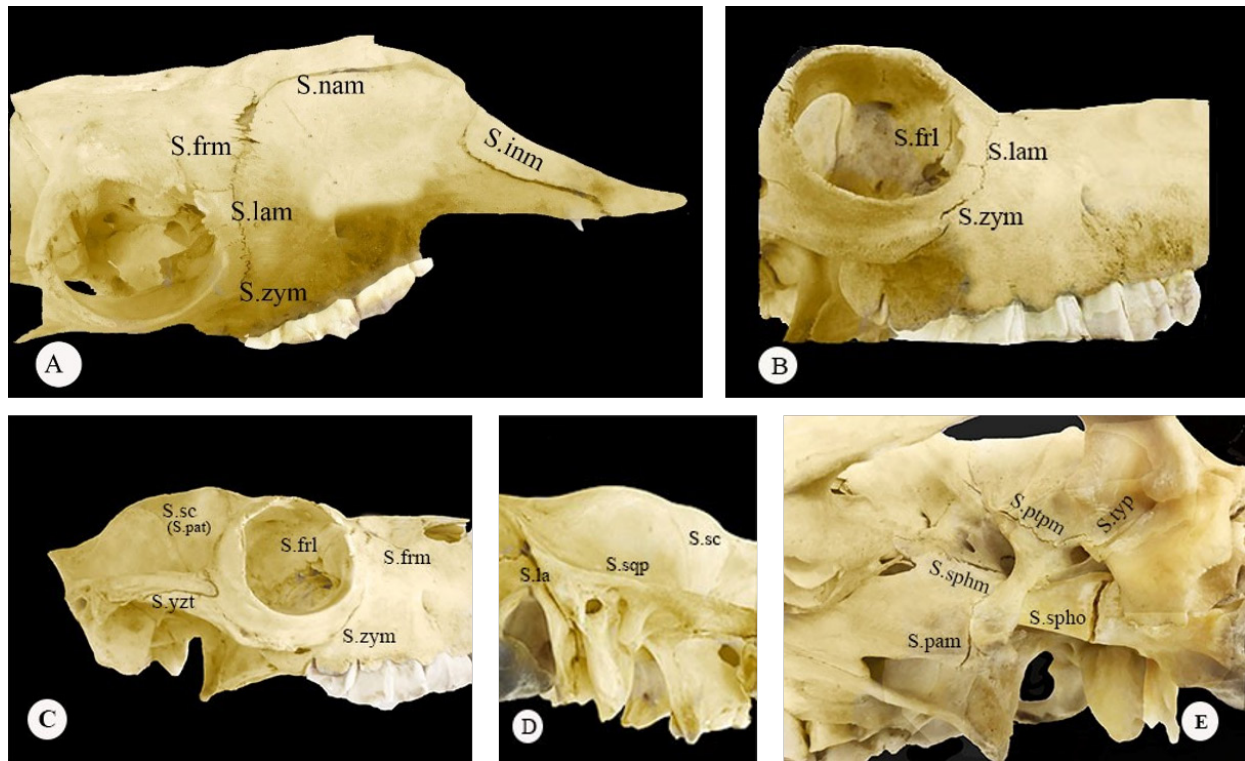
## 2. Sutura plana palatina mediana (S.pam)

It is formed at the line of fusion of the horizontal plates of the palatine processes of the maxillary bone at the median plane (Figs. 3A, b; B, a; and 6a). It extends rostrally through the inter-incisive suture and continues the transverse palatine suture caudally.

## 3. Sutura Serrata palatina transversa (S.pat)

It is formed of unit two of the palatine bones, and the palatine process of the maxillary (Figs. 3A, c; B, b; and 6b).





**Fig. 2.** Lateral view of skull showing the position of the skull sutures. (A): (a) S.inm: Sutura incisiveomaxillaris, (b) S.nam: Sutura nasomaxillaris, (c) S.frm: Sutura frontomaxillaris, (d) S.lam: Sutura lacrimomaxillaris, (e) S.zym: Sutura zygomaticomaxillaris. The camel's age is 8 months. (B): (a) S.lam: Sutura lacrimomaxillaris, (b) S.frl: Sutura frontolacimalis, (c) S.zym: Sutura zygomaticomaxillaris. The camel's age is 8 months. (C): (a) S.frm: Sutura frontomaxillaris, (b) S.frl: Sutura frontolacimalis, (c) S.zym: Sutura zygomaticomaxillaris, (d) S.yzt: Sutura zygomaticotemporalis, (e) S.sc: Sutura squamosal cranii or S.pat: Sutura squamosal parieto-temporalis. The camel's age is 6 months. (D): (a) S.sc: Sutura squamosal cranii or S.pat: Sutura squamosal parieto-temporalis, (b) S.sqp: Sutura squamosopetrousalis, (c) S.la: Sutura lambdoidea. The camel's age is 6 months. (E): (a) S.sphm: Sutura sphenomaxillaris, (b) S.typ: Sutura plana tympanopetrousalis, (c) S.ptpm: Sutura pterygo-palatino-maxillaris, (d) S.pam: Sutura plana palatomaxillaris and (e) S.spho: Sutura spheno-occipitalis. The camel's age is 8 months.

#### 4. Sutura plana palatomaxillaris (S.pam)

It joins the end of the alveolar margin with the horizontal plate of the maxillary bone with the lateral margin of the palatine bone (Figs. 2E, c; 3A, d; and B, c).

#### 5. Sutura foliate sphenovomeriana (S.sphv)

It is a cranial suture that connects the sphenoid and vomer bones to the nasal septum ventrally (Fig. 3A, e; B, d; and 6d). It has small articular surfaces that are separated into thin parallel lamellas that correspond to the vomer and sphenoid bones.

#### 6. Sutura plana spheno-occipitalis (S.spho)

It is the junction between the basphenoid and basioccipital plate bones, the suture has oblique articular surfaces that are separated into thin parallel lamellas that correspond to the sphenoid and occipital bones (Figs. 2E, e; 3A, f; and B, e).

#### 7. Sutura foliate pterygo-Palatino-maxillaris (S.ptpm)

This suture is attached to four pieces of ossification are pterygoid, maxillary, palatine, lateral, and medial plates of the pterygoid process of the sphenoid bone)

(Figs. 2E, d; 3B, f; and 6, c). It has been found the cranial-ventrally direction of the palate-maxillary-sphenoid bones. The pterygopalatomaxillary suture is considered to have an important role in the posteroanterior growing of the maxilla.

#### 8. Sutura squamosal Petroulis (S.sp)

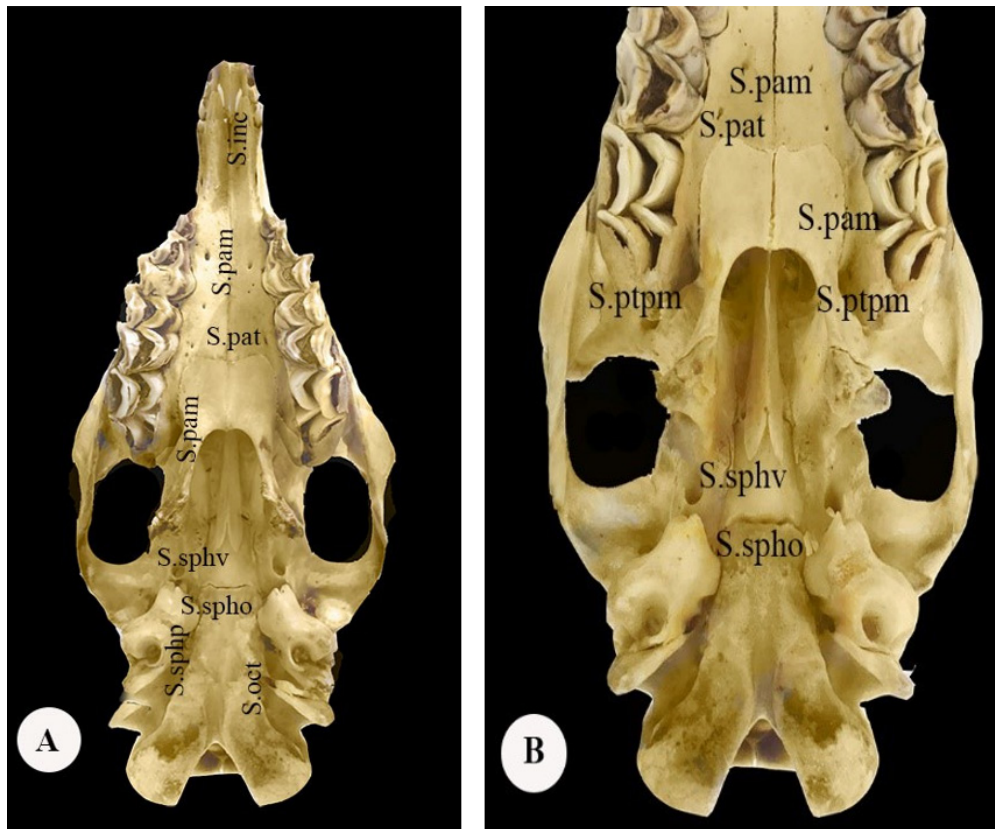
It articulates between the interosseous borders of the petrous and squamous parts of the temporal bone (Fig. 2D, b and E, a).

#### 9. Sutura foliata sphenomaxillaris (S.sphm)

It attaches the pterygoid processes of the basphenoid part of the sphenoid bone and the hook of the maxillary bone (Fig. 2E, a).

#### 10. Sutura plana sphenoparietalis (S.sphp)

The sphenoid-petrosal of temporal suture or sphenosquamosal suture connects the caudal edge of the greater wing of the sphenoid bone with the cranial border of the squamous part of the temporal bone (Fig. 3A, h). This suture is a vertical cranial suture that



**Fig. 3.** Ventral view of skull showing the site of the skull sutures. (A): (a) S.inc: Sutura incisiva, (b) S.pam: Sutura palatina mediana, (c) S.pat: Sutura palatina transversa, (d) S.pam: Sutura palatomaxillaris, (e) S.sphv: Sutura sphenovomeriana, (f) S.spho: Sutura spheno-occipitalis, (g) S.oct: Sutura occipital-temporalis or S.ocm Sutura occipitomastoidea, (h) S.sphp: Sutura sphenoparietalis. The camel's age is 6 months. (B): (a) S.pam: Sutura palatina mediana, (b) S.pat: Sutura palatina transversa, (c) S.pam: Sutura plana palatomaxillaris, (d) S.sphv: Sutura sphenovomeriana, (e) S.spho: Sutura spheno-occipitalis, (f) S.ptpm: Sutura pterigo-palatino-maxillaris. The camel's age is 6 months.

lies directly lateral to the foramen oval and forms part of the caudal wall of the foramen lacerum.

#### 11. Sutura plana tympanopetrousalis (S.typ)

It lies between the cranial edge of the tympanic and petrous parts of the temporal bone (Fig. 2E, b). It is considered a medial continuation of the tympanic squamosal suture.

#### The inside a group

The skull sutures of this group are visible from the inside of the skull involving the ethmoid bone (Figs. 4 and 7). It articulates with the frontal bone dorsally, two parietal bones laterally, and sphenoid and vomer bone ventrally.

#### 1. Sutura Serrata frontoethmoidalis (S.freth)

The suture is formed between the cribriform plate of the ethmoid bone and the ventral aspect of the frontal bone (Figs. 4a and 7b).

#### 2. Sutura limbosa parieto ethmoidalis (S.paeth)

It is a bilateral and overlapping suture. It is located between the ethmoid bone's perpendicular plate and the medial wall of the parietal bone (Figs. 4b and 7c).

#### 3. Sutura limbosa sphenothmoidalis (S.spheth)

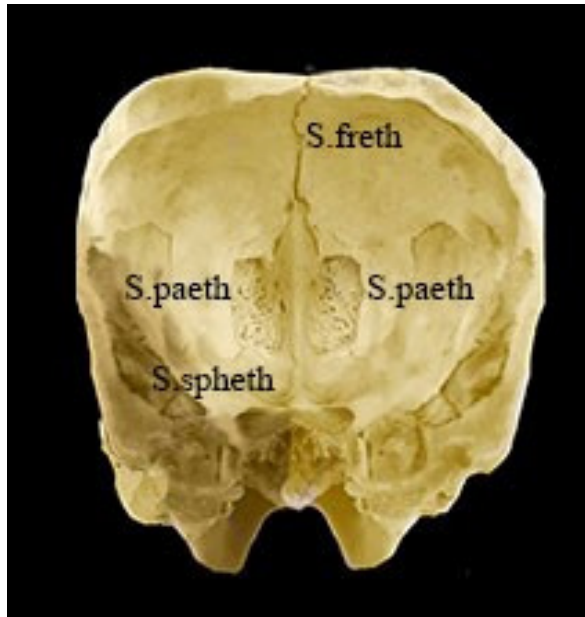It is formed between the body of the presphenoid of the sphenoid bone and the perpendicular and cribriform plates of the ethmoidal bone (Figs. 4c and 7d).

#### Discussion

All bones of the skull except the mandible are firmly interconnected in adults by immobile fibrous joints called sutures. The pattern and shape of the sutures in the skull depending on the shape and size of the bones involved in different types of animals, especially camels.

The sutures in the camel skull were investigated, and it was revealed that the bones are joined by sutures. These findings agree with that of Standring (2008) who stated that the majority of these bones were connected by sutures and are isolated sutural bones of different shapes and sizes. Cohen (2000) and Persson (1995) recorded that the sutures are sites of appositional bone growth that are crucial in the developing skull. Klein *et al.* (2019) showed that the sutures are not always

in the same anatomical location. On the contrary, in our study, the location doesn't change, but with the development of age, it becomes less visible as a result of the ossification process. On the other hand; De Pollack (1996) stated that increased bone growth at suture margins is linked to cranial suture fusion (craniosynostosis) and added that Jones *et al.* (2011) recorded that there are over 100 sutural joints in the skull. The suture has been intensively investigated as



**Fig. 4.** Vertical or inside view of skull showing the position of the skull sutures. (a) S.freth: Sutura frontoethmoidalis, (b) S.paeth: Sutura parieto ethmoidalis, (c) S.spheth: Sutura sphenoethmoidalis. The camel's age is 6 months.

a model system for skeletal development, according to the report by Di Ieva *et al.* (2013).

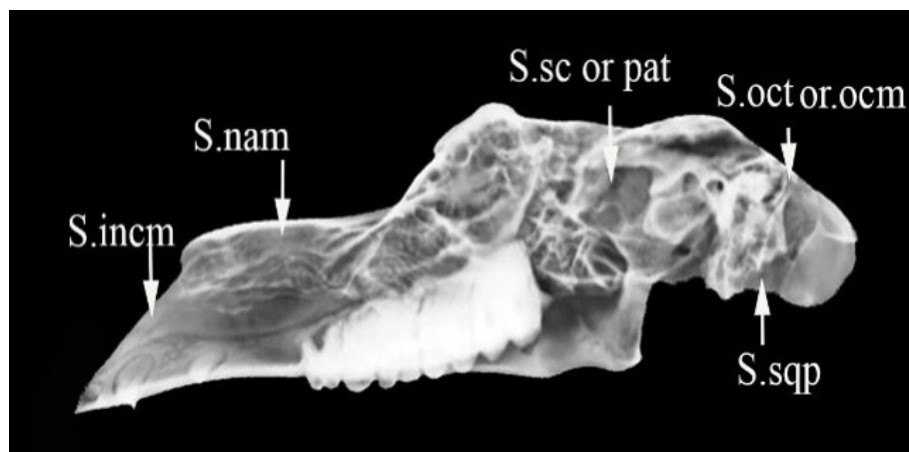
The pattern of joints between the facial and cranial bones and the surrounding bones, such as the maxillary and others, has been shown in numerous domestic animals as having a full suture- or fissure-like structure (Getty, 1975; Miller *et al.*, 1975).

The camel skull has various types of sutures which are related to the shape and nature of the attached bone to give the skull a unique shape that suits the environment in which it lives. Our findings are in accordance with those in different domestic animals (Getty, 1975; Evans, 1993) and goats (Yi *et al.*, 2001) reported that the differences between animals depend on the articulation configuration between the skull bones and adjacent bones such as the maxillary, lacrimal, and incisive bones, which had been featured in a variety of different animals as producing a full suture.

In camels, the internasal suture and nasal suture were fused tightly to the surrounding bones, unlike in goats by Olopade (2006) and cattle by Getty (1975); Dyce *et al.* (2010), whereas Nickel *et al.* (1986) mentioned a prominent straight internasal suture in domestic animals. On the contrary, they were not completely fused to the surrounding bones, according to Getty (1975) and Dyce *et al.* (2010).

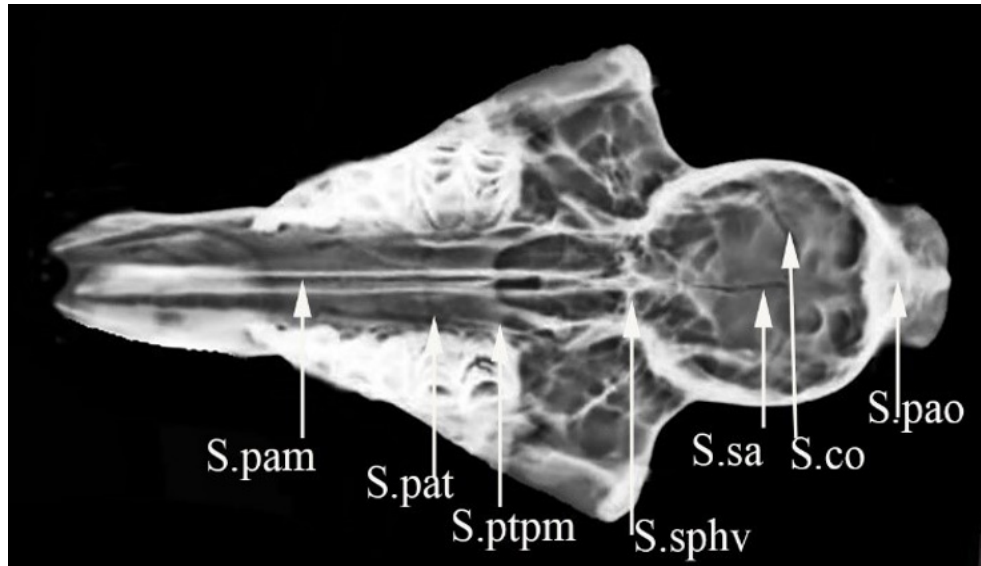
According to the coronal suture of the camel, it was smooth and not prominent. These results disagree with Capitan *et al.* (2011) presented skull coronal suture synostosis in cattle. On the other hand, the frontonasal suture has been found to have a higher degree of interdigitation than the other sutures (Rafferty and Herring, 1999).

In this study, the incisive and maxillary bones were observed articulated caudodorsally with the maxillary bone. Our results are in agreement with Smut (1986) in camels and Getty (1975) and Dyce *et al.* (2010) in

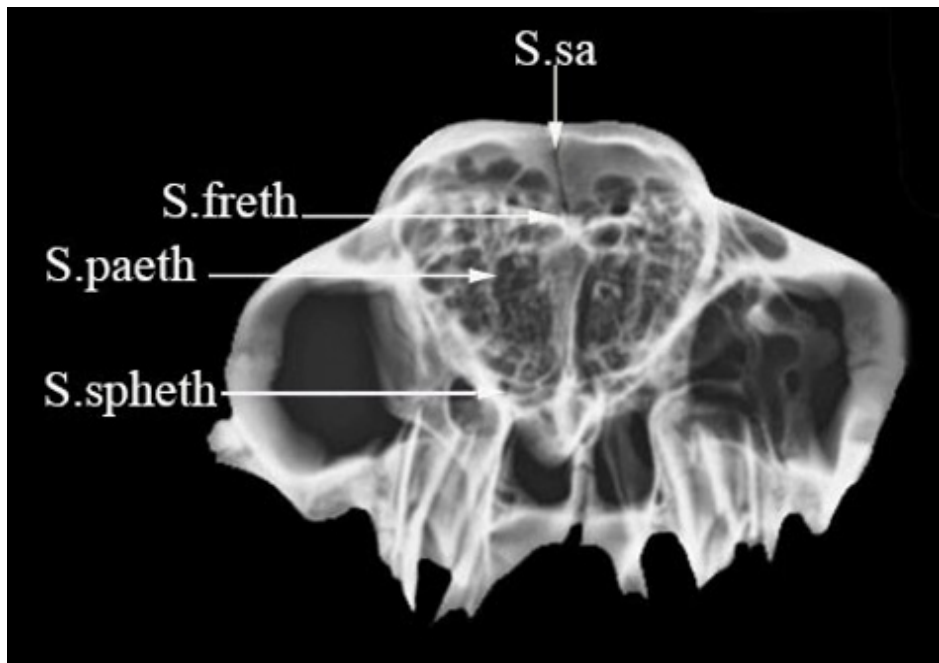


**Fig. 5.** Lateral radiograph of camel head view showing site of the skull sutures. (a) S.incm: Sutura incisiveomaxillaris, (b) S.nam: Sutura plana nasomaxillaris, (c) S.sc: Sutura squamosal cranii or S.pat: Sutura squamosal parieto-temporalis, (d) S.oct: Sutura occipital-temporalis or S.ocm: occipitomastoidea, (e) S.sqp: Sutura squamosopetrousalis. The camel's age is 10 months.





**Fig. 6.** Dorsoventral radiograph of camel skull showing position of the skull sutures: (a) S.pam: Sutura palatina mediana, (b) S.pat: Sutura palatina transversa, (c) S.ptpm: Sutura folata pterygo-palatino-maxillaris, (d) S.sphv: Sutura sphenovomeriana, (e) S.sa: Sutura sagittalis, (f) S.co: Sutura Coronalis, (g) S.pao: Sutura Parieto-occipitalis. The camel's age is 8 months.



**Fig. 7.** Posteroanterior radiograph of camel skull showing site of the skull sutures. (a) S.sa: Sutura sagittalis, (b) S.freth: Sutura frontoethmoidalis, (c) S.paeth: Sutura parieto ethmoidalis, (d) S.spheth: Sutura sphenothmoidalis. The camel's age is 8 months.

the sheep and cattle that stated the incisive bone was in contact with maxillary bones only.

On the other hand, the relevant findings disagree with Yahya *et al.* (2014) who reported that the incisive bone was related caudo-dorsally with maxillary and nasal bones in camels.

Yahya *et al.* (2014) represented that two types of suture patterns were observed; the first type of nasal-maxillary-incisive was the articulation of the maxilla to the nasal bone dorsally and the incisive bone rostrally to form naso-maxillo-incisive notch, while the second type was nasal-incisive notches. These findings were

not observed in the current investigation because there is no connection between the incisive and nasal bones, only between the incisive and maxillary bones, which form the incisive maxillary suture. However, there was various information concerning the nasolacrimal suture and the nasal-maxillary suture, which was mostly shown as the nasomaxillary suture in ruminants (Nickel *et al.*, 1986).

Smuts and Bezuidenhout (1987) stated that the nasal-incisive suture was clearly in camel; in contrast, the nasal-incisive suture was not seen in this study, which is similar to Yahya *et al.* (2014).

A paired nasofrontal serrate suture is serrate edges and formed between the caudal aspect of the nasal bones and the cranial aspect of the frontal bones.

The nasofrontal suture in this study has a large and wide surface resulting in a wider surface between the dorsal borders of the orbits between two frontal bones. These observations were in agreement with previously published reports in camel (Choudhary *et al.*, 2021).

Raghavan (1964) in ox, while Reda (2019) in lion published that the caudal projection of the nasofrontal suture extended more caudal than that of the maxillary-frontal suture. Moreover; Yahaya *et al.* (2012) in camels showed that there was no continuous meeting of the frontomaxillary suture in some camels and added that they were either absent or sometimes unilateral in the remaining skulls, in contrast, we resulted from a disagreement with the previous author where our results the maxillary-frontal suture was bilateral and all specimens. On the other hand, the nasofrontal suture of the horse was small and narrow as reported by Dyce *et al.* (2010).

Due to the absence of lacrimal bones at the place of meeting between the nasal, frontal, and maxillary bones in camels, nasofrontomaxillary suture found in this study cannot be termed a nasolacrimal fissure as in horses, cattle, and goats. This is because camel lacrimal bone is so small that it cannot reach the site of meetings between nasal and maxillary bone as recorded in cattle, goats, and horses by Getty (1975) and Dyce *et al.* (2010). The parietal and interparietal suture were located on the nuchal transverse crest and this suture united the parietal, interparietal bones, and nuchal crest of the occipital bone also shown in the ox skull (Raghavan, 1964). Similar recommendations were advised in previous studies by Sun *et al.* (2004) who stated that the internal surfaces of the interparietal sutures of all animals were flat or slightly irregular.

In this work, the occipital-mastoid squamosal suture or occipitotemporal suture extends in the groove between the occipital bone and the mastoid process of the temporal bone. Our findings agree with that of Shahid and Kausar (2005) in camels who recorded that the occipital bone joined the parietal bone in the transverse suture. In contrast to our findings, Choudhary *et al.* (2021) camel mentioned the occipital-temporal suture

in camel was situated between the occipital and parietal behind, the frontal dorsal and the sphenoid ventrally.

Similar results for median palatine have been reported by El-Allali *et al.* (2017) in camels who reported that the median palatine suture is formed at the lines of fusion of the two palatine bones and two maxillae bones and added that transverse palatine suture is the fusion of palatine bone and the palatine process of the maxillary bone. Contrary to the median palatine suture, a transverse palatine suture was missing in the binturong (Kalita *et al.*, 2020).

The spaces that remain in ruminants between most of the head bones on the other cannot be sutured but form fissures (Yahaya *et al.*, 2014). Smuts and Bezuidenhout (1987) reported that the camel skull outline appears closer to that of the equine. Similarities also exist in the age-related changing of the skull surface.

The ethmoid sutures in this study were the fronto-ethmoidal, parietal-ethmoidal, and sphenoid-ethmoidal sutures agree with Getty (1975) and Dyce *et al.* (2010) in domestic animals, and Gibelli *et al.* (2018) in humans recorded that the ethmoid bone consists of the cribriform plate, two ethmoid labyrinths, and the perpendicular plate articulates with frontal, parietal, and sphenoid bones. Finally, premature cranial suture fusion (craniosynostosis) is associated with increased bone formation at suture margins.

### Conclusion

The present study provided a solid foundation for a description of the cranial suture in the camel, which was the anatomical description of the camels' skull suture types including coronal, serrate, plane, squamosal, and foliate, which were different from other animals. The suture has been well studied as a model system. The sutures in their various forms were the locations of the union of the skull's bones. These sutures form important anatomical landmark points for surgical approaches to the closed box of the neuroskull enclosing the brain, arteries, and venous sinuses. These sutures form important anatomical landmark points for surgical approaches to the closed box of the neuro skull enclosing the brain, arteries, and venous sinuses.

### Acknowledgments

The authors would like to thank the Deanship of Scientific Research, Qassim University for financially aiding in the publication of this project. The authors acknowledge the support of the Department of Veterinary Medicine, College of Agriculture and Veterinary Medicine, Qassim University, Buraidah, Saudi Arabia.

### Conflict of interest

The authors declare that they have no competing interests.

### Authors contributions

G.A.: planned and conceived the study. G.A. and F.A. performed the practical section and interpreted



the results. Both authors wrote and revised the final manuscript.

### References

- Allouch, G.M. 2014. Scientific technique for skeleton preservation and preparation of anatomical models to promote veterinary anatomy. *J. Vet. Anat.* 7(2), 133–139.
- Capitan, A., Grohs, C., Weiss, B., Rossignol, M.N., Reversé, P. and Eggen, A. 2011. A newly described bovine type 2 scurs syndrome segregates with a frame-shift mutation in TWIST1. *PLoS One.* 6(7), e22242.
- Choudhary, O.P., Priyanka, P.C., Doley, P.J., Kalita, A. and Keneisenuo, A. 2021. A Morphological Study on the Skull of Dromedary (*Camelus dromedarius*). *Explor. Anim. Med. Res.* 11(1), 135–139.
- Choudhary, O.P. and Singh, I. 2016. Morphological and radiographic studies on the skull of Indian blackbuck (*Antilope cervicapra*). *Int. J. Morphol.* 34(2), 788–796.
- Cohen, M.M. Jr. 1993. Sutural biology and the correlates of craniosynostosis. *Am. J. Med. Genet.* 47(5), 581–616.
- De Pollack, C., Renier, D., Hott, M. and Marie, P.J. 1996. Increased bone formation and osteoblastic cell phenotype in premature cranial suture ossification (craniosynostosis). *J. Bone Miner. Res.* 11(3), 401–407.
- Di Ieva, A., Bruner, E., Davidson, J., Pisano, P., Haider, T., Stone, S.S., Cusimano, M.D., Tschabitscher, M. and Grizzi, F. 2013. Cranial sutures: a multidisciplinary review. *Childs Nerv. Syst.* 29(6), 893–905.
- Dyce, K.M., Sack, W.O. and Wensing, C.J.G. 2010. *Textbook of veterinary anatomy*, 4th ed. Beijing, China: Saunders Elsevier.
- El-Allali, K., Achaaban, M.R. and Ousassat, M. 2017. Anatomy of the dromedary head skeleton revisited. *J. Morphol. Sci.* 34(2), 73–88.
- Evans, H.E. 1993. *Miller's anatomy of dog*, 3rd ed. Philadelphia, PA: Saunders, pp: 148–157.
- Getty, R. 1975. *Sisson and Grossman's: anatomy of the domestic animals*, 5th ed.. Philadelphia, PA: W.B. Saunders.
- Gibelli, D., Cellina, M., Gibelli, S., Cappella, A., Oliva, A.G., Termine, G. and Sforza, C. 2018. Anatomical variants of ethmoid bone on multidetector CT. *Surg. Radiol. Anat.* 40(11), 1301–1311.
- Jones, M.E.H., Curtis, N., Fagan, M.J., O'Higgins, P. and Evans, S.E. 2011. Hard tissue anatomy of the cranial joints in *Sphenodon* (*Rhynchocephalia*): sutures, kinesis, and skull mechanics. *Palaeontol. Electron.* 14(2), 17A.
- Kalita, P.C., Debroy, S., Choudhary, O.P., Kalita, A. and Doley, P.J. 2020. Morphological and morphometrical studies on the skull of binturong (*Arctictis binturong*). *J. Anim. Res.* 10(2), 309–314.
- Klein, L., Furst, A.E., Del Chicca, F., Theiss, F. and Jackson, M.A. 2019. Clinical, radiographic and histologic findings, therapy and outcome in 15 horses with suture periostitis: a case series. *Pferdeheilkunde – Equine Med.* 35(3), 204–210.
- Lindsay, A., Fürst, A. and Jackson, M. 2021. A histological evaluation of facial suture lines in six horses aged 1 day to 9 years. Posted at the Zurich Open Repository and Archive, University of Zurich. ZORA. Available via <https://doi.org/10.5167/uzh-202772>.
- Olopade, J.O. 2006. Morphometric analysis of the skulls of three breeds of goats in Nigeria, Ph.D. Thesis, Department of Veterinary Anatomy, University of Ibadan, Nigeria.
- Miller, M.S., Christensen, G.C. and Evans, H.E. 1975. *The skeletal system, skull. From: anatomy of the dog*, 1st ed. Philadelphia, PA: W.B. Saunders Co.
- Nickel, R., Schummer, A. and Seiferli, E. 1986. *Anatomy of the domestic animals.*, Berlin, Germany: Verlag Paul Parey.
- Persson, M. 1995. The role of sutures in normal and abnormal craniofacial growth. *Acta. Odontol. Scand.* 53(3), 152–161.
- Reda, M. 2019. Anatomical and Radiographic Study on the Skull and Mandible of the African Lion (*Panthera leo*). *J. Morphol. Sci.* 36, 174–181.
- Rafferty, K.L. and Herring, S.W. 1999. Craniofacial sutures: morphology, growth, and in vivo masticatory strains. *J. Morphol.* 242(2), 167–179.
- Raghavan, D. 1964. *Anatomy of Ox*, 1st ed. New Delhi, India: Indian Council of Agricultural Research.
- Ramadan, R.O. 1994. *Surgery and radiology of the dromedary camel*, 1st ed. Al Khobar, Kingdom of Saudi Arabia: Al-Jawad Printing Press.
- Rice, D.P. 2008. Developmental anatomy of craniofacial sutures. *Front. Oral Biol.* 12, 1–21.
- Shahid, R.U. and Kausar, R. 2005. Comparative Gross Anatomical Studies of the Skull of One-Humped Camel (*Camelus dromedarius*). *Pakistan Vet. J.* 25(4), 205–207.
- Smuts, M.W. and Bezuidenhout, A. J. 1987. *Anatomy of the dromedary* Oxford, UK : Clarendon Press.
- Standring, A. 2008. *Gray's anatomy. the anatomical basis of clinical practice*, 40th ed. London, UK: Churchill Livingstone Elsevier, pp: 409–421.
- Sun, Z., Leem E. and Herring, S.W. 2004. Cranial sutures and bones: growth and fusion in relation to masticatory strain. *Anat. Rec. A Discov. Mol. Cell Evol. Biol.* 276(2), 150–161.
- Yahaya, A., Olopade, J.O., Kwari, H.D. and Wiam, I.M. 2012. Osteometry of the skull of one-humped camels. Part I: immature animals. *Ital. J. Anat. Embryol.* 117(1), 23–33.
- Yahaya, A., Olopade, J.O. and Kwari, H.D. 2014. Anatomical Study of the Variations of the Facial bones in Skull of the Camel (*Camelus*

- 
- Dromedaries) in Nigeria. *Nigerian Vet. J.* 35(3), 1053–1059.
- Yi, S.J., Kim, J.S. and Lee, H.S. 2001. Comparative anatomical study on fissura nasolacrimalis and nasomaxillaris in skull of the Korean native goat (*Capra hircus*). *Anat. Histol. Embryol.* 30(3), 133–134.
- Yi, S.J., Lee, H.S., Kim, K.S. and Kang, T.C. 1998. The comparative anatomical study of the parietal region of the skull of the Korean native goat (*Capra hircus*). *Anat. Histol. Embryol.* 27(5), 323–325.
- Wilson, R.T. 1984. *The camel*. London & New York: Longman, pp: 60–65.