

Research article

Radiological usual interstitial pneumonia pattern is associated with two-year mortality in patients with idiopathic pulmonary fibrosis

Ignacio Gayá García-Manso ^{a,*},¹, Juan Arenas Jiménez ^{b,1}, Luis Hernández Blasco ^{a,c}, Elena García Garrigós ^b, Ester Nofuentes Pérez ^d, Marina Sirera Matilla ^b, Sandra Ruiz Alcaraz ^e, Raquel García Sevilla ^a

^a Department of Pulmonology, Dr. Balmis General University Hospital, ISABIAL, Alicante, Spain

^b Department of Radiology, Dr. Balmis General University Hospital, ISABIAL, Alicante, Spain

^c Department of Clinical Medicine. UMH. Alicante, Spain

^d Department of Pulmonology, Vinalopó University Hospital, Elche, ISABIAL, Alicante, Spain

^e Department of Pulmonology, Elche General University Hospital, Elche, ISABIAL, Alicante, Spain

ARTICLE INFO

Keywords:

Idiopathic pulmonary fibrosis
Interstitial lung diseases
Radiological pattern
Usual interstitial pneumonia
Survival

ABSTRACT

Introduction: The new diagnostic guidelines for idiopathic pulmonary fibrosis (IPF) did not rule out the possibility of combining the radiological patterns of usual interstitial pneumonia (UIP) and probable UIP, given the similar management and diagnostic capacity. However, the prognostic implications of these patterns have not been fully elucidated, with different studies showing heterogeneous results. We applied the new criteria to a retrospective series of patients with IPF, assessing survival based on radiological patterns, findings, and their extension.

Methods: Two thoracic radiologists reviewed high-resolution computed tomography images taken at diagnosis in 146 patients with IPF, describing the radiological findings and patterns. The association of each radiological finding and radiological patterns with two-year mortality was analysed.

Results: The two-year mortality rate was 40.2% in IPF patients with an UIP radiological pattern versus 7.1% in those with probable UIP. Compared to the UIP pattern, probable UIP was protective against mortality, even after adjusting for age, sex, pulmonary function, and extent of fibrosis (hazard ratio (HR) 0.23, 95% confidence interval (CI) 0.06–0.99). Receiving antifibrotic treatment was also a protective factor (HR 0.51, 95%CI 0.27–0.98). Honeycombing (HR 3.62, 95%CI 1.27–10.32), an acute exacerbation pattern (HR 4.07, 95%CI 1.84–8.96), and the overall extent of fibrosis (HR 1.04, 95%CI 1.02–1.06) were predictors of mortality.

Conclusions: In our series, two-year mortality was higher in patients with IPF who presented a radiological pattern of UIP versus probable UIP on the initial scan. Honeycombing, an acute exacerbation pattern, and a greater overall extent of fibrosis were also predictors of increased

* Corresponding author. Pintor Baeza, 11, 03010, Alicante, Spain.

E-mail addresses: nachogaya@gmail.com (I. Gayá García-Manso), j.arenasjimenez@gmail.com (J. Arenas Jiménez), lhernandez@umh.es (L. Hernández Blasco), piolelena@hotmail.com (E. García Garrigós), e.nofuentesperez@gmail.com (E. Nofuentes Pérez), marinasirera@gmail.com (M. Sirera Matilla), ruizalcarazsandra@gmail.com (S. Ruiz Alcaraz), raquelgsevila@gmail.com (R. García Sevilla).

¹ **Joint first authorship:** Ignacio Gayá García-Manso and Juan Arenas Jiménez have contributed equally.

mortality. The prognostic differences between the radiological pattern of UIP and probable UIP in our series would support maintaining them as two differentiated patterns.

1. Introduction

Idiopathic pulmonary fibrosis (IPF) is a chronic, progressive, fibrosing interstitial pneumonia of unknown aetiology, mainly affecting older adults. Involvement is limited to the lung, and it is correlated with the radiological and histological pattern of usual interstitial pneumonia (UIP) [1,2]. There are some genetic factors known to be associated with IPF, which may also be related to different radiological patterns [3]. Compared with other diffuse interstitial lung diseases, IPF has a poorer prognosis, with a median survival of 2–5 years from diagnosis [1,4], although studies during the last decade suggest that the development of new drugs for specifically treating this disease have improved survival [5,6].

Several authors have studied the relationship between different radiological findings in high-resolution computed tomography (HRCT) and mortality in patients with IPF, finding some solid evidence on the influence of honeycombing [7–9] and its extension [10], the severity of traction bronchiectasis [11–13], and the overall extent of fibrosis [14–17] on disease prognosis. However, research on whether the different radiological patterns condition the patient's prognosis has not generated definitive conclusions.

The latest update of the clinical practice guidelines on diagnosis and treatment of IPF, published in 2022 by the American Thoracic Society (ATS), European Respiratory Society (ERS), Japanese Respiratory Society (JRS), and Latin American Thoracic Society (ALAT) [18], discusses the possibility of combining the radiological patterns of UIP and probable UIP, based on the fact that they are handled quite similarly, since histological confirmation is generally not necessary in either. However, one of the main arguments for finally deciding to maintain the four-pattern classification is that some studies show better survival in patients with a radiological pattern of probable UIP compared to those with a UIP pattern, even while other published studies have not observed differences.

An important limitation when analysing the evidence on differences in prognosis according to radiological patterns is that much of the literature published in this regard used the now outdated three-pattern classification (“UIP,” “possible UIP,” “inconsistent with UIP”) from the 2011 international diagnostic guidelines [4]. In 2018, a new version of the international guidelines [19] and a consensus document by the Fleischner Society [20] were published, dividing the radiological patterns into four groups: “UIP,” “probable UIP,” “indeterminate for UIP,” and “alternative diagnosis” [19] or “CT features most consistent with non-IPF diagnosis” [20] (hereafter “non-UIP”). This classification was maintained in the latest guidelines published in 2022 [18]. The literature based on this four-pattern classification is scarce, and with contradictory results in the different series, representing one of the points of debate in the latest update of the guidelines [18].

Therefore, in our study we decided to retrospectively analyse the HRCT images at diagnosis in patients with IPF applying the new four-pattern classification of the latest guidelines, with the aim of analysing whether there are differences in survival depending on the new radiological patterns or the different radiological findings and their extent.

2. Methods

The ethics committee for drug research of Alicante Health Department- General University Hospital Dr. Balmis approved the study (Ref. CEim:PI2019/028). It was carried out in accordance with the principles of the Declaration of Helsinki. The requirement for informed consent was waived given the retrospective nature of the study and the lack of intervention.

2.1. Study population

We included all patients diagnosed with IPF at our centre, a tertiary referral hospital, from 2010 to 2019, and who completed at least two years of follow-up or died during that period of time. The diagnosis of IPF was established following current international guidelines [19], integrating clinical, radiological, and pathological data. In light of the retrospective nature of the study and the availability of follow-up data, information on the disease course was reviewed to determine the definitive clinical diagnosis. The multidisciplinary board in our centre, composed of pulmonologists, radiologists, pathologists, and rheumatologists, performed the final evaluation. The survival status and causes of death of the 146 patients from diagnosis to the end of two-year follow-up were obtained from electronic medical records. Patients receiving a lung transplant during the first two years of follow-up were excluded.

2.2. Radiological assessment

The chest HRCT images taken closest to the diagnosis were reviewed. These were acquired using different equipment from various centres, thus presenting a wide range of technical features. The minimum technical characteristics were slices with a thickness of 1.5 mm or less, with a lung window and a high-resolution spatial reconstruction filter, and volumetric acquisition without spacing between reconstructions. If there were other phases, only scans in the inspiratory phase taken in the supine position were read.

HRCT images were reviewed by two of three thoracic radiologists, JAJ, EGG, and MSM, with 25, 12, and 5 years of experience, respectively. The reproducibility in the evaluation of CT images among these readers has already been demonstrated with the good correlation reported in previous publications [21]. The radiologists reviewed the images independently and blindly, without knowing the diagnoses or other patient data. A multiplanar assessment was performed using a PACS station, with access to images in coronal

and sagittal planes to facilitate description and quantification. The interpretation of the radiological findings was performed according to the ATS/ERS/JRS/ALAT guidelines [19] and the glossary of thoracic radiology terms of the Fleischner Society [22]. Chest HRCT images were evaluated describing the presence or absence of reticulation, traction bronchiectasis, honeycombing, ground-glass opacities, mosaic attenuation, and emphysema. The overall extent of the disease was quantified as a percentage in 5% intervals. For traction bronchiectasis, involvement was graded by adapting the Hida et al. [23] score: minimal/doubtful (subtle bronchial dilations limited to the most peripheral subpleural lung, without obvious bronchiectasis), mild (obvious small bronchiectasis), moderate (mild to severe), and severe (marked bronchi dilation). The degrees of honeycombing were: minimal/doubtful (doubts about its presence), mild (but without doubts about its presence), moderate, and severe (predominant finding). To assess the radiological patterns, the four-pattern classification published in the ATS/ERS/JRS/ALAT guidelines [19] was used. A radiological pattern of acute exacerbation (AE) was defined as the existence of multiple patchy areas of ground glass appearing in otherwise normal lung without signs of fibrosis, in a CT scan that showed fibrotic changes with parenchymal distortion, traction bronchiectasis and/or honeycombing elsewhere in the lungs [24,25] (Fig. 1 (A-D)). Discrepancies in the qualitative variables were resolved by consensus with the participation of the third reader. The discrepancies in the quantification were resolved by obtaining the average values between observers.

2.3. Statistical analysis

Descriptive statistics of baseline characteristics and radiological features were expressed as absolute and relative frequencies for categorical variables, and as median and interquartile range or as mean and standard deviation (depending on the normality of the distribution) for quantitative variables. Comparisons according to radiological patterns were performed using the chi square test for categorical variables, the Kruskal-Wallis *U* test for nonparametric quantitative variables, or the ANOVA test for parametric variables. A Cox proportional hazards regression model was fitted to identify risk factors for mortality. Subsequently, a multivariate analysis was performed for the relevant variables that showed significant differences in the univariate analysis, adjusting for age, sex, pulmonary function, and global extent of fibrosis. Kaplan-Meier curves were used for survival analysis, and the log-rank test was used to determine

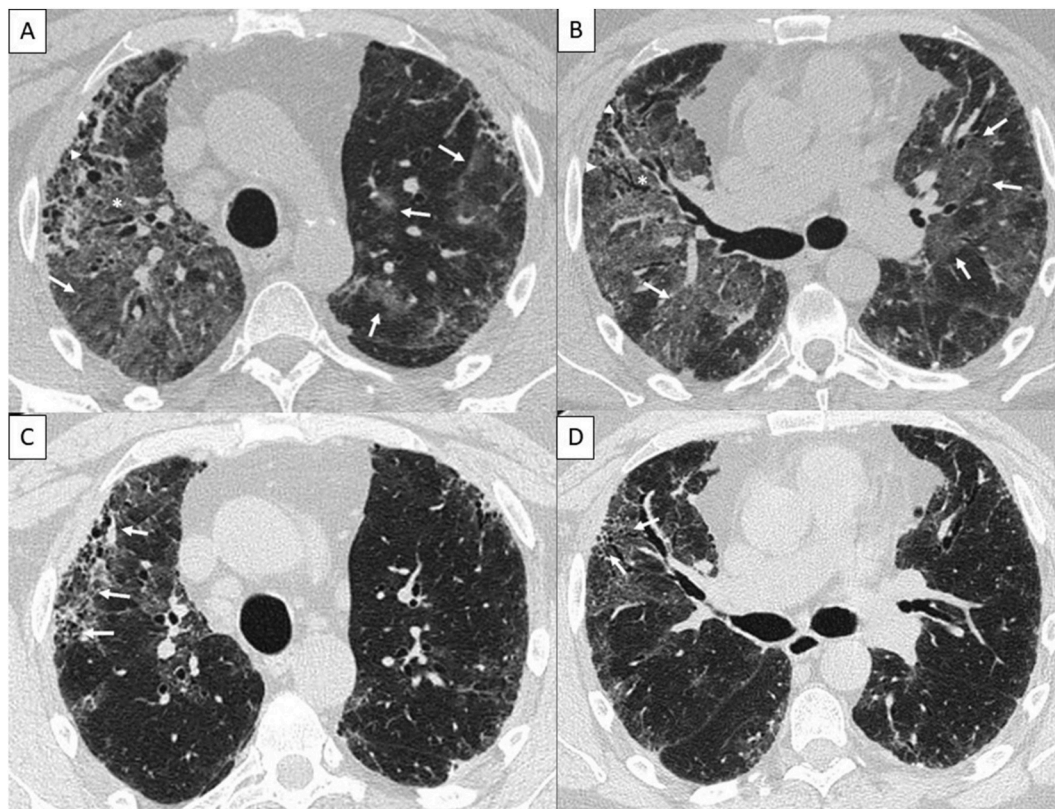


Fig. 1. (A–D). Acute exacerbation pattern. Initial HRCT scan (A,B) and follow-up (C,D) in a 52-year-old man who experienced shortness of breath for 3 weeks with no previous respiratory symptoms. The initial HRCT scan (A,B) showed ground glass opacities in non-fibrotic lung (arrows) together with fibrotic changes manifested by traction bronchiectasis (arrowheads). Some ground glass is apparent in fibrotic areas (asterisk). Four weeks later (after receiving treatment with methylprednisolone boluses and subsequent descending regimen), another HRCT scan (C,D) showed improvement in ground glass opacities and progression of fibrosis with traction bronchiectasis (arrows). A video-assisted lung biopsy confirmed a histological usual interstitial pneumonia. The multidisciplinary team concluded that the patient had an idiopathic pulmonary fibrosis with acute exacerbation as debut.

statistical significance. P values of less than 0.05 were considered statistically significant. All analyses were performed using IBM SPSS Statistics for Windows, version 25.

3. Results

3.1. Demographics characteristics

Fig. 2 shows the flow chart for the patient selection process, which resulted in a sample of 146. The mean age at diagnosis was 71.2 (SD 10.6) years; most patients were white (n = 142, 97.3%), were men (n = 110, 75.3%), and had a history of smoking (n = 97, 66.4%). Just 10 (6.8%) had a family history of diffuse interstitial lung disease. On physical examination, crackles were observed in 122 (83.6%) patients and clubbing in 30 (20.5%). Regarding the radiological patterns, the most frequent was the UIP pattern (82 patients, 56.2%), followed by probable UIP (28, 19.2%), indeterminate for UIP (19, 13.0%) and non-UIP (17, 11.6%). Diagnosis required surgical lung biopsy in 43 (29.5%) patients.

3.2. Comparison according to radiological patterns

Tables 1 and 2 show the sample's baseline characteristics and radiological findings according to radiological patterns. Patients with indeterminate and non-UIP patterns were significantly younger. There were no differences in the frequency of antifibrotic treatment or in the acute exacerbation pattern between groups. Significant differences were found in lung function, with patients with a probable UIP pattern presenting better FVC and DLCO at diagnosis. Patients with UIP pattern had less global extension of fibrosis. Of note, although honeycombing was described in 4 of the 28 patients with a probable UIP pattern, in all of them it was graded as minimal/doubtful, so that it was not considered by the radiologist when classifying the radiological pattern. The presence of some degree of mosaic attenuation was common in all groups, but given the limited extent, it was not considered significant, nor did it modify the radiological pattern.

3.3. Predictors of mortality

Tables 3 and 4 show the results of the Cox regression for two-year survival according to baseline clinical characteristics and radiological findings and patterns, respectively. The most relevant result was the association of the UIP pattern with higher two-year mortality compared to the probable UIP pattern (HR 0.23, 95% (CI) 0.06–0.99). The presence of honeycombing (HR 3.62, 95%CI 1.27–10.32), the AE pattern (HR 4.07, 95%CI 1.84–8.96), and the greater overall extent of fibrosis (HR 1.04, 95%CI 1.02–1.06) were also predictors of mortality. Antifibrotic treatment (hazard ratio (HR) 0.51, 95% confidence interval (CI) 0.27–0.98), better lung function, and less severe bronchiectasis were protective factors. All significant differences remained so after adjusting the analysis for age, sex, pulmonary function, and global extent of fibrosis.

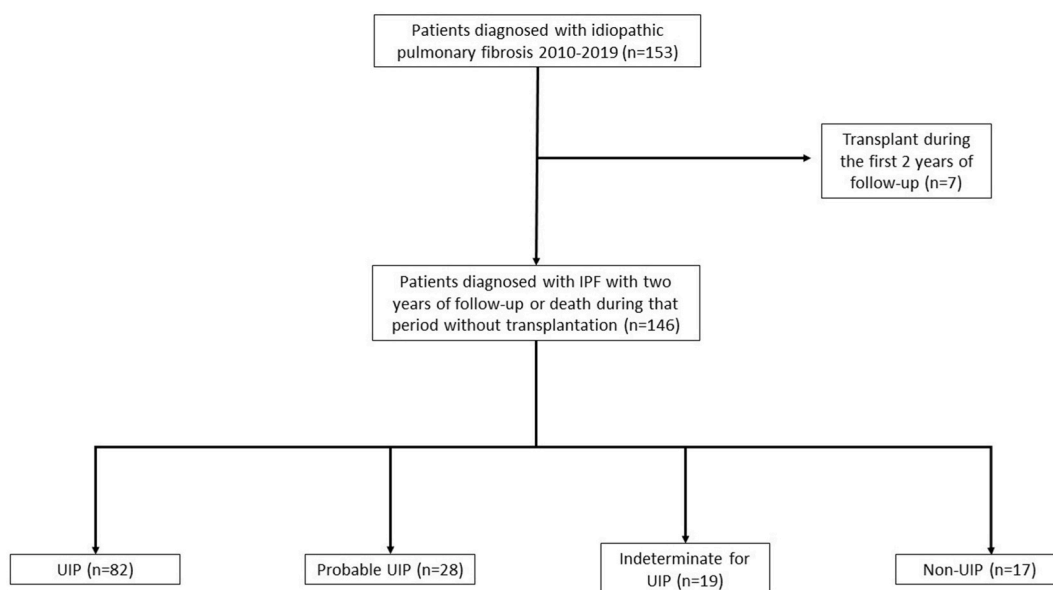


Fig. 2. Patient flow chart. Description of the patients included and excluded in the study. IPF: idiopathic interstitial pneumonia. UIP: usual interstitial pneumonia.

Table 1
Baseline patient characteristics, according to radiological pattern.

	UIP (n = 82)	Probable UIP (n = 28)	Indeterminate for UIP (n = 19)	Non-UIP (n = 17)	p value
Demographics					
Age at diagnosis, years	73.6 ± 9.0	73.0 ± 7.7	65.8 ± 14.3	62.5 ± 11.0	<0.001
Male sex	66 (80.5)	21 (75.0)	10 (52.6)	13 (76.5)	0.091
Ever smoked	60 (73.2)	19 (67.9)	9 (47.4)	9 (52.9)	0.103
Pack-years	31.0 (13.8–50.5)	30.0 (15.0–32.0)	45.0 (18.5–52.5)	35.0 (19.0–51.5)	0.756
Duration of symptoms until diagnosis, months	6.0 (2.0–12.0)	6.0 (2.0–8.0)	8.0 (2.0–24.0)	7.0 (1.5–18.0)	0.175
Dyspnoea (mMRC)					
0	17 (21.3)	9 (32.1)	1 (5.6)	0 (0.0)	–
1	12 (15.0)	8 (28.6)	4 (22.2)	4 (23.5)	
2	34 (42.5)	10 (35.7)	9 (50.0)	9 (52.9)	
3	15 (18.8)	1 (3.6)	4 (22.2)	4 (23.5)	
4	2 (2.5)	0 (0.0)	0 (0.0)	0 (0.0)	
Cough	58 (72.5)	10 (35.7)	15 (83.3)	8 (47.1)	0.001
Antifibrotic treatment	42 (51.2)	16 (57.1)	12 (63.2)	7 (41.2)	0.566
Pulmonary function testing					
FVC, ml	2318.0 ± 821.2	2577.1 ± 784.7	1920.0 ± 594.7	2082.0 ± 601.4	0.036
FVC, %	74.8 ± 18.7	89.3 ± 23.7	68.5 ± 16.6	61.3 ± 16.3	<0.001
DLCO, %	50.3 ± 19.7	66.5 ± 19.2	46.5 ± 22.0	44.1 ± 13.1	0.001
TLC, ml	4198.5 ± 1012.5	4091.0 ± 1273.6	3214.0 ± 722.0	3826.7 ± 1019.7	0.064
TLC, %	74.5 (64.0–85.3)	69.0 (56.0–82.0)	57.0 (51.5–71.5)	69.0 (63.0–84.0)	0.175
6MWT distance, m	431.0 (337.8–480.0)	440.0 (378.0–480.0)	454.0 (295.0–540.0)	380.0 (289.5–448.0)	0.102

Data presented as n (%) or median (interquartile range). In bold statistically significant differences. mMRC: modified Medical Research Council. FVC: forced vital capacity. DLCO: diffusing capacity of the lung for carbon monoxide. TLC: total lung capacity. 6MWT: 6-min walk test.

Table 2
Radiological features according to radiological pattern.

	UIP (n = 82)	Probable UIP (n = 28)	Indeterminate for UIP (n = 19)	Non-UIP (n = 17)	p value
Reticulation	82 (100.0)	28 (100.0)	19 (100.0)	16 (94.1)	0.054
Traction bronchiectasis	82 (100.0)	28 (100.0)	19 (100.0)	16 (94.1)	0.054
Extent of traction bronchiectasis					
Minimal/doubtful	1 (1.2)	2 (7.1)	0 (0.0)	0 (0.0)	
Mild	3 (3.7)	14 (50.0)	2 (10.5)	7 (43.8)	
Moderate	18 (22.0)	10 (35.7)	8 (42.1)	5 (31.3)	
Severe	60 (73.2)	2 (7.1)	9 (47.4)	4 (25.0)	
Honeycombing	81 (98.9)	4 (14.3)	16 (84.2)	3 (17.6)	<0.001
Extent of honeycombing					
Minimal/doubtful	15 (18.5)	4 (100.0)	7 (43.8)	1 (33.3)	
Mild	33 (40.7)	0 (0.0)	3 (18.8)	2 (66.7)	
Moderate	29 (35.8)	0 (0.0)	5 (31.3)	0 (0.0)	
Severe	4 (4.9)	0 (0.0)	1 (6.3)	0 (0.0)	
Ground-glass	52 (63.4)	14 (50.0)	17 (89.5)	16 (94.1)	0.003
Acute exacerbation pattern	7 (8.5)	1 (3.6)	2 (10.5)	2 (11.8)	0.746
Mosaic attenuation	62 (75.6)	18 (64.3)	18 (94.7)	14 (82.4)	0.101
Emphysema	35 (42.7)	2 (7.1)	7 (36.8)	4 (23.5)	0.005
Global extent, %	55.0 (40.0–60.0)	60.0 (40.0–62.5)	75.0 (60.0–80.0)	70.0 (65.0–70.0)	<0.001

Data presented as n (%) or median (interquartile range). In bold statistically significant differences. UIP: usual interstitial pneumonia.

3.4. Two-year survival

The survival curves showed significant differences depending on the radiological patterns, the presence of honeycombing, onset with an AE pattern, and antifibrotic treatment (Fig. 3 (A-D)). Patients with a pattern of probable UIP, indeterminate for UIP, and non-UIP presented a two-year mortality of 7.1%, 26.3%, and 17.6%, respectively. Prognosis was worse in patients with a UIP pattern, with mortality at two years standing at 40.2% (p = 0.006). Honeycombing was associated with a higher two-year mortality rate (37.5% vs. 9.5%, p < 0.001), as was debut with an AE pattern (91.7% vs. 8.3%, p < 0.001). Patients taking antifibrotic treatment presented a lower two-year mortality rate (20.8% vs. 39.1%, p = 0.015).

Table 3

Baseline prognostic factors for two-year mortality, assessed using Cox's proportional hazards model.

	Univariable		Adjusted for age and sex, FVC (%) and global extent	
	HR (95% CI)	p value	HR (95% CI)	p value
Demographics				
Age at diagnosis, years	1.03 (0.99–1.06)	0.127		
Male sex	1.44 (0.67–3.10)	0.354		
Ever smoked	1.14 (0.59–2.18)	0.698		
Pack-years	1.00 (0.99–1.01)	0.925		
Duration of symptoms until diagnosis, months	0.96 (0.91–1.01)	0.102		
Dyspnoea (mMRC)				
0	933.09(0.00–5.49*10 ⁶⁸)	0.929		
1	1829.58 (0.00–1.07*10 ⁶⁹)	0.923		
2	5275.09 (0.00–3.09*10 ⁶⁹)	0.912		
3	10323.22 (0.00–6.04*10 ⁶⁹)	0.905		
4	Ref			
Cough	1.89 (0.95–3.74)	0.070		
Antifibrotic treatment	0.45 (0.24–0.83)	0.011	0.51 (0.27–0.98)	0.043
Pulmonary function testing				
FVC, ml	1.00 (1.00–1.00)	0.041		
FVC, %	0.98 (0.96–0.99)	0.003		
DLCO, %	0.96 (0.94–0.99)	0.003		
TLC, ml	1.00 (1.00–1.00)	0.882		
TLC, %	0.99 (0.96–1.01)	0.297		
6MWT distance, m	1.00 (0.99–1.00)	0.007		

Data presented as n (%) or median (interquartile range). In bold statistically significant differences. HR: Hazard ratio. CI: confidence interval. mMRC: modified Medical Research Council. FVC: forced vital capacity. DLCO: diffusing capacity of the lung for carbon monoxide. TLC: total lung capacity. 6MWT: 6-min walk test.

Table 4

Prognostic radiological features and patterns for two-year mortality, assessed using Cox's proportional hazards model.

	Univariable		Adjusted for age and sex, FVC (%) and global extent	
	HR (95% CI)	p value	HR (95% CI)	p value
Reticulation	20.34 (0.00–6.27*10 ⁷)	0.693		
Traction bronchiectasis	20.34 (0.00–6.27*10 ⁷)	0.693		
Extent of traction bronchiectasis				
Minimal/doubtful	0.63 (0.09–4.63)	0.653	4.09 (0.41–41.17)	0.232
Mild	0.06 (0.01–0.46)	0.007	0.13 (0.02–0.98)	0.048
Moderate	0.26 (0.11–0.61)	0.002	0.34 (0.13–0.89)	0.029
Severe	Ref		Ref	
Honeycombing	4.79 (1.71–13.41)	0.003	3.62 (1.27–10.32)	0.016
Extent of honeycombing				
Minimal/doubtful	17050.05 (0.00–5.47*10 ⁸⁹)	0.923		
Mild	25663.43 (0.00–8.23*10 ⁸⁹)	0.919		
Moderate	32072.07 (0.00–1.03*10 ⁹⁰)	0.918		
Severe	Ref			
Ground-glass	1.97 (0.95–4.11)	0.070		
Acute exacerbation pattern	7.42 (3.71–14.83)	<0.001	4.07 (1.84–8.96)	0.001
Mosaic attenuation	1.72 (0.76–3.86)	0.192		
Emphysema	1.26 (0.68–2.34)	0.460		
Radiological pattern				
UIP	Ref		Ref	
Probable UIP	0.14 (0.03–0.59)	0.007	0.23 (0.06–0.99)	0.048
Indeterminate for UIP	0.62 (0.24–1.58)	0.313	0.42 (0.12–1.47)	0.173
Non-UIP	0.38 (0.12–1.23)	0.107	0.34 (0.10–1.16)	0.084
Global extent, %	1.04 (1.02–1.06)	<0.001		

Data presented as n (%) or median (interquartile range). In bold statistically significant differences. UIP: usual interstitial pneumonia.

3.5. Cause of death

Of the 43 deaths over two-year follow-up, 37 (84.0%) had respiratory causes, of which 16 (37.2%) were due to IPF progression, 12 (27.9%) to acute exacerbation, 6 (14.0%) to lung cancer, and 3 (7.0%) to respiratory infections. The six patients who died from non-respiratory causes included two from extrathoracic neoplasms (colon and maxillofacial), and one patient each from abdominal sepsis, arterial ischemia, liver cirrhosis, and kidney failure.

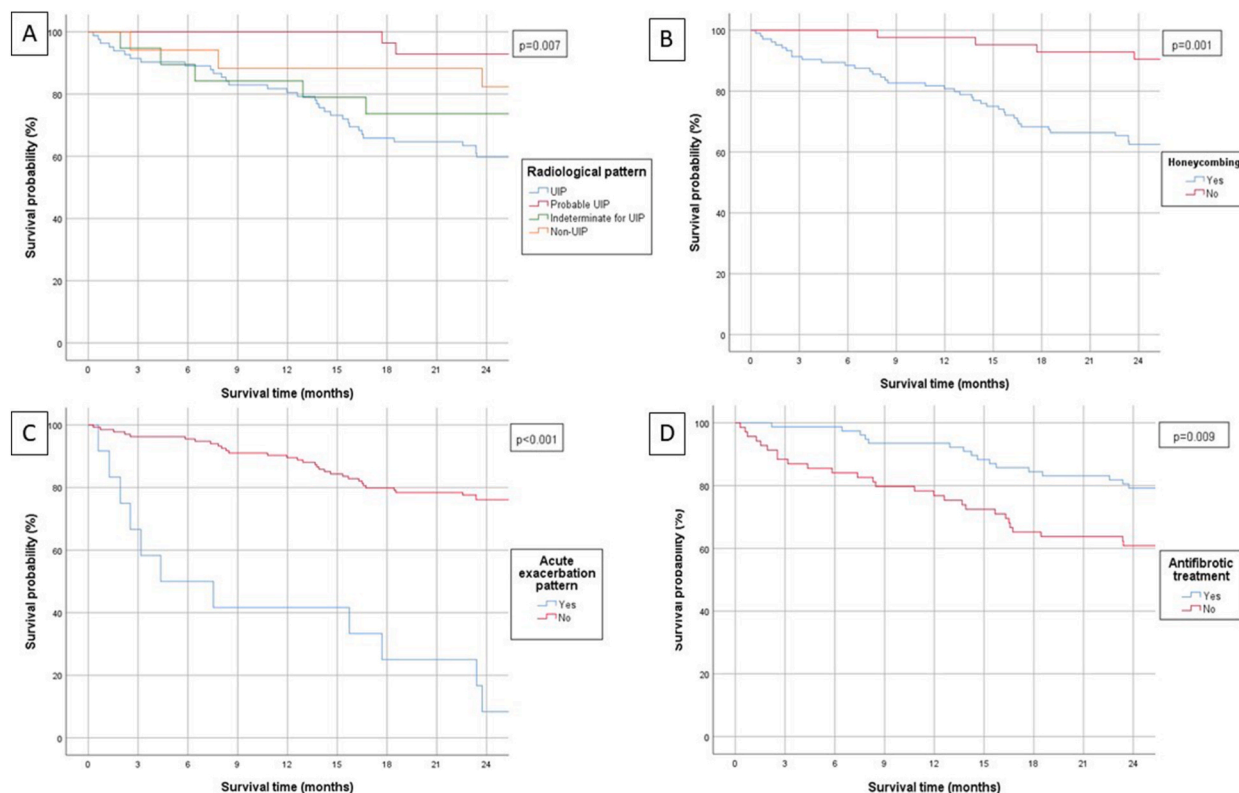


Fig. 3. Comparison of the survival curves according to (A) radiological patterns, (B) presence of honeycombing, (C) acute exacerbation pattern, and (D) antifibrotic treatment. UIP: usual interstitial pneumonia.

4. Discussion

This retrospective study in 146 patients with IPF analysed the influence of the radiological patterns described in the ATS/ERS/JRS/ALAT guidelines [4], the different radiological findings, and their severity on mortality at two years. The main objective was to analyse whether there are differences in survival based on these new radiological patterns. The most relevant result was that patients with a radiological pattern of probable UIP presented significantly lower mortality at two years than those with UIP pattern, and that the presence of honeycombing, the AE pattern, and the greater overall extent of fibrosis on the diagnostic HRCT were predictors of mortality.

The evolution of diagnostic guidelines for IPF in recent years [1,4,18,19] reflects the attempt to optimize the diagnosis of UIP without the need for lung biopsy, relegating the prognostic differences between the different patterns to a secondary concern. In that line, the possibility of combining the UIP and probable UIP patterns has recently been discussed [18], since both the management and the positive predictive value for the diagnosis of histological UIP are very similar. However, one aspect that remains to be elucidated is whether there are differences in prognosis according to radiological patterns, and our results can be contextualized around this question. Recent studies have shown heterogeneous results, but comparisons between the various series are hindered by differences in patient populations, diagnoses, and characteristics. Moreover, the radiological criteria used, and the endpoints analysed vary, which could explain the disparity of the results. Table 5 summarizes the results of the main published studies.

Since the publication of the 2018 international guidelines [19], which differentiated between four different radiological patterns, there have been few studies. In our cohort, 40.2% of the patients with a UIP pattern died within two years, compared to just 7.1% of those with a probable UIP pattern. These differences were confirmed in the analysis adjusting for age, sex, pulmonary function, and global extent of fibrosis as well as in the survival curves, but no significant differences were found compared to the indeterminate pattern, as in other series [26,27], or to the non-UIP pattern. Choe et al. [26] demonstrated a better prognosis with an indeterminate pattern for UIP in a cohort including patients diagnosed with IPF, idiopathic non-specific interstitial pneumonia, and chronic hypersensitivity pneumonitis; these results were also consistent when analysing only the IPF subgroup. Similar results were published by Kwon et al. [27] in a series of patients with IPF and lung biopsy, with better survival in patients with an indeterminate pattern compared to the rest. However, these results are difficult to extrapolate to the present: the sample was older, diagnosed between 1995 and 2016, and generally received the standard treatment at the time—corticosteroids and immunosuppressants—while a low proportion were treated with antifibrotic drugs. In any case, the authors did not find differences in prognosis between patients with a UIP versus probable UIP pattern, unlike Fukihara et al. [28], who despite finding differences in survival between these two patterns in

Table 5

Characteristics of studies of survival according to radiological patterns.

Author	Year of publication	Radiological criteria ^a	Study population	Significant differences? Result
Gayá et al.	2023	2018	IPF	YES. Higher mortality at 2 years in UIP pattern vs probable UIP
Choe et al. [26]	2021	2018	IPF, NSIP and chronic HP	YES. Better survival in indeterminate for UIP pattern, considering all diagnoses, but also for IPF subgroup
Kwon et al. [27]	2020	2018	IPF with lung biopsy	YES. Better prognosis in indeterminate for UIP pattern compared to other patterns
Fukihara et al. [28]	2020	2018	IIP (IPF) with UIP and probable UIP patterns	YES. Better survival in probable UIP pattern in patients with IIP NO differences in analysis of IPF subgroup
Diridollou et al. [29]	2020	2018	Possible UIP pattern, reclassified as probable UIP or indeterminate for UIP	YES. Worse prognosis in probably UIP compared to indeterminate pattern (composite endpoint: death, transplant, admission, or $\geq 10\%$ fall in FVC)
Mononen et al. [12]	2021	2011	IPF	YES. Better survival with possible UIP vs UIP pattern
Salisbury et al. [30]	2017	2011	IPF with histological UIP	YES. Better survival with possible UIP vs UIP pattern
Arcadu et al. [31]	2017	2011	IPF (with and without lung biopsy)	NO differences
Romei et al. [13]	2015	2011	IIP	YES. Higher mortality with UIP vs possible UIP and inconsistent with UIP patterns
Le Rouzic et al. [32]	2015	2011	IPF	NO differences
Lee et al. [33]	2015	2011	IIP, UIP vs possible UIP	NO differences. Kaplan-Meier curves tend to separate
Novelli et al. [34]	2014	2011	IPF	NO differences. Kaplan-Meier curves tend to separate
Sumikawa et al. [35]	2014	2011	IPF with histologically confirmed UIP	NO differences

^a Radiological criteria 2018 [19], radiological criteria 2011 [4]. IPF: idiopathic pulmonary fibrosis. UIP: usual interstitial pneumonia. NSIP: non-specific interstitial pneumonia. HP: hypersensitivity pneumonitis. IIP: interstitial idiopathic pneumonia. FVC: forced vital capacity.

patients with idiopathic interstitial pneumonia (IIP), did not find them when analysing only the subgroup of patients diagnosed by the multidisciplinary committee with IPF. Diridollou et al. [29] reclassified 89 patients with the old pattern of possible UIP as probable UIP or indeterminate UIP, observing a worse prognosis in patients with probable UIP.

Using the old pattern classification from the 2011 guidelines [4], the results are also conflicting. As described in Table 5, some groups found differences similar to those reported here, with a worse prognosis in patients with a radiological pattern of UIP compared to possible and indeterminate UIP [12,13,30], while in other studies of patients with IPF [31,32,34,35] or IIP [33], no differences were found. However, in some of these series [34,33], the Kaplan-Meier survival curves tend to diverge, suggesting that with a larger number of patients or longer follow-up time, differences could emerge. In our study, we also found significant differences in the survival curves, with a worse prognosis in patients with a UIP pattern (Fig. 3A).

Regarding the study of the different radiological findings and their relationship with prognosis, in line with the results of the correlation of the UIP pattern with mortality at two years, in our study the presence of honeycombing was associated with a worse prognosis, as shown in previous studies [36]. This occurs regardless of the known limitations of radiological evaluation of honeycombing itself [37]. Although in our study the presence of bronchiectasis was not related to mortality, as other authors have described [14], greater severity was associated with higher mortality, as shown in patients with fibrosing interstitial diseases [11] and in series of patients with interstitial lung abnormalities [38,39]. In our series, the overall extent of fibrosis was also associated with prognosis, as has already been widely reported both in patients with IPF [14–16] and in fibrotic IIP [11,40,41], as well as more recently in studies using automatic quantification through deep-learning systems [17].

In addition, we analysed the finding defined as a pattern of AE, which was very relevant in the prognosis, since it appears in up to 8.3% of patients with IPF at diagnosis, and its presence is associated with a seven-fold risk of death at two years. Although acute exacerbations are known to be a poor prognostic factor and the most frequent cause of death in patients with IPF [25,42], data on the frequency and prognostic meaning of AE at presentation are scarce. One study, using strict criteria, reported AE as the initial presentation of IPF in 3 out of 147 patients [43]. Our results highlight the need to recognize this radiological pattern [24] and make early therapeutic decisions in these patients [25,44].

The association between survival and the use of antifibrotic treatment has also been known since the approval of antifibrotic treatments [5,6], and our results corroborate that relationship, showing longer survival from the first two years of follow-up.

The main limitations of our study include the low number of patients, especially in the indeterminate and non-UIP patterns, and the retrospective application of the new criteria. Moreover, not all patients had histological confirmation, although based on current guidelines, the combination of radiological patterns and evaluation by the multidisciplinary committee represent a reliable diagnostic tool. In addition, the fact that the diagnoses were based on a combination of data from the time of diagnosis and from patient follow-up favors diagnostic precision, although it could also limit the ability to extrapolate the results to predict the prognosis at initial presentation. The differences in relevant characteristics such as age or lung function between the different radiological patterns could be a limitation when interpreting the differences found in the prognosis. However, when the multivariate analysis was performed adjusting for these variables, the differences in survival remained. Finally, the study was carried out in a single centre, and the readers also belong to the same hospital; however, it is a reference hospital, so patients referred from other hospitals were included.

5. Conclusions

In our series, patients with IPF showed higher two-year mortality in the presence of honeycombing, an acute exacerbation pattern, a greater overall extent of fibrosis, and a radiological pattern of UIP versus probable UIP (based on the new guidelines). At this time when there is debate about whether the radiological UIP and probable UIP patterns should be combined, the prognostic differences shown in our study would support maintaining them as two differentiated patterns.

Ethics approval and consent to participate

This study was approved by our centre's institutional ethics committee for research with medicines and performed in compliance with the principles of the Declaration of Helsinki. Informed consent waiver was obtained because of the retrospective nature of the study and the absence of intervention. Comité de ética para la investigación con medicamentos del departamento de salud de Alicante - Hospital General. Referencia 190111. Acta 2019/04.

Consent for publication

Not applicable.

Availability of data and materials

The datasets generated and analysed during the current study are not publicly available due to privacy notices but are available from the corresponding author on reasonable request.

Competing interests

The authors declare that they have no competing interests.

Funding

This work has received funding from two competitive grants from Fundación de Neumología de la Comunidad Valenciana and from Instituto de Investigación Sanitaria y Biomédica de Alicante (ISABIAL).

Data availability statement

Has data associated with your study been deposited into a publicly available repository?
No. Data will be made available on request.

CRediT authorship contribution statement

Ignacio Gayá García-Manso: Writing – review & editing, Writing – original draft, Project administration, Methodology, Investigation, Funding acquisition, Formal analysis, Data curation, Conceptualization. **Juan Arenas Jiménez:** Writing – review & editing, Writing – original draft, Project administration, Methodology, Investigation, Funding acquisition, Formal analysis, Data curation, Conceptualization. **Luis Hernández Blasco:** Validation, Supervision, Methodology, Investigation, Conceptualization. **Elena García Garrigós:** Validation, Methodology, Investigation. **Ester Nofuentes Pérez:** Methodology, Investigation. **Marina Sirera Matilla:** Methodology, Investigation. **Sandra Ruiz Alcaraz:** Project administration, Methodology, Investigation, Funding acquisition. **Raquel García Sevilla:** Validation, Supervision, Project administration, Methodology, Investigation, Funding acquisition, Conceptualization.

Declaration of competing interest

The authors declare that they have no known competing financial interests or personal relationships that could have appeared to influence the work reported in this paper.

Acknowledgements

Not applicable.

Appendix A. Supplementary data

Supplementary data to this article can be found online at <https://doi.org/10.1016/j.heliyon.2024.e26623>.

List of abbreviations

AE	Acute exacerbation
ALAT	Latin American Thoracic Association
ATS	American Thoracic Society
CI	confidence interval
ERS	European Respiratory Society
HR	hazard ratio
HRCT	high-resolution computed tomography
IIP	idiopathic interstitial pneumonia
IPF	idiopathic pulmonary fibrosis
JRS	Japanese Respiratory Society
SD	Standard Deviation
UIP	Usual interstitial pneumonia

References

- [1] American Thoracic Society, Idiopathic pulmonary fibrosis: diagnosis and treatment. International consensus statement. American Thoracic Society (ATS), and the European Respiratory Society (ERS), *Am. J. Respir. Crit. Care Med.* 161 (2000) 646–664.
- [2] A.J. Podolanczuk, C.C. Thomson, M. Remy-Jardin, L. Richeldi, F.J. Martinez, M. Kolb, et al., Idiopathic pulmonary fibrosis: state of the art for 2023, *Eur. Respir. J.* (4) (2023 Apr) 61.
- [3] E. Baratella, B. Ruaro, F. Giudici, B. Wade, M. Santagiuliana, F. Salton, et al., Evaluation of correlations between genetic variants and high-resolution computed tomography patterns in idiopathic pulmonary fibrosis, *Diagnostics* 11 (5) (2021 Apr).
- [4] G. Raghu, H.R. Collard, J.J. Egan, F.J. Martinez, J. Behr, K.K. Brown, et al., An Official ATS/ERS/JRS/ALAT Statement: idiopathic pulmonary fibrosis: evidence-based guidelines for diagnosis and management, *Am. J. Respir. Crit. Care Med.* 183 (2011) 788–824.
- [5] T.E. King Jr., W.Z. Bradford, S. Castro-Bernardini, E.A. Fagan, I. Glaspole, M.K. Glassberg, E. Gorina, P.M. Hopkins, D. Kardatzke, L. Lancaster, et al., ASCEND Study Group, A phase 3 trial of pirfenidone in patients with idiopathic pulmonary fibrosis, *N. Engl. J. Med.* 370 (2014) 2083–2092.

- [6] L. Richeldi, V. Cottin, K.R. Flaherty, M. Kolb, Y. Inoue, G. Raghu, et al., Design of the INPULSISTM trials: two phase 3 trials of nintedanib in patients with idiopathic pulmonary fibrosis, *Respir. Med.* 108 (2014) 1023–1030.
- [7] A. Adegunsoye, J.M. Oldham, S.K. Bellam, S. Montner, M.M. Churpek, I. Noth, et al., Computed tomography honeycombing identifies a progressive fibrotic phenotype with increased mortality across diverse interstitial lung diseases, *Ann Am Thorac Soc* 16 (2019) 580–588.
- [8] M.L. Salisbury, T. Gu, S. Murray, B.H. Gross, A. Chughtai, M. Sayyoub, et al., Hypersensitivity pneumonitis: radiologic phenotypes are associated with distinct survival time and pulmonary function trajectory, *Chest* 155 (2019) 699–711.
- [9] M. Inomata, T. Jo, N. Kuse, N. Awano, M. Tone, H. Yoshimura, et al., Clinical impact of the radiological indeterminate for usual interstitial pneumonia pattern on the diagnosis of idiopathic pulmonary fibrosis, *Respir Investig* 59 (2021) 81–89.
- [10] H. Nakagawa, E. Ogawa, K. Fukunaga, D. Kinose, M. Yamaguchi, T. Nagao, et al., Quantitative CT analysis of honeycombing area predicts mortality in idiopathic pulmonary fibrosis with definite usual interstitial pneumonia pattern: a retrospective cohort study, *PLoS One* 14 (2019) e0214278.
- [11] A.J. Edey, A.A. Devaraj, R.P. Barker, A.G. Nicholson, A.U. Wells, D.M. Hansell, Fibrotic idiopathic interstitial pneumonias: HRCT findings that predict mortality, *Eur. Radiol.* 21 (2011) 1586–1593.
- [12] M.E. Mononen, H.-P. Kettunen, S.-K. Suoranta, M.S. Kärkkäinen, T.A. Selander, M.K. Purokivi, et al., Several specific high-resolution computed tomography patterns correlate with survival in patients with idiopathic pulmonary fibrosis, *J. Thorac. Dis.* 13 (2021) 2319–2330.
- [13] C. Romei, L. Tavanti, P. Sbragia, A. De Liperi, L. Carrozzi, F. Aquilini, et al., Idiopathic interstitial pneumonias: do HRCT criteria established by ATS/ERS/JRS/ALAT in 2011 predict disease progression and prognosis? *Radiol. Med.* 120 (2015) 930–940.
- [14] H. Sumikawa, T. Johkoh, T.V. Colby, K. Ichikado, M. Suga, H. Taniguchi, et al., Computed tomography findings in pathological usual interstitial pneumonia: relationship to survival, *Am. J. Respir. Crit. Care Med.* 177 (2008) 433–439.
- [15] D.A. Lynch, J.D. Godwin, S. Safrin, et al., High-resolution computed tomography in idiopathic pulmonary fibrosis. Diagnosis and prognosis, *Am. J. Respir. Crit. Care Med.* 172 (2005) 488–493.
- [16] T. Nagao, S. Nagai, Y. Hiramoto, et al., Serial evaluation of high-resolution computed tomography findings in patients with idiopathic pulmonary fibrosis in usual interstitial pneumonia, *Respiration* 69 (2002) 413–419.
- [17] S.M. Humphries, J.A. Mackintosh, H.E. Jo, S.L.F. Walsh, M. Silva, L. Calandriello, et al., Quantitative computed tomography predicts outcomes in idiopathic pulmonary fibrosis, *Respirology* 27 (2022) 1045–1053.
- [18] G. Raghu, M. Remy-Jardin, L. Richeldi, C.C. Thomson, Y. Inoue, T. Johkoh, et al., Idiopathic pulmonary fibrosis (an update) and progressive pulmonary fibrosis in adults: an official ATS/ERS/JRS/ALAT clinical practice guideline, *Am. J. Respir. Crit. Care Med.* 205 (2022) e18–e47.
- [19] G. Raghu, M. Remy-Jardin, J.L. Myers, et al., Diagnosis of idiopathic pulmonary fibrosis an Official ATS/ERS/JRS/ALAT Clinical practice guideline, *Am. J. Respir. Crit. Care Med.* 198 (2018) e44–e68.
- [20] D.A. Lynch, N. Sverzellati, W.D. Travis, et al., Diagnostic criteria for idiopathic pulmonary fibrosis: a fleischner society white paper, *Lancet Respir. Med.* Elsevier Ltd 6 (2018) 138–153.
- [21] I. Gayá García-Manso, J. Arenas-Jiménez, R. García-Sevila, et al., Mosaic attenuation in non-fibrotic areas as a predictor of non-usual interstitial pneumonia pathologic diagnosis, *Sci. Rep. England* 12 (2022) 7289.
- [22] D.M. Hansell, A.A. Bankier, H. MacMahon, et al., Fleischner Society: glossary of terms for thoracic imaging, *Radiology United States* 246 (2008) 697–722.
- [23] T. Hida, M. Nishino, T. Hino, et al., Traction bronchiectasis/bronchiolectasis is associated with interstitial lung abnormality mortality, *Eur. J. Radiol.* 129 (2020) 109073.
- [24] C.I.S. Silva, N.L. Müller, K. Fujimoto, S. Kato, K. Ichikado, H. Taniguchi, et al., Acute exacerbation of chronic interstitial pneumonia: high-resolution computed tomography and pathologic findings, *J. Thorac. Imag.* 22 (2007) 221–229.
- [25] H.R. Collard, C.J. Ryerson, T.J. Corte, G. Jenkins, Y. Kondoh, D.J. Lederer, et al., Acute exacerbation of idiopathic pulmonary fibrosis. An international working group report, *Am. J. Respir. Crit. Care Med.* 194 (2016) 265–275.
- [26] J. Choe, B.S. Kwon, K.-H. Do, H.S. Hwang, J.W. Song, E.J. Chae, Diagnostic and prognostic implications of 2018 guideline for the diagnosis of idiopathic pulmonary fibrosis in clinical practice, *Sci. Rep.* 11 (2021) 16481.
- [27] B.S. Kwon, J. Choe, K.H. Do, H.S. Hwang, E.J. Chae, J.W. Song, Computed tomography patterns predict clinical course of idiopathic pulmonary fibrosis, *Respir. Res.* 21 (2020) 295.
- [28] J. Fukihara, Y. Kondoh, K.K. Brown, T. Kimura, K. Kataoka, T. Matsuda, et al., Probable usual interstitial pneumonia pattern on chest CT: is it sufficient for a diagnosis of idiopathic pulmonary fibrosis? *Eur. Respir. J.* 55 (2020).
- [29] T. Diridollou, L. Sohier, C. Rousseau, A. Angibaud, P. Chauvin, T. Gaignon, et al., Idiopathic pulmonary fibrosis: significance of the usual interstitial pneumonia (UIP) CT-scan patterns defined in new international guidelines, *Respir Med Res* 77 (2020) 72–78.
- [30] M.L. Salisbury, L.B. Tolle, M. Xia, S. Murray, N. Tayob, A.M. Nambiar, et al., Possible UIP pattern on high-resolution computed tomography is associated with better survival than definite UIP in IPF patients, *Respir. Med.* 131 (2017) 229–235.
- [31] A. Arcadu, S.C. Byrne, P. Pirina, T.E. Hartman, B.J. Bartholmai, T. Moua, Correlation of pulmonary function and usual interstitial pneumonia computed tomography patterns in idiopathic pulmonary fibrosis, *Respir. Med.* 129 (2017) 152–157.
- [32] O. Le Rouzic, S. Bendaoud, C. Chenivesse, J. Rémy, B. Wallaert, Prognostic value of the initial chest high-resolution CT pattern in idiopathic pulmonary fibrosis, *Sarcoidosis, Vasc Diffus Lung Dis Off J WASOG.* 32 (2016) 353–359.
- [33] J.W. Lee, E. Shehu, J. Gjonbrataj, Y.E. Bahn, B.H. Rho, M.-Y. Lee, et al., Clinical findings and outcomes in patients with possible usual interstitial pneumonia, *Respir. Med.* 109 (2015) 510–516.
- [34] F. Novelli, L. Tavanti, S. Cini, F. Aquilini, L. Melosini, C. Romei, et al., Determinants of the prognosis of idiopathic pulmonary fibrosis, *Eur. Rev. Med. Pharmacol. Sci.* 18 (2014) 880–886.
- [35] H. Sumikawa, T. Johkoh, K. Fujimoto, H. Arakawa, T.V. Colby, J. Fukuoka, et al., Pathologically proved nonspecific interstitial pneumonia: CT pattern analysis as compared with usual interstitial pneumonia CT pattern, *Radiology* 272 (2014) 549–556.
- [36] H.E. Jo, I. Glaspole, N. Goh, P.M.A. Hopkins, Y. Moodley, P.N. Reynolds, et al., Implications of the diagnostic criteria of idiopathic pulmonary fibrosis in clinical practice: analysis from the Australian Idiopathic Pulmonary Fibrosis Registry, *Respirology* 24 (2019) 361–368.
- [37] T. Watahani, F. Sakai, T. Johkoh, S. Noma, M. Akira, K. Fujimoto, et al., Interobserver variability in the CT assessment of honeycombing in the lungs, *Radiology* 266 (3) (2013 Mar) 936–944.
- [38] A. Hata, T. Hino, R.K. Putman, M. Yanagawa, T. Hida, A.A. Menon, et al., Traction bronchiectasis/bronchiolectasis on CT scans in relationship to clinical outcomes and mortality: the COPDGene study, *Radiology* 304 (2022) 694–701.
- [39] R.K. Putman, G. Gudmundsson, G.T. Axelsson, T. Hida, O. Honda, T. Araki, et al., Imaging patterns are associated with interstitial lung abnormality progression and mortality, *Am. J. Respir. Crit. Care Med.* 200 (2019) 175–183.
- [40] K.M. Shin, K.S. Lee, M.P. Chung, J. Han, Y.A. Bae, T.S. Kim, et al., Prognostic determinants among clinical, thin-section CT, and histopathologic findings for fibrotic idiopathic interstitial pneumonias: tertiary hospital study, *Radiology* 249 (2008) 328–337.
- [41] H.Y. Lee, K.S. Lee, Y.J. Jeong, J.H. Hwang, H.J. Kim, M.P. Chung, et al., High-resolution CT findings in fibrotic idiopathic interstitial pneumonias with little honeycombing: serial changes and prognostic implications, *AJR Am. J. Roentgenol.* 199 (2012) 982–989.
- [42] M. Kreuter, H. Koegler, M. Trampisch, S. Geier, L. Richeldi, Differing severities of acute exacerbations of idiopathic pulmonary fibrosis (IPF): insights from the INPULSIS® trials, *Respir. Res.* 20 (2019) 71.
- [43] J.G. Parambil, J.L. Myers, J.H. Ryu, Histopathologic features and outcome of patients with acute exacerbation of idiopathic pulmonary fibrosis undergoing surgical lung biopsy, *Chest* 128 (2005) 3310–3315.
- [44] M. Kolb, B. Bondue, A. Pesci, Y. Miyazaki, J.W. Song, N.Y. Bhatt, et al., Acute exacerbations of progressive-fibrosing interstitial lung diseases, *Eur Respir Rev an Off J Eur Respir Soc* 27 (2018).