

Primary Sclerosing Cholangitis–Associated Cholangiocarcinoma Demonstrates High Intertumor and Intratumor Heterogeneity

Eline J.C.A. Kamp, MD, PhD¹, Maikel P. Peppelenbosch, PhD¹, Michail Doukas, MD², Joanne Verheij, MD³, Cyriel Y. Ponsioen, MD⁴, Ronald van Marion, BSc², Marco J. Bruno, MD¹, Bas Groot Koerkamp, MD⁵, Winand N.M. Dinjens, PhD² and Annemarie C. de Vries, MD¹

INTRODUCTION: Intertumor and intratumor heterogeneity may explain the diagnostic challenge and limited efficacy of chemotherapy for primary sclerosing cholangitis–associated cholangiocarcinoma (PSC-CCA). In this study, tumor heterogeneity was assessed through p53 and p16 protein expression analysis and next-generation sequencing (NGS) of *TP53* and *CDKN2A* genetic alterations in PSC-associated CCA.

METHODS: Formalin-fixed paraffin-embedded tissue samples from resection material of patients with PSC-CCA or patients with PSC diagnosed with biliary dysplasia were selected. Sections with CCA and foci with dysplastic epithelium were identified by 2 independent gastrointestinal pathologists. Immunohistochemical evaluation of p53 and p16 protein expression and NGS of *TP53* and *CDKN2A* genetic alterations were performed.

RESULTS: A total of 49 CCA and 21 dysplasia samples were identified in the resection specimens of 26 patients. P53 protein expression showed loss of expression, wild type, and overexpression in 14%, 63%, and 23% CCA and in 19%, 62%, and 19% dysplasia samples, respectively. P16 protein expression showed negative, heterogeneous, and positive results in 31%, 57%, and 12% CCA and in 33%, 53%, and 14% dysplasia samples, respectively. NGS showed high intertumor and intratumor heterogeneity of *TP53* mutations and *CDKN2A* loss. Nearly 70% of the samples with a *TP53* missense mutation demonstrated p53 overexpression, whereas all samples with a *TP53* nonsense mutation demonstrated loss of p53 protein expression.

DISCUSSION: PSC-associated CCA is characterized by high intertumor and intratumor heterogeneity of both p53/p16 protein expression and genetic alterations in *TP53/CDKN2A*, indicating that these tumors consist of multiple subclones with substantially different genetic makeup. The high intertumor and intratumor heterogeneity in PSC-CCA should be acknowledged during the development of diagnostic and therapeutic strategies.

SUPPLEMENTARY MATERIAL accompanies this paper at <http://links.lww.com/CTG/A694>

Clinical and Translational Gastroenterology 2021;12:e00410. <https://doi.org/10.14309/ctg.0000000000000410>

INTRODUCTION

Primary sclerosing cholangitis (PSC) is a major risk factor for the development of cholangiocarcinoma (CCA), with a lifetime risk up to 15% (1). Unfortunately, timely diagnosis of PSC-associated CCA (PSC-CCA), or preferably high-grade dysplasia, remains a challenge, and PSC-CCA is largely resistant to chemotherapy.

All currently available diagnostic strategies have limitations with disappointing diagnostic value of imaging, tumor markers,

and brush cytology (2). The diagnostic value of imaging for PSC-CCA is often limited because the tumor can mimic the characteristic benign fibrotic strictures in PSC (3). The accuracy of serologic tumor markers—especially CA-19.9—is hampered by the occurrence of elevated levels in case of a benign biliary obstruction (4). Cytological assessment of brush samples, obtained during endoscopic retrograde cholangiopancreatography (ERCP), has limited sensitivity and a considerable rate of false-

¹Department of Gastroenterology and Hepatology, Erasmus MC, University Medical Center Rotterdam, the Netherlands; ²Department of Pathology, Erasmus MC Cancer Institute, University Medical Center Rotterdam, the Netherlands; ³Department of Pathology, Amsterdam UMC, the Netherlands; ⁴Department of Gastroenterology and Hepatology, Amsterdam UMC, the Netherlands; ⁵Department of Surgery, Erasmus MC, University Medical Center Rotterdam, the Netherlands. **Correspondence:** Annemarie C. de Vries, MD. E-mail: a.c.devries@erasmusmc.nl

Received February 23, 2021; accepted August 22, 2021; published online October 5, 2021

© 2021 The Author(s). Published by Wolters Kluwer Health, Inc. on behalf of The American College of Gastroenterology

negative results (5). Diagnostic accuracy remains disappointing even when routine cytology is combined with fluorescence *in situ* hybridization (FISH) by using probes for chromosomes 3, 7, 9, and 17 (6) or *MCL1*, *MYC*, *EGFR*, and *CDKN2A* (7).

Intertumor and intratumor heterogeneity of PSC-CCA may partly account for the diagnostic limitations regarding assessing molecular aberrations, including FISH, and the relative resistance of cancer to chemotherapy. Molecular diagnostic methods may be hampered by differences in the level of genetic profiles and transcription and protein expression profiles. High intratumor clonal diversity has been observed for sporadic intrahepatic CCA (8). However, molecular data of PSC-CCA are scarce.

Prompted by the abovementioned considerations, we decided to study the clonal diversity of PSC-CCA. Mutations in *TP53* and *CDKN2A* genes and protein expression of p53 and p16 were selected as markers in this respect because of their important and well-known role in the regulation of apoptosis and senescence.

METHODS

Tissue samples and histology

Patients with PSC diagnosed with biliary dysplasia or CCA in hepatobiliary resection specimens were included after liver transplantation, pancreaticoduodenectomy, or extrahepatic biliary resection between 1996 and 2019 at Erasmus MC University Medical Center, Rotterdam and Amsterdam University Medical Center, the Netherlands. The diagnosis of PSC was based on the presence of a cholestatic biochemical profile combined with characteristic bile duct changes in histological examination or on cholangiography. Causes of secondary sclerosing cholangitis had to be excluded. After fixation of the specimen, the tissue was sampled and embedded in paraffin (FFPE) directly after surgical resection, according to standard routine care. From the FFPE, tissue blocks of 4- μ m thick sections were cut, and histological areas with tumor or dysplasia were selected. To explore intratumor heterogeneity, multiple distinct tumor areas were chosen. Two expert hepatobiliary pathologists (M.D. and J.H.) independently reviewed hematoxylin and eosin-stained tissue slides. In case of discrepancies, a consensus diagnosis was achieved. This study was approved by the local Medical Ethics Review Board (MEC-2018-1262).

Immunohistochemistry

An immunohistochemical analysis for p53 and p16 was performed on the selected FFPE sections using the Ventana Benchmark ULTRA (Ventana Medical Systems Inc). The 4- μ m FFPE sections were stained for p53 and p16 using UltraView Universal DAB Detection Kit (#760-700, Ventana). In brief, after deparaffinization and heat-induced antigen retrieval with CC1 (#950-500, Ventana) for 64 minutes, the tissue samples were incubated with either p53 or p16 antibody for 32 minutes at 37°C. Incubation was followed by hematoxylin II counterstain for 8 minutes and then a blue-coloring reagent for 8 minutes according to the manufacturer's instructions (Ventana) (Supplementary Table 1, <http://links.lww.com/CTG/A694>). The specificity of the reaction was confirmed by positive and negative controls. Protein expression was scored according to a consensus of 2 investigators (E.K. and M.D.). Nuclear expression of p53 was classified as loss of expression, wild type, or overexpression. Protein expression of p16 was scored as negative, heterogeneous, or positive (Supplementary Figure 1, <http://links.lww.com/CTG/A694>).

Tumor genetic heterogeneity analysis

The tumor and dysplastic areas were manually microdissected under a dissecting microscope from hematoxylin-stained sections. DNA was extracted with 5% Chelex resin and proteinase K, after which DNA concentrations were measured using the Qubit 2.0 fluorimeter. Next-generation sequencing was performed with a gene panel targeting 96% and 99% of the open reading frame and all exon-intron boundaries of *TP53* and *CDKN2A*, respectively. Libraries were created with the Ion AmpliSeq 2.0 Library Plus Kit; template preparation was performed using an Ion Chef system and sequencing using the Ion GeneStudio S5 Prime System on 540 chips with the Ion 540 Chef Kit. Data were analyzed with the Variant Caller v5.10.0.18. The threshold for total coverage per amplicon was 100 reads, and variants reported in the ESP6500si or 1000 genomes databases in more than 1% were excluded, assuming that these were single nucleotide polymorphisms. Variants were considered potentially reliable if present in at least 20% of the called reads and/or corresponded to the tumor cell percentage.

Copy number variations were identified using Sequence Pilot from JSI medical systems. Control samples required for this analysis consisted of DNA isolated from the nonneoplastic liver or pancreas tissue from the same resections. Normalized and relative coverages were calculated for each amplicon of tumor and dysplasia samples. The copy number variations were considered reliable when all amplicons in the indicated gene reached the thresholds for loss or gain.

In case of loss of expression and overexpression of p53 within a neoplastic lesion on 1 section, the tumor tissue with loss of expression and overexpression was manually microdissected from stained sections of FFPE tissue blocks, separately. Both samples were analyzed for mutations and CNVs, after which these genetic alterations were compared.

Finally, the concordance between gene aberrations and the corresponding protein expression was examined.

RESULTS

Tissue samples

A total of 26 patients with PSC were identified: 24 patients with CCA and 2 patients with biliary dysplasia as the most severe neoplastic lesion. Patient characteristics, different tumor locations, and surgical procedures are given in Table 1. Two pathologists reviewed hematoxylin and eosin-stained sections independently and selected 49 tumor and 21 dysplasia regions in the resection specimens; in 3 samples, a consensus diagnosis of indefinite for dysplasia was reached.

Immunohistochemistry

Overexpression of p53 protein was present in 11 CCA (23%) and 4 dysplasia (19%) samples, loss of expression in 7 CCA (14%) and 4 dysplasia (19%) samples, and wild type expression in 31 CCA (63%) and 13 dysplasia (62%) samples (Figure 1). Three indefinite for dysplasia samples showed wild type expression. Focal loss of expression with an abrupt transition to overexpression was observed in 2 samples (1 CCA and 1 dysplasia) of 1 patient (Figure 2A).

Strong and diffuse staining of p16 was observed in 6 CCA (12%) and 3 dysplasia (14%) samples and negative staining in 15 CCA (31%) and 7 dysplasia (33%) samples, and the remaining 28 CCA (57%) and 11 dysplasia (53%) samples demonstrated a heterogeneous pattern. One indefinite for dysplasia sample

Table 1. Patient characteristics

Characteristics	No. of patients
Men	18 (69%)
Age at PSC diagnosis (yr)	40 (SD = 3)
Age at CCA diagnosis	27 (SD = 3)
Survival after resection (mo)	29 (SD = 9)
IBD	17 (65%)
Ulcerative colitis	16
Crohn's disease	1
Location of CCA	n = 24
Distal	6 (25%)
Perihilar	13 (54%)
Intrahepatic	5 (21%)
Surgical resection	n = 26
Liver transplantation	6
Liver transplantation and Whipple procedure	1
Hemihepatectomy	11
Hemihepatectomy and Whipple procedure	1
Whipple procedure	5
Cholecystectomy	1
Autopsy	1

showed heterogeneous expression that gradually changed into a strong and diffuse positive staining. Remarkably, tumor samples of this patient showed a heterogeneous p16 expression pattern.

Genetic alterations and tumor heterogeneity

In 9 patients, *TP53* mutations were detected, including missense mutations in 11 CCA and 3 dysplasia samples (see Supplementary Table 2, <http://links.lww.com/CTG/A694>). Two different missense mutations were found in 1 tumor sample of a patient. One dysplasia sample showed the combination of a splice site and missense mutation. Samples of 2 patients demonstrated a *TP53* nonsense mutation. Loss of *CDKN2A* was found in 6 patients: 8 CCA and 3 dysplasia samples. No *CDKN2A* mutations were detected. Genetic variation existed between samples in 6 patients. Both *TP53* mutations and *CDKN2A* loss demonstrated subclonality in 4 tumors, of which 2 tumors showed heterogeneity of *TP53* mutations and *CDKN2A* loss.

In the abovementioned case with abrupt transition of loss of p53 protein expression to p53 overexpression, genetic alterations in both expression regions were analyzed. The CCA region with p53 overexpression showed a missense mutation in *TP53* (NM_001126114; c.818G>A; p.Arg273His), whereas no *TP53* mutation was found in the CCA sample region with loss of p53 expression (Figure 2B).

Concordance between genetic alterations and protein expression

In total, 9 (69%) of 14 CCA and dysplasia samples with *TP53* missense mutations showed p53 overexpression. The remaining 5 samples with *TP53* missense mutations showed wild type expression. The 4 samples with a *TP53* nonsense mutation

demonstrated loss of p53 expression. In addition, aberrant p16 protein expression was observed in only 3 (27%) of 11 samples (1 negative and 2 positive results) with *CDKN2A* loss, whereas 8 samples showed a heterogeneous expression pattern.

DISCUSSION

Molecular data on the carcinogenesis of PSC-CCA are required to improve timely diagnosis of PSC-CCA and develop targeted therapy. In this study, we demonstrated that PSC-CCA exhibits a diversity of p53 and p16 protein expression patterns and contain multiple genetic alterations in *TP53* and *CDKN2A* genes. This diversity in protein expression and genetic alterations is evident both between and within tumors, consistent with high intertumor and intratumor heterogeneity. In apparent agreement, dissimilar gradual changes and abrupt transitions in protein expression patterns are observed within tumors. Although intratumor heterogeneity has been described in several cancer types (9), the extent of this heterogeneity in PSC-CCA observed is remarkable and may hold important clues as to explaining the specific features of the disease, especially regarding therapy resistance. Indeed, alternative p53 and p16 protein expression and genetic alterations of *TP53* and *CDKN2A* are already observed in dysplasia, indicating a role for these genes early in the neoplastic cascade leading to PSC-CCA. These findings thus not only alter our view of PSC-CCA carcinogenesis and signify the important role of these genes in the development of CCA but also show the presence of multiple competing clones in this process.

The observed high intratumor heterogeneity in this study provides new insights into the biological processes involved in the oncogenesis of PSC-CCA. In a large study (n = 186), Goepfert et al. (10) identified several interesting molecular alterations in PSC-CCA, which are potential targets for individualized therapy. This study adds to these data that because of significant tumor heterogeneity, the number of mutations per tumor might be underestimated in the study of Goepfert et al. because only 1 sample per tumor was investigated. This is a general consequence of whole genome sequencing (WGS) and whole exome sequencing studies because usually only 1 region of the tumor is selected, and additional genetic alterations in other regions of the tumor (i.e., subclonal populations of tumor cells) will escape detection (11,12). This study serves as a plea to recognize subclonal cell populations in the future whole genome sequencing and whole exome sequencing studies.

The most direct clinical implication of our findings concerns the interpretation of a negative result of FISH or genetic analysis of a biliary stricture in patients with PSC. The presence of subclonal populations should be taken into account because a single brush or biliary biopsy may underestimate or fail to detect oncogenic mutations in these heterogeneous tumors. Similarly, for FISH analysis, a small region of tissue, suspected of invasive cancer, is selected for analysis, which can lead to the nondetection of subclonal tumor cells with chromosomal instability. Therefore, it may be recommended to repeat an ERCP to obtain a biliary brush or biopsy when cytology or histopathology, mutational analysis, and clinical context (including imaging results) reach indistinct results. Previous studies substantiate the yield of repeated biliary brushes in PSC, both during one and repeated ERCP procedures (13). In addition, more sensitive approaches might improve diagnostic outcomes with less invasive procedures, including molecular sequencing of circulating tumor cells or circulating tumor DNA (14,15). However, these strategies are

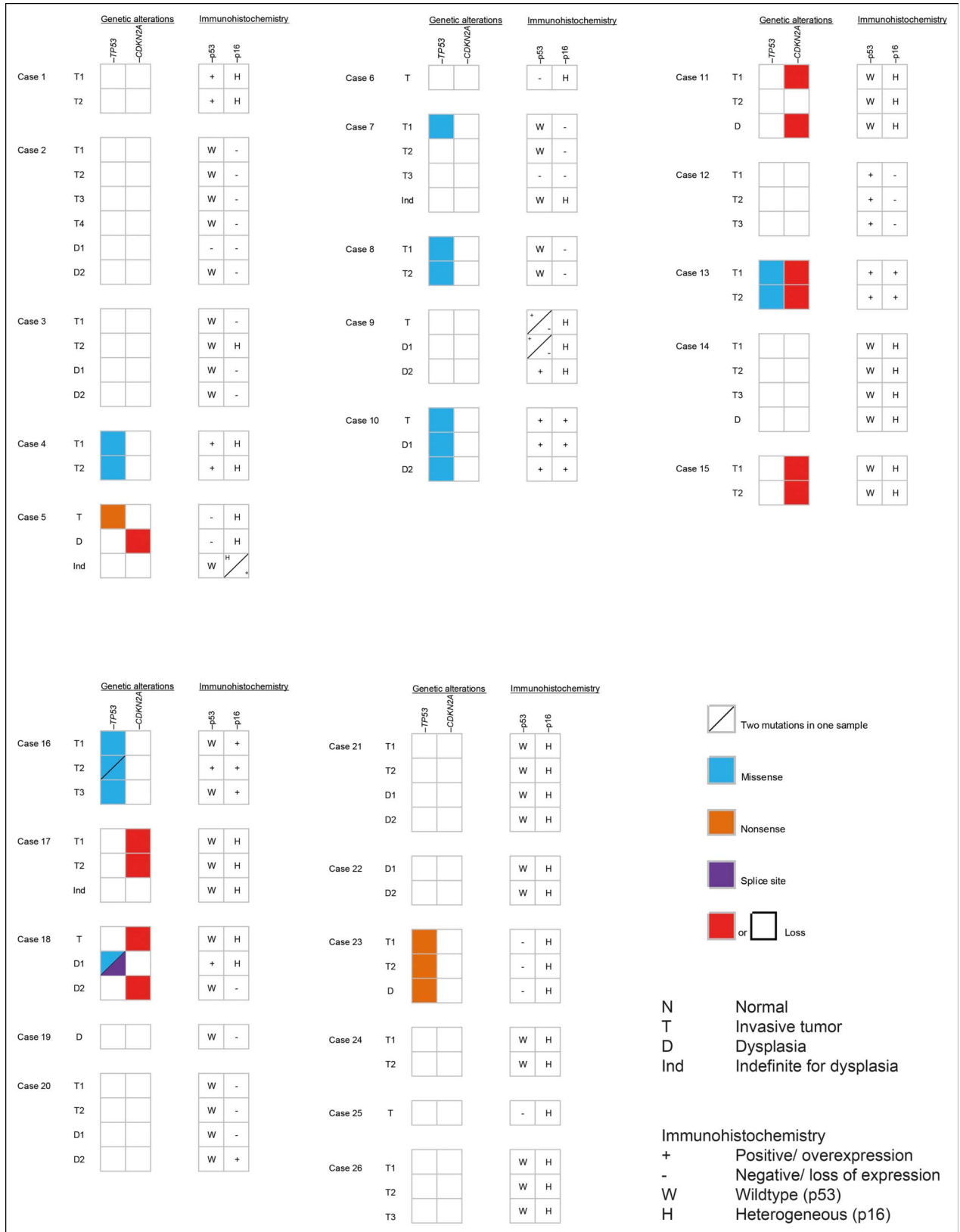


Figure 1. Overview of mutations, analysis of copy number variations, and immunohistochemistry in resection specimens of 26 patients with primary sclerosing cholangitis with biliary neoplasia.

Study Highlights

WHAT IS KNOWN

- ✓ Intertumor and intratumor clonal diversity of cholangiocarcinoma (CCA) is relevant for the development of diagnostic and (chemo)therapeutic strategies.
- ✓ The presence of intratumor clonal diversity has been observed for sporadic intrahepatic CCA but is largely unexplored for primary sclerosing cholangitis-associated CCA.

WHAT IS NEW HERE

- ✓ Primary sclerosing cholangitis-associated CCA is characterized by high intertumor and intratumor heterogeneity of both p53/p16 protein expression and genetic alterations in *TP53/CDKN2A* genes, indicating that these tumors consist of multiple subclones.
- ✓ *TP53* missense mutations are correlated with p53 overexpression, whereas *TP53* nonsense mutations are correlated with loss of p53 expression.

REFERENCES

1. Hirschfield GM, Karlsen TH, Lindor KD, et al. Primary sclerosing cholangitis. *Lancet* 2013;382(9904):1587–99.
2. Siqueira E, Schoen RE, Silverman W, et al. Detecting cholangiocarcinoma in patients with primary sclerosing cholangitis. *Gastrointest Endosc* 2002; 56(1):40–7.
3. Moreno Luna LE, Gores GJ. Advances in the diagnosis of cholangiocarcinoma in patients with primary sclerosing cholangitis. *Liver Transpl* 2006;12(11 Suppl 2):S15–9.
4. Levy MJ, Baron TH, Clayton AC, et al. Prospective evaluation of advanced molecular markers and imaging techniques in patients with indeterminate bile duct strictures. *Am J Gastroenterol* 2008;103(5): 1263–73.
5. Trikudanathan G, Navaneethan U, Njei B, et al. Diagnostic yield of bile duct brushings for cholangiocarcinoma in primary sclerosing cholangitis: A systematic review and meta-analysis. *Gastrointest Endosc* 2014;79(5): 783–9.
6. Kipp BR, Stadheim LM, Halling SA, et al. A comparison of routine cytology and fluorescence in situ hybridization for the detection of malignant bile duct strictures. *Am J Gastroenterol* 2004;99(9):1675–81.
7. Barr Fritcher EG, Voss JS, Brankley SM, et al. An optimized set of fluorescence in situ hybridization probes for detection of pancreatobiliary tract cancer in cytology brush samples. *Gastroenterology* 2015;149(7): 1813–24.e1.
8. Walter D, Döring C, Feldhahn M, et al. Intratumoral heterogeneity of intrahepatic cholangiocarcinoma. *Oncotarget*. 2017;8(9):14957–68.
9. Dentre SC, Leshchiner I, Haase K, et al. Characterizing genetic intra-tumor heterogeneity across 2,658 human cancer genomes. *Cell* 2021; 184(8):2239–54.e39.
10. Goepfert B, Folseraas T, Roessler S, et al. Genomic characterization of cholangiocarcinoma in primary sclerosing cholangitis reveals novel therapeutic opportunities. *Hepatology* 2020;72(4):1253–66.
11. Wardell CP, Fujita M, Yamada T, et al. Genomic characterization of biliary tract cancers identifies driver genes and predisposing mutations. *J Hepatol* 2018;68(5):959–69.
12. de Bruin EC, McGranahan N, Mitter R, et al. Spatial and temporal diversity in genomic instability processes defines lung cancer evolution. *Science* 2014;346(6206):251–6.
13. Rabinovitz M, Zajko AB, Hassanein T, et al. Diagnostic value of brush cytology in the diagnosis of bile duct carcinoma: A study in 65 patients with bile duct strictures. *Hepatology* 1990;12(4 Pt 1):747–52.
14. Rizzo A, Ricci AD, Tavolari S, et al. Circulating tumor DNA in biliary tract cancer: Current evidence and future perspectives. *Cancer Genomics Proteomics* 2020;17(5):441–52.
15. Winter H, Kaisaki PJ, Harvey J, et al. Identification of circulating genomic and metabolic biomarkers in intrahepatic cholangiocarcinoma. *Cancers (Basel)* 2019;11(12):1895.
16. Pribluda A, de la Cruz CC, Jackson EL. Intratumoral heterogeneity: From diversity comes resistance. *Clin Cancer Res* 2015;21(13):2916–23.
17. Bailey C, Black JRM, Reading JL, et al. Tracking cancer evolution through the disease course. *Cancer Discov* 2021;11(4):916–32.
18. Brandi G, Farioli A, Astolfi A, et al. Genetic heterogeneity in cholangiocarcinoma: A major challenge for targeted therapies. *Oncotarget* 2015;6(17):14744–53.
19. Jamal-Hanjani M, Quezada SA, Larkin J, et al. Translational implications of tumor heterogeneity. *Clin Cancer Res* 2015;21(6):1258–66.
20. Ewald JA, Desotelle JA, Wilding G, et al. Therapy-induced senescence in cancer. *J Natl Cancer Inst* 2010;102(20):1536–46.
21. Guillon J, Petit C, Toutain B, et al. Chemotherapy-induced senescence, an adaptive mechanism driving resistance and tumor heterogeneity. *Cell Cycle* 2019;18(19):2385–97.
22. Lee J, Park SH, Chang HM, et al. Gemcitabine and oxaliplatin with or without erlotinib in advanced biliary-tract cancer: A multicentre, open-label, randomised, phase 3 study. *Lancet Oncol* 2012;13(2):181–8.
23. Bekaii-Saab T, Phelps MA, Li X, et al. Multi-institutional phase II study of selumetinib in patients with metastatic biliary cancers. *J Clin Oncol* 2011; 29(17):2357–63.
24. Ramanathan RK, Belani CP, Singh DA, et al. A phase II study of lapatinib in patients with advanced biliary tree and hepatocellular cancer. *Cancer Chemother Pharmacol* 2009;64(4):777–83.
25. Borbath I, Ceratti A, Verslype C, et al. Combination of gemcitabine and cetuximab in patients with advanced cholangiocarcinoma: A phase II study of the Belgian group of digestive oncology. *Ann Oncol* 2013;24(11):2824–9.

Open Access This is an open access article distributed under the terms of the Creative Commons Attribution-Non Commercial-No Derivatives License 4.0 (CCBY-NC-ND), where it is permissible to download and share the work provided it is properly cited. The work cannot be changed in any way or used commercially without permission from the journal.