



Received: 2016.08.16
Accepted: 2016.09.05
Published: 2017.05.13

Authors' Contribution:

- A** Study Design
- B** Data Collection
- C** Statistical Analysis
- D** Data Interpretation
- E** Manuscript Preparation
- F** Literature Search
- G** Funds Collection

Role of Computed Tomography (CT) in Localisation and Characterisation of Suprahyoid Neck Masses

Rashmeet Kaur^{1ABCDEF}, Paramdeep Singh^{1CDE}, Navkiran Kaur^{2ABF}, Simmi Bhatnagar^{2DE}, Anshul Dahuja^{3EF}

¹ Department of Radiology, Guru Gobind Singh Medical College and Hospital, Baba Farid University of Health Sciences, Faridkot, Punjab, India

² Department of Radiology, Government Medical College and Hospital, Patiala, Punjab, India

³ Department of Orthopedics, Guru Gobind Singh Medical College and Hospital, Baba Farid University of Health Sciences, Faridkot, Punjab, India

Author's address: Paramdeep Singh, Department of Radiodiagnosis, Guru Gobind Singh Medical College and Hospital, Baba Farid University of Health Sciences, Faridkot, Punjab, India, e-mail: paramdeepdoctor@gmail.com

Summary

Background:

Suprahyoid neck lesions are difficult to assess only by means of clinical inspection and therefore imaging techniques are required to precisely evaluate suprahyoid neck spaces. The aim of this study was to evaluate the distinctive role of computed tomography in the assessment of anatomical source and pathological type of masses involving the suprahyoid neck spaces.

Material/Methods:

Sixty patients presenting with suprahyoid neck masses underwent computed tomography of the neck. The CT findings were correlated with histopathological findings and a final diagnosis was made.

Results:

Overall, male preponderance was seen except in the case of parotid space lesions where female predominance was seen. The most common aetiology was squamous cell carcinoma and the majority of cases (30%) were seen in patients aged 41–50 years. The majority of lesions were found in the pharyngeal mucosal space (n=16) with squamous cell carcinoma being the most common pathology. In the parotid space, pleomorphic adenoma and in the prestyloid parapharyngeal space, squamous cell carcinoma were the most common lesions, respectively. In the retropharyngeal space, an equal incidence of malignant and inflammatory aetiologies was seen. Abscesses were the most common lesions in the prevertebral space. The pleomorphic adenoma was the most common benign tumour and was also the second most common tumour in the suprahyoid neck spaces. CT had an excellent correlation with histopathological findings with sensitivity of 96.4%, specificity of 100%, positive predictive value of 100% and a negative predictive value of 91.67%.

Conclusions:

Computed tomography definitely has a major role to play in the evaluation of suprahyoid neck masses as it has an excellent correlation with post-operative histopathological diagnosis.

MeSH Keywords:

Head and Neck Neoplasms • Neck • Pathology • Tomography, Spiral Computed

PDF file:

<http://www.polradiol.com/abstract/index/idArt/901072>

Background

The neck has a complex anatomy and contains small anatomic structures that are closely spaced. This necessitates a thorough understanding of normal spatial relationships and anatomical variants for the diagnosis of lesions. Better visualization with the help of computed tomography (CT) can

provide the clinician with key information for an improved management of patients.

The tubular shaped soft tissue of the neck can be divided at the level of hyoid bone into two separate areas – the suprahyoid and infrahyoid portions. The three sheets of the deep cervical fascia, i.e. superficial, middle and deep

layers, split the suprahyoid part of the neck into distinct spaces that are valuable anatomic markers for evaluating pathological alterations and their spread. The spaces of the suprahyoid neck region are comprised by the parotid space, retropharyngeal space, pharyngeal mucosal space, masticator space, prestyloid parapharyngeal space, post-styloid parapharyngeal space or carotid space, and prevertebral space. Space occupying lesions (SOL's originating in any of these spaces will initially expand the respective space and then distort the neighbouring spaces, which offers the evidence regarding its place of origin [1,2].

A neck mass can be a diagnostic challenge in patients of any age and is commonly evaluated with computed tomography (CT), magnetic resonance imaging (MRI) or ultrasound. The use of multislice helical CT has led to better resolution and substantial reduction in scan acquisition and display time. CT is non-invasive, non-operator dependent and allows for precise measurements of tissue attenuation coefficients. Better quality volume data sets can be acquired with multi-slice CT, which can be retrospectively manipulated to acquire axial sections of preferred thickness and increment. Multiplanar reconstructions can be obtained in any preferred plane with isotropic resolution. CT offers superb distinction of fat from other tissues and is undoubtedly better than magnetic resonance imaging (MRI) for the assessment of bone and calcifications. Additionally, CT is less susceptible to motion artefacts, has better temporal resolution, and therefore has better compliance with claustrophobic patients as compared to MRI, and can also be done in patients with MR incompatible devices. Brilliant 3-dimensional imaging is achievable using volume rendering, maximum intensity projection and shaded surface display methods, which enables the surgeon to comprehend the anatomical extent of the lesion and its relationship to adjacent structures in a much better way [1-4].

On the other hand, MR imaging do not use ionizing radiation, has superb intrinsic soft tissue contrast and better display of exogenous contrast enhancement as compared to CT. MR imaging is better than CT in showing the relationship of neck masses to adjacent muscles and soft tissues due to better soft tissue delineation. MR imaging and contrast-enhanced CT are comparable in delineating vascular anatomy and pathology, however, MR imaging is superior when CT imaging is done without intravenous contrast material. Nevertheless, CT is more useful in showing bone, cartilage and airway abnormalities [3-5].

Ultrasound is widely accessible, easy-to-use, non-invasive, low-priced, without metallic artefacts and is relatively safe as it uses only ultrasound waves that are non-ionizing. Ultrasound easily differentiates cystic from solid lesions and is also helpful in evaluating malignant/benign masses and detecting the presence of enlarged lymph nodes. However, this modality is extremely reliant on operator skill and has restricted fields of view. Unlike MRI, ultrasound lacks high soft tissue contrast and specificity required for tumour staging [1-5].

Suprahyoid neck masses are hard to evaluate solely by means of clinical inspection and therefore imaging techniques such as computed tomography (CT) are

indispensable to accurately evaluate this area. There is paucity of studies and data regarding different suprahyoid neck masses from the Indian subcontinent. The aim of this paper was to evaluate the diverse roles of CT in the assessment of anatomical source and pathological type of lesions involving the suprahyoid region.

Material and Methods

Patients

A total of 60 patients who had clinical features suggesting a suprahyoid neck mass and subsequently underwent CT examination were included in this study. Patients of all ages and both sexes were included. A comprehensive history was elicited from all patients. Procedural workup comprised of a proper clinical examination and routine biochemical investigations. Patients who were presumed to have a suprahyoid neck mass due to trauma were excluded.

CT technique

Before commencing the scan, the procedure was described to the patient in their vernacular language and a written informed consent was taken. In the current study, the scans were done in a Siemens Somatom Emotion 6 machine, a spiral multislice apparatus (6 slices). For neck CT, the following protocol was used: 130 kVp, reference of 85 mAs, 6×2.0 mm collimation, 0.85 pitch factor and rotation time of 0.8 seconds. Initially, a topogram was acquired after positioning the patient in supine position with neck hyperextended, with normal breathing pattern and without deglutition. Contrast-enhanced CT (CECT) was performed in all patients with bolus intravenous administration of 1-2 mL/kg of non-ionic iodinated contrast agent (Iomeron, 350 mg/ml, Bracco S.p.A., Milan, Italy). Axial 3-mm thick sections with 3-mm collimation were acquired from the base of the skull to the suprasternal notch. Suitable sagittal and coronal reconstructions were done. The patients were carefully monitored after contrast administration to look for adverse reactions.

Analysis of the images

CT images of all patients were evaluated for the following features: location, size, density, contour, type of enhancement, necrosis, calcification, fat planes with the adjoining structures, lymph nodes and any other supplementary CT findings. The following radiological descriptions were used in the categorization of suprahyoid masses. Malignant lesions were assumed to demonstrate contrast enhancement, invasion of adjoining soft tissues, invasion of the bones and likely perineural spread. Inflammatory lesions were supposed to demonstrate absent or peripheral enhancement in post-contrast images and were sometimes associated with the presence of other inflammatory changes in the adjacent structures. On the basis of patient's age, symptoms, clinical and CECT findings, a provisional diagnosis was made. Histopathological analysis was used as the reference standard.

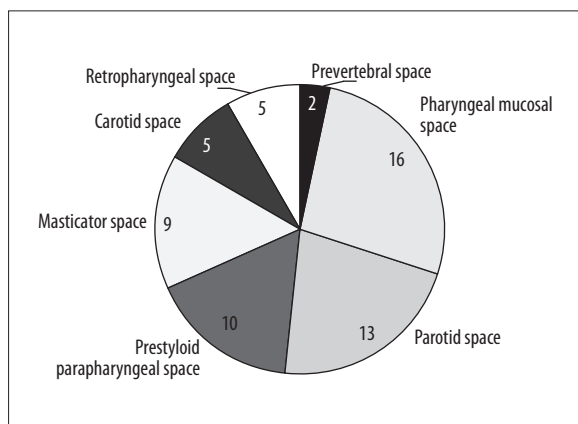


Figure 1. Pie diagram showing distribution of lesions in each suprahyoid neck space.

Results

Out of total 60 patients, there were 40 males and 20 females with male to female ratio of 2: 1. Only in the case parotid space lesions, females outnumbered males with M: F ratio of 1: 2.5. A wide-ranging age distribution of patients was seen, from 9 months to 80 years of age. The majority of patients (44 cases; 73.3%) were in the age group of 31–60 yrs, with 41–50 yrs age group comprising 30% (20 cases) of the all cases of suprahyoid neck masses. The majority of lesions were found in the pharyngeal mucosal space (n=16), followed by parotid space (n=13) and parapharyngeal space (PPS; n=10), respectively. The rest of the lesions were seen in the masticator, carotid, retropharyngeal and prevertebral space in that order (Figure 1).

Of 60 cases of suprahyoid neck masses, the most common masses (n=28) were malignant (46.66%), of which 11 were seen in the pharyngeal mucosal space (PMS) (Table 1). Squamous cell carcinoma (Figures 2,3) was the most common pathology in the majority of spaces, i.e. PMS, PPS, carotid and masticator space. Out of total 11 benign lesions, the highest number of lesions was seen in the parotid space (n=7) with pleomorphic adenoma (Figure 4) being the most common pathology in this space. The inflammatory neck lesions (Figure 5) were almost proportionately distributed in suprahyoid neck spaces, with a maximum number of 4 cases in PMS. There were four

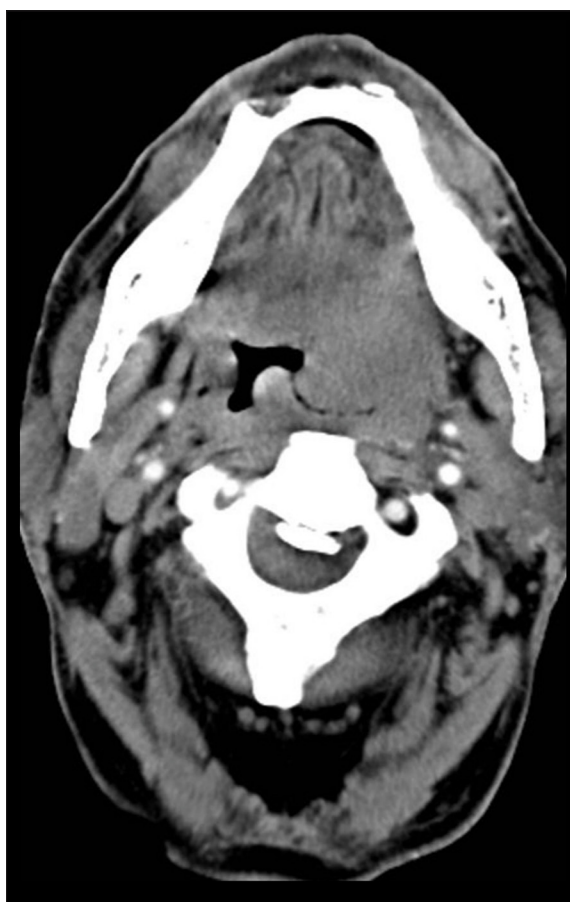

Figure 2. Heterogeneous mass (squamous cell carcinoma) in the left tonsillar fossa in a patient presenting with painful swelling. The mass is causing a bulge and narrowing of the oropharynx, with loss of fat planes with the base of the tongue and retropharyngeal space on the left side.

cases of congenital lesions. In the retropharyngeal space, an equal incidence of malignant and inflammatory aetiology was seen. Abscesses were the most frequent cause of suprahyoid prevertebral space masses (Table 2). Of total 11 benign lesions, max largest number of cases were wund in the age group of 41–50 yrs (n=6) with a lesser smumber of benign lesions seen in the extremes of age. Out of 28 malignant lesions, 13 cases (46.42%) were seen in patients aged

Table 1. Table showing the different types of etiologies in respective suprahyoid spaces.

Space	Congenital	Inflammatory	Benign	Malignant
Pharyngeal mucosal space	–	4	1	11
Parotid space	1	2	7	3
Prestyloid parapharyngeal space	1	3	2	4
Masticator space	1	2	1	5
Carotid space	1	1	–	3
Retropharyngeal space	–	3	–	2
Prevertebral space	–	2	–	–
Total	4	17	11	28

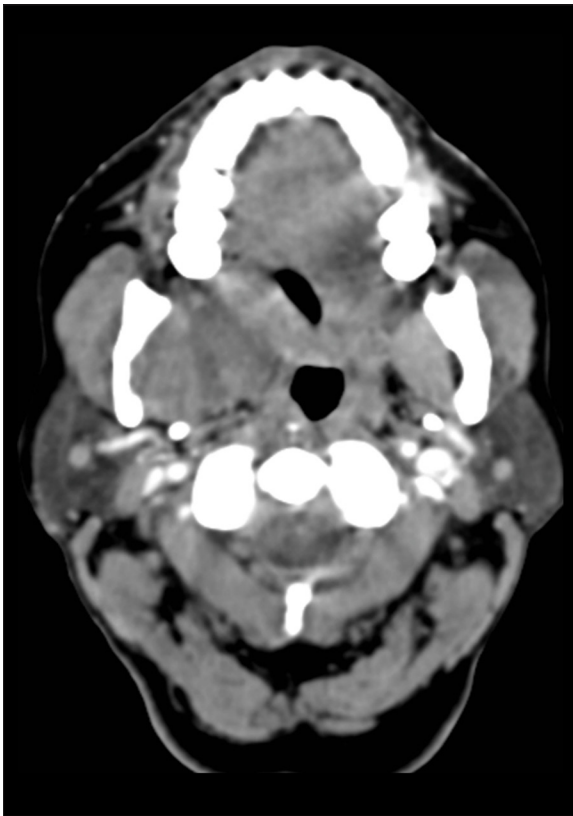


Figure 3. Ill-defined heterogeneous mass (squamous cell carcinoma) in the right masseteric space and retromolar trigone region in a patient presenting with difficulty in swallowing.

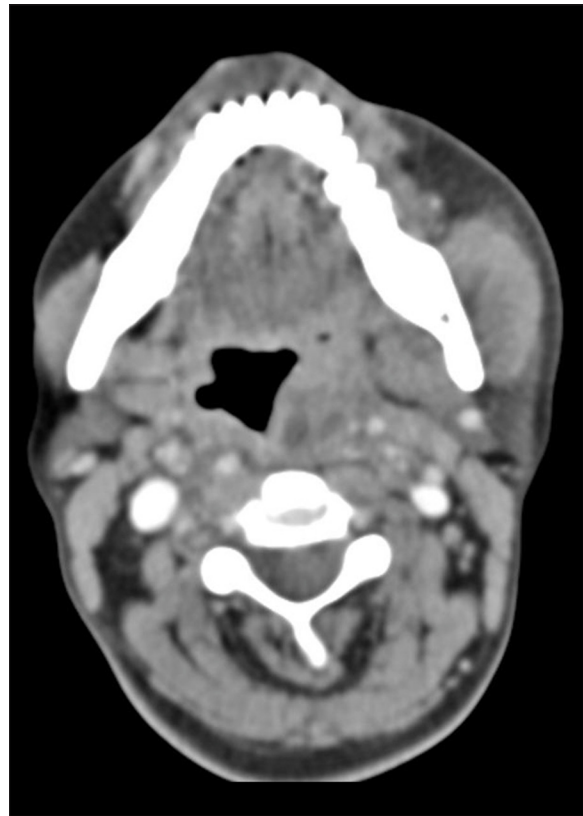


Figure 5. Low-attenuating collections with a rim enhancement in the left tonsillar fossa (abscesses) in a patient presenting with fever, sore throat and painful swelling. The mass is causing a bulge in the medial wall of oropharynx and displacing the parapharyngeal space laterally.

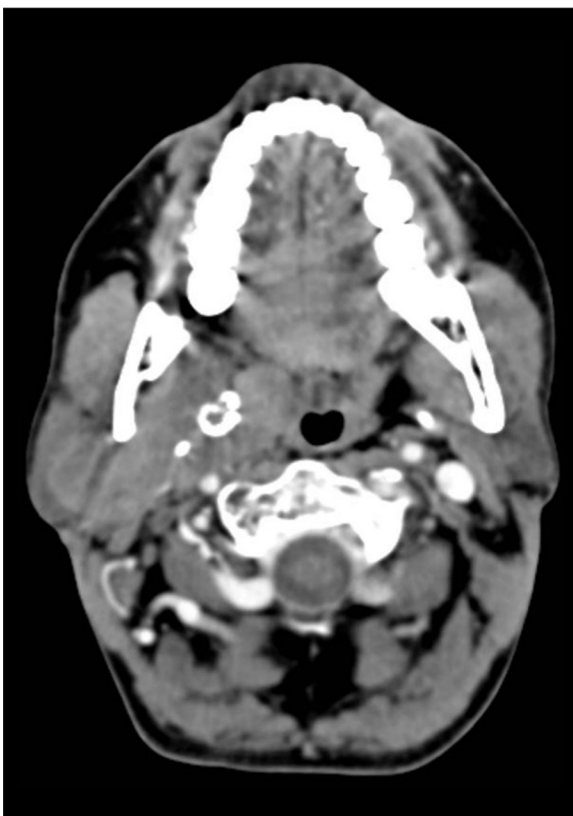

Table 2. Table showing the most common pathology in each suprahyoid neck space.

Space	Most common pathology
Pharyngeal mucosal space	Sq. cell carcinoma
Parotid space	Pleomorphic adenoma
Prestyloid parapharyngeal space	Squamous cell carcinoma
Carotid space	Malignant LAP
Masticator space	Sq. cell ca.
Retropharyngeal space	Malignancy and abscess
Prevertebral space	Abscess

Figure 4. Well-defined, marginated enhancing mass in the right parotid gland (pleomorphic adenoma) extending through the widened stylomandibular tunnel into the right prestyloid parapharyngeal space. Areas of coarse calcification are seen in the deep part. It is causing a mild deviation of the oropharyngeal airway to the left.

Table 3. Table showing CT features of different pathologies in their respective spaces.

Space	Well defined margins	Enhancement	Necrosis	Calcification
Pharyngeal mucosal space	4	16	14	–
Parotid	10	11	4	1
Parapharyngeal space	6	8	6	1
Carotid space	2	4	4	–
Masticator space	3	6	6	–
Retropharyngeal space	2	4	4	–
Prevertebral space	2	2	2	–
Total	29	51	40	2

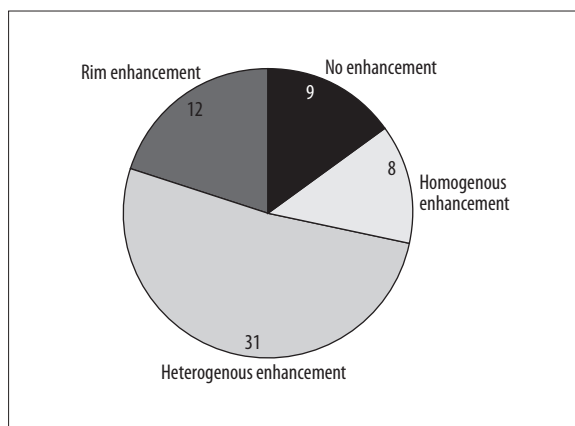


Figure 6. Pie diagram showing the pattern of enhancement of suprahyoid masses on contrast-enhanced CT.

the 51–60 yrs of grouere no malignant cases reported in the age group of 1–30 years in the present study.

Key features of the suprahyoid masses appreciated on CT were margins, enhancement, necrosis and calcification (Table 3). Well-defined margins were seen in 29 cases, which

was indicative of a benign nature of the lesions. Contrast enhancement was seen in 51 cases, which was suggestive of tissue activity. In 40 cases, necrosis was visualized, which generally indicated malignancy or inflammatory changes. The enhancement pattern of the lesions gave valuable evidence (Figure 6) in characterising the lesions in the suprahyoid region. Of 60 cases, 51 showed enhancement with the highest number of cases exhibiting heterogeneous enhancement, which usually indicated malignancy. Abscesses were diagnosed with the imaging features of low attenuation collections surrounded by enhancing walls (rim enhancement). The rim enhancement (12 cases) or homogenous enhancement (8 cases) usually implied the nign nature of the disease.

In all the 60 patients presenting with suprahyoid neck masses, a provisional diagnosis was made based on clinical findings and CT morphology/characteristics of the mass. The final diagnosis was made on the basis of operative or histo/cytopathological analysis whenever feasible. In the present study, 28 patients were given provisional diagnosis of malignant aetiology on CT, which was further confirmed on histopathology. There was an agreement between CT and histopathological diagnosis in the majority of cases (Table 4), except for two cases. One case diagnosed on CT

Table 4. Table showing comparison of CT findings with final histopathological diagnosis.

Lesion	CT diagnosis	Final histopathological/intraoperative diagnosis
Pleomorphic adenoma	8	7
Lipoma	2	2
IJV thrombosis	1	1
Abscess	15	14
Branchial cleft cyst	2	3
Lymphangioma	1	1
Ameloblastoma	1	1
Juvenile angiofibroma	1	1
Primary & secondary malignancy	20	20
Metaststic lymphadenopathy	7	7
NHL	1	1

as pleomorphic adenoma was found to be mucoepidermoid carcinoma on histopathological analysis. The one case of brachial cleft cyst was misdiagnosed on CT as an abscess.

Of 60 cases of suprahyoid neck masses, the incidence of abscesses in this study was 23.3%, and out of 14 cases the highest number of abscesses was found in PMS (4 cases). The second most common space was PPS, and the lowest percentage of abscesses of 7.1% was seen in the parotid space, i.e. 1 out of 14 lesions. We observed four varieties (10 cases; 16.67%) of parotid space tumours in the present study, with the most common type being pleomorphic adenoma, i.e. 6 out of 10 cases. Out of total 10 tumours of the parotid gland, 7 were of benign nature and 3 were malignant. The ratio of benign parotid tumours in males to females was 1: 2.5, and in malignant parotid cases the male to female ratio was 2: 1. In this study, pleomorphic adenoma was the second most common tumour after squamous cell carcinoma. Out of total 28 malignant tumours, 23 were found in males and only 5 tumours in females, clearly showing the male preponderance. Most of the malignant cases were of squamous cell carcinoma. The male to female ratio for the malignant aetiology was 4.6: 1. Ipsilateral nodal involvement was observed in the majority of malignant lesions. The majority of the involved lymph nodes were distributed in the vicinity of the lymph nodal drainage site of the lesions. Necrosis and post-contrast enhancement were seen in malignant nodes in contrast to benign ones. The sensitivity of CT in detecting malignant lesions was 96.4% with a specificity of 100%, positive predictive value of 100% and a negative predictive value of 91.67%.

Discussion

In the last few years, MR imaging has been regarded as the technique of choice for suprahyoid neck masses due to better soft tissue and contrast resolution in addition to no ionizing radiation exposure. Latest innovations in CT imaging, for example isotropic imaging and multiplanar reconstructions, have enhanced the role of CT in the evaluation of head and neck lesions. Furthermore, CT has been shown to be more precise in bone assessment [1–5]. Computed tomography (CT) has the ability of outlining the exact location of a neck mass in a particular space outlined by neck fascias and its influence on adjacent structures. Such a “spatial approach” also restricts the differential diagnosis to an exclusive set of pathological processes specific to each anatomic space [6,7]. In the present study, CT assessment was done in 60 patients with suprahyoid neck masses of diverse pathologies. Typical CT features of these pathologies were evaluated and correlated with the histopathological findings as well as with studies done in the past, as this approach might help to achieve better management of patients with suprahyoid masses. A wide variability of suprahyoid neck masses was seen because of the diverse aetiologies of neck masses and their varied age of presentation.

The most common age group in the present study was 41–50 years ($n=18$), followed by 51–60 years ($n=15$). The majority of cases were between 41–60 yrs of age, which was similar to the study done by Shreshtha et al. [8]. Gupta et al. [9], in their study with 45 patients presenting

with neck masses, affirmed that male to female ratio was 1.8: 1, while in our study the male to female ratio was 2: 1. However, in the case of parotid space masses, females exceeded males as pleomorphic adenoma was the most common lesion and was predominantly seen in females, which is in agreement with the published literature [10–12]. In the present study with 60 cases of suprahyoid neck masses, the bulk of lesions were seen in the pharyngeal mucosal space, followed by the parotid space. The third most common space was the prestyloid parapharyngeal space and then masticator space, which was comparable to the results of the study done by Semnic et al. [13]. In the present study, the most common lesions were of malignant aetiology ($n=28$, 46.6%), amongst which squamous cell carcinoma ($n=23$) had the maximum incidence of 38.3%. The second most common lesions were inflammatory, i.e. 28.3%. The benign and congenital masses were the third most common lesions and comprised 23% of the total suprahyoid neck space lesions. In another study on neck masses done by Tanriverdi et al. [14], out of 981 cases, 485 (49.5%) had masses of neoplastic origin, whereas 383 (39%) had inflammatory masses and 113 patients (11.5%) had congenital neck lesions.

In the present study, squamous cell carcinoma was the most common pathology in the PMS (62.5% of the cases), while in the parotid space the pleomorphic adenoma was the most common lesion. In PPS, the most common lesion was squamous cell carcinoma, while in the carotid and masticator spaces the most common lesion was of malignant aetiology. Similar data have already been documented in the published literature [1,15]. In the retropharyngeal space, the most common aetiologies in our study were malignancy and inflammatory, both being 40%. In the study done by Davis et al. [16] in 39 patients with retropharyngeal space lesions, it was showed that the incidence of malignant lesions was 43.5%, which was comparable to our study, however, the incidence of inflammatory lesions was lower with only 23%. This difference could be attributed to a higher prevalence of infections in the Indian subcontinent as compared to the West.

Abscesses demonstrated typical features on CT as low-density fluid collections with enhancing walls. CT detected abscesses with 100% accuracy in all patients with a clinical suspicion of neck mass of infectious aetiology. The most common space with abscess formation was PMS, comprising 26% of all cases, followed by PPS in which 20% of total cases of abscesses were seen, similarly to previous studies [17,18] which affirmed that the most often infected neck space was the peritonsillar space (42.9% of cases). In the present study, out of 10 parotid gland tumours, 6 were pleomorphic adenomas, 1 was benign lipomatosis and 3 were malignant tumours. The incidence of pleomorphic adenoma was around 60% out of all parotid tumours and malignant tumours were 3 out of 10 with an incidence of 30%. The results of our study were comparable to the study done by Choi et al. [19], which found that out of 64 patients with salivary gland tumors 35 cases were pleomorphidenomas, 9 cases were warthin's tumours and the remaining 20 cases malignant tumours of the salivary glands. Similar findings were seen in an another study, which showed that out of 30 parotid gland tumors, 19 were benign pleomorphic

adenomas and the rest were malignant tumors, i.e. 63% pleomorphic adenomas and 36% malignant lesions [20].

All the malignant masses of PMS were seen in males, however, females were more likely to have inflammatory lesions. The most common age group was 51–60 yrs (46.62%) in malignant lesions, and slightly younger in the inflammatory pathologies of the suprahyoid neck spaces. Past studies [21,22] have revealed that squamous cell carcinoma is five times more common in men than in women, and mainly patients in the age group of 50 to 60 years are affected. The nature of the lesion predicted by computed tomography correlated well with surgical findings in this study, which was similar to the study done by Gupta et al. [9] in which CT correctly predicted the benign or malignant nature of lesions in 33/34 patients. Except for two cases, there was an agreement between CT and histopathological diagnosis in the remaining cases. One case diagnosed on CT as pleomorphic adenoma was found to be mucoepidermoid carcinoma, possibly due to its atypical appearance. The one case of brachial cleft cyst was diagnosed on CT as an abscess due to an older age at presentation and infected contents of the cyst.

In a 9-month-old infant, CT revealed poorly circumscribed, multiloculated, homogenous fluid attenuation masses diagnosed as a lymphangioma (cystic hygroma). However, considering the age of the patient, CT should be avoided due to a high radiation exposure. Ultrasound is an alternative modality in these patients, as it can very well differentiate between solid and cystic masses with no ionizing radiation exposure to the patient. However, it has poor soft tissue resolution and limited fields of view. The relationship between cystic hygroma and surrounding soft tissues of the

neck is best exhibited with MR imaging due to superior soft tissue and contrast resolution [1–5].

Lipomas are easily recognized on CT scans because of their typical negative HU value and non-enhancing pattern on post-contrast images. Two histopathologically confirmed cases of lipoma were seen in the present study. In another retrospective imaging study [23], of 24 patients with histopathologically proven lipomas, it was concluded that all patients were correctly diagnosed preoperatively on CT. Cervical lymph nodal metastases have a key impact on the prognosis of patients with head and neck tumours. In the present study, 7 cases were identified to have malignant LAP with central necrosis and were confirmed to be squamous cell carcinoma deposits on histopathology. Likewise, Connor et al. [24] stated that diagnostic imaging is better than clinical staging in revealing malignant cervical lymphadenopathy. Grouping of enlarged lymph nodes in the drainage chain of a tumour is an additional indicator of metastatic disease. The most precise CT predictor of metastasis is central necrosis, which has been documented to have 100% specificity. On CT, necrosis is visualized as a central area of low attenuation surrounded by a thick irregular rim of enhancement, as was seen in our study [25–28].

Conclusions

Computed tomography plays a major role in the assessment of suprahyoid neck masses, since it has a superb correlation with post-operative histopathological findings.

Conflicts of interest

None.

References:

- Gamss C, Gupta A, Chazen JL, Phillips CD: Imaging evaluation of the suprahyoid neck. *Radiol Clin North Am*, 2015; 53: 133–44
- Harnsberger HR, Osborn AG: Differential diagnosis of head and neck lesions based on their space of origin. The suprahyoid part of the neck. *Am J Roentgenol*, 1991; 157: 147–54
- Lell M, Mantsopoulos K, Uder M, Wuert W: [Imaging of the head and neck region.] *HNO*. 2016; 64: 189–209 [in German]
- Forghani R: Advanced dual-energy CT for head and neck cancer imaging. *Expert Rev Anticancer Ther*, 2015; 15: 1489–501
- Shetty D, Jayade BV, Joshi SK, Gopalkrishnan K: Accuracy of palpation, ultrasonography, and computed tomography in the evaluation of metastatic cervical lymph nodes in head and neck cancer. *Indian J Dent*, 2015; 6: 121–24
- Tshering Vogel DW, Thoeny HC: Cross-sectional imaging in cancers of the head and neck: how we review and report. *Cancer Imaging*, 2016; 16: 20
- Galli F, Flor N, Villa C et al: The masticator space. Value of computed tomography and magnetic resonance imaging in localisation and characterisation of lesions. *Acta Otorhinolaryngol Ital*, 2010; 30: 94–99
- Shrestha MK, Ghartimagar D, Ghosh A: Diagnostic accuracy of computed tomogram in the evaluation of a neck mass. *J Nepal Med Assoc*, 2011; 51: 164–70
- Gupta P, Bhargava SK, Mehrotra G, Rathi V: Role of multislice spiral C.T. in the evaluation of neck masses. *Journal International Medical Sciences Academy*, 2013; 26: 51–54
- Prasad RS: Parotid Gland Imaging. *Otolaryngol Clin North Am*, 2016; 49: 285–312
- Borner U, Stow NW, Landis BN: Pleomorphic adenoma of the parotid gland. *Am J Med*, 2016; 129: e1–2
- Bogaert J, Hermans R, Baert AL: Pleomorphic adenoma of the parotid gland. *J Belge Radiol*, 1993; 76: 307–10
- Semnic R, Jovic R, Bogdanovic D, Zvezdin A: The value of magnetic resonance imaging in diagnosis and staging of supra-hyoid neck tumors. *Arch Oncol*, 2000; 8: 51–53
- Tanriverdi MH, Bakir S, Kınış V et al: Neck masses: Retrospective analysis of 981 cases. *Turkiye Klinikleri J Med Sci*, 2012; 32: 1267–72
- Yousem DM: Suprahyoid spaces of the head and neck. *Semin Roentgenol*, 2000; 35: 63–71
- Davis WL, Harnsberger HR, Smoker WRK, Watanabe AS: Retropharyngeal space: Evaluation of normal anatomy and diseases with CT and MR imaging. *Radiology*, 1990; 174: 59–6.
- Kawabata M, Umakoshi M, Makise T et al: Clinical classification of peritonsillar abscess based on CT and indications for immediate abscess tonsillectomy. *Auris Nasus Larynx*, 2016; 43: 182–86
- Al-Noury K, Lotfy A: Deep neck spaces radiology and review of deep neck infections at King Abdulaziz University Hospital. *Egyptian Journal of Ear, Nose, Throat and Allied Sciences*, 2010; 11: 69–73
- Choi DS, Na DG, Byun HS et al: Salivary Glands tumors: Evaluation with two-phase helical CT. *Radiology*, 2000; 214: 231–36
- Som PM, Biller HF, Lawson W et al: Parapharyngeal space masses: An updated protocol based upon 104 cases. *Radiology*, 1984; 153: 149–56
- Abraham J: Imaging for head and neck cancer. *Surg Oncol Clin N Am*, 2015; 24: 455–71
- Sadick M, Schoenberg SO, Hoermann K, Sadick H: Current oncologic concepts and emerging techniques for imaging of head and neck squamous cell cancer. *GMS Curr Top Otorhinolaryngol Head Neck Surg*, 2012; 11: Doc08

23. Abd El-Monem MH, Gaafar AH, Magdy EA: Lipomas of the head and neck: Presentation variability and diagnostic work-up. *J Laryngol Otol*, 2006; 120: 47–55
24. Connor SE, Olliff JF: Imaging of malignant cervical lymphadenopathy. *Dentomaxillofac Radiol*, 2000; 29: 133–43
25. Fu F, He A, Zhang Y et al: Dual-energy virtual noncontrast imaging in diagnosis of cervical metastasis lymph nodes. *J Cancer Res Ther*, 2015; 11: C202–4
26. Wang X, Zhao Y, Wu N et al: Application of single-source dual-energy spectral CT in differentiating lymphoma and metastatic lymph nodes in the head and neck. *Zhonghua Zhong Liu Za Zhi*, 2015; 37: 361–66
27. Fujita A, Buch K, Truong MT et al: Imaging characteristics of metastatic nodes and outcomes by HPV status in head and neck cancers. *Laryngoscope*, 2016; 126: 392–98
28. Sun J, Li B, Li CJ et al: Computed tomography versus magnetic resonance imaging for diagnosing cervical lymph node metastasis of head and neck cancer: A systematic review and meta-analysis. *Oncotargets Ther*, 2015; 8: 1291–313