

A Rare Case of Thrombotic Thrombocytopenic Purpura Caused by Pancreatitis and Clopidogrel

Authors' Contribution:
Study Design A
Data Collection B
Statistical Analysis C
Data Interpretation D
Manuscript Preparation E
Literature Search F
Funds Collection G

AEF 1 **Muhammad Shabbir Rawala**
E 2 **S. Tahira Shah Naqvi**
E 3 **Muhammad Yasir Khan**
AE 1 **Amr El Toukhy**

1 Department of Internal Medicine, Charleston Area Medical Center, Charleston, WV, U.S.A.
2 Department of Medicine, Jinnah Medical and Dental College, Karachi, Pakistan
3 Department of Medicine, Capitol Health Regional Medical Center, Trenton, NJ, U.S.A.

Corresponding Author: Muhammad Shabbir Rawala, e-mail: muhammad_rawala@hotmail.com
Conflict of interest: None declared

Patient: **Male, 71**
Final Diagnosis: **Thrombotic thrombocytopenic purpura**
Symptoms: **Abdominal and/or epigastric pain**
Medication: —
Clinical Procedure: —
Specialty: **General and Internal Medicine**

Objective: **Rare co-existence of disease or pathology**





Background: Thrombotic thrombocytopenic purpura is mostly characterized by symptoms and signs of hemolytic anemia, thrombocytopenia, renal impairment, fever and neurologic dysfunction. It is not always necessary to have all 5 characteristic symptoms, and presentations can vary. It can be congenital or acquired by any etiology that causes deficiency or dysfunction of ADAMST13 enzyme.

Case Report: We present a case of a 71-year-old man who presented to our hospital initially with abdominal pain. He was diagnosed with pancreatitis, and conservative management was started with pain control and hydration. During the hospital course, the patient developed anemia that was hemolytic in nature, acute kidney injury and thrombocytopenia. He was then diagnosed as having TTP secondary to pancreatitis with additive effect of clopidogrel, as he had recently been started on clopidogrel due to percutaneous coronary intervention. He was started on prompt treatment with plasma exchange and intermittent dialysis, and he achieved full recovery after that.

Conclusions: TTP is a potentially fatal disease with high mortality risk. It is judicious to recognize and have high suspicion of TTP being caused by such rare causes (pancreatitis and clopidogrel), as immediate recognition and treatment can enhance survival.

MeSH Keywords: **Acute Kidney Injury • Pancreatitis • Platelet Aggregation Inhibitors • Purpura, Thrombotic Thrombocytopenic • Thrombocytopenia**

Full-text PDF: <https://www.amjcaserep.com/abstract/index/idArt/911679>

 1002  1  1  17



Background

The first description of thrombotic thrombocytopenic purpura (TTP) came out in 1924 as the Moschcowitz syndrome. It was defined as, "A pathologic alteration of the microvasculature with detachment or swelling of the endothelium, amorphous material in the sub-endothelial space and luminal platelet aggregation leading to compromise of the microcirculation" [1]. Today it is recognized as a rare disorder, with an annual incidence of around 6 per million. [2] TTP has multiple and diverse etiologies, manifestations, associated conditions, and risk factors. This disease has a characteristic pentad of symptoms: microangiopathic hemolytic anemia (MAHA), neurologic changes, fever, thrombocytopenia, and renal dysfunction. TTP has been found to be fatal in 90% of cases if not promptly treated with plasma exchange, with the survival rate being 81% to 96% in those who were urgently diagnosed and treated [3]. TTP can be congenital (deficiency of ADAMTS13) or acquired. To the best of our knowledge, there are only a few case reports published describing the rare phenomenon of TTP induced by pancreatitis [2,4–10]. Swisher [9] reported that the expected incidence of coincidental occurrence of TTP and pancreatitis in the same year is 3.75 per 10⁹ population. Clopidogrel-induced TTP occurs at a frequency of approximately 4 per million patients [1]. In this report, we present a TTP case associated with clopidogrel intake as well as acute pancreatitis, both of which are considered very rare causes of TTP.

Case Report

A 71-year-old man with a history of coronary artery disease (s/p coronary artery bypass graft and recent cardiac catheterization), hypertension, and abdominal aorta aneurysm presented to the Emergency Department (ED) with complaints of a headache, nausea, vomiting, and abdominal pain. On examination, the patient had mild tenderness in the abdomen, but the overall exam was unremarkable.

Laboratory findings showed 321 U/L amylase, 4077 U/L lipase, 2.3 mg/dl creatinine, 27 mg/dl urea, 14.2 gm/dl hemoglobin (HB),

42.8% hematocrit (HCT), 12 600/mm³ white blood cell (WBC) count, and 178 000/mm³ platelets (PLT) (Table I). An ultrasound of the abdomen showed abdominal aortic aneurysm with no significant increase in size. A computed tomography (CT) scan of the abdomen demonstrated pancreatitis with inflammation surrounding the head (Figure 1).

After admission, in the subsequent days, the patient's urea increased to 77 mg/dl and creatinine to 6.0 mg/dl. There was a decrease in HB to 7.1 gm/dl, HCT to 21.5%, and platelets to 45 000 mm³. Workup was initiated for hemolytic anemia, showing lactate dehydrogenase of 797 U/L, total bilirubin of 4.4 mg/dl, direct bilirubin of 2.3 mg/dl, and haptoglobin of less than 8, and a peripheral smear examined by a hematologist found a schistocyte count of 1–3 per low-power field. The fibrinogen and coagulation profiles were normal.

Based on the laboratory data, the patient was labeled as having TTP, with findings of hemolytic anemia, thrombocytopenia, and renal impairment. TTP was likely induced by pancreatitis with or without the added effect of clopidogrel. Clopidogrel was temporarily held for a few days but was then restarted due to the risk of stent re-thrombosis. The patient was then started on plasmapheresis in addition to intermittent hemodialysis. Subsequently, after multiple sessions of plasmapheresis, the patient's PLT, urea, creatinine, and HB started to improve (Table 1). Clopidogrel was switched to Effient (prasugrel) at time of discharge.

Discussion

Thrombotic thrombocytopenic purpura (TTP) is a well-known and life-threatening disorder [11]. The etiologies of TTP include both congenital and acquired causes. The congenital cause of TTP is the deficiency or dysfunction of ADAMTS13 (a disintegrin and metalloproteinase with a thrombospondin type 1 motif, member 13), which leads to accumulation of ultra-large von Willebrand factor (VWF) molecules, subsequently causing VWF/platelet-rich microvascular thrombosis [10]. Most acquired causes are idiopathic, but some acquired causes may

Table 1. Comparison of laboratory data on admission, during hospitalization, and at discharge.

	At admission	Subsequent days	Discharge
Hemoglobin	14.2 gm/dl	7.1 gm/dl	9.2 gm/dl
Hematocrit	42.8%	21.5%	26.8%
Platelets	178 000/mm ³	45 000/mm ³	486 000/mm ³
Urea	27 mg/dl	77 mg/dl	32 mg/dl
Creatinine	2.3 mg/dl	6.0 mg/dl	2.8 mg/dl
White blood cells (WBC)	12 600/mm ³	12 600/mm ³	12 500/mm ³

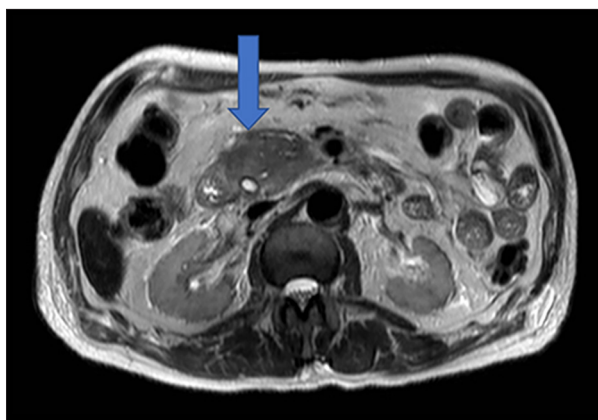


Figure 1. Computed Tomography (CT) scan demonstrating pancreatitis (arrow) with small cyst.

be secondary, including infections (e.g., hepatitis C, pneumonia, HIV, and sepsis), medications (e.g., mitomycin C), medical procedures (e.g., hematopoietic stem cell transplantation), and various underlying chronic diseases (e.g., malignancies, cirrhosis, connective tissue disorders, ulcerative colitis, diabetes mellitus, and hyperthyroidism).

The clinical presentations of TTP secondary to acquired etiologies can be highly variable [12]. Acute pancreatitis has been frequently listed as a consequence of TTP, but TTP recognized as a consequence of acute pancreatitis is very rare. Upon review of the literature, we found reports [2,4–10] suggesting that the underlying mechanism is the release of inflammatory cytokines as part of systemic inflammatory response incited by acute pancreatitis. It has been observed *in vitro* that inflammatory cytokines stimulate the endothelial cell release of ultra-large vWF multimers and inhibit their cleavage by ADAMTS13 [8,9]. Mayer et al. [13] found that cytokines peak at approximately day 3, but the timeline correlates with the temporal relationship between onset of pancreatitis and TTP, and is reported in the literature to be a median of 3 days [9].

References:

1. Cao L, Jones C, Movahed A: Low ADAMTS-13 in Plavix-induced thrombotic thrombocytopenic purpura. *World J Clin Cases*, 2013; 1(1): 31–33
2. Ali MA, Shaheen JS, Khan MA: Acute pancreatitis induced thrombotic thrombocytopenic purpura. *Indian J Crit Care Med*, 2014; 18(2): 107–9
3. Vesely SK, George JN, Lammler B et al: ADAMTS13 activity in thrombotic thrombocytopenic purpura-hemolytic uremic syndrome: Relation to presenting features and clinical outcomes in a prospective cohort of 142 patients. *Blood*, 2003; 102: 60–68
4. Gurjar M, Saigal S, Azim A et al: Acute pancreatitis-induced thrombotic thrombocytopenic purpura. *JOP*, 2012; 13: 80–82
5. Arimoto M, Komiyama Y, Okamae F et al: A case of thrombotic thrombocytopenic purpura induced by acute pancreatitis. *Int J Gen Med*, 2012; 5: 307–11
6. Jeliaskova P, Noe S, Jost P et al: Postendoscopic retrograde cholangiopancreatography pancreatitis: A rare cause of thrombotic thrombocytopenic purpura-hemolytic uremic syndrome. *Eur J Gastroenterol Hepatol*, 2011; 23: 825–27
7. Chaudhry MS, Saweirs MW: Thrombotic thrombocytopenic purpura precipitated by acute pancreatitis. *Transfus Apher Sci*, 2011; 45: 143–47
8. Bergmann IP, Kremer Hovinga JA, Lammler B et al: Acute pancreatitis and thrombotic thrombocytopenic purpura. *Eur J Med Res*, 2008; 13: 481–82
9. Swisher KK, Doan JT, Vesley SK et al: Pancreatitis preceding acute episodes of thrombotic thrombocytopenic purpura-hemolytic uremic syndrome: Report of five patients with a systematic review of published reports. *Haematologica*, 2007; 92: 936–43
10. McDonald V, Laffan M, Benjamin S et al: Thrombotic thrombocytopenic purpura precipitated by acute pancreatitis: A report of seven cases from a regional UK TTP registry *Br J Haematol*, 2009; 144(3): 430–33
11. Karkowski L, Wolf M, Lescamp J et al: A Clopidogrel induced thrombotic thrombocytopenic purpura *Rev Med Interne*, 2011; 32(12): 762–65
12. Fujimura Y, Matsumoto M: Registry of 919 patients with thrombotic microangiopathies across Japan: database of Nara Medical University during 1998–2008. *Intern Med*, 2010; 49(1): 7–15

Drugs are associated with <15% of all cases of TTP [14], with the pathogenesis most likely being immunologic [11]. The number of percutaneous coronary interventions (PCI) done is increasing globally. Generally, patients are placed on dual antiplatelet therapy after PCI, including aspirin and mostly clopidogrel. TTP caused by clopidogrel is a rare occurrence; therefore, clinicians should be vigilant of this rare, yet possible, adverse effect of clopidogrel. The time of occurrence of TTP is mostly within the first 2 weeks of initiation of clopidogrel, with a mortality rate of around 10–20% [15, 16]. Prompt treatment is imperative to avoid a fatal outcome [11]. Consideration should be given to changing the antiplatelet therapy (required after PCI) to the newer P2Y12 antagonist, especially in patients who have previously experienced clopidogrel-induced TTP [17].

Conclusions

Our case report highlights the short interval between the diagnosis of acute pancreatitis and the subsequent manifestations of TTP. Therefore, a high index of clinical suspicion is required to make an early diagnosis and allow early initiation of plasma exchange therapy, leading to a favorable outcome. It also highlights the importance of being aware of medications associated with TTP.

Department and Institution where work was done

Department of Internal Medicine, Charleston Area Medical Center, West Virginia University, Charleston, WV, U.S.A.

Conflict of interests

None.

13. Mayer J, Rau B, Gansauge F, Beger HG: Inflammatory mediators in human acute pancreatitis: Clinical and pathophysiological implications *Gut*, 2000; 47: 546–52
14. Scully M, Hunt BJ, Benjamin S et al: Guidelines on the diagnosis and management of thrombotic thrombocytopenic purpura and other thrombotic microangiopathies. *Br J Haematol*, 2012; 158: 323–35
15. Tsai HM, Rice L, Sarode R et al: Antibody inhibitors to von Willebrand factor metalloproteinase and increased binding of von Willebrand factor to platelets in ticlopidine-associated thrombotic thrombocytopenic purpura. *Ann Intern Med*, 2000; 132: 794–99
16. Bennett CL, Weinberg PD, Rozenberg-Ben-Dror K et al: Thrombotic thrombocytopenic purpura associated with ticlopidine. A review of 60 cases. *Ann Intern Med*, 1998; 128: 541–44
17. Patel H, Bress A, Shroff A: Personalizing oral antiplatelet therapy in PCI. *Cardiac Interventions Today* 2012; Sep/Oct: 20–27. Available from: https://citoday.com/pdfs/cit0912_pharma_Shroff.pdf