

Extranodal natural killer/T-cell lymphoma presenting as orbital cellulitis

Abstract

Objective: To report an aggressive case of extranodal natural killer/T-cell lymphoma (NKTCL) of the ethmoid sinus presenting as orbital cellulitis

Method: Case report

Results: A 56-year-old male presented with right eye redness, reduced vision, and periorbital swelling for 5 weeks duration associated with a two-month history of blocked nose. The visual acuity of the right eye was 6/18. The eye was proptosed with periorbital oedema and conjunctival chemosis. The pupil was mid-dilated but there was no relative afferent pupillary defect. The fundus was normal. The extraocular movements were restricted in all directions of gaze. Nasal endoscopy revealed pansinusitis that corresponded with CT scan orbit and paranasal sinuses findings. Despite treatment, he showed no clinical improvement. Ethmoidal sinus biopsies performed revealed extranodal NKTCL. Further imaging showed involvement of the right orbital contents and its adnexa with intracranial extension into the right cavernous sinus and meninges over right temporal fossa. The patient underwent chemotherapy. However he succumbed to his illness two months after the diagnosis.

Conclusion: Extranodal NKTCL is a great mimicker. This case demonstrated how an acute initial presentation of extranodal NKTCL can present as orbital cellulitis with pansinusitis.

Keywords: extranodal NK/T cell lymphoma, orbital cellulitis, sinusitis

Hanis Zuhaimy¹

Hayati Abdul Aziz¹

Suresh Vasudevan¹

Siah Hui Hui²

1 Ophthalmology Department,
Hospital Sultanah Aminah
Johor Bahru, Johor, Malaysia

2 Pathology Department,
Hospital Sultanah Aminah
Johor Bahru, Johor, Malaysia

Introduction

Extranodal natural killer T-cell lymphoma (NKTCL) is a rare form of non-Hodgkin lymphoma (NHL). It is highly invasive with an extremely aggressive course. It is commonly found in Asians, Mexicans and South Americans [1]. Majority of cases present in the nasal, nasopharynx and paranasal area. The diagnosis of extranodal NKTCL is often delayed and difficult due to its wide variety of non-specific sign and symptoms. We report an aggressive case of extranodal NKTCL of the ethmoid sinuses that presented as orbital cellulitis.

Case description

A 56-year-old Malay male presented with progressive right eye periorbital swelling, eye redness and blurring of vision for 5 weeks duration. His symptoms were preceded by a 2-month history of persistent nose block.

On examination, the right eye was proptosed. The upper and lower eyelids were swollen and erythematous with conjunctival chemosis (Figure 1). His visual acuity was 6/18 and 6/9 on the right and left eye respectively. The right pupil was mid-dilated but there was no relative afferent pupillary defect. The intraocular pressure of the right eye was 28 mmHg and the extraocular movements were

restricted in all directions of gaze. The anterior segment and funduscopy examination were unremarkable. He was febrile with temperature of 38.5 °C. Cranial nerves were normal and there were no palpable cervical, inguinal or axillary lymph nodes.

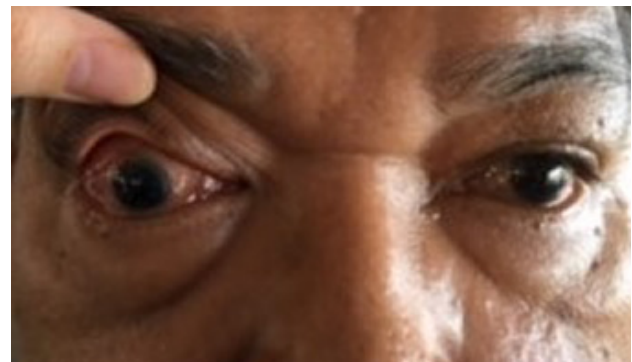

Figure 1: Conjunctival chemosis and proptosis of the right eye

Computed tomography (CT) scan of the orbit and paranasal sinuses (Figure 2) revealed right periorbital soft tissue swelling and enhancement with enlargement of the right lacrimal gland. The right extraocular muscles were bulkier compared to the left with fat streakiness in the extra and intraconal spaces. There was soft tissue density within the frontal sinuses, ethmoidal air cells, and mucosal thickening in both maxillary sinuses with evi-

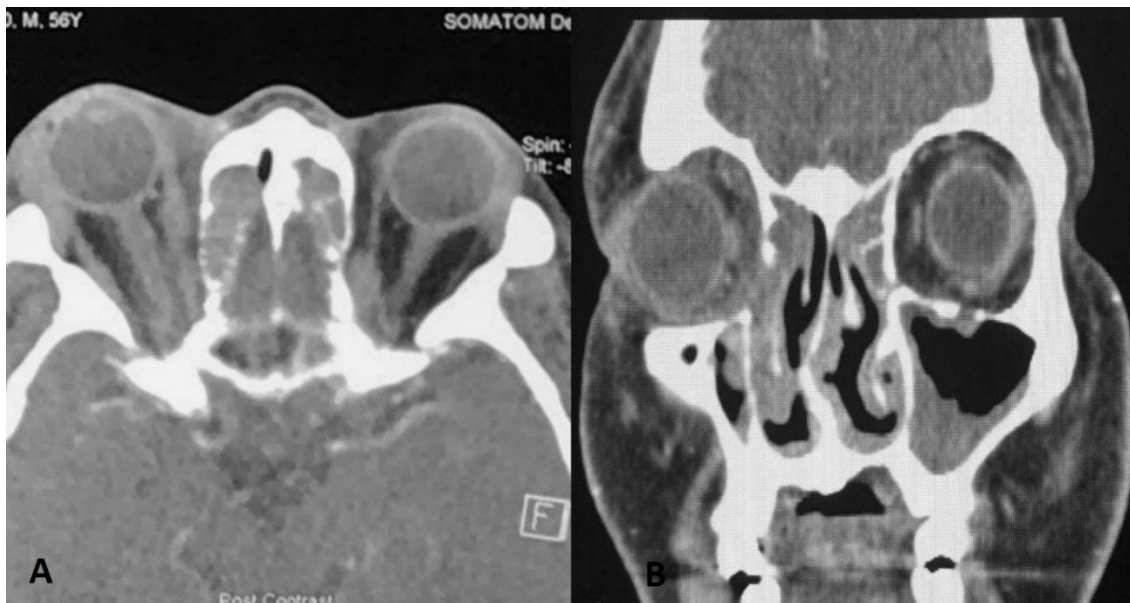

Figure 2: CT scan imaging of the orbit and paranasal sinuses: A) Axial view (left) demonstrated right periorbital soft tissue swelling with right extraocular muscle bulkier compared to left side. There was enlargement of the right lacrimal gland. Soft tissue density was seen within ethmoidal air cells. B) Coronal view (right) demonstrated soft tissue density in the frontal sinus, ethmoidal air cells and mucosal thickening in both the maxillary sinuses with obliteration of both osteomeatal complex. There was erosion of the right lamina papyracea.

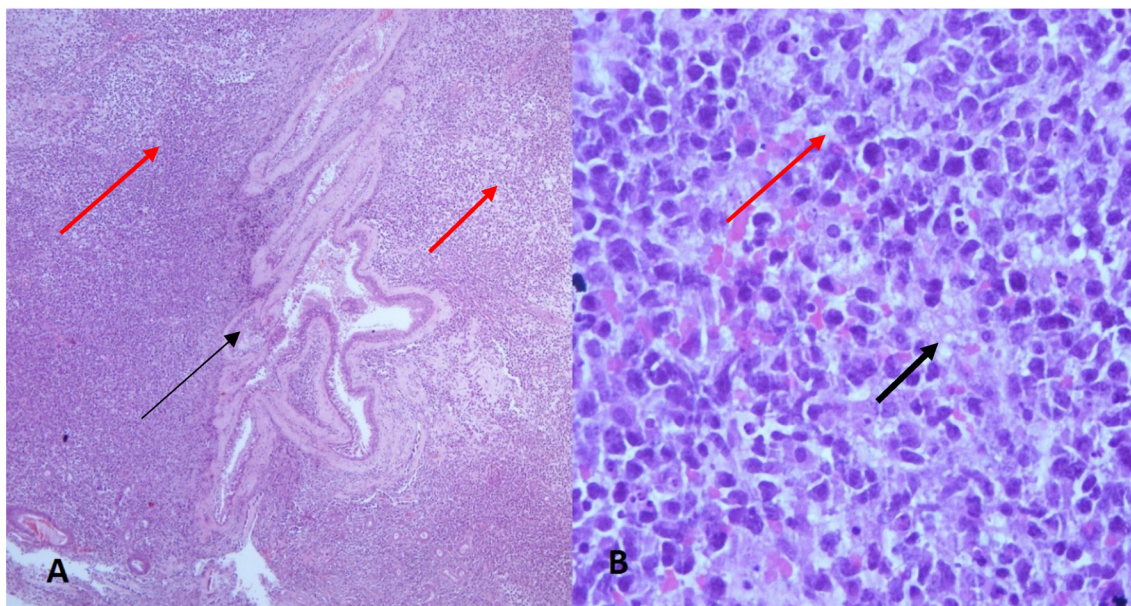


Figure 3: Ethmoid sinus biopsy specimen A: H&E stain (100x) showed a piece of lymphoid tissue covered by respiratory epithelium (black arrow) and the stroma was densely infiltrated by neoplastic lymphoid cells (red arrows) B: H&E stain (400x) showed dense infiltration of the stroma with neoplastic lymphoid cells. There were prominent scattered areas of necrosis and apoptotic bodies seen (black arrow).

dence of erosion of the right lamina papyracea. Both osteomeatal complexes were obliterated. The nasal endoscopy findings showed deviated nasal septum to the right, mucinous discharge from posterior ethmoid sinus in the right nostril with obliteration of osteomeatal complex in both nostrils suggestive of pansinusitis. No evidence of tumour or polyp was seen.

The patient was diagnosed as orbital cellulitis secondary to pansinusitis. Intravenous amoxicillin/clavulanic acid, nasal decongestants, and anti-histamine were com-

menced. Culture and sensitivity of the ethmoid sinuses grew *Klebsiella pneumoniae*. However, despite a week of treatment the patient showed no clinical improvement. An urgent functional endoscopic sinus surgery (FESS) and paranasal sinus biopsies were performed as there was suspicion of an underlying sinister pathology. Histopathological specimens of the ethmoidal tissues (Figure 3) revealed multiple fragments of fibrocollagenous tissue focally covered by respiratory epithelium containing seromucinous glands. The stroma was densely infiltrated

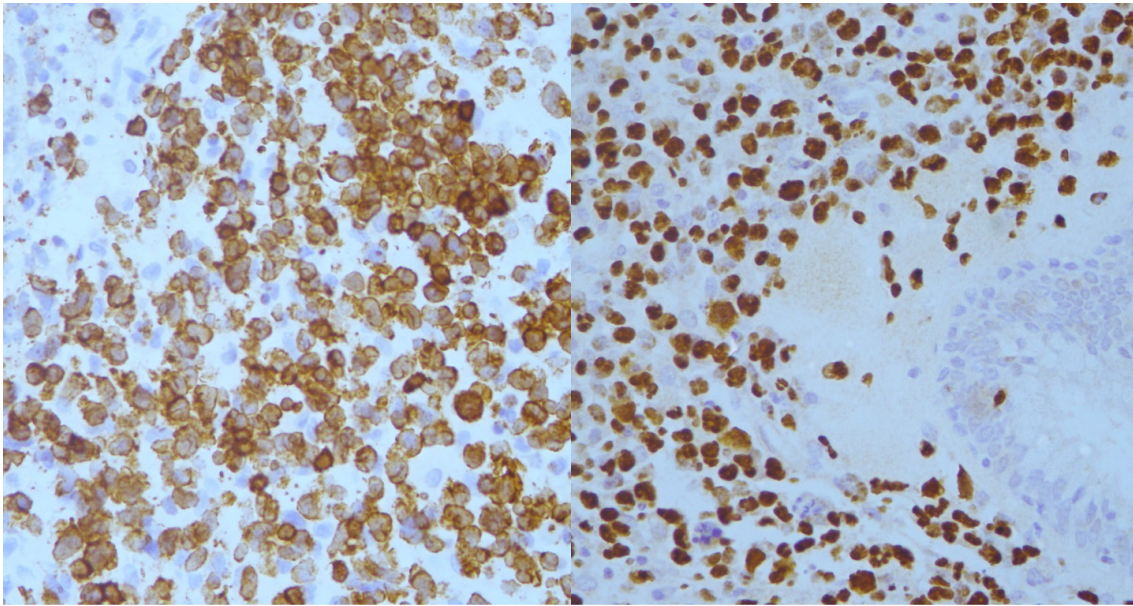


Figure 4: Immunohistochemical staining showed positivity for CD3 (left) and in-situ hybridization for EBV encoded RNA (right).

by neoplastic lymphoid cells with areas of necrosis. Immunohistochemical staining were positive for CD3, TIA, EBER-ISH and negative for CD20, CD10, tdt, cyclin-D1, CD4, CD8, CD5, CD30 and ALK (Figure 4). The Ki-67 proliferative index was high (~60–70%). These findings were suggestive of an aggressive extranodal NK/T-cell lymphoma.

The patient subsequently was subjected to further imaging and work out for staging purposes. Magnetic resonance imaging of brain, and orbit showed involvement of the right recti muscles, lacrimal gland, optic nerve and orbital fat with intracranial extension to the cavernous sinuses and meninges over right temporal fossa. Bone marrow biopsy showed evidence of infiltration with abnormal lymphoid cells which were positive for TIA, CD3, Ki67 and negative for CD56 and CD20. Lumbar puncture showed numerous lymphoid cells in the cerebrospinal fluid indicating central nervous system (CNS) infiltration. The patient was diagnosed with stage IV extranodal NK/T-cell lymphoma with CNS involvement. He underwent SMILE chemotherapy (dexamethasone, methotrexate, ifosfamide, L-asparaginase, etoposide). However he succumbed to his death within one month of chemotherapy, approximately 2 months after the diagnosis of extranodal NKTCL.

Discussion

Extranodal natural killer/T-cell lymphoma (NKTCL) is a rare form of non-Hodgkin lymphoma (NHL). The tumour is derived from natural killer cells and/or cytotoxic T-lymphocytes. It accounts for only 7–10% of Non-Hodgkin lymphomas in Asia and Central America [1]. In the Asian population, it is more commonly found among the Chinese, Japanese and Koreans [2]. The disease has an unknown etiology but has been postulated to be caused by the Epstein Barr virus (EBV) infection [3].

Extranodal NKTCL is a great mimicker. Due to its wide variety of non-specific sign and symptoms the diagnosis is often delayed and difficult. It commonly presents in the nasal, nasopharynx and paranasal area in 70% of cases [3], [4]. Typically the disease presents with midline destruction of the nasal cavity, paranasal sinuses and nasopharynx giving rise to common symptoms such as nasal obstruction (87%), purulent nasal discharge (73%), and epistaxis (60%) [3]. Other possible extranasal sites include skin, breast, testis or gastrointestinal tract [4], [5].

Our patient first presented with orbital and concurrent sinonasal involvement. Cases of extranodal NKTCL with orbital and sinonasal involvement masquerading as orbital cellulitis with similar findings as our patient had been reported [6], [7], [8], [9], [10]. Orbital involvement is usually a result of extension or invasion from the nasal cavity and paranasal sinuses with or without bony erosion [4]. However, Woog et al. reported three out of eight cases of extranodal NKTCL had only orbital, adnexa, and/or ocular involvement [10].

Orbital cellulitis secondary to pansinusitis was diagnosed in our patient based on the clinical signs and symptoms supported by imaging and nasal endoscopy findings. In addition, ethmoid tissue C&S also revealed *Klebsiella pneumoniae* infection. Our patient showed no response to the conventional treatment of orbital cellulitis leading to a suspicion of other underlying sinister pathology. Hence an urgent histopathological study was warranted. Extensive necrosis of the sinuses in pansinusitis are often misinterpreted as an infectious process rather than extranodal NKTCL superimposed with infection [7]. This was demonstrated in our patient's CT report and nasal endoscopy finding. Due to the nature of the disease that is characterized by angioinvasion and midline destruction, biopsies for extranodal NKTCL are most of the time inconclusive. Histopathological findings often show prominent necrosis and mixture of inflammatory cells [7]. Previous

Table 1: Ann Arbor staging for lymphoma

Stage	Definition
I	Involvement of a single lymph node region
II	Involvement of two or more lymph node regions on the same side of the diaphragm (the mediastinum is a single site, hilar lymph nodes are each counted as a site)
III	Involvement of several lymph node regions on both sides of the diaphragm
E designation when applicable, to stages I, II or III	Extranodal disease contiguous to lymph node involvement that can be encompassed within an irradiation field; different from the disseminated nature of stage IV disease
IV	Diffuse or disseminated foci of involvement of one or more extralymphatic organs or tissues, with or without associated lymphatic involvement
Symptoms	
A	No symptoms
B	At least one of the following symptoms <ul style="list-style-type: none"> - Unexplained weight loss of >10% of body weight during the 6 months before staging investigation - Unexplained fever with temperatures >38°C for at least 7 days - Drenching night sweats

case reports have highlighted the importance of adequate initial biopsies and repeated biopsies to diagnose extranodal NKTL [6], [8]. We managed to arrive at an early diagnosis in our patient due to multiple tissue biopsies taken from the ethmoid sinuses.

Despite an early diagnosis, our patient unfortunately was found to be at an advanced stage of the disease. He was diagnosed with extranodal NKTCL stage IV with central nervous system involvement according to the Ann Arbor classification for staging of lymphoma (Table 1). SMILE chemotherapy was commenced. However he succumbed to his illness after 2 months of diagnosis.

Current treatment strategies for extranodal NKTCL depend on extent and stage of disease. According to the Ann Arbor classification, the disease can be classified into four stages [11]. Localised disease (stage I/II) is treated with chemotherapy and radiotherapy while disseminated disease (stage III/IV) is given combined chemotherapy. The prognosis of extranodal NKTCL described in literature varies, but generally the disease is rapidly progressive with poor prognosis and short survival times from the time of diagnosis. It has a high mortality rate and low response to chemotherapy and radiotherapy in comparison to other subtypes of neck and head lymphomas with an average survival of 12.5 months after diagnosis [7]. Seven out of eight patients with extranodal NKTCL in a cases series by Woog et al. died 5 weeks to 13 months after presentation and only one survived with no evidence of disease at 5 years after treatment [10]. Meanwhile another literature review found median survival for 26 patients with nasal-type NK/T cell lymphoma was only 7.4 months [12].

In conclusion, extranodal NKTCL is highly invasive and has an aggressive course. The prognosis is poor with a high mortality rate. This case demonstrated how an acute initial presentation of extranodal NKTCL nasal type can present as orbital cellulitis with pansinusitis. A non-responsive orbital cellulitis and sinusitis to conventional therapy should alert the ophthalmologist to the possibility of extranodal NKTCL.

Notes

Acknowledgment

We would like to thank our colleagues in the Department of Ophthalmology, Hospital Sultanah Aminah Johor Bahru for their support.

Competing interests

The authors declare that they have no competing interests.

References

1. Kwong YL. The diagnosis and management of extranodal NK/T-cell lymphoma, nasal-type and aggressive NK-cell leukemia. *J Clin Exp Hematop.* 2011;51(1):21-8. DOI: 10.3960/jslr.51.21
2. Liang Q, Ye ZY, Su ZL, Lin HL, Shao CK, Lin SX, Rao HL, Mei KY, Zhao T, Liu YH, Luo DL, Zhu MG, Chen SH, Lin TY. [Clinicopathologic study of 963 cases of mature T-cell and natural killer/T-cell lymphoma with respect to 2008 WHO classification of lymphoid neoplasms]. *Zhonghua Bing Li Xue Za Zhi.* 2010 May;39(5):291-5.
3. Tababi S, Kharrat S, Sellami M, Mamy J, Zainine R, Beltaief N, Sahtout S, Besbes G. Extranodal NK/T-cell lymphoma, nasal type: report of 15 cases. *Eur Ann Otorhinolaryngol Head Neck Dis.* 2012 Jun;129(3):141-7. DOI: 10.1016/j.anorl.2011.08.004
4. Jimnez-Prez JC, Yoon MK. Natural Killer T-Cell Lymphoma of the Orbit: An Evidence-Based Approach. *Semin Ophthalmol.* 2017;32(1):116-124. DOI: 10.1080/08820538.2016.1228405
5. Wood PB, Parikh SR, Krause JR. Extranodal NK/T-cell lymphoma, nasal type. *Proc (Bayl Univ Med Cent).* 2011 Jul;24(3):251-4.
6. Termote K, Dierickx D, Verhoef G, Jorissen M, Tousseyn T, Mombaerts I. Series of extranodal natural killer/T-cell lymphoma, nasal type, with periorbital involvement. *Orbit.* 2014 Aug;33(4):245-51. DOI: 10.3109/01676830.2014.902478
7. Pine RR, Clark JD, Sokol JA. CD56 negative extranodal NK/T-cell lymphoma of the orbit mimicking orbital cellulitis. *Orbit.* 2013 Feb;32(1):45-8. DOI: 10.3109/01676830.2012.736603

8. Charton J, Witherspoon SR, Itani K, Jones FR, Marple B, Morse B. Natural killer/T-cell lymphoma masquerading as orbital cellulitis. *Ophthal Plast Reconstr Surg.* 2008 Mar-Apr;24(2):143-5. DOI: 10.1097/IOP.0b013e3181659867
9. Kim JW, An JH. Extranodal natural killer/T-cell lymphoma, nasal type, of the orbit mimicking recurrent orbital cellulitis. *J Craniofac Surg.* 2014 Mar;25(2):509-11. DOI: 10.1097/SCS.0000000000000677
10. Woog JJ, Kim YD, Yeatts RP, Kim S, Esmaeli B, Kikkawa D, Lee HB, Korn BS, Punja K, Habermann TM, Colgan JP, Salomao D, Cameron JD. Natural killer/T-cell lymphoma with ocular and adnexal involvement. *Ophthalmology.* 2006 Jan;113(1):140-7. DOI: 10.1016/j.ophtha.2005.09.036
11. Armitage JO. Staging non-Hodgkin lymphoma. *CA Cancer J Clin.* 2005 Nov-Dec;55(6):368-76. DOI: 10.3322/canjclin.55.6.368
12. Lee J, Kim WS, Park YH, Park SH, Park KW, Kang JH, Lee SS, Lee SI, Lee SH, Kim K, Jung CW, Ahn YC, Ko YH, Park K. Nasal-type NK/T cell lymphoma: clinical features and treatment outcome. *Br J Cancer.* 2005 Apr;92(7):1226-30. DOI: 10.1038/sj.bjc.6602502

Corresponding author:

Hanis Zuhaimy
Department of Ophthalmology, Hospital Sultanah Aminah,
Jalan Persiaran Abu Bakar Sultan, 80100 Johor Bahru,
Johor, Malaysia, Phone: +6072257000
hanis_zuhaimy@hotmail.com

Please cite as

Zuhaimy H, Aziz HA, Vasudevan S, Hui Hui S. Extranodal natural killer/T-cell lymphoma presenting as orbital cellulitis. *GMS Ophthalmol Cases.* 2017;7:Doc04.
DOI: 10.3205/oc000055, URN: urn:nbn:de:0183-oc0000556

This article is freely available from

<http://www.egms.de/en/journals/oc/2017-7/oc000055.shtml>

Published: 2017-02-06

Copyright

©2017 Zuhaimy et al. This is an Open Access article distributed under the terms of the Creative Commons Attribution 4.0 License. See license information at <http://creativecommons.org/licenses/by/4.0/>.