



Case report

Severe complications from anastomotic leakage after total mesorectal excision with the protective loop ileostomy in three patients

Qizhi Liu^{a,1}, Minjun Zhou^{a,1}, Zhuo Chen^{a,1}, Junyi Chen^a, Dehua Zhou^a, Cheng Xin^b, Xiaohuang Tu^{a,*}

^a Department of Gastrointestinal Surgery, Shanghai Fourth People's Hospital, Tongji University, Shanghai 200434, China

^b Department of Colorectal Surgery of Changhai Hospital, Naval Medical University, Shanghai 200433, China

ARTICLE INFO

Keywords:

Anastomotic leakage
Abdominal infection
Protective loop ileostomy

ABSTRACT

Introduction and importance: A protective loop ileostomy is recommended in ultra-low rectal cancer to reduce the complications associated with anastomotic leakage (AL), but there are few studies on the complications after AL. The purpose of this study was to outline our experience in the successful treatment of severe abdominal infection after AL in rectal cancer patients with the protective loop ileostomy.

Case presentation: In this report, we describe three cases of AL after standard total mesorectal excision with the protective loop ileostomy. Severe abdominal infection occurred postoperatively. The patients were successfully treated by surgical reoperation and had an uneventful recovery. No recurrence was observed after 2 years.

Clinical discussion: We consider that pelvic floor reconstruction and extending the extubation time should be performed in patients with a high risk of AL. Moreover, when severe abdominal infection and early infectious shock occur after AL, immediate reoperation should be performed to minimize the complication.

Conclusion: Protective loop ileostomy can't decrease the re-operation rate for patients with AL. We should take preventive measures during and after the operation, as well as early detection and early treatment.

1. Introduction

Surgical treatment of ultra-low rectal cancer with preserved anal function often involves the routine formation of the protective loop ileostomy. It has been established that a protective loop ileostomy reduces the sequelae, but not the incidence of anastomotic leakage (AL) [1,2]. A protective loop ileostomy allows the leak to be treated conservatively and mitigates the clinical consequences of AL, to a certain extent, and reoperation is avoided [3]. A multicenter observational study reported that the rate of AL requiring surgical reoperation was reduced by the provision of a protective the protective loop ileostomy [4].

One hundred and seventy-nine rectal cancer patients that underwent total mesorectal excision (TME) surgery in Changhai Hospital between January 2014 and December 2017 were evaluated retrospectively. Of the 1079, 260 underwent protective loop ileostomy intent to protect the distal anastomosis. The incidence of clinically significant leakage after rectal anastomosis was 9%. No second operation is required after AL

occurs in most of patients with stoma. Here, we report three cases of AL after TME surgery with a protective loop ileostomy complicated with severe abdominal infection, where successful reoperation was performed.

The purpose of this retrospective study was to outline the details of the successful treatment of patients with clinical signs of severe abdominal infection after AL and the protective loop ileostomy. Valuable lessons were learned during the management of severe abdominal infection for patients with the protective loop ileostomy after AL.

2. Case presentation

2.1. Case 1

A 58-year-old man with diabetes mellitus was admitted due to hematochezia. Clinical examinations disclosed ultra-low rectal cancer with bilateral mesorectal lymph node metastasis. Preoperative tumor staging is cT₃N₂M₀. After 25 courses of radiotherapy plus Capecitabine,

* Corresponding author.

E-mail address: tuxiaohuang@126.com (X. Tu).

¹ Qizhi Liu, Minjun Zhou and Zhuo Chen contributed equally to this article.

magnetic resonance imaging (MRI) showed a partial response, and laparoscopic resection of rectal cancer with the protective loop ileostomy was performed. An end-to-end anastomosis was performed using EEA-28 circular stapling device. The abdominal drainage tube is placed at the lowest point of the pelvis. The pelvic floor was not reconstructed in this patient during surgery. The distance from the anal verge to the anastomosis was 2 cm. Postoperative pathological stage is ypT₃N₁M₀.

Anastomotic hemorrhage occurred on the first day after surgery, and was relieved by anal canal compression to stop bleeding through the anus. On the 4th postoperative day, finger examination of the anus was performed due to high fever and revealed a minor AL. As the patient had the protective loop ileostomy, conservative therapy was continued. Although irrigation of the abscess cavity was started from the 4th postoperative day, the abscess cavity did not get better. Computed tomography (CT) images of the area are shown in Fig. 1A. The patient's condition continued to deteriorate, with increased abdominal distension and labored breathing requiring intubation. Emergency surgery was performed on the 5th postoperative day. During the operation, a large amount of fecal ascites was found in the abdominal cavity, and there was a leak in the anastomosis. Abdominal irrigation was performed during surgery and an abdominal double cannula was placed in the anal canal. The patient was transferred to the intensive care unit (ICU) for secondary treatment. When the drainage was less than 5 mL, the drainage tube was removed. Following this successful treatment regimen, the patient was discharged. Hemoglobin changes in this patient and his corresponding treatment schedule are shown in Fig. 1B.

2.2. Case 2

A 50-year-old woman with cT₃N₀M₀ rectal cancer was referred to our hospital. Low anterior resection with the protective loop ileostomy was performed with open approach. An end-to-end anastomosis was performed with EEA-28 circular stapling device. This patient did not undergo pelvic floor reconstruction during surgery. The abdominal drainage tube is placed at the lowest point of the pelvis. The distance from the anal verge to the anastomosis was 3 cm. Postoperative pathological stage is pT₃N₀M₀.

Anastomotic hemorrhage occurred in the evening of the operative day, and was attenuated by colonoscopic hemostasis (Fig. 2A). Her hemoglobin dropped to 99 g/L, and improved following a blood transfusion. The patient was discharged 7 days after surgery. However, she experienced symptoms of high fever on the 8th postoperative day. Abdominal CT examination showed an intra-pelvic abscess due to AL. At that time, the drain had been removed. The patient was delayed more than 20 h on her way to hospital, and on arrival showed symptoms of infectious shock. Emergency irrigation of peritoneal cavity was

performed immediately. During the operation, a large amount of abdominal pus was found in the abdominal cavity. After the operation, this patient was transferred to the ICU for further treatment. During the postoperative period, she developed inflammatory response syndrome and multiple organ dysfunction syndrome. Following surgery, serum C-reactive protein (CRP) and procalcitonin levels gradually decreased. The patient was successfully discharged from hospital. Her hemoglobin changes and corresponding treatment are shown in Fig. 2B.

2.3. Case 3

A 55-year-old man diagnosed with ultra-low rectal cancer was admitted to our hospital. Preoperative tumor staging is cT₃N₀M₀. He underwent standard TME and the protective loop ileostomy with laparoscopic approach. An end-to-end anastomosis was performed using a surgical circular stapling device, and the proximal and distal donuts of transected tissue were inspected. The patient did not undergo pelvic floor reconstruction during surgery. A drainage tube was placed close to the anastomosis. Postoperative pathological stage is pT₃N₁M₀.

On the 1st postoperative day, the patient developed lower abdominal pain. Physical examination revealed tachycardia (130 bpm), pyrexia (greater than 39 °C), elevated serum CRP and bloody abdominal drainage fluid. Abdominal CT suggested pelvic hemorrhage (Fig. 3A). A large hemorrhage secondary to anastomotic disruption was drained via the drainage tube.

The patient received a blood transfusion and intravenous antibiotics (imipenem-cilastin 500 mg and metronidazole 500 mg three times daily). Conservative treatment was ineffective. The patient underwent emergency surgery on the 3rd postoperative day in order to clear abdominal infective ascites. Abdominal irrigation was performed during surgery. The patient was discharged to a skilled nursing facility, and tolerated a regular diet on the 10th postoperative day. When the drainage was less than 5 mL, the drainage tube was removed. Hemoglobin changes in this patient and his corresponding treatment are shown in Fig. 3B.

The operations were operated by the same surgeon. The report is in line with the SCARE Guidelines 2020 [5], and has been registered at <http://www.researchregistry.com> (registration ID: researchregistry5349). The study protocol was approved by local ethical committee of Changhai Hospital. Characteristics of these three patients are shown in Table 1. These patients were followed up at three-monthly intervals and recovered well without further complications of the initial or subsequent procedures. In the presence of a well-healed anastomosis, closure of the diverting loop ileostomy was finally performed. No recurrences were observed within 2 years of follow-up.

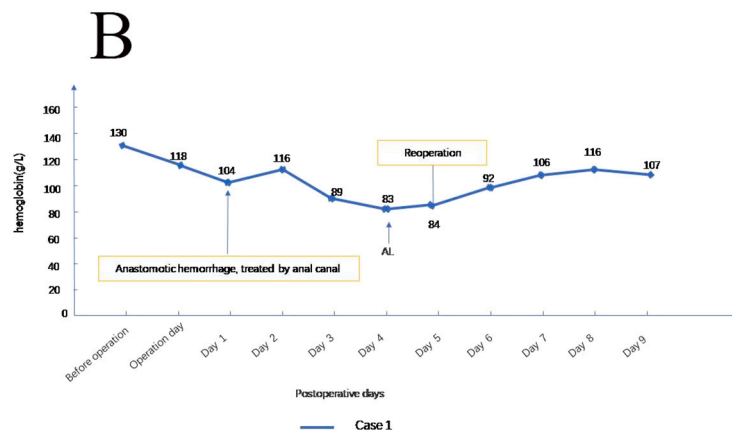
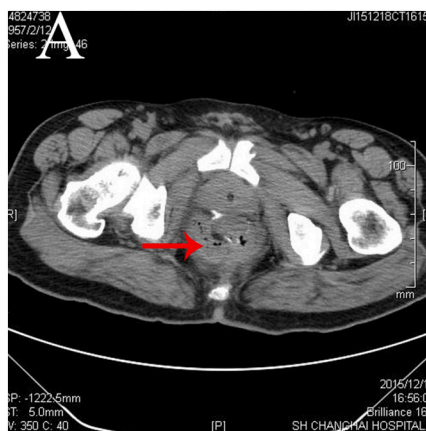


Fig. 1. CT findings A: CT scan revealed a small amount of extraluminal air and seroperitoneum around the anastomosis. B: Changes in hemoglobin and appropriate therapy in Case 1.

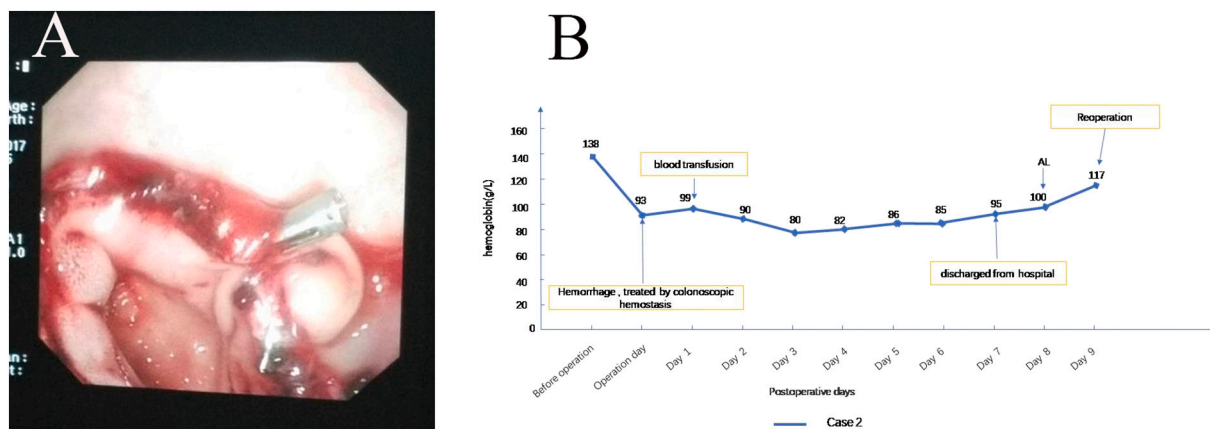


Fig. 2. CT findings A: Anastomotic hemorrhage treated by colonoscopy. B: Changes in hemoglobin and appropriate therapy in Case 2.

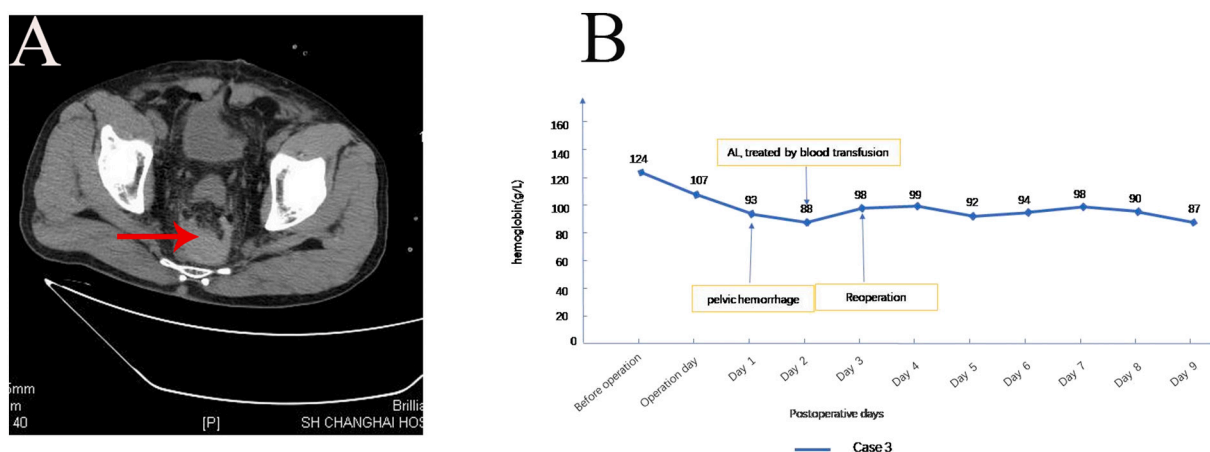


Fig. 3. CT findings A: Abdominal CT suggested pelvic hemorrhage. B: Changes in hemoglobin and appropriate therapy in Case 3.

Table 1
Characteristics of the three patients.

	Gender	Age (y)	Preoperative chemo-radiotherapy	Distance from the anal verge to anastomosis	Anastomotic hemorrhage	Time to removal of the drainage tube	Pelvic floor reconstruction
Case 1	Male	58	Yes	2 cm	Yes	7 d after operation	No
Case 2	Female	50	No	3 cm	Yes	≤5 mL at discharge	No
Case 3	Male	55	No	3 cm	No, pelvic hemorrhage	≤5 mL at discharge	No

3. Discussion

The protective loop ileostomy is created to switch the temporary fecal stream from a distal anastomosis and to mitigate the consequences of leakage. The recent meta-analysis by Gu et al. suggested that a dysfunctional stoma could effectively reduce the clinical consequences of AL and reoperation [6]. However, the three patients in our study developed severe abdominal infection following AL. These patients were treated by surgical reintervention. The causes of severe intra-abdominal infection after TME with the protective loop ileostomy are worth investigating.

Various risk factors for AL have been analyzed, including male sex, steroid use, smoking, open approach, operative time, and preoperative chemotherapy [7]. However, an analysis of risk factors for AL in patients with the protective loop ileostomy has seldom been performed. Therefore, we would like to share our experience regarding the treatment of

severe intra-abdominal infection after AL, especially in high-risk patients with the protective loop ileostomy. In addition to the reported risk factors, the following factors may be related to severe abdominal infection after AL, and could possibly even prevent it.

Firstly, it is well recognized that neoadjuvant chemoradiotherapy is the most significant and consistently reported risk factor for AL [8]. However, the mechanism underlying this association is poorly understood. Hu et al. reported that neoadjuvant therapy does not appear to increase the incidence of postoperative AL after anterior resection for mid and low rectal cancer. In addition, neither the interval between surgery and neoadjuvant therapy nor the radiotherapy regimen increases the rate of postoperative AL [9]. Case 1 in this study underwent preoperative neoadjuvant chemoradiotherapy, and had a serious complication after AL. Perhaps AL in patients with preoperative neoadjuvant chemoradiotherapy is associated with tissue edema and poor blood supply.

Secondly, the timing of drainage tube removal is also an important factor, and is rarely reported in the literature. With regard to the drainage tube, the present study showed no significant difference in the AL rate between the patients with and without a routine drainage tube [10]. However, a recent meta-analysis indicated a reduction in AL rate with pelvic drainage [11]. The time to AL was approximately 7 days [12]. AL occurred on the second day after extubation in Case 2 in our study. Thus, AL may be associated with early removal of the drainage tube, especially if blood is present in the drainage fluid. Therefore, we suggest that the extubation time should be extended in high-risk AL patients.

Thirdly, with the development of stapling techniques, a series of complications can occur, including anastomotic hemorrhage which is one of the early complications of anterior resection for rectal cancer. The reported incidence rate of anastomotic hemorrhage is up to 4%. Post-operative anastomotic hemorrhage can occur within a few minutes to 7 d after surgery, and is most common within 48 h [13]. Colonoscopic treatment, including electrocoagulation and clipping, are both safe and effective in stopping persistent anastomotic bleeding. The limitation of this treatment is the possibility of anastomotic disruption and subsequent leakage due to colonoscopic electrocoagulation in the early postoperative stage. However, due to the small number of cases reported, there is insufficient statistical evidence to demonstrate an increased risk of anastomotic fistula with colonoscopic electrocoagulation. Two of the three cases in our report developed anastomotic hemorrhage after surgery. Therefore, severe abdominal infection may be explained by colonoscopic treatment of anastomotic hemorrhage. As there is insufficient evidence to support this suggestion, further research concerning this issue is necessary.

Fourthly, pelvic floor reconstruction can separate anastomotic stoma with abdominal cavity. TME produces a large defect in the pelvic floor. Reconstruction of the pelvic floor was performed with the method of sewing the pelvic peritoneum to the rectum, in order to separate the small intestine from the presacral operating field (Fig. 4). Thus, pelvic floor reconstruction may be a good method to reduce sequelae after AL. An abscess following AL does not extend into the abdominal cavity, and does not cause severe infectious shock. Pelvic floor reconstruction can

confine pus to the pelvic cavity, and creates an opportunity for the pus to be drained from the anus. The three patients described in this study did not undergo pelvic floor reconstruction. Therefore, we strongly suggest that pelvic floor reconstruction should be carried out in patients with a high risk of AL.

In our experience, another important element should also be considered. If severe abdominal infection and early infectious shock occur after AL, surgical reintervention should be performed without any delay. Fever, abdominal or perineal pain, abdominal distention, high white cell count, high serum CRP, the presence of fecal liquid in the abdominal drainage fluid, and digital palpation of the rectal anastomosis are factors that play an important role in deciding whether to operate.

To the best of our knowledge, this is the first attempt to explain the reasons for severe abdominal infection after AL in patients who have undergone rectal surgery with the protective loop ileostomy. This raises the need for better understanding of severe abdominal infection after AL in order to assist surgical decision-making to prevent and/or reduce the severity of AL. Limited to a small number of patients, further research concerning this issue is necessary.

Sources of funding

We had no sources of funding for this case report.

Ethical approval

This case is exempt from ethical approval.

Consent

We have obtained written and signed consent to publish a case report from the patient.

Author contribution

Qizhi Liu, Minjun Zhou and Zhuo Chen drafted the manuscript. Junyi Chen, Dehua Zhou and Cheng Xin collected the data. Xiaohuang Tu

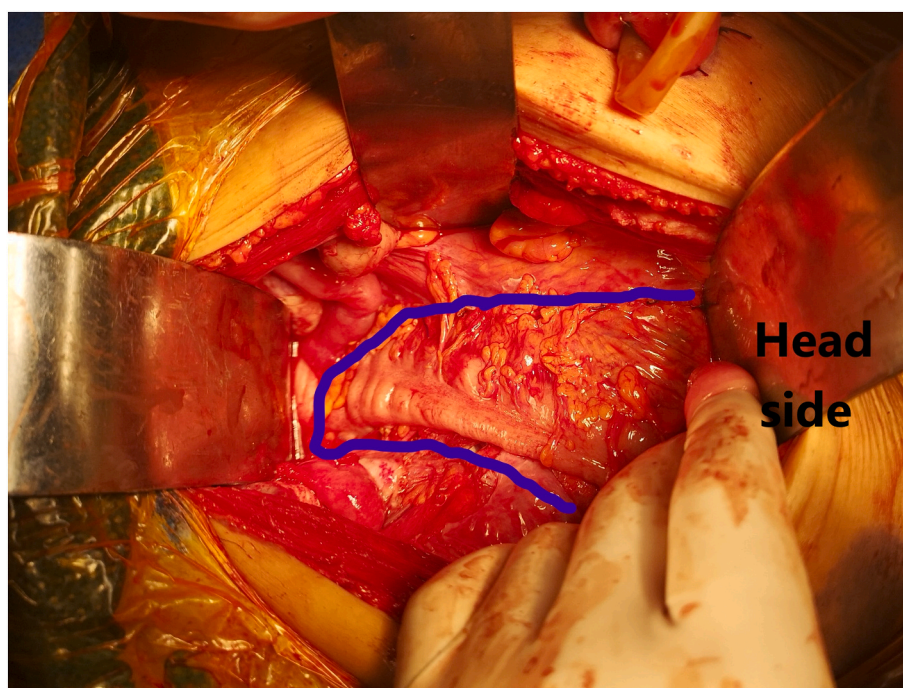


Fig. 4. Pelvic floor reconstruction. Reconstruction of the pelvic floor was performed with the method of sewing the pelvic peritoneum to the rectum. The blue is suture line. (For interpretation of the references to colour in this figure legend, the reader is referred to the web version of this article.)

revised it critically.

Registration of research studies

This case is a retrospective study.

Guarantor

Qizhi Liu.

Provenance and peer review

Not commissioned, externally peer-reviewed.

Declaration of competing interest

No conflicts of interest.

References

- [1] L. Niu, J. Wang, P. Zhang, X. Zhao, Protective ileostomy does not prevent anastomotic leakage after anterior resection of rectal cancer, *J. Int. Med. Res.* 48 (2020), 300060520946520.
- [2] J. Tanaka, T. Nishikawa, T. Tanaka, T. Kiyomatsu, K. Hata, K. Kawai, S. Kazama, H. Nozawa, H. Yamaguchi, S. Ishihara, E. Sunami, J. Kitayama, T. Watanabe, Analysis of anastomotic leakage after rectal surgery: a case-control study, *Ann. Med. Surg. (Lond.)* 4 (2015) 183–186.
- [3] M.M. Chiarello, P. Fransvea, M. Cariati, N.J. Adams, V. Bianchi, G. Brisinda, Anastomotic leakage in colorectal cancer surgery, *Surg. Oncol.* 40 (2022), 101708.
- [4] S. Jatal, V.D. Pai, J. Demenezes, A. Desouza, A.P. Saklani, Analysis of risk factors and management of anastomotic leakage after rectal cancer surgery: an Indian series, *Indian J. Surg. Oncol.* 7 (2016) 37–43.
- [5] R.A. Agha, T. Franchi, C. Sohrabi, G. Mathew, A. Kerwan, SCARE Group, The SCARE 2020 guideline: updating consensus Surgical CAse REport (SCARE) guidelines, *Int. J. Surg.* 84 (2020) 226–230.
- [6] W.L. Gu, S.W. Wu, Meta-analysis of defunctioning stoma in low anterior resection with total mesorectal excision for rectal cancer: evidence based on thirteen studies, *World J. Surg. Oncol.* 13 (2015) 9.
- [7] C. Foppa, S.C. Ng, M. Montorsi, A. Spinelli, Anastomotic leak in colorectal cancer patients: new insights and perspectives, *Eur. J. Surg. Oncol.* 46 (2020) 943–954.
- [8] Q.Y. Qin, Y.L. Wu, Y.H. Cai, Y.Y. Kuang, Y.J. He, X.Y. Huang, H. Wang, T.H. Ma, Clinical features and prognosis of anastomotic leak after anterior resection for rectal cancer following neoadjuvant chemoradiotherapy, *Zhonghua Wei Chang Wai Ke Za Zhi.* 24 (2021) 513–522.
- [9] M.H. Hu, R.K. Huang, R.S. Zhao, K.L. Yang, H. Wang, Does neoadjuvant therapy increase the incidence of anastomotic leakage after anterior resection for mid and low rectal cancer? A systematic review and meta-analysis, *Color. Dis.* 19 (2017) 16–26.
- [10] A. Karliczek, E.C. Jesus, D. Matos, A.A. Castro, A.N. Atallah, T. Wiggers, Drainage or nondrainage in elective colorectal anastomosis: a systematic review and meta-analysis, *Color. Dis.* 8 (2006) 259–265.
- [11] F. Rondelli, W. Bugiantella, M.C. Vedovati, R. Balzarotti, N. Avenia, E. Mariani, G. Agnelli, C. Becattini, To drain or not to drain extraperitoneal colorectal anastomosis? A systematic review and meta-analysis, *Color. Dis.* 16 (2014) O35–O42.
- [12] S.A. Boyce, C. Harris, A. Stevenson, J. Lumley, D. Clark, Management of low colorectal anastomotic leakage in the laparoscopic era: more than a decade of experience, *Dis. Colon Rectum* 60 (2017) 807–814.
- [13] W. Chen, G. Lin, Prevention and management of anastomotic bleeding after laparoscopic anterior resection of rectal cancer, *Zhonghua Wei Chang Wai Ke Za Zhi.* 19 (2016) 383–385.