

Pure single-incision laparoscopic D2 lymphadenectomy for gastric cancer: a novel approach to 11p lymph node dissection (midpancreas mobilization)

Sang-Hoon Ahn, Do Hyun Jung, Sang-Yong Son, Do Joong Park, Hyung-Ho Kim

Department of Surgery, Seoul National University Bundang Hospital, Seoul National University College of Medicine, Seongnam, Korea

We developed a novel approach to perform a perfect 11p lymph node dissection (LND), the so-called 'midpancreas mobilization' (MPM) method. Briefly, in pure single-incision laparoscopic distal gastrectomy (SIDG), after the completion of 7, 8a/12a, and 9 LND in the suprapancreatic portion, we started 11p LND after midpancreas mobilization. After mobilization of the entire midpancreas from the white line of Toldt, two gauzes were inserted behind the pancreas. This maneuver facilitated exposure of the splenic vein and complete detachment of soft tissue, including 11p lymph nodes, from the white line of Toldt, which was possible because of the tilting of the pancreas. The dissection plane along the splenic artery and vein for 11p LND could be visualized just through control of the operator's grasper without the need of an assistant. Fourteen patients underwent the procedure without intraoperative events, conversion to conventional laparoscopy, or surgery-related complications, including postoperative pancreatic fistula. All patients underwent D2 LND by exposure of the splenic vein. The mean numbers of retrieved lymph node and 11p lymph node were 61.3 ± 9.0 (range, 49–70), and 4.00 ± 3.38 (range, 1–10). Thus, we concluded that MPM for 11p LND in pure SIDG appears feasible and embryologically ideal; this method can be used in conventional laparoscopic gastrectomy.

[Ann Surg Treat Res 2014;87(5):279-283]

Key Words: Stomach neoplasms, D2 lymphadenectomy, Single-incision laparoscopic gastrectomy, Single-port, Midpancreas mobilization

INTRODUCTION

Laparoscopic distal gastrectomy (LDG) has been adopted as an alternative treatment for early gastric cancer in Korea [1]. Its benefits over conventional gastrectomy in terms of short-term outcomes, such as improved cosmetics, reduced postoperative pain, shorter hospital stay, and improved quality of life, have been well demonstrated in prospective studies [2,3]. Moreover, some retrospective studies have shown comparable long-term survival [4].

As techniques and instruments in laparoscopic gastrectomy improve, experienced laparoscopic surgeons are performing

laparoscopic D2 lymph node dissection (LND) for gastric cancer. This laparoscopic approach was shown to be technically feasible, with complications rates comparable to those of open D2 gastrectomy even in advanced gastric cancer [5]. However, laparoscopic D2 LND for gastric cancer is still technically demanding. The surgeon has to dissect the 11p lymph nodes (LNs) along the splenic artery and vein and the 12a LNs along the proper hepatic artery and portal vein to accomplish D2 LND in distal gastrectomy, as stated in the 3rd Japanese Gastric Cancer Treatment Guidelines [6]. During laparoscopic D2 gastrectomy, the most technically challenging part of the laparoscopic 11p LND procedure is exposing the proximal part

Received June 30, 2014, Revised July 24, 2014, Accepted July 25, 2014

Corresponding Author: Hyung-Ho Kim

Department of Surgery, Seoul National University Bundang Hospital, 82 Gumi-ro 173beon-gil, Bundang-gu, Seongnam 463-707, Korea

Tel: +82-31-787-7095, Fax: +82-31-787-4078

E-mail: hkim@snuhb.org

Copyright © 2014, the Korean Surgical Society

© Annals of Surgical Treatment and Research is an Open Access Journal. All articles are distributed under the terms of the Creative Commons Attribution Non-Commercial License (<http://creativecommons.org/licenses/by-nc/3.0/>) which permits unrestricted non-commercial use, distribution, and reproduction in any medium, provided the original work is properly cited.

of the splenic artery and splenic vein.

In certain cases, D2 LND becomes necessary because of unexpected LN enlargement that may be present even in early gastric cancer. We have developed a novel approach to perform a perfect 11p LND, the so-called "midpancreas mobilization" (MPM) method. This approach can be used in pure single-incision laparoscopic distal gastrectomy (SIDG), and it does not require technical assistance. We successfully used this technique for 14 patients who underwent pure SIDG.

The purpose of this article is to describe the MPM technique and report its feasibility for 11p LND, along with the surgical outcome of the 14 patients we treated. This technique and concept can be applied to conventional laparoscopic gastrectomy.

SURGICAL TECHNIQUE

Pure SIDG with D2 LND

The patient was placed in a lithotomy position with reverse Trendelenburg. The operator and a scopist were positioned between the patient's legs. A longitudinal transumbilical 2.5-cm long incision was made. A commercial 4-hole single port (Glove port, Nelis, Bucheon, Korea) was placed in the single incision, and the abdominal cavity was insufflated with carbon dioxide at a pressure of 13 mmHg. No additional assistant trocar was used. A 10-mm flexible high-definition scope (Endoeye flexible HD camera system, Olympus Medical Systems Co., Tokyo, Japan), a Harmonic Scalpel (Ethicon Endo-Surgery Inc., Cincinnati, OH, USA), and a LigaSure 5-mm Blunt Tip (Covidien, Mansfield, MA, USA) were used to visualize nearly the same field as that observed in conventional laparoscopic gastrectomy and to facilitate dissection and bleeding control. The detailed

procedures, including a modified combined suture retraction of the liver, partial omentectomy, and LND for LNs 6, 5, 12a, 8a, and 7, have been described in our previous reports [7].

Herein, we will focus on the detailed procedures regarding 11p LND through MPM.

Midpancreas mobilization

After completion of 8a/12a, 7, and 9 LND in the suprapancreatic portion, which is located on the right side of the suprapancreatic area, 11p LND was started from the midpancreas. First, we dissected around the inferior border of pancreas from the left side of inferior mesenteric vein and kept the mobilization plane upward along the white line of Toldt, identifying the left renal vein on the dorsal side and the splenic vein on the ventral side. This plane was maintained to dissect up to the suprapancreatic border, which resulted in mobilization of the entire mid-pancreas from the white line of Toldt (Fig. 1). Then, two gauzes were inserted behind the pancreas, and the splenic vein could be easily exposed because of dorsal tilting of the suprapancreas and detachment of soft tissue, including 11p LNs, from the white line of Toldt (Fig. 2). The dissection plane along the splenic artery and vein for 11p LND could be visualized and exposed just through control of the operator's grasper without the need of an assistant (Fig. 3).

After 11p LND (Fig. 4), LN 1, including the vagus nerve, was dissected and the lesser curvature was cleared for transection of the stomach. We usually perform uncut Roux-en-Y gastrojejunostomy for reconstruction after pure SIDG. One Jackson-Pratt (J-P) drainage tube was placed through the umbilical wound around the suprapancreatic area, and the incision was closed.

Between January 2013 and November 2013, 14 consecutive

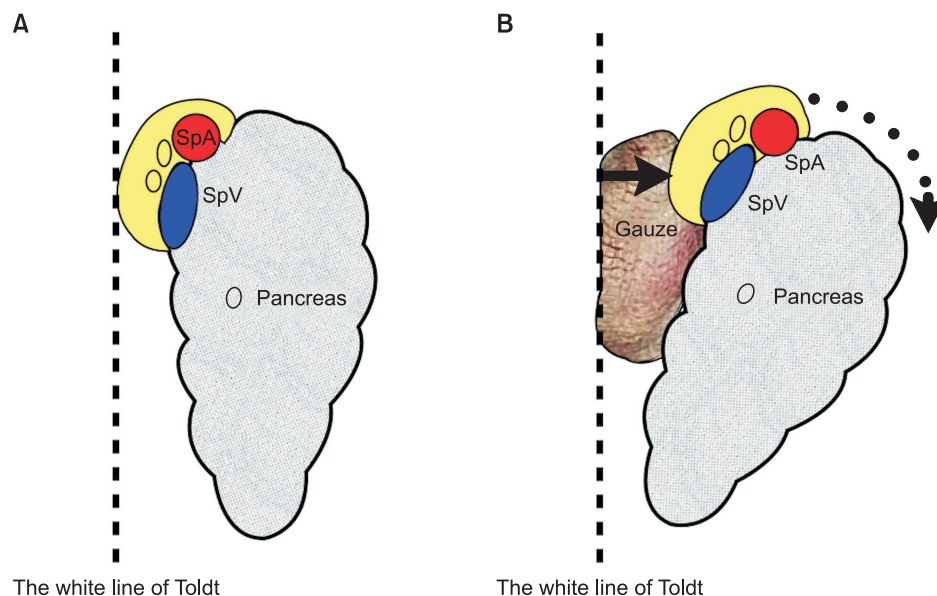


Fig. 1. An illustration of the concept for midpancreas mobilization; (A) normal arrangement of the pancreas, the splenic vessels and the soft tissue containing 11p lymph nodes; (B) ventrally migrated and tilted arrangement of the pancreas, the splenic vessels, and the soft tissue containing 11p lymph nodes.

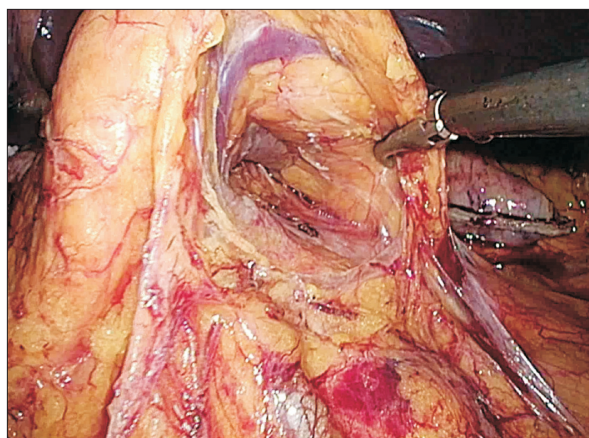


Fig. 2. Midpancreas mobilization in pure single-incision laparoscopic distal gastrectomy.

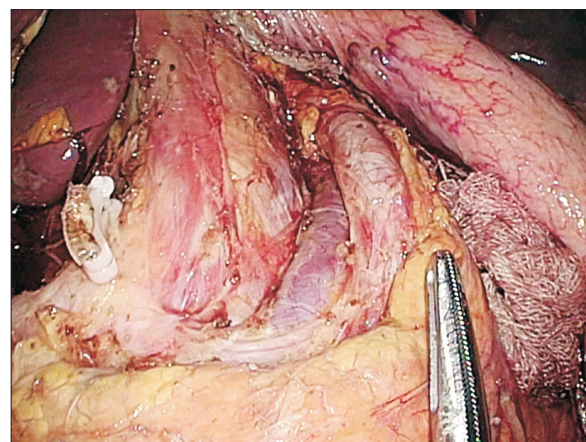


Fig. 4. A complete view of 11p lymph node dissection.

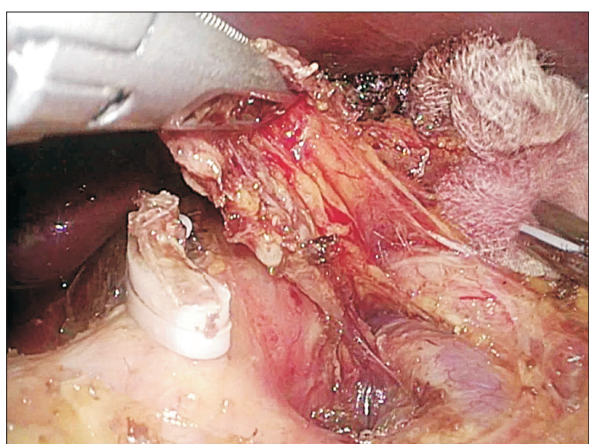


Fig. 3. An 11p lymph node dissection with proper exposure of the splenic artery and vein.

patients underwent pure SIDG with D2 LND at Seoul National University Bundang Hospital. In this study, patient eligibility criteria were a preoperative diagnosis of stage I gastric cancer, according to the American Joint Committee on Cancer staging manual 7th edition, with no LN enlargement, 20 to 80 years of age, no history of other malignancies, chemotherapy, or radiotherapy, and no severe comorbidity. Patients underwent the procedure after providing written informed consent. This study was approved by the Institutional Review Board of Seoul National University Bundang Hospital. The clinical features, demographics (e.g., sex, age, tumor size, and number of retrieved metastatic, suprapancreatic 11p LNs), and early postoperative complications such as postoperative pancreatic fistula (POPF) (0–30 days) were analyzed based on the information obtained from our prospectively collected gastric cancer database. During the postoperative hospital stay, the patients were managed according to our institutional critical pathway protocols. Sips of water, a semifluid diet (SFD), and a soft blended diet (SBD)

Table 1. Patient demographics and clinical characteristics

Variable	Pure SIDG with D2 LND (n = 14)
Age (yr), mean ± SD	62.6 ± 10.4
Sex (male : female)	6 : 5
Body mass index (kg/m ²), mean ± SD	21.7 ± 2.4
Comorbidity, n (%)	7 (50.0)
Previous abdominal operation history, n (%)	0 (0)
ASA score	
1	4
2	7

SIDG, single-incision laparoscopic distal gastrectomy; LND, lymph node dissection; SD, standard deviation; ASA, American Society of Anaesthesiologists.

were given to the patients on postoperative days 2, 3, and 4, respectively. After SBD intake, the J-P drainage tube was removed. Finally, the patients were routinely discharged from the hospital on the fifth postoperative day, if they exhibited no discomfort, abdominal pain, or abnormal results on laboratory tests. Early and late complication was defined as complications that occur within thirty days and after postoperative day 30, respectively. The surgery and after postoperative day 30, respectively. POPF is diagnosed when the drainage amylase is three times higher than the upper normal limit of serum amylase on the third postoperative day. Thus far, pure SIDG with D2 LND using MPM has been performed for 14 patients with gastric cancer at clinical stage I. The demographics and operative data of patients are described in Table 1. No intraoperative events occurred (conversion to conventional laparoscopy or open gastrectomy, uncontrolled bleeding, unexpected injury to the adjacent organ, or surgery-related complications). The mean operation time was 156.8 ± 34.6 minutes (range, 120–235 minutes). The mean estimated blood loss was 65.6 ± 36.8 mL (range, 3–150 mL). The total number

Table 2. Operative data

Variable	Pure SIDG with D2 LND (n = 14)
Operation time (min), mean \pm SD (range)	156.8 \pm 34.6 (120–235)
Conversion to conventional laparoscopy (multiport) or open surgery, n (%)	0 (0)
R0 resection, n (%)	14 (100)
Estimated blood loss (mL), mean \pm SD	65.6 \pm 36.8
Reconstruction	
BI : R-Y	0 : 10

SIDG, single-incision laparoscopic distal gastrectomy; LND, lymph node dissection; SD, standard deviation.

of retrieved LNs was 61.3 ± 9.0 (range, 49–70), including 15.3 suprapancreatic LNs (range, 5–23). The mean number of 11p LNs was 4.00 ± 3.38 (range, 1–10) (Table 2).

All the patients recovered rapidly after the operation. They tolerated consumption of SFD on the third postoperative day and SBD on the fourth postoperative day. No POPF was observed. The mean levels of serum amylase and drain amylase were 55.16 ± 25.82 U/L (range, 30–86 U/L) and 101.75 ± 73.98 U/L (range, 47–211 U/L), respectively. Postoperative delirium was the only early postoperative complication and was observed in a 77-year-old man who had chronic obstructive pulmonary disease and was receiving a medication for delirium. The mean duration of postoperative hospital stay was 6.25 ± 3.15 days (range, 5–14 days) (Table 3).

DISCUSSION

This study was designed to evaluate the technique and feasibility of MPM for 11p LND, in particular, the preciseness of 11p LND, the number of 11p LNs, and early postoperative complications including POPF. To the best of our knowledge, this is the first report of MPM for 11p LND. The present study results suggest that pure SIDG with D2 LND using MPM is not only feasible and safe but also an embryologically ideal method for 11p LND. This procedure can even be adapted to conventional laparoscopic and open D2 gastrectomy.

Gastric cancer is still one of the most common causes of cancer-related death in spite of decreasing worldwide incidence. The only curative treatment for gastric cancer is radical gastrectomy and D2 LND. According to the 3rd Japanese gastric cancer Treatment guidelines, D2 LND in distal gastrectomy is defined as D1 + LND (1, 3, 4sb, 4d, 5, 6, 7, 8a, 9) plus the complete removal of the LNs along the proper hepatic (station 12a) and the splenic artery (station 11p) [6]. However, dissection of the tissue adjacent to the splenic artery and exposure of the splenic vein are the most technically demanding parts of the procedure. It is not easy to expose the splenic vein adequately

Table 3. Postoperative outcomes and pathologic findings

Variable	Pure SIDG with D2 LND (n = 14)
Postoperative hospital stays (day)	6.25 \pm 3.15 (5–14)
Postoperative pancreatic fistula	0 (0)
Serum amylase (U/L)	55.16 \pm 25.82 (30–86)
Drain amylase (U/L)	101.75 \pm 73.98 (47–211)
No. of retrieved lymph node	61.13 \pm 8.95 (49–70)
No. of suprapancreatic lymph node (7, 8a, 9, and 11p)	15.25 \pm 6.90 (5–23)
No. of 11p lymph node	4.00 \pm 3.38 (1–10)
Early complications	1 (9.1)
Late complications	0 (0)
Reoperation	0 (0)
Postoperative mortality	0 (0)

Values are presented as mean \pm standard deviation (range) or number (%).

SIDG, single-incision laparoscopic distal gastrectomy; LND, lymph node dissection.

even in open surgery and obese patients. This is because the splenic vein is usually located below the splenic artery and behind the pancreas, and there is a serious risk of bleeding caused by injuries to neighboring vessels.

The main difficulty in laparoscopic D2 LND is that the splenic vein is not always easy to access using usual trocar placements and approaches. To overcome this difficulty, we usually compress the pancreas during 11p LND to tilt the upper side of the pancreas and expose the splenic vein. However, it is sometimes nearly impossible to expose the splenic vein because of various anatomical variations [8]. Therefore, a radical change of approach to this area is required to obtain consistent results.

As recently as October 2010, the surgeons in our institute began using SIDG. They started pure single-incision laparoscopic distal and total gastrectomy for early gastric cancer in November 2012 [7]. In some cases, we have encountered the need for D2 LND because of unexpected LN enlargement that may be present even in early-stage gastric cancer. 11p LN could be dissected in some low BMI patients with a favorable anatomy. However, 11p LND in single-port could always not be done in all patients by conventional approach. Therefore, we have developed a novel approach to perform a perfect 11p LND, the so-called MPM method. This approach can even be performed in SIDG, without the need for an assistant. We successfully used this technique in 14 patients who underwent pure SIDG.

As in open resections, LND was considered to increase morbidity and even mortality in Western studies [9]. In the present study, the morbidity rate was lower than the historical control, and there was no hospital mortality. In terms of mortality and morbidity rates, our results are lower than the mortality rates of 0.6%–0.8% and the morbidity rates

of 17.4%–20.1% reported from advanced centers with vast experience in D2 LND [10].

Although the sample size of this study was too small to draw a firm conclusion, we conclude that MPM for 11p LND in pure SIDG may be a feasible and embryologically ideal procedure that can be used in conventional laparoscopic gastrectomy and open gastrectomy. However, further experience and prospective randomized studies are needed to confirm the safety and efficacy of this technique.

CONFLICTS OF INTEREST

No potential conflict of interest relevant to this article was reported.

ACKNOWLEDGEMENTS

This study was supported by grant 02-2013-083 from Seoul National University Bundang Hospital, Republic of Korea.

REFERENCES

1. Jeong O, Park YK. Clinicopathological features and surgical treatment of gastric cancer in South Korea: the results of 2009 nationwide survey on surgically treated gastric cancer patients. *J Gastric Cancer* 2011;11:69-77.
2. Kim HH, Hyung WJ, Cho GS, Kim MC, Han SU, Kim W, et al. Morbidity and mortality of laparoscopic gastrectomy versus open gastrectomy for gastric cancer: an interim report: a phase III multicenter, prospective, randomized Trial (KLASS Trial). *Ann Surg* 2010;251:417-20.
3. Kim YW, Baik YH, Yun YH, Nam BH, Kim DH, Choi IJ, et al. Improved quality of life outcomes after laparoscopy-assisted distal gastrectomy for early gastric cancer: results of a prospective randomized clinical trial. *Ann Surg* 2008;248:721-7.
4. Hwang SH, Park DJ, Jee YS, Kim MC, Kim HH, Lee HJ, et al. Actual 3-year survival after laparoscopy-assisted gastrectomy for gastric cancer. *Arch Surg* 2009;144:559-64.
5. Park DJ, Han SU, Hyung WJ, Kim MC, Kim W, Ryu SY, et al. Long-term outcomes after laparoscopy-assisted gastrectomy for advanced gastric cancer: a large-scale multicenter retrospective study. *Surg Endosc* 2012;26:1548-53.
6. Japanese Gastric Cancer Association. Japanese gastric cancer treatment guidelines 2010 (ver. 3). *Gastric Cancer* 2011; 14:113-23.
7. Ahn SH, Park DJ, Son SY, Lee CM, Kim HH. Single-incision laparoscopic total gastrectomy with D1+beta lymph node dissection for proximal early gastric cancer. *Gastric Cancer* 2014;17:392-6.
8. Hongo N, Mori H, Matsumoto S, Okino Y, Ueda S, Shuto R. Anatomical variations of peripancreatic veins and their intrapancreatic tributaries: multidetector-row CT scanning. *Abdom Imaging* 2010;35:143-53.
9. Bonenkamp JJ, Hermans J, Sasako M, van de Velde CJ, Welvaart K, Songun I, et al. Extended lymph-node dissection for gastric cancer. *N Engl J Med* 1999;340:908-14.
10. Park DJ, Lee HJ, Kim HH, Yang HK, Lee KU, Choe KJ. Predictors of operative morbidity and mortality in gastric cancer surgery. *Br J Surg* 2005;92:1099-102.