

Treatment of Acute Thigh Muscle Injury with or without Hematoma Puncture in Athletes*

Tratamento das lesões musculares agudas da coxa com ou sem punção do hematoma em atletas

Rodrigo Moreira Sales¹ Marcelo Cortês Cavalcante¹ Moisés Cohen¹ Benno Ejnisman¹
 Carlos Vicente Andreoli¹ Alberto de Castro Pochini¹

¹Paulista School of Medicine, Department of Orthopedics and Traumatology, Universidade Federal de São Paulo (Unifesp), São Paulo, SP, Brazil

Address for correspondence Marcelo Cortês Cavalcante, Universidade Federal de São Paulo, Escola Paulista de Medicina, Departamento de Ortopedia e Traumatologia, São Paulo, SP, Brazil (e-mail: Marcelo_cortes88@hotmail.com).

Rev Bras Ortop 2019;54:6–12.

Abstract

Objectives To correlate the mean time of return of athletes to sport after acute injury of the thigh muscle with hematoma that was punctured or not.

Methods Study based on clinical intervention, controlled and non-randomized with 20 amateur and professional athletes, divided into moderate and total or subtotal thighs lesions, according with the Munich Consensus Statement. Nine athletes were included in the intervention group and 11 athletes in the control group. In the intervention group, the athletes were submitted to a puncture of the hematoma, associated to physical therapy; the control group did only physical therapy. The variable mean time of return to sport was analyzed using the Mann-Whitney test and a significance level of 5% ($p < 0.05$; 95% confidence interval [CI]) was established.

Results The mean group was composed mostly of men, eight of them were amateur athletes. There were three women, two of whom were amateur athletes. The average age of participants was 34.70 ± 12.79 years. There were 13 patients with posterior thigh lesions, 5 with anterior lesions and two with adductor lesions. Considering all injuries, the mean time of return to sport was of 48.50 ± 27.50 days in the intervention group. In the control group, this period was of 102.09 ± 52.02 days, showing a statistically significant difference between them ($p = 0.022$).

Conclusion In the present study, hematoma drainage in athletes with moderate and total or subtotal muscle injuries associated with hematomas decreased their return time to sport.


Keywords

- ▶ skeletal muscle/ injuries
- ▶ thigh
- ▶ hematoma
- ▶ drainage

Resumo

Objetivos Comparar o tempo médio de retorno dos atletas ao esporte após lesão muscular aguda da coxa com hematoma que foi ou não puncionado.

* Study developed at the Sports Medicine and Physical Activity Course, Department of Orthopedics and Traumatology, Universidade Federal de São Paulo (Unifesp), São Paulo, SP, Brazil.

 Marcelo Cortês Cavalcante's ORCID is <https://orcid.org/0000-0003-1207-9185>.

Métodos Estudo longitudinal de intervenção clínica, controlado e não randomizado, com participação de 20 atletas amadores e profissionais com lesão muscular aguda do tipo parcial moderada ou (sub)total na região da coxa, segundo a classificação do Consenso de Munique. Nove atletas foram incluídos no grupo intervenção e 11 no grupo controle. Os atletas do grupo intervenção foram submetidos a punção do hematoma e fisioterapia e os do grupo controle, apenas a fisioterapia. A variável tempo de retorno ao esporte foi analisada com o teste de Mann-Whitney e o nível de significância usado foi 95% ($p < 0,05$).

Resultados A população estudada foi composta principalmente por homens, dos quais oito eram praticantes de esportes no nível amador. Três mulheres, das quais duas eram amadoras, foram incluídas no estudo. A média de idade dos participantes foi de $34,70 \pm 12,79$ anos. Houve 13 indivíduos com lesões na região posterior da coxa, cinco com lesões na região anterior e dois com lesões na região adutora. Considerando todas as lesões, o tempo médio de retorno ao esporte foi de $48,50 \pm 27,50$ dias no grupo intervenção. Já no grupo controle, esse intervalo foi de $102,09 \pm 52,02$ dias ($p = 0,022$).

Conclusão No presente estudo, a punção do hematoma muscular mostrou-se efetiva em abreviar o tempo de retorno ao esporte dos atletas com lesões musculares parciais moderadas e (sub)totais associadas a hematomas.

Palavras-chave

- ▶ músculo esquelético/lesões
- ▶ coxas
- ▶ hematoma
- ▶ drenagem

Introduction

Muscle injuries are the most frequent conditions in athletes from several modalities, with an incidence rate of up to 39.2%.¹

This is a very relevant subject due to its high incidence, high treatment costs and negative impact over an athlete's career. Several therapeutic proposals tried to minimize the harmful effects of a muscle injury. Among them, therapy with platelet-rich plasma appears promising. However, some studies failed to show a decrease in the time required to return to sport.² More traditional approaches, such as non-steroidal anti-inflammatory drugs (NSAIDs) or steroids injections, did not demonstrate benefits in improving muscle healing or reducing the time for return to sport.³ Accordingly, a muscle hematoma puncture could represent an option in the treatment of extensive muscle injuries.

Muscle hematomas are blood collections resulting from contusions or indirect traumas and can be intra- or inter-muscular. These muscle collections are consistently present in partial and (sub)total lesions (Munich Consensus Statement) and can be aspirated by puncture in their chronic phase.⁴ However, there is no consensus that hematoma puncture must be performed during the acute phase. It is hypothesized that this procedure could speed up tissue healing and, consequently, allow a quicker return to sport. This reasoning is grounded in the physiopathological foundations of muscle injury, in which the phases of degeneration, regeneration and cellular remodeling are present.⁵

According to some studies, the degeneration period is marked by the accumulation of inflammatory cells and proteins (chemokines, cytokines and growth factors) involved in absorbing the muscle hematoma.^{6,7} In the presence of an extensive hematoma, there would be a delay in muscle

healing resulting from a prolonged degeneration phase.⁸ Moreover, it is believed that the hematoma would also favor cicatricial, fibrous tissue formation, which would be inadequate for the proper function of the injured muscle.⁹

Therefore, the present study was based upon the need to evaluate the effects of puncturing a muscle hematoma resulting from acute lesions on the recovery time of amateur and professional athletes.

Material and Methods

Study Type

Clinical intervention, pilot, longitudinal, controlled, and non-randomized study approved by the Ethics and Research Committee of Universidade Federal de São Paulo (Unifesp, in the Portuguese acronym).

Data Collection

Data were collected between 2014 and 2016, at the Sports Medicine outpatient facility (Ambulatório de Medicina Esportiva) from Unifesp and at the Medical Department of Clube Sociedade Esportiva Palmeiras, after obtaining a signed informed consent from the participants. Data were obtained during medical care, and some information, such as the number of physical therapy sessions, date of return to sport (normal training and/or competitions), and lesion recurrence, were obtained by telephone. Lesions were considered as recurrences if they happened up to 30 days after medical discharge.

Sample

Twenty amateur and professional athletes from several modalities participated in the study. Their ages ranged from 18 to 68 years-old among men, and from 39 to 48 years-old among

women, with an average of 34.70 ± 12.79 years-old. Five participants (25%) were professional athletes and 15 (75%) were amateur athletes, with 17 (85%) men and 3 (15%) women.

Nine (45%) individuals were submitted to muscle hematoma puncture (intervention group) and physical therapy. The remaining participants (control group) did not comply with the muscle puncture and were submitted only to physical therapy. The physical therapy followed the conventional muscular rehabilitation protocol. Professional athletes attended an average of two physical therapy sessions per day, totaling 10 sessions per week. Amateur athletes attended an average of three physical therapy sessions per week. Each physical therapy session lasted about 90 minutes in both groups. Strengthening trainings were also considered as rehabilitation sessions and were performed as prescribed by the physical therapist at the late recovery phases. During physical therapy sessions, performed by a sports physical therapist, electrothermal phototherapy and kinesiotherapy were done according to the individual evolution of each athlete. Initially, the rehabilitation approach emphasized pain relief, followed by slow and gradual progression to isometric, isotonic exercises, functional trainings and proprioceptive routines for lower limbs. Since the athletes must agree with the muscle hematoma puncture, participants allocation in each group occurred based on consent with the procedure. In the professional athlete group, 3 (15%) patients were submitted to the puncture, and in the amateur group, 6 (30%). Most (55%) athletes played soccer and were male.

The inclusion criteria for the clinical study were: healthy people from both genders aged from 18 to 70 years-old, with acute thigh lesions (up to 3 weeks) associated with a hematoma (essentially Type 3 B and 4 lesions according to the Munich Consensus Statement).

The exclusion criteria were: smoker athletes, those with systemic diseases, those in regular use of medications such as corticosteroids, antiinflammatory and antifibrotic agents and patients who abandoned the study.^{3,8,10}

Participants were divided in an intervention group (hematoma puncture associated with physical therapy) and a control group (physical therapy) and subdivided according to their sport activity level as professional or amateur athletes. Professional athletes were those in high-performance sports (official competitions) or receiving some type of financial compensation to play.

Athletes' lesions were classified according to a superimposition of clinical and ultrasonographic criteria. Initially, athletes were submitted to a clinical evaluation (history taking and physical exam) by a physician specialized in sports medicine who observed one or more of the following clinical parameters: severe pain at the moment of the lesion (with an analog visual scale for pain); functional inability (muscle contraction inability); pain when stretching the involved muscles (passive and active stretching); and muscle alteration at palpation during physical exam.^{8,11,12} Immediately after history taking and physical exam, if the clinical suspicion was consistent with the diagnostic hypothesis of acute muscle injury, the patient was submitted to an ultrasound. Ultrasound examinations identifying complete or subtotal muscle injuries,

tendinous avulsions or muscle stump retractions were classified as structural, type 4 lesions (Munich Classification). Lesions without the sonographic findings mentioned above, but presenting with measurable hematomas and muscle injuries, were classified as moderate partial (type 3 B lesions according to the Munich's Classification). Exams were performed immediately after the medical visit by radiologists with expertise in the musculoskeletal apparatus; an ultrasound-guided muscle hematoma puncture was performed by the sports physician who first cared for the athlete. The ultrasound equipment used for the diagnosis and to orient puncture procedures was the GE Logiq P6 (GE Healthcare, Chicago, IL, USA). Athletes submitted to the puncture fulfilled the inclusion and exclusion criteria and signed the informed consent form for the procedure.

After puncture, the athletes were asked to rest for 2 days and to follow the Price protocol (protection, rest, limb elevation and ice) 3 times a day, for 7 days.

Discharge occurred after a cooperative evaluation by the sports medicine and physical therapy teams. To be discharged, the patients had to perform functional exercises (analogous to the sports they used to play) with no pain or limitations of the knee and hip range of motion. The ultrasound performed at this moment should demonstrate the healed muscle lesion. To safely corroborate the medical discharge, the physical therapist proceeded to a functional test (Hop Test), in which a contralateral difference of less than 10% should be present.^{13,14} The successful return to sport was defined as the unrestricted participation in trainings (like those performed prior to the lesion) or competitions, with no lesions at the first 30 days postdischarge.

Data Analysis

Data was presented as mean \pm standard deviation. Possible differences in the variables collected from both groups (intervention and control) were analyzed at the GraphPad Prism 6 software (GraphPad Software, San Diego, CA, USA) through a non-parametric Mann-Whitney test for unpaired samples. Significance level was 95% ($p < 0.05$).

Results

Muscle injuries in the posterior region occurred in 13 cases (65%); in the anterior region, there were 5 cases (25%) and in the adductor region, 2 cases (10%) (**Fig. 1**).

The average size of the hematomas was 9.17 ± 7.89 mL, ranging from 2.00 to 28.00 mL. In the intervention group, the average size of muscle hematomas was 12.06 ± 7.35 mL, ranging from 4.70 to 27.00 mL. The average aspirated volume from hematomas was 5.33 ± 3.35 mL, ranging from 1.00 to 12.00 mL (**Table 1**).

The mean time to return to sport in the intervention group was 48.50 ± 27.50 days, ranging from 15 to 85 days; in the control group, the mean time was 102.09 ± 52.02 days, ranging from 30 to 180 ($p = 0.022$) (**Fig. 2**).

The 6 amateur athletes submitted to hematoma puncture (40% of the amateur athletes) performed, on average, 12.50 ± 4.76 physical therapy sessions and returned to sport in an average time of 54.16 ± 29.56 days. Patients who were

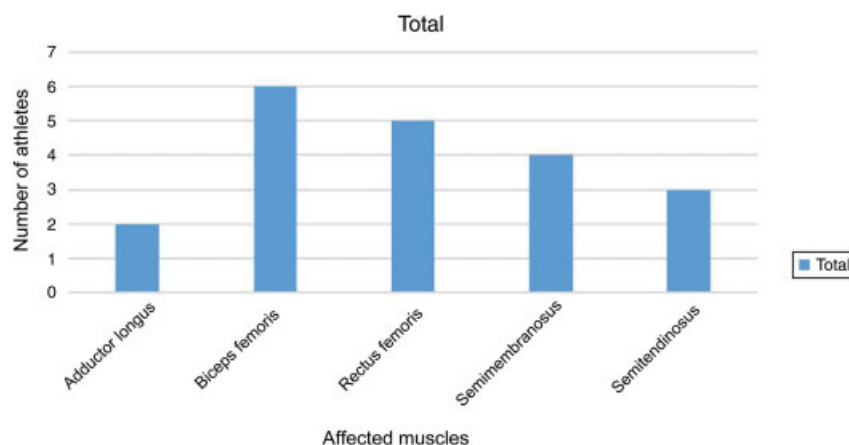


Fig. 1 Thigh muscles evaluated at the study.

Table 1 Epidemiological profile of the athletes participating in the study

Athlete	Gender/Age (years-old)	Sport/Performance level	Affected muscle	Lesion degree / puncture	Days for return
1	M/30	Soccer/Professional	Adductor Longus	3/yes	15
2	M/52	Soccer/Amateur	Semimembranosus	3/yes	75
3	M/22	Soccer/Professional	Rectus Femoris	3/yes	35
4	M/18	Soccer/Amateur	Adductor Longus	3/yes	15
5	M/18	Soccer/Amateur	Biceps Femoris	3/yes	30
6	M/26	Rugby/Professional	Biceps Femoris	3/yes	62
7	F/39	Soccer/Amateur	Semitendinosus	4/yes	40
8	M/50	Soccer/Amateur	Rectus Femoris	4/yes	80
9	M/28	Handball/Amateur	Semimembranosus	4/yes	85
10	M/68	Table tennis/Amateur	Semitendinosus	3/no	30
11	F/41	Classical ballet/Professional	Semimembranosus	4/no	120
12	M/45	Street race/Amateur	Biceps Femoris	4/no	180
13	M/27	Soccer/Amateur	Biceps Femoris	3/no	90
14	M/25	Soccer/Amateur	Rectus Femoris	3/no	70
15	M/36	Street race/Amateur	Biceps Femoris	3/no	78
16	M/33	Soccer/Amateur	Rectus Femoris	4/no	120
17	M/32	Soccer/Amateur	Semitendinosus	3/no	45
18	M/29	Taekwondo/Amateur	Biceps Femoris	3/no	180
19	M/25	Indoor soccer/Professional	Rectus Femoris	3/no	60
20	F/48	Pole Dance/Amateur	Semimembranosus	3/no	150

not submitted to puncture performed, on average, 28.66 ± 16.02 physical therapy sessions and returned to sport in an average time of 104.77 ± 55.79 days.

On the other hand, professional athletes submitted to puncture performed, on average, 38.33 ± 18.77 physical therapy sessions and returned to sport in an average time of 37.83 ± 23.58 days. However, those who were not submitted to hematoma puncture performed, on average, 40.00 ± 11.31 physical therapy sessions and returned to sport in an average time of 90.00 ± 42.42 days (**Fig. 3**). The only complication observed was the de novo formation of a hematoma in one of

the athletes submitted to puncture. In this case, recovery took 80 days (above the average time observed in the intervention group), but the athlete had no other complications or lesion recurrence after medical discharge. Moreover, one weightlifting athlete was excluded from the study after deciding to abandon the sport and discontinue the treatment.

Discussion

In sports such as soccer, thigh lesions represent up to 30% of the musculoskeletal complaints.^{15,16} Most athletes from the

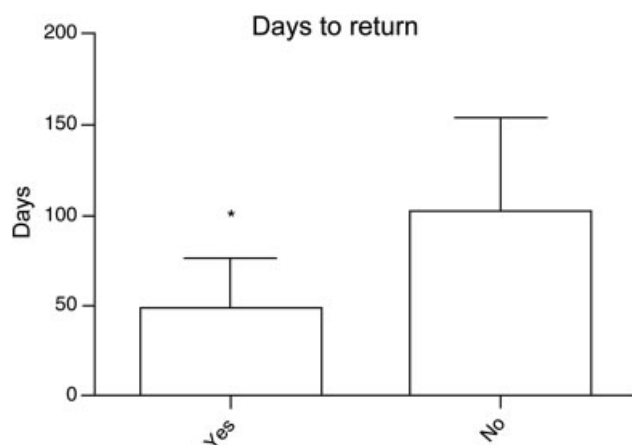


Fig. 2 Mean time in days to return to sport in the intervention group (Yes) and in the control group (No). The Mann-Whitney test was performed, and a significant difference was noted in the intervention group with $p = 0.022$ (*).

present study were male and played soccer (► **Table 1**). Moreover, the incidence of lesions in the posterior aspect of the thigh was higher, a finding consistent with the international literature.^{11,17}

A recently published meta-analysis showed that the risk of thigh lesion development was high in athletes with a history of previous ischiotibial injuries, increased age and higher quadriceps peak torque.¹⁸ Other associated risk factors, such as inadequate flexibility and muscular balance, could also contribute to these lesions.^{19,20} Regarding biomechanical aspects, the higher incidence of lesions in the posterior thigh could also be influenced by the biarticular muscles from these region. Therefore, rapid contraction movements could predispose them to lesion.²¹⁻²³

Some supplementary imaging methods are used to help diagnosing muscle injuries and identifying hematomas.

Musculoskeletal ultrasound has an important role, since it estimates the prognosis through the complete evaluation of the lesion (extension, hematoma formation, dynamic stability of the muscle stumps and fibrosis resulting from muscle healing).²⁴

In addition, ultrasound use to guide muscle hematoma puncture procedures is also described. It is believed that extensive hematomas on lesion site would make proper healing of the affected tissue difficult.^{25,26} There is even the recommendation to perform an ultrasound 1 week after the lesion, since the hematoma could not be easily aspirated before such period.^{4,12,27}

Regarding complications resulting from hematoma puncture, similarly to what was found in this work, the rate of severe complications of ultrasound-guided punctures is low.²⁶

The amateur athletes group treated only with physical therapy presented a longer average period, of 104.7 days, to return to sport. This can be partially justified by the lower commitment of amateur athletes with the proposed treatment. Moreover, the three amateur athletes, even after cleared for physical activities, were afraid to return to sport and chose to perform more physical therapy sessions. These factors certainly influenced to increase the time to return to sport observed in the amateur group compared with the professional group.

On the other hand, amateur athletes submitted to muscle hematoma puncture performed a lower number of physical therapy sessions (on average, 12.50 versus 28.60 days) and their returned to sports was quicker. The average time to return to sport was of 54.16 days and it represented about half the time from the control group. These results favored hematomas puncture on this group.

A few papers in the literature state the time to return to sport in amateur athletes with more severe muscle injuries. The complexity of research in this group probably results

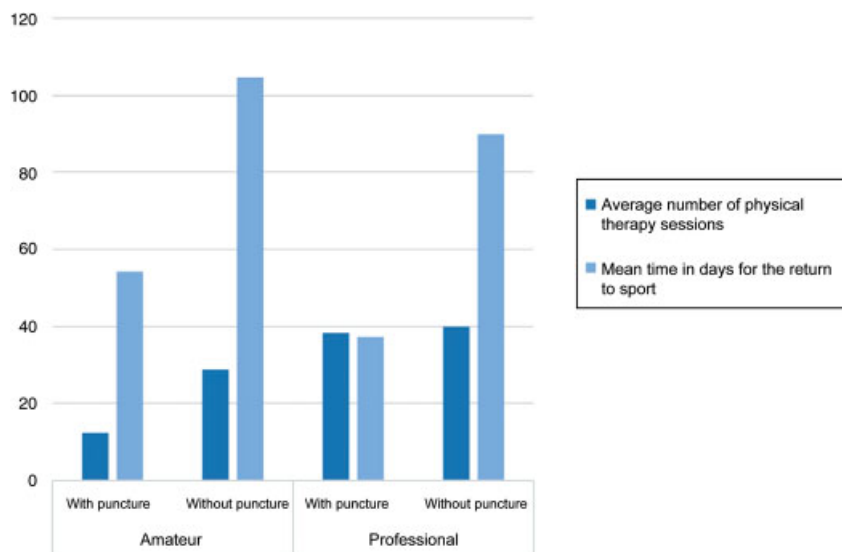


Fig. 3 Amateur (left) and professional athletes (right) groups. The intervention is evaluated among amateur and professional athletes and confronted with the control group through the following variables: average number of physical therapy sessions and mean time, in days, for the return to sport.

from the longer period required for rehabilitation, the need of serial medical follow-up and the difficulty controlling several variables, such as physical therapy. A group of amateur athletes with more severe muscle injuries was studied, and, at the end of the research, 4 athletes presented an average time to return to sport of 67 weeks, ranging from 40 to 104.²⁸ This period is considerably higher than the average observed in the present study, and it reflects the heterogenous evolution of the different injury types according to the athlete's age, the size of the lesion, its location (more proximal), the affected thigh region, the lesion mechanism (stretching or running) and also the criteria used to define the return to sport.^{28,29}

Regarding professional athletes, there is enough information in the medical literature about muscle injuries, especially in the posterior thigh of soccer players. However, there is a similar difficulty in controlling the several variables involved in the study of the muscle injury, and there are few publications with a high scientific evidence level about the time to return to sport. The quicker return to sport in this group is probably influenced by the higher commitment of the athletes and the higher number of physical therapy sessions. However, despite such factors, muscle hematoma puncture also reduced the time to return to sport in the professional athletes' group of this work.

A recently published study revealed the mean time to return to sport of 37.90 ± 24.00 days in moderate lesions at the anterior thigh.³⁰ This published data is analogous to the results observed in our study, with the case of a professional soccer player with a similar injury at the anterior thigh that returned to sport in 35 days after hematoma puncture. The similar time probably results from the fact that muscle puncture is already used in high-performance soccer players although its efficacy lacks scientific proof.

In addition to the possible limitations already mentioned, this work presented some other valuable questions. The studied population had few women. The age of the participants was inhomogeneous, and it is possible that the evolution time of the muscle injuries differs among sports. Moreover, there was a variation in the moment when the hematoma punctures were performed, and we do not know for sure if there is a difference in the muscle healing evolution at the early (3 days) or late (21 days) phase of hematoma formation. Other limitations were the lack of randomization, and the small number of participants in the sample. Therefore, further studies are required to corroborate these findings and elucidate the questions raised.

Conclusions

This study demonstrated that a muscle hematoma puncture is effective in reducing the time to return to sport in athletes with moderate, partial and (sub)total muscle injuries associated to hematomas.

Conflicts of Interest

The authors have no conflicts of interest to declare.

References

- Cohen M, Abdalla RJ, Eijnisman B, Amaro JT. Lesões ortopédicas no futebol. *Rev Bras Ortop* 1997;32(12):940-4
- Pas HI, Reurink G, Tol JL, Weir A, Winters M, Moen MH. Efficacy of rehabilitation (lengthening) exercises, platelet-rich plasma injections, and other conservative interventions in acute hamstring injuries: an updated systematic review and meta-analysis. *Br J Sports Med* 2015;49(18):1197-205
- Mishra DK, Fridén J, Schmitz MC, Lieber RL. Anti-inflammatory medication after muscle injury. A treatment resulting in short-term improvement but subsequent loss of muscle function. *J Bone Joint Surg Am* 1995;77(10):1510-9
- Orlandi D, Corazza A, Arcidiacono A, Messina C, Serafini G-Sconfienza LM, et al. Ultrasound-guided procedures to treat sport-related muscle injuries. *Br J Radiol* 2016;89(1057):20150484
- Kalimo H, Rantanen J, Järvinen M. Muscle injuries in sports. *Baillieres Clin Orthop*. 1997;2(1):1-24
- Warren GL, O'Farrell L, Summan M, Hulderman T, Mishra D, Luster MI, et al. Role of CC chemokines in skeletal muscle functional restoration after injury. *Am J Physiol Cell Physiol* 2004;286(5):C1031-6
- Tidball JG. Inflammatory cell response to acute muscle injury. *Med Sci Sports Exerc* 1995;27(7):1022-32
- Järvinen TA, Järvinen TL, Kääriäinen M, Kalimo H, Järvinen M. Muscle injuries: biology and treatment. *Am J Sports Med* 2005;33(5):745-64
- Järvinen MJ, Lehto MU. The effects of early mobilisation and immobilisation on the healing process following muscle injuries. *Sports Med* 1993;15(2):78-89
- Bedair HS, Karthikeyan T, Quintero A, Li Y, Huard J. Angiotensin II receptor blockade administered after injury improves muscle regeneration and decreases fibrosis in normal skeletal muscle. *Am J Sports Med* 2008;36(8):1548-54
- Mueller-Wohlfahrt HW, Haensel L, Mithoefer K, Ekstrand J, English B, McNally S, et al. Terminology and classification of muscle injuries in sport: the Munich consensus statement. *Br J Sports Med* 2013;47(6):342-50
- Maffulli N, Oliva F, Frizziero A, Nanni G, Barazzuol M, Via AG, et al. ISMuLT Guidelines for muscle injuries. *Muscles Ligaments Tendons J* 2014;3(4):241-9
- Reid DC. *Sports injury, assessment and rehabilitation*. New York: Churchill Livingstone; 1992
- Reid A, Birmingham TB, Stratford PW, Alcock GK, Giffin JR. Hop testing provides a reliable and valid outcome measure during rehabilitation after anterior cruciate ligament reconstruction. *Phys Ther* 2007;87(3):337-49
- Rubin DA. Imaging diagnosis and prognostication of hamstring injuries. *AJR Am J Roentgenol* 2012;199(3):525-33
- Ekstrand J, Healy JC, Waldén M, Lee JC, English B, Häggglund M. Hamstring muscle injuries in professional football: the correlation of MRI findings with return to play. *Br J Sports Med* 2012;46(2):112-7
- Ekstrand J, Häggglund M, Waldén M. Epidemiology of muscle injuries in professional football (soccer). *Am J Sports Med* 2011;39(6):1226-32
- Freckleton G, Pizzari T. Risk factors for hamstring muscle strain injury in sport: a systematic review and meta-analysis. *Br J Sports Med* 2013;47(6):351-8
- Foreman TK, Addy T, Baker S, Burns J, Hill N, Madden T. Prospective studies into the causation of hamstring injuries in sport: a systematic review. *Phys Ther Sport* 2006;7:101-9
- Prior M, Guerin M, Grimmer K. An evidence-based approach to hamstring strain injury: a systematic review of the literature. *Sports Health* 2009;1(2):154-64
- Fernandes TL, Pedrinelli A, Hernandez AJ. Muscle injury - physiopathology, diagnosis, treatment and clinical presentation. *Rev Bras Ortop* 2015;46(3):247-55

- 22 Askling CM, Malliaropoulos N, Karlsson J. High-speed running type or stretching-type of hamstring injuries makes a difference to treatment and prognosis. *Br J Sports Med* 2012;46(2):86–7
- 23 Askling CM, Tengvar M, Saartok T, Thorstensson A. Acute first-time hamstring strains during slow-speed stretching: clinical, magnetic resonance imaging, and recovery characteristics. *Am J Sports Med* 2007;35(10):1716–24
- 24 Tok F, Özçakar L, De Muynck M, Kara M, Vanderstraeten G. Musculoskeletal ultrasound for sports injuries. *Eur J Phys Rehabil Med* 2012;48(4):651–63, quiz 707
- 25 Cheng Y, Yang HL, Sun ZY, Ni L, Zhang HT. Surgical treatment of gastrocnemius muscle ruptures. *Orthop Surg* 2012;4(4):253–7
- 26 Dave RB, Stevens KJ, Shivaram GM, McAdams TR, Dillingham MF, Beaulieu CF. Ultrasound-guided musculoskeletal interventions in American football: 18 years of experience. *AJR Am J Roentgenol* 2014;203(6):W674–W83
- 27 Peetrons P. Ultrasound of muscles. *Eur Radiol* 2002;12(1):35–43
- 28 Askling CM, Tengvar M, Saartok T, Thorstensson A. Proximal hamstring strains of stretching type in different sports: injury situations, clinical and magnetic resonance imaging characteristics, and return to sport. *Am J Sports Med* 2008;36(9):1799–804
- 29 Sherry MA, Johnston TS, Heiderscheit BC. Rehabilitation of acute hamstring strain injuries. *Clin Sports Med* 2015;34(2):263–84
- 30 Ekstrand J, Askling C, Magnusson H, Mithoefer K. Return to play after thigh muscle injury in elite football players: implementation and validation of the Munich muscle injury classification. *Br J Sports Med* 2013;47(12):769–74