

Efficacy and safety of combined high-dose interferon and red light therapy for the treatment of human papillomavirus and associated vaginitis and cervicitis

A prospective and randomized clinical study

Hui-Juan Shi, MD^{a,*}, Hongbin Song, MD^b, Qian-Ying Zhao, MD^c, Chun-Xia Tao, MS^d,
Min Liu, BS^a, Qin-Qin Zhu, MS^d

Abstract

Background: We evaluated the efficacy and safety of combined high-dose interferon (IFN) and red light therapy for the treatment of subclinical and latent human papillomavirus (HPV) infections.

Methods: Ninety women diagnosed with subclinical or latent HPV infection were randomized to receive topical application of low-dose recombinant IFN α -2b (1 million IU), high-dose IFN α -2b (9 million IU), or a combination of high-dose IFN α -2b and red light therapy on the cervix and vagina. All patients received treatment once daily for 4 weeks. HPV titer was measured immediately and 4, 8, and 12 weeks after treatment to determine the rates of viral clearance and infection cure. Treatment of HPV-associated vaginitis and cervicitis was also evaluated.

Results: Results showed that immediately and 4, 8, and 12 weeks after treatment, the HPV clearance rates and infection cure rates were higher in the high-dose IFN and combination groups compared to the low-dose IFN group. High-dose IFN and combination therapies were significantly effective against both low-risk and high-risk HPV infections. Although the cure rates for vaginitis and cervicitis were significantly higher in the high- compared to the low-dose IFN group, rates were even higher in the combination group compared to the high-dose IFN group. Mild adverse effects were reported by a very small subset of patients (3/30) in the combination group.

Conclusions: This study suggests that combination of high-dose IFN and red light therapy is safe and effective against subclinical and latent HPV infections.

Abbreviations: CA = condylomata acuminata, CI = confidence interval, CIN = cervical intraepithelial neoplasia, CO₂ = carbon dioxide, HPV = human papillomavirus, IFN = interferon, PDT = photodynamic therapy.

Keywords: human papillomavirus, interferon, latent infection, subclinical infection

Editor: Mehmet Bakir.

H-JS and HS contributed equally to the article.

The abstract of the present study was presented at the 13th Chinese Medical Association National Laser Medical Conference, 23–25 September 2016, Wuhan, Hubei Province, China and was published as Abstract page 288 in *Chin J Laser Med Surg* 25(5), 2016.

The authors have no conflicts of interest relevant to this article.

^a Department of Dermatovenereology, Ningxia Medical University General Hospital, Yinchuan, ^b Department of Dermatology, Chinese PLA General Hospital, Beijing, ^c Medical Experimental Center, Ningxia Medical University General Hospital, ^d Department of Dermatovenereology, Ningxia Yangguang Hospital, Yinchuan, China.

* Correspondence: Hui-Juan Shi, Department of Dermatovenereology, Ningxia Medical University General Hospital, 804 Shengli South Street, Xingqing District, Yinchuan City, Ningxia Hui Autonomous Region, China (e-mail: shjyj@163.com).

Copyright © 2018 the Author(s). Published by Wolters Kluwer Health, Inc. This is an open access article distributed under the terms of the Creative Commons Attribution-Non Commercial-No Derivatives License 4.0 (CCBY-NC-ND), where it is permissible to download and share the work provided it is properly cited. The work cannot be changed in any way or used commercially without permission from the journal.

Medicine (2018) 97:37(e12398)

Received: 10 November 2017 / Accepted: 24 August 2018

<http://dx.doi.org/10.1097/MD.0000000000012398>

1. Introduction

In recent years, the incidence of human papillomavirus (HPV) infection has increased, prompting further investigation of HPV biology and pathogenesis. HPV infection may be clinical (manifested by visible lesions), subclinical, or latent,^[1] and most genital HPV infections are classified as 1 of these 3 types.^[2] The most important biomarker of HPV infection is the detection of HPV DNA.^[3] Infections can be considered high- or low-risk, with high-risk infections having tumorigenic potential. Persistent high-risk HPV infection is closely related to cervical cancer and some genital tumor lesions.^[4–6] In fact, the majority of invasive cervical cancers worldwide are HPV positive.^[4] In addition, HPV infection can contribute to vaginitis and cervicitis. Srivastava et al^[7] reported that a significant increase in HPV prevalence was associated with increased severity of cervicitis, cervical intraepithelial neoplasia (CIN), and cervical cancer, suggesting that HPV may be an important risk factor in disease progression. It was reported that the rate of HPV infection in chronic cervicitis cases was 98.7% (78/79).^[8] In addition, bacterial infections appear to facilitate persistent HPV infections.^[9]

Conventional treatments for visible lesions include cryotherapy, carbon dioxide (CO₂) therapy, laser therapy, and surgical

excision. However, these therapies lack tissue specificity. Moreover, as subclinical and latent HPV infections are sometimes located in the lower female genital tract, especially in the vaginal and cervical mucosa, treating these lesions remains difficult. Subclinical lesions and virus-shedding areas cannot be treated effectively and therefore contribute to the high recurrence rate.^[10] In the 1990s, 5-aminolevulinic acid-mediated photodynamic therapy (PDT) was developed for the treatment of nonmelanoma skin cancers^[11] and was widely used for the treatment of condylomata acuminata (CA).^[12] PDT is an attractive, noninvasive method for treating the lower female genital tract that is amenable to both topical drug application and light irradiation.^[13] However, PDT also has limitations. Because of the particular anatomical structure of female genitalia, light irradiation cannot reach the vaginal or cervical folds and thus, a subclinical or latent reservoir of HPV remaining in adjacent epithelial cells and mucous membranes cannot be completely eradicated. Because there are limited treatment options, HPV relapses occur frequently.^[14]

Interferon (IFN) exerts antiviral, immunoregulatory, and antitumor effects, and also plays critical roles in the innate immune response against viral infections by inhibiting the replication of HPV.^[15] Immunologic therapy with IFNs represents a promising antiviral modality that can be directed against all sites of infection, including clinical, subclinical, and latent disease.^[16] Previous studies reported that intralesional administration of IFN α is an effective and safe treatment for patients with recurrent or recalcitrant genital warts.^[17,18] IFNs have been used in the clinic for the treatment of HPV-associated CIN and cervical cancer, with mixed results.^[19] Some researchers found that high-dose IFN treatment caused growth arrest and apoptosis of HPV-positive squamous carcinoma cells, with episomal HPV DNA being eliminated from surviving cells.^[20] Furthermore, a study reported that the IFN-inducible protein, P56, inhibited HPV DNA replication by binding to the viral protein E1.^[15] However, the efficacy of IFN in the treatment of subclinical and latent HPV infections has not been established.

Phototherapy with visible light has gained recent attention in dermatological practice. Phototherapy is typically used for the treatment of acne vulgaris, seasonal affective disorders, psoriasis, eczema, and neurodermatitis.^[21] Red light (wavelength range: 620–770 nm) can penetrate the skin to a depth of about 6 mm and, thus, can affect fibroblasts of the skin dermis directly.^[22] Red light irradiation can be used to reduce skin inflammation, facilitate the resolution of inflammation, and enhance the immune function of skin.^[14] Animal studies have shown that red light irradiation enhances mitochondrial catalase activity, which improves cell metabolism and leads to increased glycogen and protein biosynthesis. These changes promote cell growth and wound healing.^[23,24]

We hypothesized that the beneficial effects of red light irradiation could also apply to the resolution of vaginitis and cervicitis caused by subclinical or latent HPV infection. In this study, we combined topical application of high-dose IFN and red light irradiation to treat HPV infections. We assessed 26 types of HPV DNA by flow-fluorescence in situ hybridization (flow-FISH) before and after treatment to investigate the effects of the combination therapy on viral clearance.

2. Patients and methods

2.1. Patients

A total of 90 female patients diagnosed with subclinical or latent HPV infection were recruited to outpatient clinics for sexually

transmitted diseases at Ningxia Medical University General Hospital (China) and Ningxia Yangguang Hospital (China) between April 2013 and May 2014. Date of patients diagnosed with subclinical or latent HPV infection clinical and/or molecular examination in the dermatological clinics of the General Hospital of Ningxia Medical University was collected as the previous clinical trials in which the cure rate of HPV was 50% after 12 weeks in the high-dose group, 80% in the combination group, and 30% in the low-dose group. Estimation of sample size is based on the minimal efficacy and maximum efficacy in previous clinical trials. Sample size calculations showed that when the cure rate of HPV at 12 weeks after treatment used as a major result indicator, the power of test is 0.90, and the alpha level is set at 0.05. Considering that up to 10% will be lost to follow-up, the study needed to recruit at least 76 participants. The final number of complete cases will be no <26 in each groups. This study sample of 90 patients included 72 patients (52 with subclinical and 20 with latent HPV infections) who presented with vaginitis or cervicitis. The cohort included 34 participants who had been diagnosed previously with CA and treated with CO₂ laser or cryotherapy; the sexual partners of 27 of these patients had a history of CA. The other 56 patients without a history of condyloma acuminata diagnosis had vaginitis or cervicitis and tested positive for HPV infection. Participants were excluded if, in addition to HPV, they also presented with gonorrhea, nongonococcal urethritis, autoimmune disease, or HIV infection, or were using systemic glucocorticoids. No patients were lost to follow-up after completion of therapy.

All patients were informed about the study and signed a detailed informed consent form describing the study design and possible adverse effects of topical application of high-dose IFN and red light therapy. This prospective study was approved by the Medical Ethics Committee affiliated with the Ningxia Medical University General Hospital.

A single-blind, parallel, single-center, randomized clinical trial was carried out. Randomization was performed based on random number tables. The 90 female patients were divided randomly into 3 treatment groups: low-dose IFN, high-dose IFN, or a combination of high-dose IFN and red light irradiation (N = 30 per group). Baseline characteristics, such as age, HPV infection type, and cases of vaginitis and cervicitis, were comparable among the 3 groups. However, some patients had single virus infection, whereas others may have 2 or more viruses infection, so the number of HPV infection in each group were as follows: N = 48 in low-dose IFN, N = 48 in high-dose IFN, and N = 52 in combination.

2.2. Diagnosis of HPV infection, vaginitis, and cervicitis

Subclinical HPV infections are macroscopically invisible, and are diagnosed when both the acetowhite test and flow-FISH results are positive. A latent HPV infection is confirmed negative by the acetowhite test, but positive by flow-FISH.^[25]

Nonspecific vaginitis was diagnosed based on the following symptoms: abnormal vaginal discharge, vaginal odor, and perineal stimulation (including genital itching, burning sensation, pain, or vaginal vestibular intercourse difficulty).^[26] Cervicitis was diagnosed based on 2 major characteristics: a purulent or mucopurulent endocervical exudate visible in the endocervical canal or on an endocervical swab specimen (commonly referred to as mucopurulent cervicitis) and sustained endocervical bleeding easily induced by gentle passage of a cotton swab through the cervical orifice. Either or both clinical signs may be

present. Cervicitis is frequently asymptomatic, but some women report abnormal vaginal discharge and intermenstrual or postcoital vaginal bleeding.^[27] The infection is frequently associated with symptoms such as burning, fissuring, and dyspareunia.^[28]

2.3. Specimen collection

Specimens were collected before; immediately after; and 4, 8, and 12 weeks after treatment. Secretions in the cervix and vagina were first cleared with a sterilized cotton swab. The mucosal epithelium of the cervix and its surroundings were collected by a swab dipped in physiological saline solution for no <30 seconds. Specimens were frozen at -80°C until further processing. Isolated DNA was stored at -20°C .

2.4. Flow-FISH

Samples for polymerase chain reaction (PCR) were prepared by mixing the PCR premix (Shanghai Tellgen Life Science Co Ltd, Shanghai, China), primers, and polymerase, and dispensing them into PCR reaction tubes. The specimen supernatant ($5\ \mu\text{L}$) was added to the PCR tubes, and samples were centrifuged at 2000 rpm for 10 seconds. PCR cycling parameters were set as follows: 5 cycles of 95°C for 5 minutes, 95°C for 30 seconds, 58°C for 30 seconds, and 72°C for 30 seconds, followed by 35 cycles of 95°C for 30 seconds, 55°C for 30 seconds, 72°C for 30 seconds, and an annealing/extension step at 72°C for 3 minutes. The temperature of the Luminex 200 instrument microwell plate was set to 48°C , and the preheating course took 30 minutes. During this period, in situ hybridization was performed. Three microliters of PCR-amplified product were denatured at 95°C for 5 minutes and hybridized at 48°C for 30 minutes. Then, $75\ \mu\text{L}$ of fluorescein SA-PE were added to each well on the hybrid plate, mixed, sealed, and incubated for an additional 15 minutes at 48°C . The microporous hybridization plate was transferred quickly to a preheated Luminex 200 flow analyzer for HPV titer measurement. Specimen testing was conducted by an author (Q-YZ) who was blinded to group assignments.

2.5. Treatment of patients

Patients receiving low-dose IFN were arranged in the lithotomy position such that the vulva was fully exposed. Cervical and vaginal secretions were first cleared using a sterilized cotton ball. Recombinant human IFN α -2b cream (1 million IU) was applied to the cervix and vagina. For patients in the high-dose IFN group, cervical and vaginal secretions were cleared as described above. The patient's hips were elevated by a bolster. Three vials of injectable recombinant human IFN α -2b (9 million IU) were dissolved in 6 mL of physiological saline and applied externally to the cervix and vagina using gauze for no <3 hours. For patients in the combination group, cervical and vaginal secretions were cleared, and recombinant human IFN α -2b (9 million IU) was applied externally as described above. Then, with the help of a vaginal dilator, the ML-1201 red light therapeutic instrument was positioned over the cervix and vagina. Red light was emitted for 20 minutes at a distance of <5 cm with an output power of 7 to 10 W. All groups were treated once a day for 4 weeks, except during menstruation. All patients were prohibited from sexual intercourse during the course of treatment and were advised to use condoms during intercourse for 3 months after treatment.

2.6. Reagents and red light instrumentation

Recombinant human IFN α -2b used for injections (3 million IU/vial) was produced by Hainan Unipul Pharmaceutical Co Ltd, Hainan, China. Recombinant human IFN α -2b topical cream (1 million IU/vial) was produced by Anhui Anke Biotechnology Group Co Ltd, Hefei, China. Fluorescence detection kits for HPV nucleic acid amplification (Shanghai Tellgen Life Science Co Ltd, Shanghai, China) were used to detect high-risk HPV-16, 18, 26, 31, 33, 35, 39, 45, 51, 52, 53, 55, 56, 58, 59, 66, 68, 82, and 83, and low-risk HPV-6, 11, 40, 42, 44, 61, and 73. HPV DNA was detected by flow-FISH using the Luminex 200 (USA). The red light therapeutic instrument (ML-1201; Wuhan Miracle Laser Co Ltd, Wuhan, China) had an output wavelength of 625 ± 10 nm and optical power density of 2.5 to 25 MW/cm² (continuously adjustable).

2.7. Determination of therapy efficacy

In this study, before treatment, some patients had single virus infection, whereas the others may have 2 or more viruses infection, so HPV clearance rate differs from patient cure rate after treatment (Fig. 1). The HPV clearance rate refers to the rate of clearance of 1 HPV type. The cure rate refers to the rate of clearance of all HPV types (cure of subclinical and latent HPV infections). The acetowhite test and flow-FISH were performed in all patients immediately and 4, 8, and 12 weeks after treatment to evaluate HPV clearance. Cure was confirmed if an acetowhite test and flow-FISH showed negative results and no symptoms of vaginitis or cervicitis were reported. The primary end point was the HPV infection cure rates at 12 weeks after treatment. The secondary end points included the HPV clearance rate, HPV-associated vaginitis, and cervicitis. Side effects were recorded throughout the whole study to assess the safety profile.

2.8. Statistical analysis

Data were analyzed by using the SPSS Version 17.0 statistical software package (IBM, Armonk, NY). A Pearson Chi Square test was used to compare data between groups. However, Fisher exact test was used to compare data between groups when 1 cell (25.0%) in a 2×2 table has an expected count of <5. A P value <.05 indicated statistical significance between all 3 groups, and a P value <.0125 indicated statistical significance when all groups were compared pairwise.

3. Results

The cohort included 65 HPV subclinical infections and 25 latent infections. Among the 90 patients recruited, 72 cases (including 52 subclinical and 20 latent HPV infections) also presented with vaginitis or cervicitis. Participants' mean age at the onset of treatment was 35.4 years (range 18–56 years) for the low-dose IFN group, 33.8 years (range 19–55 years) for the high-dose IFN group, and 35.2 years (range 18–58 years) for the combination group. Before treatment, there were no significant differences in the baseline characteristics of patients among the 3 groups (P for age = .736 and >.05; Table 1). All 90 patients had a complete follow-up.

HPV clearance rates and cure rates before; immediately after; and 4, 8, and 12 weeks after treatment are presented in Tables 2 and 3 and Figure 1. Before treatment, 55 of the 90 patients (61.11%) were diagnosed with high-risk or mixed HPV infection. At the end of treatment and at follow-up, HPV clearance rates and cure rates were significantly different among the 3 groups

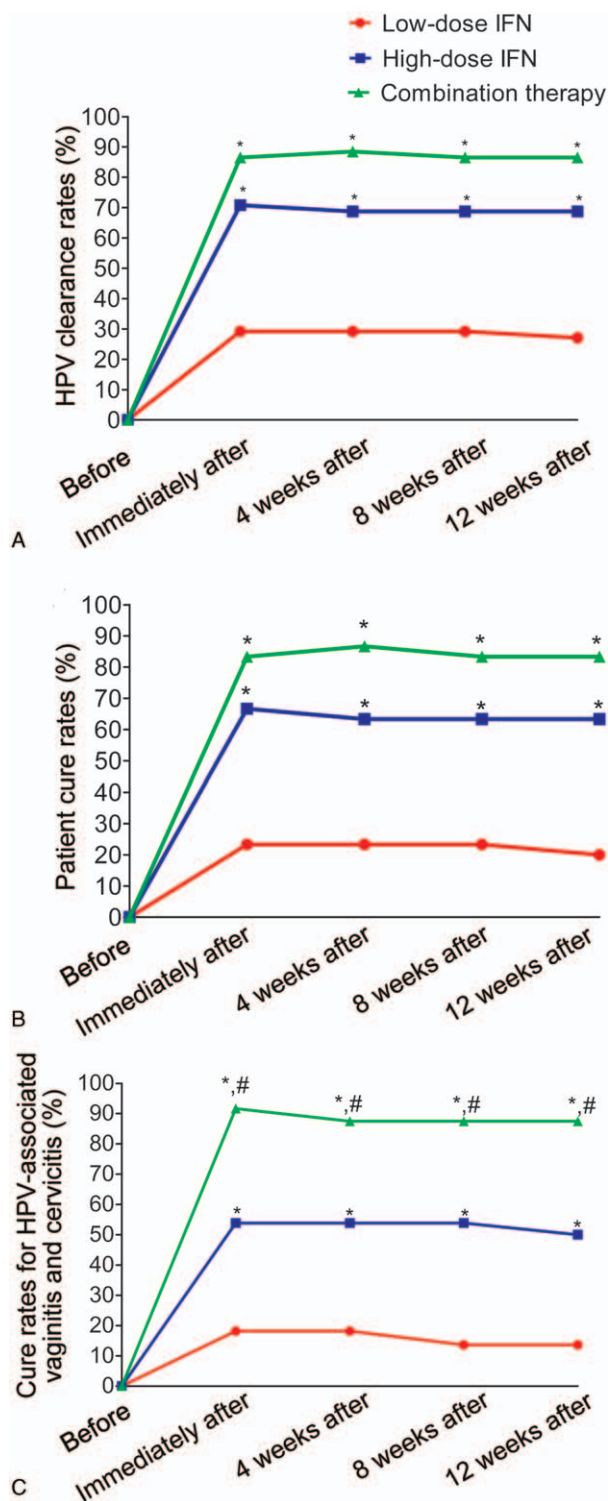


Figure 1. A, HPV clearance rates. B, Cure rates for subclinical and latent infections. C, Cure rates for HPV-associated vaginitis and cervicitis. **P* < .0125 vs low-dose IFN group; #*P* < .0125 vs high-dose IFN group. HPV = human papillomavirus, IFN = interferon,

(*P* < .001). At the end of treatment, HPV clearance rates were significantly higher in the high-dose IFN [70.83%; 95% confidence interval (CI), 54.56%–87.10%, *P* < .001] and combination groups (86.54%; 95% CI, 74.33%–98.75%, *P* < .001) compared to the low-dose IFN group (29.17%; 95%

CI, 12.90%–45.44%). Subclinical and latent infection cure rates were significantly higher in the high-dose IFN (66.67%; 95% CI, 49.80%–83.54%, *P* = .001) and combination groups (83.33%; 95% CI, 69.99%–96.67%, *P* < .001) compared to the low-dose IFN group (23.33%; 95% CI, 8.20%–38.46%). At 12 weeks after treatment, HPV clearance rates were significantly higher in the high-dose IFN (68.75%; 95% CI, 52.16%–85.34%, *P* < .001) and combination groups (86.54%; 95% CI, 74.33%–98.75%, *P* < .001) compared to the low-dose IFN group (27.08%; 95% CI, 11.18%–42.98%). Subclinical and latent infection cure rates were significantly higher in the high-dose IFN (63.33%; 95% CI, 46.09%–80.57%, *P* = .001) and combination groups (83.33%; 95% CI, 69.99%–96.67%, *P* < .001) compared to the low-dose IFN group (20.00%; 95% CI, 5.69%–34.31%). However, the high-dose IFN and combination groups were equally effective against both low-risk and high-risk HPV infections. Table 3 shows that cure rate of single virus and 2 viruses infection were significantly higher in combination group compared to low-dose IFN group (all *P* < .0125). And cure rate of single virus infection was significantly higher in high-dose IFN group (50.00%; 95% CI, 36.64%–63.36%) compared to low-dose IFN group (0%, *P* < .001) at 12 weeks after treatment.

Table 4 and Figure 1 demonstrate patients diagnosed with vaginitis or cervicitis before treatment, at the end of treatment, and during follow-up. At the end of treatment, cure rates for vaginitis and cervicitis were significantly higher in patients receiving high-dose IFN (53.85%; 95% CI, 36.01%–71.69%, *P* = .011) than those receiving low-dose IFN (18.18%; 95% CI, 4.38%–31.98%). And at 12 weeks after treatment, cure rates for vaginitis and cervicitis were significantly higher in patients receiving high-dose IFN (50.00%; 95% CI, 32.11%–67.89%, *P* = .011) than those receiving low-dose IFN (13.64%; 95% CI, 1.36%–25.92%). However, at the end of treatment, cure rates were even higher in the combination group (91.67%; 95% CI, 81.78%–100.00%, *P* = .003) compared to the high-dose IFN group (53.85%; 95% CI, 36.01%–71.69%), and at 12 weeks after treatment, cure rates were higher in the combination group (87.50%; 95% CI, 75.67%–99.33%, *P* = .003) compared to the high-dose IFN group (50.00%; 95% CI, 32.11%–67.89%), suggesting additive beneficial effects of the red light therapy.

One patient (3.33%) in the combination group experienced HPV infection recurrence 8 weeks after treatment. This patient, presenting with subclinical infection, exhibited HPV-42 and HPV-11 infections before treatment, which were not detected immediately or 4 weeks after treatment. However, HPV-11 infection was detected again at 8 and 12 weeks after treatment. The patient was also diagnosed with vaginitis before treatment, which was cured immediately after treatment. However, she was diagnosed with cervicitis at 4, 8, and 12 weeks after treatment. A second course of combination therapy with high-dose IFN and red light irradiation was conducted. The patient tested negative for all HPV types and the symptoms of cervicitis disappeared during the entire course of follow-up.

3.1. Adverse reactions

Mild adverse reactions were reported by 3 patients in the combination group during the study. These reactions included some burning and slight stinging of the treated area, which arose within 2 days of treatment but gradually subsided. There were no incidences of infection, ulcers, or local scarring, and no patients

Table 1
Baseline characteristics of patients in each treatment group.

Group	Cases N	Mean age, y	Subclinical infection, N	Latent infection, N	Vaginitis or cervicitis, N
Low-dose IFN	30	35.40 ± 7.99	20	10	22
High-dose IFN	30	33.77 ± 9.28	24	6	26
Combination	30	35.17 ± 8.84	21	9	24

IFN = interferon.

Table 2
Human papillomavirus, cure, and clearance rates before versus after treatment.

Group	Time relative to treatment	Cases N	Cases, N (%)			Cure rate (%)	HPV-positive N	HPV type, Low risk N (%)	N (%) High risk N (%)	Clearance rate, %	
			Low risk	High risk	Mixed						
Low-dose IFN	Before	30	12 (40.00)	11 (36.67)	7 (23.33)	23.33	48	26 (54.17)	22 (45.83)	–	
	Immediately after		8 (26.67)	10 (33.33)	5 (16.67)					29.17	
	4 Weeks after		8 (26.67)	10 (33.33)	5 (16.67)					23.33	29.17
	8 Weeks after		8 (26.67)	10 (33.33)	5 (16.67)					23.33	29.17
	12 Weeks after		8 (26.67)	11 (36.67)	5 (16.67)					20.00	27.08
High-dose IFN	Before	30	11 (36.67)	10 (33.33)	9 (30.00)	66.67*	48	27 (56.25)	21 (43.75)	–	
	Immediately after		3 (10.00)	4 (13.33)	3 (10.00)					70.83*	
	4 Weeks after		3 (10.00)	5 (16.67)	3 (10.00)					63.33*	68.75*
	8 Weeks after		3 (10.00)	5 (16.67)	3 (10.00)					63.33*	68.75*
	12 Weeks after		3 (10.00)	5 (16.67)*	3 (10.00)					63.33*	68.75*
Combination	Before	30	12 (40.00)	10 (33.33)	8 (26.67)	83.33*	52	28 (53.85)	24 (46.15)	–	
	Immediately after		1 (3.33)*	2 (6.67)*	2 (6.67)					86.54*	
	4 Weeks after		0 (0.00)*	2 (6.67)*	2 (6.67)					86.67*	88.46*
	8 Weeks after		1 (3.33)*	2 (6.67)*	2 (6.67)					83.33*	86.54*
	12 Weeks after		1 (3.33)*	2 (6.67)*	2 (6.67)					83.33*	86.54*

Cure rate reflects the percentage out of 30 patients. Clearance rate reflects percentage of HPVs cleared; the HPV positivity Ns sum low- and high-risk HPV types such that HPV-positive.

HPV = human papillomavirus, IFN = interferon.

* P < .0125 vs low-dose IFN group.

complained of fever, nausea, vomiting, fatigue, or dysuria during the course of the study.

4. Discussion

Cervical cancer is the third most common malignancy affecting women worldwide, after breast and colorectal cancers.^[29] Early

detection and treatment of precancerous lesions can prevent progression to cervical cancer.^[30] Many studies have revealed the close correlation between HPV infection and cervical cancer development.^[31] In fact, epidemiological studies have shown that HPV is necessary, if not sufficient, to cause nearly 100% of cases of cervical cancer.^[32] Infection with high-risk HPV variants causes CIN and invasive cervical cancer.^[33] Therefore, earlier detection of high-risk HPV types may improve triage, treatment, and follow-up in infected patients.^[30] This study showed that before treatment, about two thirds of participants had high-risk or mixed HPV infections. A research reported a similar incidence of high-risk HPV infection in a larger cohort (488/849; 57.48%).^[34]

Prognosis remains dismal in more than half of patients with HPV infection, prompting investigation of new treatments to eradicate infection. Methods for treating subclinical and latent HPV infections remain controversial. Some researchers suggested that asymptomatic HPV infection not be diagnosed or treated until realization of the pathogenic potential of the infection.^[28] Conversely, a study hypothesized that the relatively high recurrence rate of genital warts can be attributed to the unsuccessful elimination of viruses, especially subclinical or latent infection.^[35] According to this study, the identification and treatment of subclinical or latent infection are key to reducing recurrence.

A cross-sectional evaluation of HPV DNA prevalence in 13 areas across 11 countries indicated that approximately 6.6% of women in the age range of 15 to 74 years with normal cytology are carriers of HPV DNA,^[36] making HPV the most common known sexually transmitted agent worldwide.^[37] However, most

Table 3
Numbers of patients infected with 1, 2, or 3 human papillomavirus, types.

Group	Time relative to treatment	HPV infection, N		
		Single virus	Two viruses	Three viruses
Low-dose IFN	Before	14	14	2
	Immediately after	13	9	1
	4 Weeks after	13	9	1
	8 Weeks after	13	9	1
	12 Weeks after	14	9	1
High-dose IFN	Before	14	14	2
	Immediately after	6	4	0
	4 Weeks after	7	4	0
	8 Weeks after	7	4	0
	12 Weeks after	7*	4	0
Combination	Before	11	16	3
	Immediately after	3*	2*	0
	4 Weeks after	2*	2*	0
	8 Weeks after	3*	2*	0
	12 Weeks after	3*	2*	0

HPV = human papillomavirus, IFN = interferon.

* P < .0125 vs low-dose IFN group.

Table 4**Case features before versus after treatment.**

Group	Time relative to treatment	Cases N	Presentation, N				Cure rate, %
			Vaginitis	Cervicitis	Single infection	Mixed infection	
Low-dose IFN	Before	22	16	10	18	4	
	Immediately after	18	12	9	15	3	18.18
	4 Weeks after	18	12	9	15	3	18.18
	8 Weeks after	19	12	10	16	3	13.64
	12 Weeks after	19	12	10	16	3	13.64
High-dose IFN	Before	26	16	14	22	4	
	Immediately after	12	5	8	11	1	53.85*
	4 Weeks after	12	5	8	11	1	53.85*
	8 Weeks after	12	4	9	11	1	53.85*
	12 Weeks after	13	5	9	12	1	50.00*
Combination	Before	24	15	15	18	6	
	Immediately after	2	1	2	1	1	91.67*†
	4 Weeks after	3	0	3	3	0	87.50*†
	8 Weeks after	3	0	3	3	0	87.50*†
	12 Weeks after	3	0	3	3	0	87.50*†

IFN = interferon.

* $P < .0125$ vs low-dose IFN group.† $P < .0125$ vs high-dose IFN group.

HPV infections are self-limiting and regress spontaneously within 1 to 2 years owing to cell-mediated immunity.^[38] As HPV research demonstrated the high prevalence and transient nature of most cervical HPV infections, it became clear that the notion of inexorable CIN progression was incorrect.^[3] According to the 2012 updated consensus guidelines for the management of abnormal cervical cancer screening tests and cancer precursors,^[39] repeat cytology cotesting or colposcopy is recommended for HPV-positive women 30 years of age and older. Importantly, HPV infection clearance reduces the risk of CIN 3+ substantially.^[39,40]

However, in our study, 53 participants reported a history of high-risk sexual behaviors, and 34 of 90 patients reported a history of condyloma acuminata, and had been treated with CO₂ laser or cryotherapy. During a follow-up visit after wart removal, HPV was still detected in the vagina or cervix. Therefore, further treatment was necessary to prevent the recurrence of condyloma acuminata. Twenty-seven participants visited our clinic to be tested for HPV because their sexual partners had history of condyloma acuminata or were currently afflicted by condyloma acuminata. Upon diagnosis of subclinical or latent HPV infection, these 27 patients sought treatment to prevent condyloma acuminata and HPV-associated CIN. The remaining patients had been suffering from vaginitis or cervicitis, and obtained positive HPV test results. The prevention of condyloma acuminata or HPV-associated CIN remains to be evaluated in these patients in future studies. Given the benefits of treatment, we do not think our therapy is overtreatment, in conflict with the 2012 updated consensus guidelines for the management of abnormal cervical cancer screening tests and cancer precursors.^[39]

A study reported that HPV infections, particularly those caused by oncogenic variants, were prevalent among Chinese women with mucopurulent cervicitis or cervical cancer.^[6] Another study found that 78 of 79 patients with chronic cervicitis tested positive for HPV.^[8] In accordance with these studies, we found that before treatment, approximately 80% of patients were diagnosed with cervicitis and vaginitis, suggesting that HPV infection may cause local mucosal damage and contribute to cervicitis and vaginitis.

IFN signaling is one of the body's natural defenses against foreign components, such as microbes, tumors, and antigens. IFN engages in antiviral, antimicrobial, antitumor, and immunomodulatory actions.^[41] IFN-induced proteins with tetratricopeptide repeats are involved in protective responses against viral infections.^[42] IFNs can enhance the activation of cell-mediated cytotoxic effects and phagocytosis to improve host resistance to disease and exert antiviral effects.^[16] Disease can be effectively controlled by IFN when the HPV infection is subclinical or latent, and thus, cervical cancer incidence could potentially be prevented.

Patients in the high-dose IFN and combination groups experienced higher HPV clearance rates, subclinical and latent infection cure rates, and vaginitis and cervicitis cure rates than patients in the low-dose IFN group. These observations strongly suggest that high-dose IFN exerted greater curative effects than low-dose IFN. In a study, 16 patients with subclinical HPV infection were treated with weekly instillations of 25 million units of IFN α -2b for 6 weeks and followed for an average of 11.8 months. Nine of the 14 (64%) patients remained disease free throughout follow-up.^[43] We observed a very similar response to daily topical applications of 9 million units of IFN for 4 weeks.

Results from clinical trials have indicated that IFN therapy shows some efficacy in treating low-risk HPV-induced lesions; however, it is unclear whether similar effects occur in high-risk HPV infections, and the results remain controversial.^[44,45] In our study, we found that topical application of high-dose IFN or combination therapy was highly effective in treating not only low-risk HPV infections, but also high-risk infections.

Compared with a single HPV infection, multiple HPV infections in CA were related to a more severe disease and a worse prognosis,^[46] and therefore, curing multiple HPV infections is problematic. In our study (Table 3), the cure rates for a single viral infection and 2 infections were significantly higher in the combination group compared to the low-dose IFN group, suggesting that combination therapy is effective at treating both single and multiple HPV types. The cure rate for multiple viral infections was not significantly different between the low-dose and high-dose IFN groups, an effect that may have been observed due to insufficient sample size. Further studies are necessary to clarify this finding.

Red light exhibits strong penetrability and can be used clinically as a local or systemic treatment that exerts various biological effects, such as stimulation of cell proliferation, growth factor release, collagen deposition, and neovascularization.^[47,48] Animal studies have shown that red light irradiation enhances mitochondrial catalase activity to boost the biosynthesis of glycogen and proteins, ultimately promoting cell growth and wound healing.^[24] Red light therapy is also associated with repair and immunomodulatory functions and can enhance mucosal immunity, improve the local microenvironment, reduce skin inflammation, and prevent infection.^[14] HPV infection is likely to induce vaginitis and cervicitis; however, vaginitis and cervicitis also cause cervical mucosal damage and local microenvironmental changes that are conducive to the invasion and proliferation of HPV.^[49,50] We found that the cure rates for vaginitis and cervicitis were significantly higher when red light therapy was added to high-dose IFN, suggesting potentially additive effects of the red light on the immune microenvironment.

Some studies found that flu-like symptoms, such as fever, chills, myalgia, headache, fatigue, and leukopenia occurred in patients when IFN α was administered intralesionally to treat condylomata acuminata.^[14,23] Some patients even discontinued therapy because of more severe side effects.^[14] However, we only noted mild adverse reactions in 3 patients receiving the combination therapy, which included some burning and slight stinging that gradually subsided after treatment. Thus, topical application of high-dose IFN appears to be safe and well-tolerated.

In conclusion, topical application of high-dose IFN combined with red light therapy to treat subclinical and latent HPV infections resulted in a high viral clearance rate, high cure rate, and few adverse reactions. This safe and effective treatment strategy has the potential to prevent many conditions associated with HPV infection, including cervical cancer, and warrants further clinical investigation. Treating HPV subclinical and latent infections is still controversial, but is recommended when a diagnosed individual is at high-risk for HPV-associated conditions. For example, patients with a personal or sexual partner history of condyloma acuminata, those engaging in sex-related occupations or unprotected sex, those with multiple sexual partners, or those with poor genital hygiene may benefit greatly from IFN-related treatment. In the further study, the HPV positive patients with potentially pathogenic who come to the STD clinics will be divided into a treatment group and a non treatment group to explore whether immune system could play a role in the natural course of virus clearance.

Acknowledgments

The authors want to thank Hui Qiao, the epidemiologist of Ningxia Medical University, who gave us active help in statistical analysis. This manuscript has been edited and proofread by Medjaden Bioscience Limited.

Author contributions

Conceptualization: Chun-Xia Tao, Qin-Qin Zhu.
Data curation: Hongbin Song, Chun-Xia Tao, Min Liu.
Formal analysis: Hui-Juan Shi, Hongbin Song, Qin-Qin Zhu.
Investigation: Hui-Juan Shi, Hongbin Song, Min Liu.
Methodology: Hui-Juan Shi, Qian-Ying Zhao, Min Liu, Qin-Qin Zhu.
Project administration: Hongbin Song, Qian-Ying Zhao, Chun-Xia Tao, Min Liu, Qin-Qin Zhu.

Resources: Hui-Juan Shi.
Software: Hongbin Song, Min Liu.
Supervision: Hui-Juan Shi.
Validation: Hui-Juan Shi, Qin-Qin Zhu.
Visualization: Chun-Xia Tao.
Writing – original draft: Hui-Juan Shi, Hongbin Song.
Writing – review and editing: Hui-Juan Shi, Qian-Ying Zhao, Chun-Xia Tao, Min Liu, Qin-Qin Zhu.

References

- [1] Hoffmann M, Klose N, Gottschlich S, et al. Detection of human papillomavirus DNA in benign and malignant sinonasal neoplasms. *Cancer Lett* 2006;239:64–70.
- [2] Kumar B, Gupta S. The acetowhite test in genital human papillomavirus infection in men: what does it add? *J Eur Acad Dermatol Venereol* 2001;15:27–9.
- [3] Schiffman M, Wentzensen N. Human papillomavirus infection and the multistage carcinogenesis of cervical cancer. *Cancer Epidemiol Biomarkers Prev* 2013;22:553–60.
- [4] Walboomers JM, Jacobs MV, Manos MM, et al. Human papillomavirus is a necessary cause of invasive cervical cancer worldwide. *J Pathol* 1999;189:12–9.
- [5] Moscicki AB. Impact of HPV infection in adolescent populations. *J Adolesc Health* 2005;37(6 suppl):S3–9.
- [6] Shen XH, Liu SH. Human papillomavirus genotypes associated with mucopurulent cervicitis and cervical cancer in Hangzhou, China. *Asian Pac J Cancer Prev* 2013;14:3603–6.
- [7] Srivastava S, Shahi UP, Dibya A, et al. Distribution of HPV genotypes and involvement of risk factors in cervical lesions and invasive cervical cancer: a study in an Indian population. *Int J Mol Cell Med* 2014;3:61–73.
- [8] Mirzaie-Kashani E, Bouzari M, Talebi A, et al. Detection of human papillomavirus in chronic cervicitis, cervical adenocarcinoma, intra-epithelial neoplasia and squamous cell carcinoma. *Jundishapur J Microbiol* 2014;7:e9930.
- [9] Guo YL, You K, Qiao J, et al. Bacterial vaginosis is conducive to the persistence of HPV infection. *Int J STD AIDS* 2012;23:581–4.
- [10] Zaak D, Hofstetter A, Frimberger D, et al. Recurrence of condylomata acuminata of the urethra after conventional and fluorescence-controlled Nd:YAG laser treatment. *Urology* 2003;61:1011–5.
- [11] Blume JE, Oseroff AR. Aminolevulinic acid photodynamic therapy for skin cancers. *Dermatol Clin* 2007;25:5–14.
- [12] Zhang Z, Lu XN, Liang J, et al. Evaluation of photodynamic therapy using topical aminolevulinic acid hydrochloride in the treatment of condylomata acuminata. *Int J Clin Exp Med* 2015;8:6517–21.
- [13] Wang HW, Zhang LL, Miao F, et al. Treatment of HPV infection-associated cervical condylomata acuminata with 5-aminolevulinic acid-mediated photodynamic therapy. *Photochem Photobiol* 2012;88:565–9.
- [14] Shi H, Zhang X, Ma C, et al. Clinical analysis of five methods used to treat condylomata acuminata. *Dermatology* 2013;227:338–45.
- [15] Terenzi F, Saikia P, Sen GC. Interferon-inducible protein, P56, inhibits HPV DNA replication by binding to the viral protein E1. *EMBO J* 2008;27:3311–21.
- [16] Rockley PF, Tyring SK. Interferons alpha, beta and gamma therapy of anogenital human papillomavirus infections. *Pharmacol Ther* 1995;65:265–87.
- [17] Eron LJ, Judson F, Tucker S, et al. Interferon therapy for condylomata acuminata. *N Engl J Med* 1986;315:1059–64.
- [18] Friedman-Kien AE, Eron LJ, Conant M, et al. Natural interferon alfa for treatment of condylomata acuminata. *JAMA* 1988;259:533–8.
- [19] Koromilas AE, Li S, Matlashewski G. Control of interferon signaling in human papillomavirus infection. *Cytokine Growth Factor Rev* 2001;12:157–70.
- [20] Chang YE, Pena L, Sen GC, et al. Long-term effect of interferon on keratinocytes that maintain human papillomavirus type 31. *J Virol* 2002;76:8864–74.
- [21] Song E, Reja D, Silverberg N, et al. Phototherapy: kids are not just little people. *Clin Dermatol* 2015;33:672–80.
- [22] Niu T, Tian Y, Ren Q, et al. Red light interferes in UVA-induced photoaging of human skin fibroblast cells. *Photochem Photobiol* 2014;90:1349–58.
- [23] Holder MJ, Milward MR, Palin WM, et al. Effects of red light-emitting diode irradiation on dental pulp cells. *J Dent Res* 2012;91:961–6.

- [24] Reddy GK, Stehno-Bittel L, Enwemeka CS. Laser photostimulation accelerates wound healing in diabetic rats. *Wound Repair Regen* 2001;9:248–55.
- [25] Odom RB, James WD, Berger TG (ed.) *Viral diseases*. In: *Andrews' Diseases of the Skin Clinical Dermatology*. 9th ed. Science Press, Harcourt Asia W.B. SAUNDERS; 2001:509–520.
- [26] Amsel R, Totten PA, Spiegel CA, et al. Diagnostic criteria and microbial and epidemiologic associations. *Am J Med* 1983;74:14–22.
- [27] Workowski KA, Bolan GA. Centers for Disease Control and Prevention: sexually transmitted diseases treatment guidelines, 2015. *MMWR Recomm Rep* 2015;64:1–37.
- [28] Strand A, Rylander E. Human papillomavirus. Subclinical and atypical manifestations. *Dermatol Clin* 1998;16:817–22.
- [29] Arbyn M, Castellsagué X, De Sanjosé S, et al. Worldwide burden of cervical cancer in 2008. *Ann Oncol* 2011;22:2675–86.
- [30] Burd EM. Human papillomavirus and cervical cancer. *Clin Microbiol Rev* 2003;16:1–7.
- [31] Muñoz N, Bosch FX, de Sanjosé S, et al. International Agency for Research on Cancer Multicenter Cervical Cancer Study Group: epidemiologic classification of human papillomavirus types associated with cervical cancer. *N Engl J Med* 2003;348:518–27.
- [32] Chao A, Huang HJ, Lai CH. Human papillomavirus research on the prevention, diagnosis, and prognosis of cervical cancer in Taiwan. *Chang Gung Med J* 2012;35:297–308.
- [33] Coutlée F, Ratnam S, Ramanakumar AV, et al. Distribution of human papillomavirus genotypes in cervical intraepithelial neoplasia and invasive cervical cancer in Canada. *J Med Virol* 2011;83:1034–41.
- [34] Lin H, Ma YY, Moh JS, et al. High prevalence of genital human papillomavirus type 52 and 58 infection in women attending gynecologic practitioners in South Taiwan. *Gynecol Oncol* 2006;101:40–5.
- [35] Wang HW, Wang XL, Zhang LL, et al. Aminolevulinic acid (ALA)-assisted photodynamic diagnosis of subclinical and latent HPV infection of external genital region. *Photodiagnosis Photodyn Ther* 2008;5:251–5.
- [36] Clifford GM, Gallus S, Herrero R, et al. IARC HPV Prevalence Surveys Study Group: worldwide distribution of human papillomavirus types in cytologically normal women in the International Agency for Research on Cancer HPV prevalence surveys: a pooled analysis. *Lancet* 2005;366:991–8.
- [37] De Sanjosé S, Diaz M, Castellsagué X, et al. Worldwide prevalence and genotype distribution of cervical human papillomavirus DNA in women with normal cytology: a meta-analysis. *Lancet Infect Dis* 2007;7:453–9.
- [38] Cho HW, So KA, Lee JK, et al. Type-specific persistence or regression of human papillomavirus genotypes in women with cervical intraepithelial neoplasia 1: a prospective cohort study. *Obstet Gynecol Sci* 2015;58:40–5.
- [39] Massad LS, Einstein MH, Huh WK, et al. 2012 ASCCP Consensus Guidelines Conference: 2012 updated consensus guidelines for the management of abnormal cervical cancer screening tests and cancer precursors. *J Low Genit Tract Dis* 2013;17(5 suppl 1):S1–27.
- [40] Rodríguez AC, Schiffman M, Herrero R, et al. Proyecto Epidemiológico Guanacaste Group: rapid clearance of human papillomavirus and implications for clinical focus on persistent infections. *J Natl Cancer Inst* 2008;100:513–7.
- [41] Baron S, Tyring SK, Fleischmann WR Jr, et al. The interferons. Mechanisms of action and clinical applications. *JAMA* 1991;266:1375–83.
- [42] Varela M, Diaz-Rosales P, Pereiro P, et al. Interferon-induced genes of the expanded IFIT family show conserved antiviral activities in non-mammalian species. *PLoS One* 2014;9:e100015.
- [43] Levine LA, Elterman L, Rukstalis DB. Treatment of subclinical intraurethral human papilloma virus infection with interferon alfa-2b. *Urology* 1996;47:553–7.
- [44] De Palo G, Stefanon B, Rilke F, et al. Human fibroblast interferon in cervical and vulvar intraepithelial neoplasia associated with viral cytopathic effects. A pilot study. *J Reprod Med* 1985;30:404–8.
- [45] Frost L, Skajaa K, Hvidman LE, et al. No effect of intralesional injection of interferon on moderate cervical intraepithelial neoplasia. *Br J Obstet Gynaecol* 1990;97:626–30.
- [46] Cong X, Sun R, Zhang X, et al. Correlation of human papillomavirus types with clinical features of patients with condyloma acuminatum in China. *Int J Dermatol* 2016;55:775–80.
- [47] Yu W, Naim JO, Lanzafame RJ. Effects of photostimulation on wound healing in diabetic mice. *Lasers Surg Med* 1997;20:56–63.
- [48] Yu W, Naim JO, Lanzafame RJ. The effect of laser irradiation on the release of bFGF from 3T3 fibroblasts. *Photochem Photobiol* 1994;59:167–70.
- [49] Senba M, Buziba N, Mori N, et al. Human papillomavirus infection induces NF- κ B activation in cervical cancer: a comparison with penile cancer. *Oncol Lett* 2011;2:65–8.
- [50] Gillet E, Meys JF, Verstraelen H, et al. Bacterial vaginosis is associated with uterine cervical human papillomavirus infection: a meta-analysis. *BMC Infect Dis* 2011;11:10.