

PROCEDURAL COMPLICATIONS: PART 1

ADVANCED

CASE REPORT: TECHNICAL CORNER

Percutaneous Removal of a Pulmonary Artery Catheter Inadvertently Sutured to the Heart During Valve Surgery



Lohit Garg, MD, Jeffrey S. Arkles, MD, Robert D. Schaller, DO

ABSTRACT

A 74-year old woman underwent "mini-mitral" valve surgery via a right thoracotomy. The pulmonary artery catheter could not be removed thereafter and was found to be pierced by the atriotomy suture. Removal was performed by percutaneously lacerating the catheter above and below the suture, leaving behind a small segment. (**Level of Difficulty: Advanced.**) (J Am Coll Cardiol Case Rep 2020;2:2323-6) © 2020 The Authors. Published by Elsevier on behalf of the American College of Cardiology Foundation. This is an open access article under the CC BY-NC-ND license (<http://creativecommons.org/licenses/by-nc-nd/4.0/>).

A 74-year-old woman underwent mitral valve repair with a 26-mm annuloplasty ring and neochordae to the posteromedial scallop (P3) via a right thoracotomy and left atriotomy via Sondergaard's groove. Before the procedure, an 8-F pulmonary artery catheter (PAC) (Edwards Lifesciences, Irvine, California) was inserted into the right internal jugular (IJ) vein. After valve repair

was complete, the left atrium was closed with a running prolene suture. The following day, attempted removal of the PAC from the neck was met with resistance and a single port was found to be nonfunctional.

PAST MEDICAL HISTORY

Her past medical history was significant for severe mitral regurgitation and paroxysmal atrial fibrillation.

DIFFERENTIAL DIAGNOSIS

Inability to remove the PAC suggested that it had been entrapped on the right side of the heart by the running prolene suture. It was unclear if the suture was wrapped around the PAC, which could be amenable to focused traction from above or below, or had, in fact, pierced the PAC (**Figure 1A**), requiring a nontraditional or surgical solution.

LEARNING OBJECTIVES

- To appreciate a rare complication related to hemodynamic monitoring with a pulmonary artery catheter during mitral valve repair via thoracotomy.
- To consider a nontraditional, percutaneous solution of catheter removal with tools and techniques borrowed from cardiac electrophysiology.

From the Electrophysiology Section, Cardiovascular Division, Hospital of the University of Pennsylvania, Philadelphia, Pennsylvania, USA.

The authors attest they are in compliance with human studies committees and animal welfare regulations of the authors' institutions and Food and Drug Administration guidelines, including patient consent where appropriate. For more information, visit the [Author Center](#).

Manuscript received July 1, 2020; accepted July 31, 2020.

**ABBREVIATIONS
AND ACRONYMS**

F = French
IJ = internal jugular
IVC = inferior vena cava
LLD = lead-locking stylets
PAC = pulmonary artery catheter
SVC = superior vena cava

INVESTIGATIONS

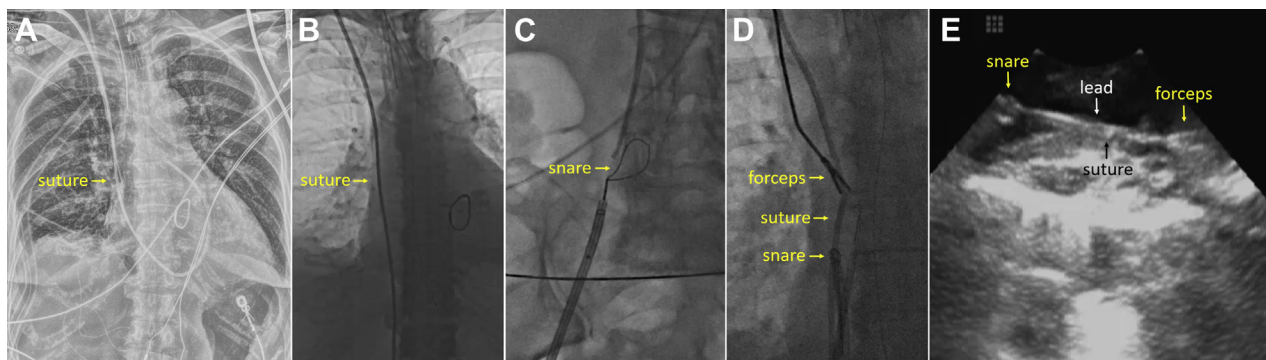
The patient presented to the interventional radiology laboratory where femoral venous access was acquired. The tip of the PAC was pulled down from the pulmonary artery to the inferior vena cava (IVC) with a deflectable sheath (Agilis, Abbott, Abbott Park, Illinois) (Figure 1B). It was then snared with a Goose Neck snare (ev3 Inc., Plymouth, Minnesota) distal to the suture and focused traction from below was applied. Resistance was once again appreciated and the PAC was unable to be removed. The patient was then referred for a repeated percutaneous removal attempt rather than undergoing surgical removal, which would require a sternotomy and cardiopulmonary bypass.

MANAGEMENT

The patient presented to the electrophysiology laboratory and was placed under general anesthesia. A cardiothoracic surgeon was immediately available in the case of a surgical emergency as was cross-matched blood. A 12-F sheath was inserted into the right IJ vein, adjacent to the PAC. A deflectable sheath (Agilis) was placed within the right femoral vein through which a Goose Neck snare (ev3 Inc.) was inserted and the PAC was secured below the suture (Figures 1C and 1D). A rigid, yet malleable, endobronchial forceps (Lymol Medical, Woburn, Massachusetts) was inserted through the IJ sheath and the PAC was grasped above the suture (Figure 1D, Video 1). A phased-array intracardiac echocardiography catheter

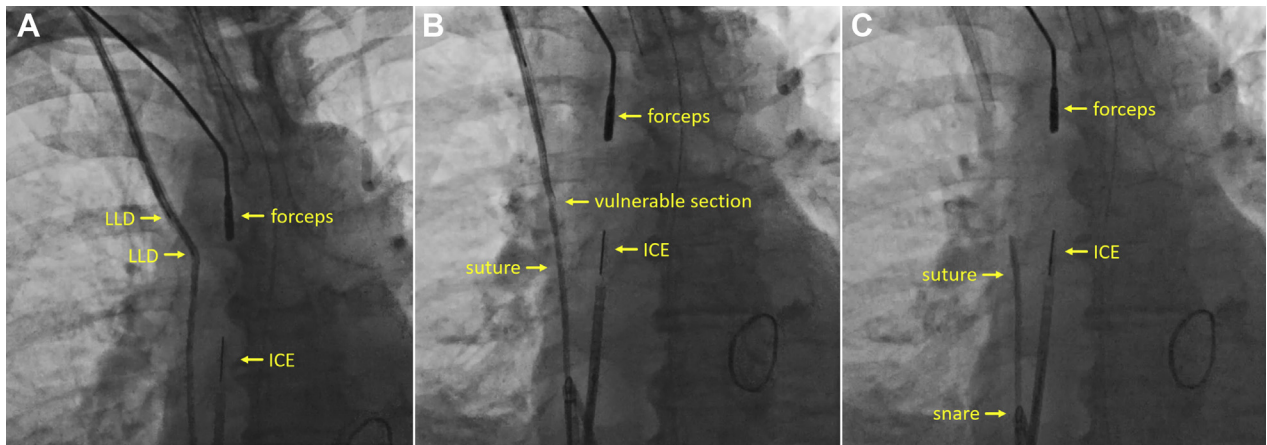
(ViewFlex Xtra, Abbott) was advanced through a 10-F femoral sheath to visualize the site of suture entrapment within the SVC (Figure 1E). Simultaneous traction from above and below resulted in the forceps repeatedly sliding off the hydrophilic PAC. The back end of the PAC was then cut, revealing 3 separate lumens, and lead-locking stylets (LLD, Philips, Colorado Springs, Colorado), traditionally used during transvenous lead extraction procedures, were placed in each lumen, ending just before the suture (Figure 2A, Video 2). These low-profile devices contain a wire mesh woven around an inner stylet, which when deployed, exert outward pressure, allowing for traction to occur over the entire lumen length. This created a region just distal to the LLD that was rendered vulnerable to laceration during traction (Figure 2B). Simultaneous traction from above and below in this new configuration resulted in the PAC lacerating just distal to the LLDs and superior to the SVC suture, followed by removal of this segment from the neck (Figures 2B and 2C, Video 3).

The Goose Neck snare from below was removed and a similar snare was placed within the IJ sheath and placed around the tip of the PAC in the IVC and secured just inferior to the SVC suture (Figures 3A and 3B). The first Goose Neck snare was then redeployed from the femoral sheath and the PAC was secured just inferior to the first Goose Neck snare (Figure 3B). Simultaneous traction, with an attempt to keep the suture in a stable fluoroscopic position, resulted in laceration of the PAC between the 2 snares (Figure 3C, Video 4). The distal portion of the PAC was removed from the femoral vein, leaving behind a small fragment of PAC containing the SVC suture

FIGURE 1 Pre-Extraction Imaging and Securement of the Pulmonary Artery Catheter

(A) Chest radiograph showing the pulmonary artery catheter in place and the level of the suture. **(B)** The tip of the pulmonary artery catheter has been pulled down to the inferior vena cava. **(C)** A Goose Neck snare is placed over the pulmonary artery catheter from below. **(D)** Securement of the pulmonary artery catheter from above with forceps and below with a Goose Neck snare. **(E)** Intracardiac echocardiography visualization of the sutured segment before simultaneous traction.

FIGURE 2 Laceration of the Superior Portion of the Pulmonary Artery Catheter



(A) Lead-locking stylets (LLDs) placed within the pulmonary artery catheter lumens. (B) Simultaneous traction from above and below showing impending laceration distal to the LLDs. (C) Laceration of the pulmonary artery catheter superior to the superior vena cava suture. ICE = intracardiac echocardiography.

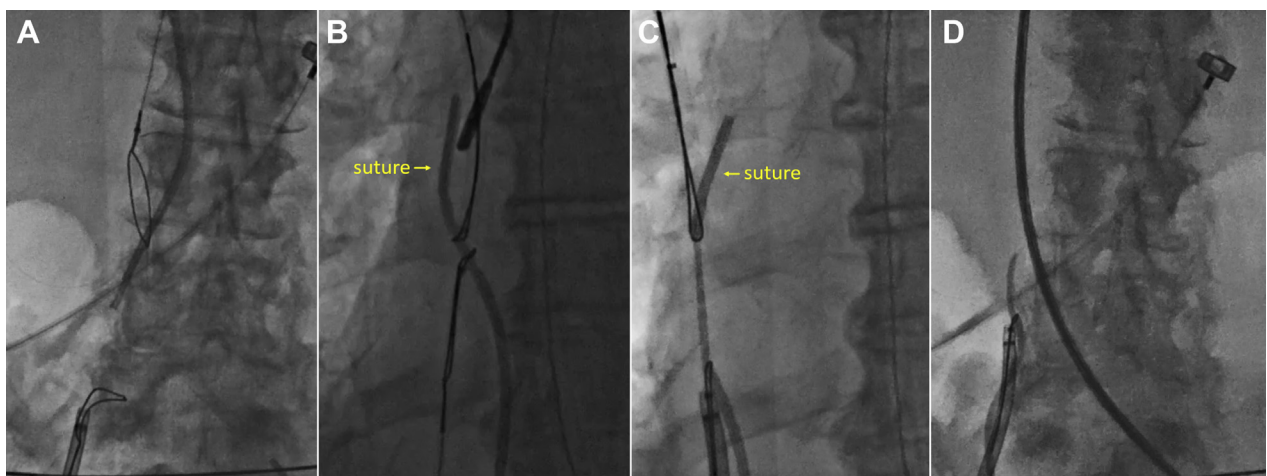
(Figures 3D, 4A, and 4B). There was no evidence of mitral valve disruption or pericardial effusion and the patient was discharged home the following day.

DISCUSSION

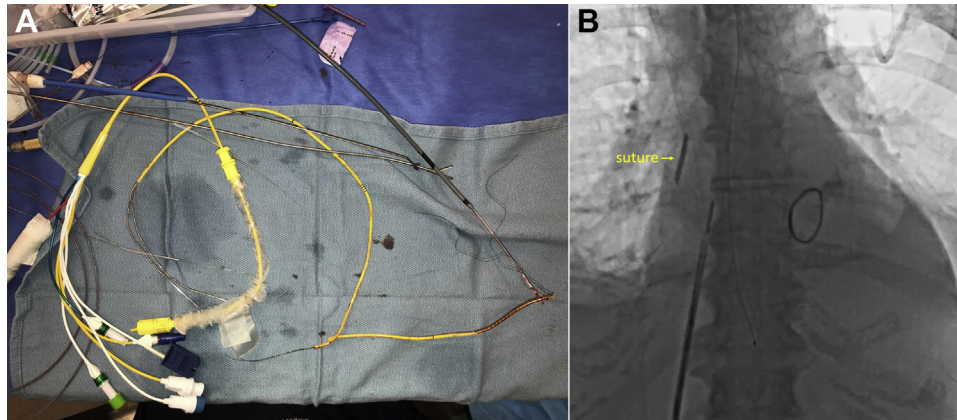
Catheter-based hemodynamic monitoring is routinely used during valvular surgery (1). Entrapment of a PAC by a suture has been described and has traditionally

required a surgical solution (2,3). Percutaneous techniques have generally been limited to unilateral traction in an effort to slide the catheter through the surrounding suture (4). Our case was unique in that the suture had pierced the PAC, as evidenced by a nonfunctional port, rendering this technique impossible. Simultaneous longitudinal traction resulting in laceration of a PAC at the level of the suture has been described, but this technique risks disruption of the

FIGURE 3 Laceration of the Inferior Portion of the Pulmonary Artery Catheter



(A) A Goose Neck snare from above being placed around the pulmonary artery catheter. (B) Goose Neck snares from above and below, both of which are inferior to the suture. (C) Simultaneous traction from above and below stretches the pulmonary artery catheter. (D) The pulmonary artery catheter has been lacerated and the inferior portion is removed from the femoral vein.

FIGURE 4 Residual Pulmonary Artery Catheter Fragment After Extraction

(A) The pulmonary artery catheter that has been removed from above and below. (B) A small fragment of pulmonary artery catheter, containing the suture, remains in the superior vena cava.

suture and the atriotomy (5). Our case, using tools borrowed from transvenous lead extraction, is the first to purposely abandon the segment of PAC that encompassed the suture, essentially using it as a PAC “pledget,” and thereby avoiding reoperation.

FOLLOW-UP

The patient has had no complications over a 2-year period. A recent chest radiograph confirms the PAC fragment to be in a stable position.

CONCLUSIONS

Removal of a PAC that has inadvertently been sutured to the heart is possible by using tools and techniques borrowed from other medical disciplines, including

cardiac electrophysiology. Because the PAC was pierced, this technique mandated a small section of PAC, containing the suture, to be left behind; unlikely to have clinical significance.

AUTHOR DISCLOSURES

This study was funded in part by the Jeffrey & Jo Ann Dickson Cardiac Electrophysiology Fund. The authors have reported that they have no relationships relevant to the contents of this paper to disclose.

ADDRESS FOR CORRESPONDENCE: Dr. Robert D. Schaller, Hospital of the University of Pennsylvania, 3400 Spruce Street, Philadelphia, Pennsylvania 19104, USA. E-mail: robert.schaller@penmedicine.upenn.edu. Twitter: [@rdschaller](https://twitter.com/rdschaller).

REFERENCES

- Rajaram SS, Desai NK, Kalra A, et al. Pulmonary artery catheters for adult patients in intensive care. *Cochrane Database Syst Rev* 2013;(2):CD003408.
- Kaplan M, Demirtas M, Cimen S, et al. Swan-Ganz catheter entrapment in open heart surgery. *J Card Surg* 2000;15:313-5.
- Vucins EJ, Rusch JR, Grum CM. Vent stitch entrapment of Swan-Ganz catheters during cardiac surgery. *Anesth Analg* 1984;63:772-4.
- Huang L, Elsharydah A, Nawabi A, Cork RC. Entrapment of pulmonary artery catheter in a suture at the inferior vena cava cannulation site. *J Clin Anesth* 2004;16:557-9.
- Matzko J, Matsumoto AH, Tegtmeier CJ, Spotnitz WD. Percutaneous removal of a Swan-Ganz catheter sutured to the superior vena cava. *J Vasc Interv Radiol* 1994;5:653-6.

KEY WORDS lead extraction, mitral valve, pledget, pulmonary artery catheter, snaring, thoracotomy, valve repair

APPENDIX For supplemental videos, please see the online version of this paper.