

Tumour devascularisation as a potential immunotherapeutic strategy

Tomas Buchler ^a, Pavel Vasek^b, Radek Spisek^c, Pavel Skrobanek^a, and Vaclav Horejsi ^d

^aDepartment of Oncology, First Faculty of Medicine, Charles University and Thomayer Hospital, Prague, Czech Republic; ^bEUC Premium s.r.o., Brno, Czech Republic; ^cDepartment of Immunology, 2nd Faculty of Medicine, Charles University and University Hospital Motol, Prague, Czech Republic; ^dInstitute of Molecular Genetics of the Czech Academy of Sciences, Prague, Czech Republic

ABSTRACT

Complete tumour devascularisation (CTD) is a surgical technique which entails the complete disruption by ligation or cutting of afferent and efferent tumour vasculature which remains in situ. In some animal models, CTD induces immune responses that lead to regression of distant metastases and protective immunity.

ARTICLE HISTORY

Received 18 June 2018
Revised 13 September 2018
Accepted 15 September 2018

KEYWORDS

Immunotherapy; ischaemia; devascularisation; cancer; tumour ligation

Introduction

The immune system plays an important role in carcinogenesis and cancer progression. Recently, novel immunotherapeutic strategies have enabled oncologists to exploit the potential anti-cancer immune responses, leading to improved survival of some cancers and even cure advanced malignancies in a minority of patients.

The concept that tumour devascularisation could induce immune responses which lead to protective immunity was pioneered by Lewis and Aptekman.¹ Additional experiments have shown that protective immunity is limited to highly immunogenic tumours such as those induced by 3-methylcholanthrene or tumours that have undergone substantial passaging.^{2–4} However, for these types of tumours simple excision also resulted in immunity.⁴ The evolution of these concepts has been previously reviewed by Gorelik.⁵

In the Czech Republic, the concept of tumour devascularisation (also called devitalisation) was developed by the surgeon Karel Fortýn.^{6–8} An experimental animal model for tumour devascularisation was developed⁸ and in 2001 a phase I study was carried out on patients with metastatic solid tumours.⁹

Treatment with complete tumour devascularisation (CTD) is virtually unknown outside the Czech Republic and is highly controversial even within the Czech medical community. Although the treatment is unapproved for clinical use in humans, CTD is occasionally used in veterinary medicine.

The aim of this review is to provide a brief overview of the method and a critical analysis of its potential within the spectrum of current antineoplastic immunotherapeutic strategies.

Induction of tumour ischaemia as immunotherapeutic strategy

Tumour ligation

The potential of tumour ischaemia to induce immune responses has been explored since the mid-20th century. In pioneering experiments published in 1951 and 1952, Lewis and Aptekman induced tumour regression in different breeds of rats by strangulation of vessels in syngeneic carcinomas, sarcomas and fibrosarcomas. The resulting ischemia-injured tumour was left in situ for 24 to 96 hours in accordance to study protocol. The procedure induced protective immunity from rechallenge with identical tumours in 70–100% of rats.^{1,10,11}

Among the many local treatments available, tumour ligation has been reported to induce a relatively strong inflammatory response and subsequently tumour-specific immune responses.^{12–15} Neel and Ritts have reported the results of a comparative study where mice carrying syngeneic tumours, including a virally induced mammary adenocarcinoma and a 3-methylcholanthrene-induced sarcoma, were subjected to rechallenge with tumour cells following simple excision, cryosurgery, electrocoagulation, excision of tumour ligated for either 4 or 24 hours, and ligation without excision. No protective immunity was generated by simple excision or excision after the 4-hour ligation. However, ligation without excision did result in less frequent or delayed appearance of tumours at the site of rechallenge, while outcomes for excision after 24-hour ligation fell in between those for simple excision and ligation without excision.¹⁴ In addition, it has also been reported that arterial embolisation potentially induces antitumor immunity in humans, although but no reliable data depicting the quantification of this effect are currently available.¹⁵

Induced ischemia-reperfusion injury of tumours

Several authors have carried out experiments to produce ischaemia-reperfusion injury of tumour tissue with the goal of inducing protective immune responses.^{16–18} Specific immunity to subsequent tumour inoculation challenge was superior after a 24-hour ligation/release procedure in comparison to tumour excision, preoperative irradiation followed by excision, cryosurgery, high-dose irradiation, and low-dose irradiation in mice bearing 3-methylcholanthrene-induced tumours.¹⁶ An eight-hour ligation with subsequent release of tumour vasculature was reported to induce a similar degree of protective immunity as that of cryosurgery while exceeding the effect of simple excision in a murine model.¹⁷ According to Kamijo et. al. ligation/release procedure significantly reduced the metastatic potential of tumours in a murine model which was inoculated with the murine osteosarcoma cell line, POS-1. This effect was attributed to a higher sensitivity to reactive oxygen species which were produced during reperfusion of the cell subpopulation with high metastatic potential.¹⁸

Technique of complete tumour devascularisation

CTD is a surgical technique which consists of the complete disruption of all afferent and efferent vasculature of a tumour by ligation or cutting, which is then left in situ (Figure 1). In both animal experiments and reported human procedures, parts of normal organs which harboured a tumour were also devascularised, e.g. the part of colon which received the same vascular supply as the tumour (Figure 2).^{6,19,20}

In order to facilitate the successful induction of an immune response by CTD several conditions have been proposed: a)

devascularisation of the primary tumour is preferred to that of metastasis; b) at least 50% of the total tumour mass in the body should be devascularised; c) the patient should not be pre-treated with standard regimens of chemotherapy or radiotherapy.^{19,20} A kinetic model has been developed to establish the optimal ratio between devascularised tumour and the remainder of the tumour mass.¹⁹

Various surgical techniques of tumour ligation have been also investigated. When ligation was performed through the skin, Lewis rats survived 20 days longer than those animals whose skin were incised, tumour isolated, ligated at the base, and re-sutured.²¹

Complete tumour devascularisation: preclinical studies

Hereditary porcine melanoma

A special strain of pig known as Melanoblastoma-bearing Libechov Minipig (MeLiM) has become the most frequently used model for CTD experiments by Czech scientists. Spontaneous multiple melanomas develop in approximately 60% of MeLiM pigs.⁸ The majority of melanomas (approximately 65%) spontaneously regress resulting in protective immunity and vitiligo, a commonly observed occurrence.⁸ Spontaneous melanomas occurring in MeLiM were shown to possess several characteristics which favour anti-tumour immune responses, including the expression of melanoma antigens TYR, MLANA, and gp100 and the constitutive expression of major histocompatibility antigens class I.²²

Due to hereditary melanoma, the mortality of the piglets from the Czech cohort has been reported at 34% up to two months of age.⁸ AA French cohort of MeLiM pigs also exists

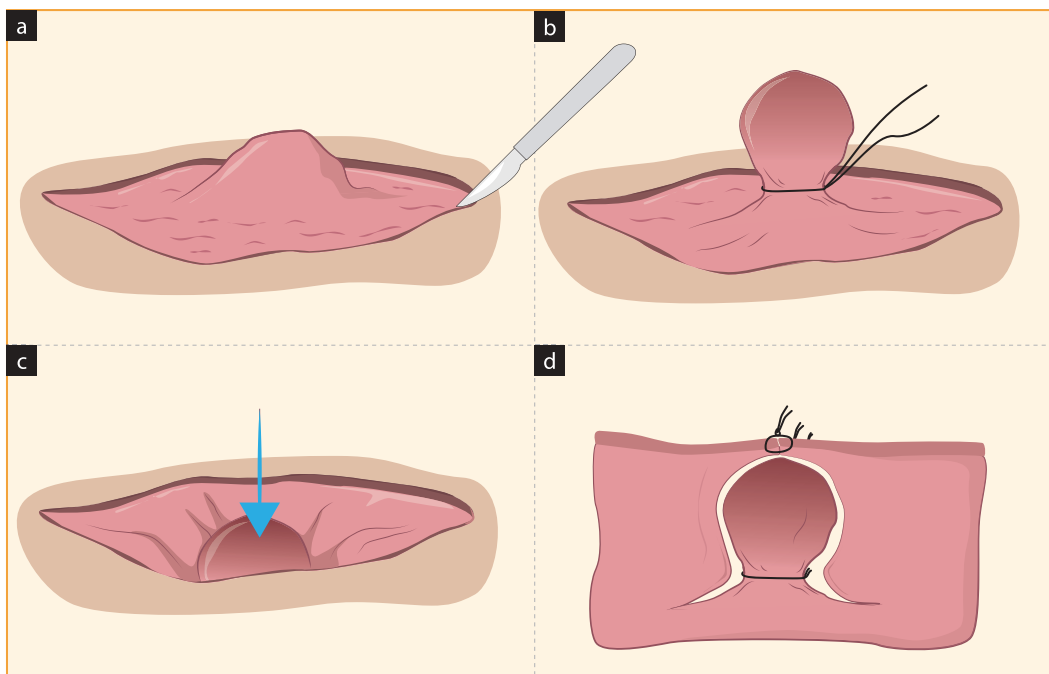


Figure 1. Complete tumour devascularisation requires permanent disruption of afferent and efferent vasculature.^{7,19} First, tumour is isolated (a) and its vascular and lymphatic supply is ligated (b). The ligated tumour is left in situ (c) and the wound is closed (d). Ligation through the skin is also possible if a tumour is superficially located, as in skin melanoma (adapted from a drawing by Karel Fortýn).

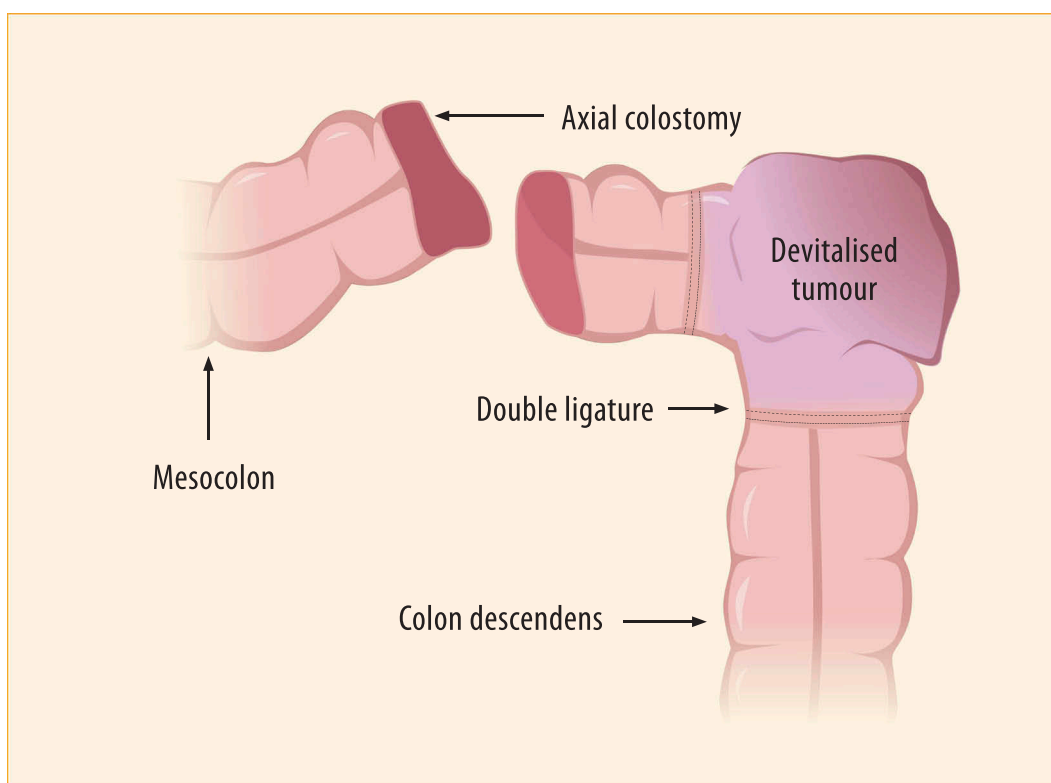


Figure 2. In some cases, the complete tumour devascularisation procedure may include the isolation of a part of the affected organ such as the colon, with reestablishment of passage by colostomy or anastomosis.⁶

in which the rate of spontaneous regression of the spontaneous melanomas has been observed to be as high as 96%.²³

In an experiment conducted by Horák et al., 40 MeLiM pigs aged between 1–2 months with advanced multifocal disease resulting in cachexia and a presumed poor prognostic outlook were treated by CTD. A complete response was achieved in all treated animals.⁸ The study did not, unfortunately, include a control i.e. non-interventional cohort of animals, hence the results could have been influenced by the very high rate of spontaneous tumour regression that is usually observed in MeLiM pigs.

The sequence of events following devascularisation of melanoma in the MeLiM model has been described by Horák et al.²⁴ Within 24 hours after ligation, increased levels of the heat-shock proteins HSP70 and HSP90 were detected in the treated tumour. The counts of CD8+ cytotoxic T cells and helper/memory T cells increased in the peripheral blood as well as in untreated skin tumours for approximately 1–3 weeks after the procedure while the concentrations of interleukin-8 decreased. The death of melanoma cells and their replacement with fibrous tissue was complete after 4–6 months.²⁴

Other animal models

The results of CTD of sarcomas have been less convincing than those recorded with melanoma in MeLiM pigs. Devascularisation of 50% of inoculated tumours in rats resulted in the regression of non-ligated tumour in 20% of these animals.²⁴ In addition, only a transient increase in HSP levels

was detected, without changes of T cell subtype counts. There was a pronounced increase in CD11b + CD45 + myeloid cells that may represent macrophages or myeloid-derived suppressor cells (MDSCs).²⁴

In dogs bearing wild type mammary gland cancers, increased counts of circulating CD8 + T cells were detected for up to approximately 40 days after ligation. Elevated levels of the heat-shock protein (HSP) 70 were also detected approximately one week after the procedure. The survival of these dogs after CTD was reported to be similar to that of animals treated with tumour excision.²¹ An increase in survival along with increased numbers of lung metastases were observed in Lewis rats that were inoculated with high- or low-grade sarcomas.²¹ It is well known that hypoxia induces epidermal-mesenchymal transition resulting in increased migration and metastasis of malignant cells and the phenomenon could explain the increased number of lung metastases in these experiments that used the highly malignant A297Nb sarcoma cell line and the less aggressive K2 cell line.²¹

Complete tumour devascularisation: clinical experience

The Czech pioneer of CTD, Karel Fortýn, treated approximately 20 patients with inoperable, advanced solid tumours. He reported that the majority of these patients recovered completely, including complete regression of distant metastases.^{6,7} Regrettably, it is now impossible to verify those studies independently because the surgeries were spread over several decades and the original medical records are lost.

In 2001, the work of Dr. Fortýn was 'discovered' by the media, triggering a sudden and renewed interest in the method among the Czech public, scientists, and clinicians in the subsequent years.

In 2001, a phase I clinical study was organised at four major Czech cancer centres, enrolling patients with metastatic colorectal carcinoma (mCRC) and melanoma. Unfortunately, the results of the clinical trial were never published in a peer-reviewed journal and are only available in the form of a letter from the Czech Ministry of Health.⁹ There were 25 enrolled patients with mCRC (16 men and 9 women) all diagnosed with advanced malignancy and were deemed unsuitable for conventional therapy, including chemotherapy, and radiotherapy. One of the patients achieved disease stabilisation while another patient remained tumour-free after one-year follow-up following complete resection of primary tumour and devascularisation of one lymphatic metastasis. No responses of distant metastases or significant improvements in quality of life were observed. There was no mortality associated with devascularisation surgery, although five cases of wound complications and one case of suppurative peritonitis were reported.⁹

The melanoma cohort included 26 patients (15 men and 11 women), of whom 24 were evaluable for safety, response and survival while two were lost to follow-up after surgery. One melanoma patient had two devascularisation procedures performed two months apart. Regression of devascularised tumour occurred in three of the 24 patients and disease stabilisation was observed in one patient, but distant metastases progressed in all patients. No improvements in quality of life were seen. There were four minor infectious wound complications. The study was discontinued prematurely due to concerns of medical futility cited by the monitoring committee.⁹

The study protocol was subsequently heavily criticised by proponents of CTD because the suggested preconditions for successful CTD outlined above were not met. However, several surgeons have conducted this type of surgery over the past 20 years, but these procedures have been carried out outside of a clinical trial framework, hence only case reports have been published.¹⁹

Immune response to complete tumour devascularisation

Studies suggest that ischaemic destruction of tumours activates innate and subsequently adaptive immunity. As outlined above, CTD results in acute ischaemia coupled with venous congestion and interruption of lymphatic drainage. Rapid cellular membrane disintegration which occurs in these dire metabolic conditions results in the release of several types of damage-associated molecular pattern molecules (DAMPs). The molecules that are released include HSPs, calreticulin, adenosine triphosphate (ATP), high mobility group box 1 protein (HMGB1) and other activators of innate immunity, leading to inflammation which is reflected by the increased production of interleukins-1 β and -18. In turn, these molecules then activate toll-like receptors (TLRs) 2 and 4 and

CD91 on dendritic cells promoting endocytosis of cell debris as well as tumour antigen processing and presentation.²⁵⁻²⁷

The entrapment of immunosuppressive cell populations such as MDSC and immature dendritic cells in the devascularised tumour could contribute to the immune response which is induced by CTD. MDSC are known to accumulate in hypoxic regions and the implementation of CTD could possibly interrupt MDSC supply to metastatic sites resulting in the reduction of the number of circulating MDSC that promote the formation and maintenance of metastases.²⁸

In addition, it has been shown that ischaemia leads to exposure of autoantigens which are recognised by pre-existing autoantibodies that in turn activate the complement cascade, leading to membrane damage, increased infiltration, and activation of neutrophils.²⁹

In 2011, Sheu et al. presented a study which demonstrated that ischemic insult to the primary tumour triggered inflammatory cascade and reduced the number of metastases in wild-type but not in Rag1 $-/-$ mice, which strongly suggested that adaptive immunity played a key role in the process.³⁰

Although specific CD8 + cells are deemed crucial for anti-tumour immunity, an antibody-mediated adaptive response plays a role in the abscopal effect of radiotherapy (see below) and contributes to the effect of anti-cancer vaccination.^{31,32}

The processes that putatively occur in devascularised tumours are summarised in (Figure 3).

Complete tumour devascularisation in context

While the benefits of CTD in patients with cancer remain unproven, it is well known that other locally destructive therapies can lead to regression of distant metastases. Two primary examples from the clinic are radiotherapy and intratumoural oncolytic viral therapy. The abscopal effect of radiotherapy results in immune-mediated regression of distant tumours after localised radiotherapy. Although the mechanisms are not fully understood, the release of DAMPs resulting in enhanced antigen presentation and T cell activation appear to play a key role.^{31,33} A significant decline of MDSC counts and increased antibody titers against NY-ESO1, a tumour antigen, have been observed in a detailed case study of the abscopal effect.³¹ Importantly, inhibitors of cytotoxic T lymphocyte-associated protein 4 (CTLA-4) and programmed cell death-1 (PD-1) increase the likelihood of the abscopal effect,³³ hence supporting the use of checkpoint inhibitors in future experiments involving CTD.

Intratumoural oncolytic therapy is already registered and available for metastatic melanoma. Injections of talimogene laherparepvec (T-Vec), a genetically engineered herpes virus, resulted in the regression of treated as well as untreated tumour lesions accompanied by increased intratumoural infiltration by melanoma-specific CD8 + cells and reduced numbers of CD4 + Foxp3 + T regulatory cells.³⁴

Conclusion

Currently, published data do not conclusively demonstrate the efficacy of CTD for malignant human or animal solid

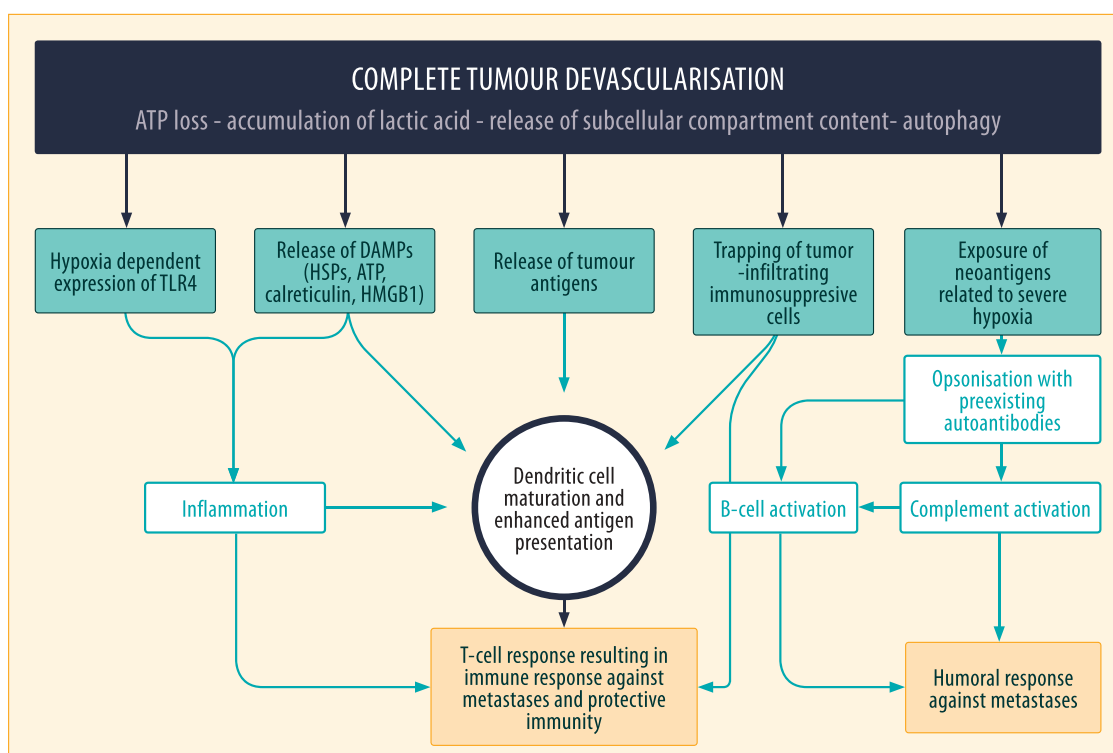


Figure 3. Possible immune mechanisms which lead to the regression of distant lesions and protective immunity following complete tumour devascularisation (ATP, adenosine triphosphate; TLR4, toll-like receptor 4; DAMPs, damage-associated molecular pattern molecules; HSP, heat shock protein; HMGB1, high mobility group box 1).

tumours, especially in the context of standard anti-tumour treatments.

CTD is a potential method for the induction of immune responses against solid tumours. Based on experience from animal models, CTD is most likely to be effective in strongly immunogenic tumours. Despite rapid progress in tumour immunology over the past decade, the processes that are induced by acute tumour ischemia as well as CTD remain poorly understood. Future research should be oriented towards evaluating the efficacy of the procedure in various settings, including pre-treatment or combinations with conventional antineoplastic therapies and/or immunomodulatory agents such as checkpoint inhibitors, as well as identification of the optimal surgical technique for specific tumours and specific tumour locations.

Acknowledgments

The authors would like to thank Dr. Jasper Manning for language revision of the manuscript.

Disclosure of potential conflicts of interest

Tomas Buchler has received research funding, speaking and consultancy fees regarding cancer immunotherapy from Roche, Merck, and Bristol Myers Squibb, unrelated to the present article. Radek Spisek is employed by Sotio, a company developing cancer immunotherapies.

Funding

Publication fee has been covered by an unrestricted grant from Roche to the First Faculty of Medicine, Charles University, Prague, Czech Republic.

Author Contribution

Conception and design of the review: T Buchler, P Vasek, R Spisek, V Horejsi

Acquisition of data: P Vasek, T Buchler

Writing first draft: T Buchler

Preparing figures: P Skrobaneck

Editing and final approval of the manuscript: T Buchler, P Vasek, R Spisek, P Skrobaneck, V Horejsi

ORCID

Tomas Buchler  <http://orcid.org/0000-0001-6667-994X>

Vaclav Horejsi  <http://orcid.org/0000-0003-4925-0142>

References

- Lewis MR, Aptekman PM. Antigenicity of sarcomata undergoing atrophy in rats. *J Immunol.* 1951 Sep;67(3):193–195. PMID: 14888881.
- Fardon JC, Prince JE. An attempt to induce resistance in an inbred strain of mice by ligation of a homologous tumor. *Cancer Res.* 1953 Jan;13(1):9–13. PMID: 13032942.
- Foley EJ. Antigenic properties of methylcholanthrene-induced tumors in mice of the strain of origin. *Cancer Res.* 1953;13:835–837. PMID: 13116120.

4. Prehn RT, Main JM. Immunity to methylcholanthrene-induced sarcomas. *J Natl Cancer Inst.* 1957 Jun;18(6):769–778. PMID: 13502695.
5. Gorelik E. Concomitant tumor immunity and the resistance to a second tumor challenge. *Adv Cancer Res.* 1983;39:71–120. PMID: 6194674.
6. Fortýn K, Hradecký J, Pazdera J, Klaudy J, Hruban V, Dvůrák P, Matousek J, Tichý J, Kolín V. Small and large intestine devascularization devitalization and potentials in the therapeutic use of this operative method. *Z Exp Chir Transplant Kunstliche Organe.* 1985;18(1):42–50. PMID: 2986369.
7. Fortyn K, Hruban V, Horák V. Treatment of malignant melanoma. *Br J Surg.* 1994;81(1):146–147. PMID:8155151.
8. Horák V, Fortyn K, Hruban V, Klaudy J. Hereditary melanoblastoma in miniature pigs and its successful therapy by devitalization technique. *Cell Mol Biol (Noisy-Le-Grand).* 1999;45(7):1119–1129. PMID: 10644016.
9. Fišer B Letter of health secretary, ministry of health of the czech republic, to president of czech association of patients Report of preliminary results of clinical trials; 2002, ref. 3924/02. doi:10.1044/1059-0889(2002/er01)
10. Lewis MR, Maxwell DB, Aptekman PM, Demchur P. Atrophy of sarcoma in rats followed by tumor immunity; a surgical method for development of tumor immunity in rats. *Surgery.* 1951 Oct;30(4):689–694. PMID:14893047.
11. Lewis MR, Aptekman PM. Atrophy of tumors caused by strangulation and accompanied by development of tumor immunity in rats. *Cancer.* 1952 Mar 5;(2):411–413. PMID: 14905430 doi:10.1002/1097-0142(195203)5:2<411::AID-CNCR2820050233>3.0.CO;2-R.
12. Baldwin RW. Immunity to methylcholanthrene-induced tumours in inbred rats following atrophy and regression of the implanted tumours. *Br J Cancer.* 1955 Dec 9;(4):652–657. PMID: 13304228; PubMed Central PMCID: PMC2073778 doi:10.1038/bjc.1955.70.
13. Allen FM, Kaplan MM, Meranze DR, Gradess M. Treatment of spontaneous tumours by temporary local ligation. A comparative study in dogs. *Bull World Health Organ.* 1960;23:727–737. PMID: 13682514; PubMed Central PMCID: PMC2555381.
14. Neel HB 3rd, Ritts RE Jr. Immunotherapeutic effect of tumor necrosis after cryosurgery, electrocoagulation, and ligation. *J Surg Oncol.* 1979;11(1):45–52. PMID: 431082.
15. Mohr SJ, Whitesel JA. Spontaneous regression of renal cell carcinoma metastases after preoperative embolization of primary tumor and subsequent nephrectomy. *Urology.* 1979 Jul;14(1):5–8. PMID: 452221.
16. Khafagy M, Wanebo HJ, Alfieri A, Hahn EW. Effect of different cancer treatment methods on immunity to an antigenic transplantable murine fibrosarcoma (Meth A). *AJR Am J Roentgenol.* 1977 Jun; 128(6):1027–1029. PMID: 414534 doi:10.2214/ajr.128.6.1027.
17. Neel HB 3rd, Ketcham AS, Hammond WG. Experimental evaluation of in situ oncicide for primary tumor therapy: comparison of tumor-specific immunity after complete excision, cryonecrosis and ligation. *Laryngoscope.* 1973 Mar;83(3):376–387. PMID: 4690029 doi:10.1288/0000537-197303000-00009.
18. Kamijo A, Koshino T, Uesugi M, Nitto H, Saito T. Inhibition of lung metastasis of osteosarcoma cell line POS-1 transplanted into mice by thigh ligation. *Cancer Lett.* 2002 Dec 15;188(1–2):213–219. PMID: 12406567.
19. Kalina V, Kopsky DJ. Autologous tumor immunizing devascularization in cancer therapy. *Med Hypotheses.* 2016 Apr; 89:72–78. PMID: 26968914 doi:10.1016/j.mehy.2016.02.004.
20. Vašek P, Krajník J, Kopsky DJ, Kalina V, Frydrych M. Autologous tumor immunizing devascularization of an invasive colorectal cancer: A case report and literature review. *Mol Clin Oncol.* 2016 Nov 5;5:521–526. PMID: 27882237 PMCID: PMC5103851. doi:10.3892/mco.2016.1033.
21. Pokorná E, Hradecký J, Morávková A, Burda P, Kotrnoch J, Klaudy J, Faldyna M, Sinkora J, Halouzka R, Jelínek F, et al. Tumour ligation (devitalisation) of mammary gland tumours in dogs and sarcoma in Lewis rats. Presented at the 28th Brno Oncology Conference, 2004. Abstract 168.
22. Rambow F, Piton G, Bouet S, Leplat JJ, Baulande S, Marrau A, Stam M, Horak V, Vincent-Naulleau S. Gene expression signature for spontaneous cancer regression in melanoma pigs. *Neoplasia.* 2008 Jul;10(7):714–722. PMID: 18592010 PMCID: PMC2435007.
23. Vincent-Naulleau S, Le Chalony C, Leplat JJ, Bouet S, Bailly C, Spatz A, Vielh P, Avril MF, Tricaud Y, Gruand J, et al. Clinical and histopathological characterization of cutaneous melanomas in the melanoblastoma-bearing Libechev minipig model. *Pigment Cell Res.* 2004 Feb;17(1):24–35. PMID: 14717842.
24. Horak V, Moravkova A, Strnadel J, Hradecky J, Usvald D, Vannucci L Devitalization as a special surgical tumour treatment inducing anti-cancer response – an experimental study in two animal models. Abstracts – 6th Annual Meeting CIMT, 15.-16.5. 2008, Mainz, Germany, P65
25. Vanden Berghe T, Linkermann A, Jouan-Lanhouet S, Walczak H, Vandenabeele P. Regulated necrosis: the expanding network of non-apoptotic cell death pathways. *Nat Rev Mol Cell Biol.* 2014 Feb;15(2):135–147. PMID: 24452471 doi:10.1038/nrm3737.
26. Belizário J, Vieira-Cordeiro L, Enns S. Necroptotic cell death signaling and execution pathway: lessons from knockout mice. *Mediators Inflamm.* 2015;2015:128076. PMID: 26491219 PMCID: PMC4600508 doi:10.1155/2015/128076.
27. Hernandez C, Huebener P, Schwabe RF. Damage-associated molecular patterns in cancer: a double-edged sword. *Oncogene.* 2016 Nov 17;35(46):5931–5941. PMID: 27086930 PMCID: PMC5119456 doi:10.1038/onc.2016.104.
28. Condamine T, Ramachandran I, Youn JI, Gabrilovich DI. Regulation of tumor metastasis by myeloid-derived suppressor cells. *Annu Rev Med.* 2015;66:97–110. PMID: 25341012 PMCID: PMC4324727 doi:10.1146/annurev-med-051013-052304.
29. Weiser MR, Williams JP, Moore FD Jr, Kobzik L, Ma M, Hechtman HB, Carroll MC. Reperfusion injury of ischemic skeletal muscle is mediated by natural antibody and complement. *J Exp Med.* 1996 May 1;183(5):2343–2348. PubMed PMID: 8642343; PubMed Central PMCID: PMC2192547.
30. Sheu EG, Wakatsuki K, Younan G, Oakes SM, Moore FD. Ischemic injury inhibits cancer metastasis by modulation of host adaptive immunity. *J Am Coll Surgeons.* 2011;213(3) S137.
31. Postow MA, Callahan MK, Barker CA, Yamada Y, Yuan J, Kitano S, Mu Z, Rasalan T, Adamov M, Ritter E, et al. Immunologic correlates of the abscopal effect in a patient with melanoma. *N Engl J Med.* 2012 Mar 8;366(10):925–931. PubMed PMID: 22397654; PubMed Central PMCID: PMC3345206. doi:10.1056/NEJMoa1112824.
32. Reed CM, Cresce ND, Mauldin IS, Slingluff CL Jr, Olson WC. Vaccination with melanoma helper peptides induces antibody responses associated with improved overall survival. *Clin Cancer Res.* 2015 Sep 1;21(17):3879–3887. Epub 2015 May 12 PubMed PMID: 25967144; PubMed Central PMCID: PMC4558239 doi:10.1158/1078-0432.CCR-15-0233.
33. Hu ZI, McArthur HL, Ho AY. The abscopal effect of radiation therapy: what is it and how can we use it in breast cancer? *Curr Breast Cancer Rep.* 2017;9(1):45–51. PMID: 28344743 doi:10.1007/s12609-017-0234-y.
34. Andtbacka RH, Kaufman HL, Collichio F, Amatruda T, Senzer N, Chesney J, Delman KA, Spitzer LE, Puzanov I, Agarwala SS, et al. Talimogene laherparepvec improves durable response rate in patients with advanced melanoma. *J Clin Oncol.* 2015 Sep 1;33(25):2780–2788. PMID: 26014293 doi:10.1200/JCO.2014.58.3377.