

Gummy Smile Management Using Diode Laser Gingivectomy Versus Botulinum Toxin Injection - A Prospective Study

Aida M. Mossaad, Mostapha A. Abdelrahman, Amr M. Kotb¹, Albraa B. Alolayan, Shadia Abdel-Hameed Elsayed²

Departments of Orodonal Genetics and ¹Dermatology, National Research Centre, ²Department of Oral and Maxillofacial Surgery, Faculty of Dental Medicine for Girls, Al-Azhar University, and Taibah University, Cairo, Egypt

Abstract

Introduction: Gummy smile (GS) is a nonesthetic condition that affects the confidence of many young people. The present study aimed to compare the results of two approaches used in the management of GS in a group of Egyptian females. **Materials and Methods:** This comparative cohort study included 24 female patients aged 25–35 years, divided into two groups. Group A included patients treated with diode dental laser gingivectomy, while Group B included patients who were treated with Botox injection. The clinical assessment of the pre-and post-operative measurements of exposed gums in millimetres on an active full smile was analyzed and compared for both groups. The paired *t*-test was used to compare pre and post measurements in each group, and the mean difference between the groups was compared using the independent *t*-test. **Results:** Group A showed instant improvement, while Group B results appeared 1 week later. The variation between preoperative and postoperative GS measurements in both groups was statistically significant. The preoperative and postoperative mean \pm standard deviation was (5.17 \pm 0.9 and 1.89 \pm 0.5) in Group A and (4.27 \pm 1.0 and 1.79 \pm 1.0) in Group B. Comparison between the two groups revealed a highly significant greater mean difference of 3.27 \pm 0.5 mm in Group A than Group B ($P < 0.001$). The findings were satisfactory in all cases of both approaches, and there were no complications. **Discussion:** Using a diode laser to treat gummy smiles for oro-dental genetics case with gingival hypertrophy saves time and effort compared to conventional surgical techniques. Diode dental laser is a safe fast and effective method of treatment giving more superior results than Botox injection which showed a less invasive alternative temporary GS therapy that is easily guaranteed and more patient-favored.

Keywords: Botulinum toxin, gingivectomy, gums, lasers, smiling

INTRODUCTION

Gummy smile (GS) is a condition that affects the confidence of many young people. It has multiple causes as short upper lip or hyperactive upper lip, excess maxillary growth, and excess gum covering teeth. When 3 mm or more of the gum is displayed, this is considered to be unaesthetic. Individuals with GS are often embarrassed to smile. Management of GS often depends on the cause in the first place.^[1,2] Anthony *et al.* 2014 tried to validate Index for Orthognathic Functional Treatment Need (IOFTN) and found this index is very reliable in helping determination of patient need, especially in severe malocclusion.^[3] After that, Borzabadi-Farahani, in 2016,^[4] assessed IOFTN index and found also that subjects with malocclusion had higher percentage of Grade 5 IOFTN scores which indicated greater functional need. According to their criteria, any upper labial segment gingival exposure >3 mm

at rest with the evidence of periodontal effects are moderate to great need for treatment.

Cases with skeletal maxillary overgrowth are managed usually with orthognathic surgeries, cases with short hyperactive

Address for correspondence: Dr. Shadia Abdel-Hameed Elsayed, Department of Oral and Maxillofacial Surgery, Faculty of Dental Medicine for Girls, Al-Azhar University, Cairo, Egypt.
E-mail: shadiaelsayed@azhar.edu.eg

Received: 17-01-2021

Last Revised: 13-02-2021

Accepted: 22-02-2021

Published: 24-07-2021

This is an open access journal, and articles are distributed under the terms of the Creative Commons Attribution-NonCommercial-ShareAlike 4.0 License, which allows others to remix, tweak, and build upon the work non-commercially, as long as appropriate credit is given and the new creations are licensed under the identical terms.

For reprints contact: WKHLRPMedknow_reprints@wolterskluwer.com

How to cite this article: Mossaad AM, Abdelrahman MA, Kotb AM, Alolayan AB, Elsayed SA. Gummy smile management using diode laser gingivectomy versus botulinum toxin injection - A prospective study. *Ann Maxillofac Surg* 2021;11:70-4.

Access this article online

Quick Response Code:



Website:
www.amsjournal.com

DOI:
10.4103/ams.ams_458_20

lips are managed with botulinum toxin injection and cases with gingival enlargement are managed with gingivectomy either surgically with scalpel or with laser to expose normal length of teeth. This can be decided clinically or by measuring keratinized gingival level.^[5-7]

Lasers have been widely used in dentistry either on soft tissue as neodymium yttrium aluminium garnet (YAG), diode, or CO₂ or hard tissue as erbium-doped: YAG. Applications for soft-tissue include biostimulation, sulcular debridement, gingival peeling, frenectomies, biopsies, and gingivectomy. The use of lasers facilitates treatment with less timing and gives better healing option rather than the conventional surgical methods using the scalpel. A common application of lasers is using diode 655–980 nm in laser gingivectomy procedure for patients who are suffering from short clinical crowns in order to decrease the gingival sulcus.^[4,7]

Gingivectomy is a surgical operation to remove excess unsupported gingival tissue to a degree at which it is attached and create a new gingival margin that is apical to the old location without compromising the biological width.^[8,9]

In the current study, diode laser was used as it is highly absorbable by haemoglobin and melanin that allows easier manipulation of soft tissue during gingival contouring in addition to improving epithelialization and wound healing. During the use of laser, heat generation allows coagulation that prevents bleeding by sealing the blood vessels and also inhibiting pain receptors.^[10]

Botulinum toxin is a minimally invasive treatment of GS for those patients having high lip line due to hyperactive upper lip muscles.^[11,12] It is injected in the muscle to block the action of the acetyl choline and enables the repolarization of the postsynaptic term. When botulinum toxin (BTX) reaches the nerve endings, it is primarily concentrated at the cholinergic neuron nerve endings, causing presynaptic membrane exocytosis phase dysfunction and acting like a scissor that cuts proteins (proteolysis effect) so that neurotransmission at the neuromuscular junction would fail; however, they are not taken up by the adrenergic nerve endings and trigger flaccid paralysis of the muscles.^[13] This leads to a localized decrease in the intensity of the elevator muscle, which relieves the forcing action of the lip during smiling. Levator labii superioris, Levator labii superioris aequae nasii, Zygomaticus major, Zygomaticus minor, and Depressor septii are muscles essential for upper lip lifting and smiling.^[14,15] In the development of smiles, both of these muscles communicate with the orbicularis oris muscle. The effect of Botox injection appears within a week and the effect lasts for 4–6 months.^[16]

Thus, the present comparative cohort study was conducted to explore the clinical outcome of management of GS condition with Dr. Smile diode laser gingivectomy (DDLG) versus botulinum toxin injection in a group of Egyptian females.

Objective

The present study aimed to compare the results of two

approaches (DDLG and botulinum toxin injection Botox) used in the management of GS in a group of Egyptian females.

MATERIALS AND METHODS

Study design and setting

This comparative cohort study performed between January 2019 and January 2020 in the clinics.

Study sample and allocation

The study sample was nonrandomized convenient subjects and included 24 female patients with age ranging from 25 to 35 years. Patients were divided into two groups that were equal. Group A consisted of 12 patients and Group B consisted of 12 patients with GS measurements exceeding 3 mm.

Population inclusion criteria

All participants were nonsmokers, healthy with no underlying systemic conditions, suffering from a GS that was diagnosed when the vertical exposure of the gingiva from the lower border of the upper lip to the free gingival margin of the maxillary anterior teeth was more than 3 mm measured when smiling.

Exclusion criteria

- Severe skeletal Class II maxillary prognathism
- History of allergy to botulinum toxin injection
- Patients affected with maxillary vertical excess.

Ethical statements

The study was conducted in accordance with the Helsinki declaration of clinical studies guidelines and approved from the National Research Centre ethical committee (# 12060204/12/2018). All surgeries were done after explaining to the patient the aim of our study and informed consent was taken. This report adhered to the guidelines of strengthening the Reporting of Observational Studies in Epidemiology.

Study groups and techniques

Group A was treated with laser gingivectomy using surgical diode laser (Dr Smile diode laser, Italy, power used 3 joules m/s) with a continuous mode power 3 watt under local anaesthesia lignocaine with epinephrine (1:100,000) which was given between maxillary right first premolar to maxillary left first premolar in the vestibular mucoperiosteum. Dental scaling was done for all participants before surgery. The procedure lasted for 30–40 min for each case with saline irrigation. No postoperative medications were prescribed and only mouthwash was advised twice daily for 5 days.

The laser tip was activated by a dark carbon paper until smoke was released, and the laser tip appears black. The laser was applied with brush movement with a haemostatic effect which allowed proper visualization of the starting point from the midline mesial line angle of the right central incisor to the distal line angle of upper second premolar and then repeated on the left arch [Figures 1 and 2].

Group B was treated with (Botox Allergan) botulinum toxin injection. By adding 2.5 ml of 0.9%, normal saline solution to 100 units of vacuum-dried Clostridium Botulinum toxin Type A, botulinum toxin Type A was diluted to produce 2 units/0.05 ml.

With a total dose of 20 U, insulin syringes measuring 1 ml with removable 30G needle were used; 4 units on each side of the nasolabial fold (at the Yonsei point 4 units on each side of the nasolabial fold (divided into 4 injections) and 2 units just below the nose (orbicularis oris muscle). The center of the triangle which included Levator labii superioris, Levator labii superioris alaeque nasi, and Zygomaticus minor is located at this point [Figures 3 and 4].

Methods of evaluation and data collection

Measurements of the vertical exposure of the gingiva from the upper lip border to the free gingival margin of the maxillary anterior teeth were recorded during a complete smile before and after 1 week of follow-up visit. Periodontal probing depth and

bleeding points were measured with an explorer for keratinized gingiva of anterior teeth using UNG-15 probe before surgical procedure and compared to after 1-week follow-up visit.

To ensure full healing in Group A and effectiveness in Group B, clinical photos were taken extraorally before the treatment and after 1 week, 1 month, 3-month follow-up periods to all cases.

Statistical analysis

All test data were processed and analyzed using SPSS version 20.0.0 software application (SPSS Inc. IBM, Chicago, USA). Pre- and postintervention mean and standard deviation (SD) were measured. Comparisons between pre- and post-measures in each group were done using paired *t*-test, and the mean difference between the two tested groups intervention was compared using the independent *t*-test. To evaluate the statistically significant difference between groups, the *P* < 0.05.

RESULTS

Descriptive data results

This study included 24 female patients suffering from GS and was divided randomly into two groups. Group A (DDLG) showed immediate effects, while results emerged after 1 week

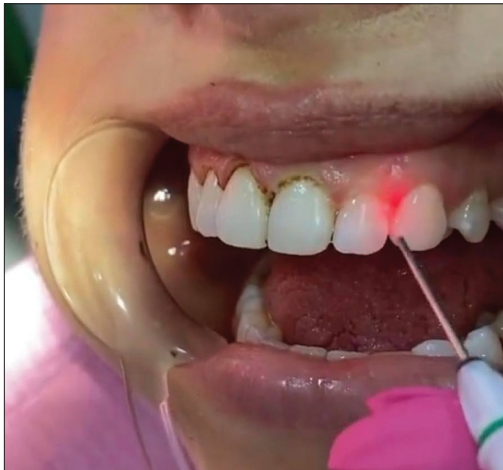

Figure 1: Intraoperative photograph demonstrating Dr. Smile diode laser gingivectomy

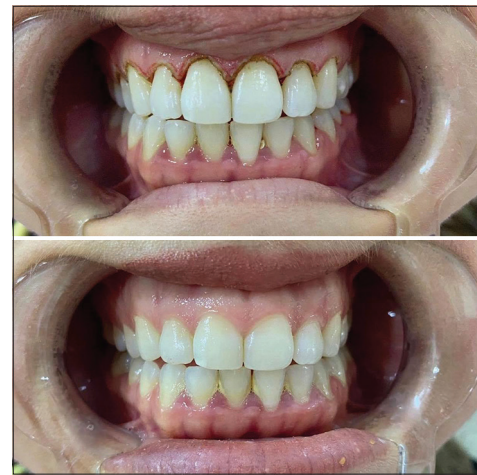

Figure 2: Intraoperative photographs showing the appearance of the gingival segment of the laser gingivectomy (Group A)

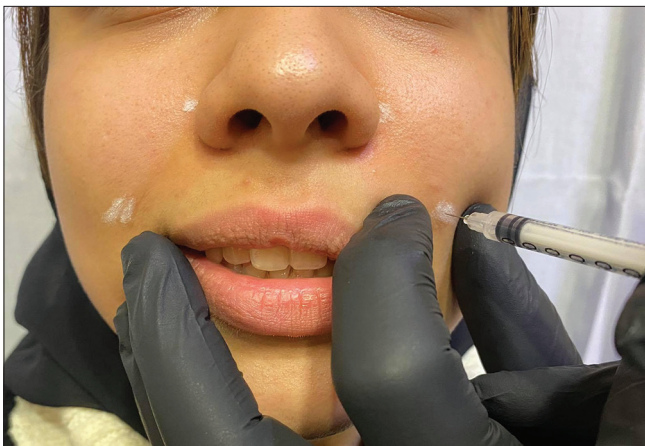

Figure 3: Intraoperative photograph of 1 ml insulin syringes used to inject 4 units of Type-A botulinum toxin on both side of the nasolabial fold and 2 units just below the nose

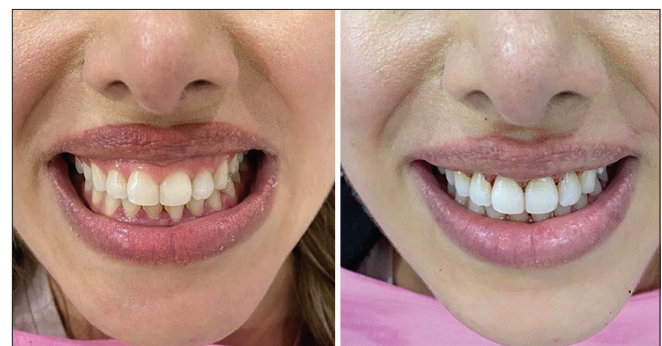

Figure 4: Preoperative and postoperative gummy smile for Botox treatment (Group B)

in Group B (Botox injection) and lasted for 4–6 months. Clinical examination and photos were taken preoperatively and after 1 week postoperatively to ensure complete healing in Group A and effectiveness in Group B. The findings showed that the preoperative mean ± SD measurements were 5.17 ± 0.9 for Group A and 1.89 ± 0.5 for the postoperative measurements. The mean difference in Group A (3.27 ± 0.5) indicates a highly statistically significant variance ($P = 0.001^*$) [Table 1]. The preoperative mean ± SD was 4.27 ± 1.0 in Group B and the postoperative mean ± SD was 1.79 ± 1.0, and the mean difference (2.48 ± 0.5) showed highly statistically significant improvements ($P < 0.001^*$). A comparison between both groups using independent *t*-test revealed highly significant intervention mean difference ($P < 0.001^*$) [Figure 5].

All cases were satisfied with the results of both techniques and no complications occurred. However, patients after laser gingivectomy had an immediate postoperative brownish discolouration of the gingiva that was explained to the patients before the procedures and it faded after complete soft-tissue healing within a week. As regard to Botox treatment, it was much preferred by most patients as a noninvasive, nonpainful, and fast procedure; however, it lasted for only 6 months. At the 6-month follow-up for patients, clinical examination showed that Group A was still enjoying the results of their laser gingivectomy treatment, while patients with Group B complained that the effect of their Botox treatment was almost gone, and they regained their GS back and needed another injection.

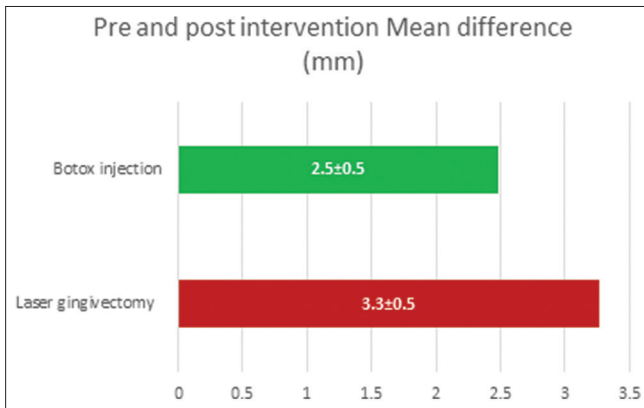


Figure 5: Chart photograph showing the mean difference between Laser and Botox intervention comparison

DISCUSSION

GS is an esthetic and psychological problem. It lowers self-confidence, leading to a hidden smile. A smile that reveals more than 2 mm of gum is called a GS. The present study key findings showed that there was a statistically significant mean difference between both approaches used for treating GS with superior significance of the diode laser group.

Esthetic dentistry nowadays comprises huge work for all dental practitioners who seek best results for their patients with rapid convenient techniques which mostly done in single chair-side visit and under local anaesthesia.^[11,15] Therefore, the present study aimed to compare the clinical outcomes of the most widely used technique in the dental offices Botox injection versus laser gingival contouring for treatment of the GS patients.

The current study population are mainly female patients and this goes in accordance with many studies conducted in esthetic dentistry branch although some others researches compare male-to-female outcomes; however, the present study showed that Egyptian males are less demanding for esthetic therapy than females.^[12,17]

Many practitioners tried various techniques to manage the annoying GS problems for their patients such as lip repositioning, esthetic crown lengthening, and gingival depigmentation: a combined approach for a GS makeover and micro-autologous fat transplantation, orthognathic surgery which requires general anaesthesia and aggressive bony osteosynthesis.^[2,18,19] However, in addition to GS measurements, there should be advanced methods for evaluating functional indications for orthognathic surgery depending on multiple other factors.^[4,20]

Another technique was applied by Litton and Fournier,^[21] in which the lip is pulled down from the bony structures above by muscle detachment. Meanwhile, in patients with GS, Silva *et al.*^[18] investigated the modified lip repositioning technique and published satisfactory results. Such procedures, however, may lead to regular recurrence and undesirable side effects such as wound contraction.

Litton and Fournier applied a treatment, in which they bring the lip down by muscle detachment from the bony structures above. Silva *et al.*^[18] investigated the modified

Table 1: Comparison between pre- and post-gummy smile measurement among both groups (Laser gingivectomy and Botox injection)

	Preoperative gingival exposure			Postoperative gingival exposure			Mean difference, mean ± SD	Paired <i>t</i> -test, <i>P</i>
	Mean (mm) ± SD	Minimum (mm)	Maximum (mm)	Mean (mm) ± SD	Minimum (mm)	Maximum (mm)		
Laser gingivectomy	5.17 ± 0.9	4	6.5	1.89 ± 0.5	1	2.5	3.27 ± 0.5	0.001*
Botox injection	4.27 ± 1.0	3	6	1.79 ± 1.0	0	2.8	2.48 ± 0.5	0.001*
Pre- and post-intervention mean difference							0.001* (independent <i>t</i> -test), <i>P</i> value	

* $P = 0.001$, The vertical exposure of the gingiva was measured (in mm) from the lower border of the upper lip to the free gingival margin of the maxillary anterior teeth during smiling. SD=Standard deviation

lip repositioning technique in patients with GS and reported satisfactory results. Nevertheless, such surgeries may lead to frequent relapse and undesirable side effects such as scar contraction.^[17] Deciding whether to treat GS with laser gingivectomy or Botox injection depends on the cause and clinical examination.

Botox injection is a fast guaranteed method of GS treatment.^[22] Most patients preferred Botox treatment as a noninvasive, nonpainful, and fast procedure, but they complained of a short time effect lasting for only 6 months and that they needed to repeat it.^[23] Patients who did laser gingivectomy achieved better results and more lasting effect. In comparison, surgical gingivectomy using scalpel required longer duration of surgery as well as had bleeding during the procedure, which necessitated placement of a surgical pack for 3-5 days postoperatively as well as analgesics for postoperative pain, that lasted for a couple of days postoperatively.

Study limitations

The current study was limited by a small number of participants and a single-study setting (one center) which recommended to be expanded in a future study to generalize the results. Deciding whether to treat GS with laser gingivectomy or Botox injection depends on the cause and clinical examination. Tools for exclusion of the functional need for orthognathic surgery and also a homologous face smile model technique should be used in future studies of the management of GS cases for prioritization treatment for better outcomes.

CONCLUSION

Within the limitation of the present study, it could be concluded that diode dental laser is a safe fast and effective method of treatment giving more superior results, while Botox injection is a fast guaranteed less invasive method of GS treatment and more preferred by patients.

Declaration of patient consent

The authors certify that they have obtained all appropriate patient consent forms. In the form the patients have given their consent for their images and other clinical information to be reported in the journal. The patients understand that their names and initials will not be published and due efforts will be made to conceal their identity, but anonymity cannot be guaranteed.

Financial support and sponsorship

Nil.

Conflicts of interest

There are no conflicts of interest.

REFERENCES

- Narayanan M, Laju S, Erali SM, Erali SM, Fathima AZ, Gopinath PV. Gummy smile correction with diode laser: Two case reports. *J Int Oral Health* 2015;7:89-91.
- Storror CL, Valverde FK, Santos FR, Deliberador TM. Treatment of gummy smile: Gingival recontouring with the containment of the elevator muscle of the upper lip and wing of nose. A surgery innovation technique. *J Indian Soc Periodontol* 2014;18:656-60.
- Ireland AJ, Cunningham SJ, Petrie A, Cobourne MT, Acharya P, Sandy JR, *et al.* An index of orthognathic functional treatment need (IOFTN). *J Orthod* 2014;41:77-83.
- Borzabadi-Farahani A. The adjunctive soft-tissue diode laser in orthodontics. *Compend Contin Educ Dent* 2017;38:e18-31.
- Verardi S, Ghassemian M, Bazzucchi A, Pavone AF. Gummy smile and short tooth syndrome-Part 2: Periodontal surgical approaches in interdisciplinary treatment. *Compend Contin Educ Dent* 2016;37:247-51.
- Gibson MP, Tatakis DN. Treatment of gummy smile of multifactorial etiology: A case report. *Clin Adv Periodontics* 2017;7:167-73.
- Ganesh B, Burnice NK, Mahendra J, Vijayalakshmi R, Anil Kumar K. Laser-assisted lip repositioning with smile elevator muscle containment and crown lengthening for gummy smile: A case report. *Clin Adv Periodontics* 2019;9:135-41.
- Sriphadungporn C, Chamnannidiadha N. Perception of smile esthetics by laypeople of different ages. *Prog Orthod* 2017;18:8.
- Dym H, Pierre R. Diagnosis and treatment approaches to a "Gummy Smile." *Dent Clin North Am* 2020;64:341-9.
- Akram HM, Ali OH, Omran NK, Ali AO. Diode laser versus scalpel gingivectomy. *Biomed Pharmacol J* 2017;10:1799-804.
- Cengiz AF, Goymen M, Akcali C. Efficacy of botulinum toxin for treating a gummy smile. *Am J Orthod Dentofac Orthop* 2020;158:5-8.
- Gupta P, Singh N, Tripathi T. Regarding "Efficacy of botulinum toxin for treating a gummy smile." *Am J Orthod Dentofac Orthop* 2020;158:780.
- Altaweel AA, Elsayed SA, Baiomy AA, Abdelsadek SE, Hyder AA. Extraoral versus intraoral botulinum toxin Type A injection for management of temporomandibular joint disc displacement with reduction. *J Craniofac Surg* 2019;30:2149-53.
- Jaspers GW, Pijpe J, Jansma J. The use of botulinum toxin Type A in cosmetic facial procedures. *Int J Oral Maxillofac Surg* 2011;40:127-33.
- Mostafa D. A successful management of sever gummy smile using gingivectomy and botulinum toxin injection: A case report. *Int J Surg Case Rep* 2018;42:169-74.
- Dinker S, Anitha A, Sorake A, Kumar K. Management of gummy smile with botulinum toxin Type-A: A case report. *J Int Oral Health* 2014;6:111-5.
- Dilaver E, Uckan S. Effect of V-Y plasty on lip lengthening and treatment of gummy smile. *Int J Oral Maxillofac Surg* 2018;47:184-7.
- Silva CO, Ribeiro-Júnior NV, Campos TV, Rodrigues JG, Tatakis DN. Excessive gingival display: Treatment by a modified lip repositioning technique. *J Clin Periodontol* 2013;40:260-5.
- Arias DM, Trushkowsky RD, Brea LM, David SB. Treatment of the patient with gummy smile in conjunction with digital smile approach. *Dent Clin North Am* 2015;59:703-16.
- Yasuda K, Nakano H, Yamada T, Albougha S, Inoue K, Nakashima A, *et al.* Identifying differences between a straight face and a posed smile using the homologous modeling technique and the principal component analysis. *J Craniofac Surg* 2019;30:2378-80.
- Litton C, Fournier P. Simple surgical correction of the gummy smile. *Plast Reconstr Surg* 1979;63:372-3.
- Pedron IG. Comment on "Botulinum toxin Type-A as an alternative treatment for gummy smile: A case report". *Dermatol Online J* 2019;25:22.
- Pedron IG, Mangano A. Gummy smile correction using botulinum toxin with respective gingival surgery. *J Dent (Shiraz)* 2018;19:248-52.