

Fatal thrombocytopenia: A rare case with possible explanation

Ramachandra Barik, A. N. Patnaik, A. S. Gulati

Department of Cardiology, Nizam's Institute of Medical Sciences, Hyderabad, Andhra Pradesh, India

Address for correspondence: Dr. Ramachandra Barik, Department of Cardiology,

Nizam's Institute of Medical Sciences, Hyderabad, Andhra Pradesh, India.

E-mail: mimansaramachandra2011@hotmail.com

ABSTRACT

A 22 year old male presented with breathlessness on exertion, ecchymosis, jaundice and features of worsening right heart failure for the last fifteen days. On physical examination, he had a mid diastolic murmur in the tricuspid area and an ejection systolic murmur in the pulmonary area. Bone marrow histopathology report showed an increased in megakaryocytes count. Routine investigations reports were normal. Echocardiography and computerized tomography (CT) revealed a single mobile large intra cardiac mass originating from the right atrium and causing dynamic obstruction of the right ventricular inflow and outflow tract. Associated fatal thrombocytopenia did not respond to intravenous steroids or platelet transfusion. Patient could not be operated because of very low platelet count, and died during hospital stay before excision biopsy could be done. Pathological autopsy was not done. This is a rare case, as the fatal thrombocytopenia observed here was the result of mechanical effects like frictional and shear force, which can be attributed to the physical presence of a large intra cardiac mass resulting in obstruction to flow.

Key words: Frictional force, intra cardiac tumor, mechanical force, shearing force, thrombocytopenia

INTRODUCTION

Cardiac tumor associated with severe thrombocytopenia and bleeding disorders is extremely rare as evident from literature review.^[1-6] There are several explanations given for thrombocytopenia associated with intra cardiac tumor. A mere presence of a large intra cardiac mass exerts a high shear and frictional force to the blood cells, and can result in extensive damage to platelets. This may sometimes cause fatal thrombocytopenia. This fact is supported by improvement in platelet count after mere removal of the cardiac mass as reported in few studies.^[1-6]

CASE REPORT

A 22 year old male presented with progressive breathlessness on exertion, increasing jaundice, easy bruising and petechial rash over a period of 15 days. There was no history of epistaxis, gingival bleeding, hematuria, hemoptysis, fever, weight loss, neurological sign or thromboembolism. Neither there was family history of coagulation disorders, nor recent past exposure to heparin or heparinoids. On examination, his blood pressure was 110/70 mmHg, and heart rate 90/min and regular. He was afebrile. His jugular venous pressure was elevated 9 cm above the angle of Louis, and he had ecchymosis. He had facial puffiness and soft tender hepatomegaly as a sign of right ventricular inflow obstruction. On cardiac auscultation, we found a long mid diastolic murmur in the tricuspid area and harsh phasic ejection systolic murmur grade III/VI without ejection click in the pulmonary area. His direct bilirubin level, total leukocyte count and neutrophil count were elevated with severe thrombocytopenia in the peripheral smear.

Access this article online	
Quick Response Code: 	Website: www.jcdronline.com
	DOI: 10.4103/0975-3583.95372

Bone marrow study showed normal cellularity and erythroid prominence (myeloid:erythroid ratio 1:1, normoblastic erythropoiesis, normal orderly myelopoiesis, no blast prominence, increase in megakaryocytes number with few hypoblastic forms and prominence of histiocytes). Chest radiograph and electrocardiography were normal. Abdominal ultrasound showed uniform congestive hepatomegaly with normal size spleen. Color Doppler ruled out deep vein thrombus in abdomen or lower limbs. Trans-thoracic echocardiography [Figure 1] showed dilated right atrium, and hypertrophied and dilated right ventricle. There was a solitary, giant pedunculated, lobulated, homogenous mobile mass obstructing right ventricular inlet and outlet, exactly similar to a large right atrial myxoma originating from fossa ovalis.

Contrast enhanced computerized tomography (CT) of chest and abdomen showed a single large non enhancing soft tissue density occupying the right atrium, right ventricle and right ventricular outflow tract, measuring 10×7.5 mm, and extending into inferior venacava with dilated of right atrium and right ventricle [Figure 2]. Mediastinum and lung parenchyma were normal. There was a mild bilateral pleural effusion, homogenous hepatomegaly and mild ascites, with other viscera as normal. Hence, the possible radiological diagnosis was of an intra cardiac thrombus. Anti phospholipids antibody, anti systemic lupus erythematosus (SLE) antibodies and anti platelet factor 4 (PF4) antibodies were negative. He was treated with empirical intravenous antibiotics, intravenous methyl prednisolone and 20 units of single donor platelet transfusion. Neither anticoagulants nor thrombolytic agents were used during the treatment. Excisional biopsy was not possible because of continuous decline in platelet counts, and none of the serial follow

up platelet count levels were above $15,000/\text{mm}^3$. On the 15th day of hospitalization, he died of cardiac arrest just one day after an episode of melena. We could not manage pathological autopsy because of the lack of consent.

DISCUSSION

The possible causes of thrombocytopenia related to cardiac pathology are as follows:

Space occupying lesions

1. Cardiac tumor like myxoma^[7,8] angiosarcoma, rhabdomyoma, lymphoma, carcinoid tumor, papillary fibroelastoma, renal cell carcinoma and metastatic germ cell tumors. The postulated mechanism of thrombocytopenia associated with cardiac tumors include use of drugs, autoimmune response, disseminated intravascular coagulation, thrombotic thrombocytopenic purpura, hemorrhage associated with extensive transfusion, paraneoplastic syndrome and idiopathic thrombocytopenic purpura. One more postulation may be mere physical presence of a large intra cardiac mass or tumor causing mechanical damage of blood cells by shear and frictional force.^[1,2,5]
2. Thrombus and vegetation.

Here, thrombocytopenia may be due to mechanical damage, autoimmunity and infection.

Stenotic lesions

1. Native valvular stenotic lesions.
2. Mechanical valves.
3. Devices like coils and occluder.

In these conditions, the possible cause of thrombocytopenia

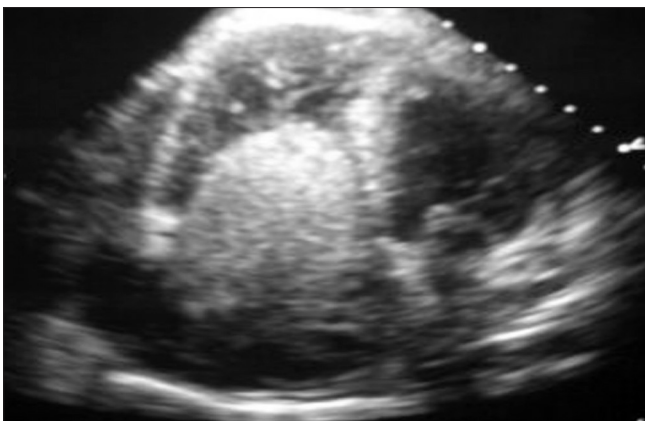


Figure 1: 2 Dimensional Echocardiograph in apical 4 chamber view (A4C) shows a right atrial, single, mobile, homogenous, large 7×10 cm mass, without satellite lesions, and causing dynamic obstruction to the right ventricular inflow and outflow tract

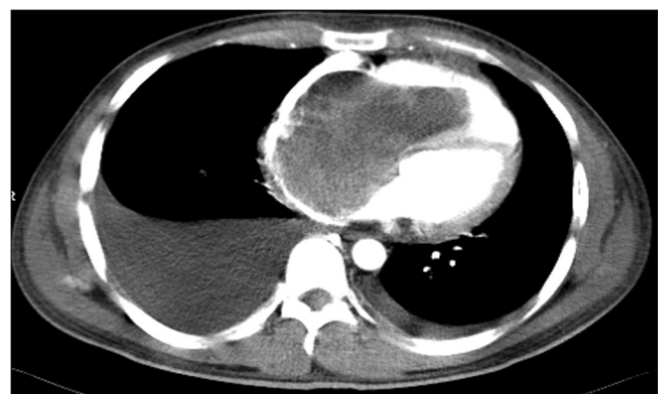

Figure 2: Computerized tomography with contrast shows a single and large contrast non enhancing intra cardiac mass occupying right atrium and right ventricle with right ventricular outflow tract and inferior venacava extension. This typical description is consistent with intra cardiac thrombus

and anemia is mechanical friction. Amongst the cardiac tumors, myxoma is most common followed by angiosarcoma and lymphoma. Both these tumors are more common in males, and have special predilection for the right side of the heart, particularly the right atrium. Right heart failure is the most common presenting symptom in these tumors. Further, angiosarcoma is much more common whereas primary lymphoma of the heart is rare. Angiosarcoma is the second most common primary cardiac tumor after myxoma, and also the commonest tumor of the right atrium. Rhabdomyoma is more frequently seen in children, and it originates from the myocardium of either ventricle. Rhabdomyosarcoma is common in children and adolescents, but rare in adults.^[1,2] Papillary fibroelastoma is the most common of the tumors involving the heart valves, and is usually seen in the elderly and not associated with thrombocytopenia. Renal cell carcinoma was excluded because of normal abdominal ultrasound and computerized tomography (CT). Carcinoid tumor mainly presents as a tricuspid valve dysfunction. Right heart failure due to intra cardiac blood flow obstruction is a relatively frequent complication of large cardiac tumors.^[7-9]

Thrombocytopenia is associated with both, benign^[1-3] and malignant^[4-6] cardiac tumors. Thrombocytopenia has also been found to be associated with other hematologic disorders such as anemia,^[8,9] and erythrocytosis;^[5] however, in our case thrombocytopenia was an isolated finding. The exact etiopathogenesis of thrombocytopenia associated with solid cardiac tumors is unclear. Idiopathic thrombocytopenic purpura (ITP) is the most common cause of thrombocytopenia in females in the age group of 15 to 50 years of age, and is defined as thrombocytopenia in apparently healthy patients without other associated causes. The defining features of ITP include thrombocytopenia, microangiopathic hemolytic anemia, neurological signs, renal abnormalities and fever. Thus, both idiopathic thrombocytopenic purpura (ITP) and thrombotic thrombocytopenic purpura (TTP) are ruled out in our case as there are no evidence of end organ damage, micro angiopathic hemolytic anemia and no response to steroid therapy. Coomb's test was negative. A negative anti systemic lupus erythmatosus (SLE) antibodies report excluded Evan syndrome. Normal lactate dehydrogenase and normal haptoglobin levels exclude hemolysis. The sudden cardiac death in the index case can be explained by sudden obstruction to inflow or outflow tract, pulmonary thromboembolism or due to massive intracranial bleed. Thrombocytopenia due to impaired production is ruled

out as bone marrow shows increased megakaryocytes. The role of antibody induced thrombocytopenia was excluded as there was no response to steroids given for two weeks.

CONCLUSION

Intra cardiac tumor associated with thrombocytopenia is extremely rare. Several possible etiopathological factors have been cited, though the exact cause is yet not known. There are some cases those fail to respond despite repeated platelet transfusions and steroids. The most important investigations like biopsy or definitive surgeries cannot be done in such situations because of significant low platelet count. Though rare but sometimes mechanical forces like frictional and shearing stress exerted by mere presence of intra cardiac tumors, causes significant damage to the blood cells, which may be the possible explanation for this fatal thrombocytopenia. Further in depth studies are required to establish a causal association.

REFERENCES

1. Burns ER, Schulman IC, Murphy MJ Jr. Hematologic manifestations and etiology of atrial myxoma. *Am J Med Sci* 1982; 284:17-22.
2. Oostenbrug LE, Ottervanger JP, Dompeling EC, Sie TH, Beukema WP. A bleeding disorder caused by a cardiac tumor: Case report. *Neth J Med* 2001;58:232-5.
3. Kucharski W, Kosmala W, Silber M, Poreba R, Zych B, Zembala M. Thrombocytopenia and disseminated intravascular coagulation in a patient with left atrial myxoma-a case report. *Kardiol Pol* 2003;59:421-4.
4. Tsuda H, Imazeki N, Fuse Y, Maruyama T, Kitani A, Mizuno K. Cardiac angiosarcoma with gastrointestinal bleeding, hypoxemia, thrombocytopenia and microangiopathic hemolytic anemia *Gan No Rinsho* 1986;32:1035-40.
5. Fishman AD, Hoffman A, Volterra F, Frymus M, Gentilluci M. Intracaval and intracardiac metastatic nonseminomatous germ cell tumor: A rare cause of hemolytic anemia and thrombocytopenia. *Cancer Invest* 2002; 20:996-1001.
6. Semino A, Danova M, Perlini S, Palladini G, Riccardi A, Perfetti V. Unusual manifestations of disseminated neoplasia at presentation: Right-sided heart failure due to a massive cardiac metastasis and autoimmune thrombocytopenia in pleomorphic rhabdomyosarcoma of the adult. *Am J Clin Oncol* 2006;29:102-3.
7. Burke A, Jeudy J Jr, Virmani R. Cardiac Tumours: An update, *Heart* 2008; 94:117-23.
8. Neragi-Miandoab S, Kim J, Vlahakes GJ. Malignant tumours of the heart: A review of tumour type, diagnosis and therapy. *Clin Oncol* 2007; 19:748-56.
9. Aktoz M, Tatli E, Ege T, Yalçın O, Büyüklü M, Aksu F, *et al.* Cardiac rhabdomyoma in an adult patient presenting with right ventricular outflow tract obstruction. *Int J Cardiol* 2008;130:105-7.

How to cite this article: Barik R, Patnaik AN, Gulati AS. Fatal thrombocytopenia: A rare case with possible explanation. *J Cardiovasc Dis Res* 2012;3:147-9.

Source of Support: Nil, **Conflict of Interest:** None declared.