

Successful Endoscopic Closure of Pyeloduodenal Fistula Using an Over-the-Scope Clip

Erica Duh, MD¹, Meredith Clary, MD², Jason Samarasena, MD², Ralph V. Clayman, MD³, and Kenneth Chang, MD²

¹Department of Internal Medicine, University of California Irvine Medical Center, Orange, CA

²Department of Gastroenterology, University of California Irvine Medical Center, Orange, CA

³Department of Urology, University of California Irvine Medical Center, Orange, CA

ABSTRACT

A 62-year-old woman underwent a series of urologic procedures for nephrolithiasis and was diagnosed with a pyeloduodenal fistula (PDF) on computed tomography urography. After the placement of a metallic ureteral stent and nephrostomy tube, an esophagogastroduodenoscopy was performed to evaluate for PDF resolution. Two areas of mucosal defects within the anterior duodenal sweep were closed using the over-the-scope clip system and hemostasis clips. We review the literature and discuss the etiologies, presentation, diagnosis, and treatment of PDF. This is the second documented case of endoscopic PDF closure using the over-the-scope clip system and the third case of endoscopically treated PDF.

INTRODUCTION

Pyeloduodenal fistula (PDF) is a rare condition that is spontaneous or traumatic in etiology. We report a patient with kidney stones who underwent a series of urologic procedures was found to have a right-sided nephro-ureteroduodenal fistula. Our case report presents the use of an over-the-scope clip (OTSC) system as a treatment option, especially for those patients in poor condition or who decline surgical intervention.

CASE REPORT

A 62-year-old woman presented with 3 months of sharp abdominal pain. She denied back pain, macroscopic hematuria, fevers, chills, dysuria, and a history of urinary tract infections or renal stones. Her medical history, family history, and social history were noncontributory. Abdominal and pelvic computed tomography (CT) showed a large trilobed staghorn stone of the right lower pole with extension into the renal pelvis.

The patient underwent right percutaneous nephrolithotomy. The procedure was complicated by pyelotomy and abdominal compartment syndrome. She later underwent a second-look procedure with the removal of the nephrostomy tube, remaining calculi, and ureteral stent placement. Two months later, a CT showed moderate right-sided hydronephrosis with 2 proximal right ureteral stones measuring 5 mm and 4 mm with multiple stone fragments of the right lower kidney pole. She underwent ureteroscopy with balloon dilation of a proximal ureteral stricture, stone removal, debris irrigation, and right ureteral stent placement. Before stent removal, a Lasix renal scan showed signs of radionuclide extravasation into the colon. A right nephro-ureteroduodenal fistula was confirmed on single-photon emission computerized tomography imaging (Figure 1). A nephrostomy tube was placed to enhance drainage and possibly promote healing of the fistula; however, a follow-up renal scan a little over a month later showed that the duodenal fistula persisted.

Gastroenterology was consulted for endoscopic clipping of the fistulous tract to avoid open surgery. The esophagogastroduodenoscopy procedure was done with fluoroscopy a little over 3 months after the initial Lasix scan showing extravasation. A

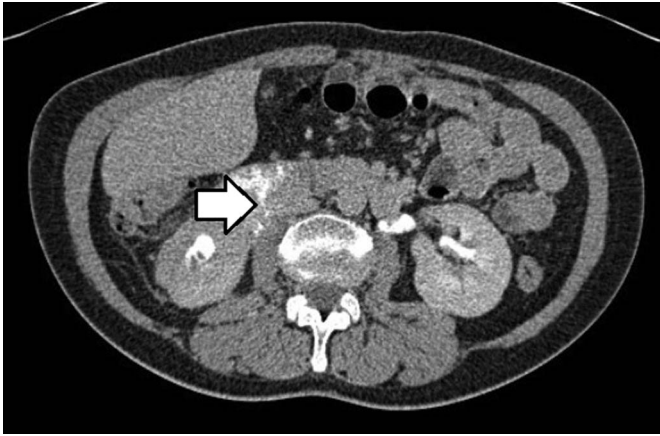


Figure 1. The white arrow denotes contrast extravasation into the gastrointestinal system confirming right pyeloduodenal fistula on single-photo emission computed tomography imaging.

150-cc mixture of methylene blue, contrast material, and normal saline was instilled through the nephrostomy tube, and contrast was seen in the right kidney and bladder. The scope was withdrawn to the first and second segments of the duodenum where a faint amount of methylene blue was detected. Two areas of mucosal defect with chronic inflammatory changes were localized in the anterior duodenal sweep in the proximal second portion of the duodenum (Figure 2). The larger of the 2 perforations measured 6 mm and was closed using the helix tissue retractor and OTSC system (Ovesco; dimensions: 12 mm endoscopic diameter of clip with 6 mm depth of cap with small spiked teeth on clip; OVESCO Endoscopy AG, Tübingen, Germany) (Figure 3). The smaller distal defect was closed with 2 11-mm hemostasis clips (ConMed Duraclip hemostasis clips; CONMED, New York, NY). Repeat fluoroscopy imaging post-

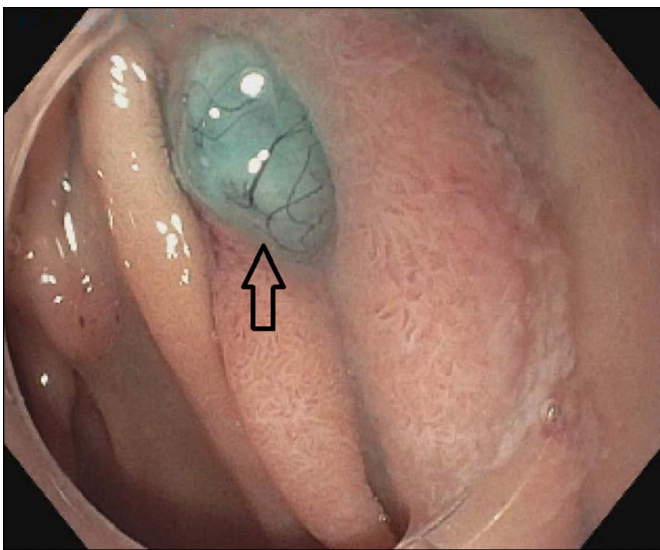


Figure 2. The scope was withdrawn slowly to the first and second segment of the duodenum where a faint amount of methylene blue was detected and two areas of mucosal defects were localized in the anterior duodenal sweep. The larger of the two defects is shown here, as indicated by the black arrow.

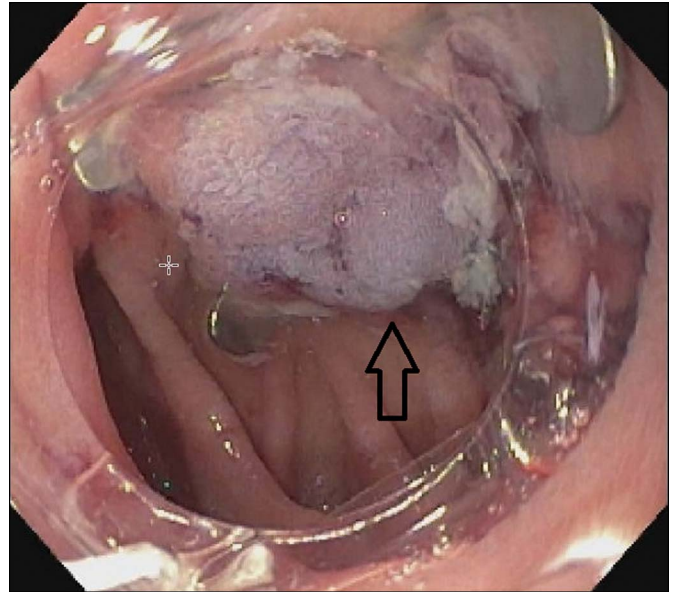


Figure 3. The larger of the two mucosal defects is shown here after closure using the over-the-scope clip (arrow).

OTSC placement showed no contrast extravasation (Figure 4). A repeat renal scan and nephrostogram 2 months later showed no extravasation, and the nephrostomy tube was removed.

DISCUSSION

PDF is a serious condition with about 100 reported cases in the literature since 1893.^{1,2} It is traumatic or spontaneous in etiology. The duodenum is well protected within the retroperitoneum, and traumatic injury to this organ is quite uncommon.^{3,4} Spontaneous

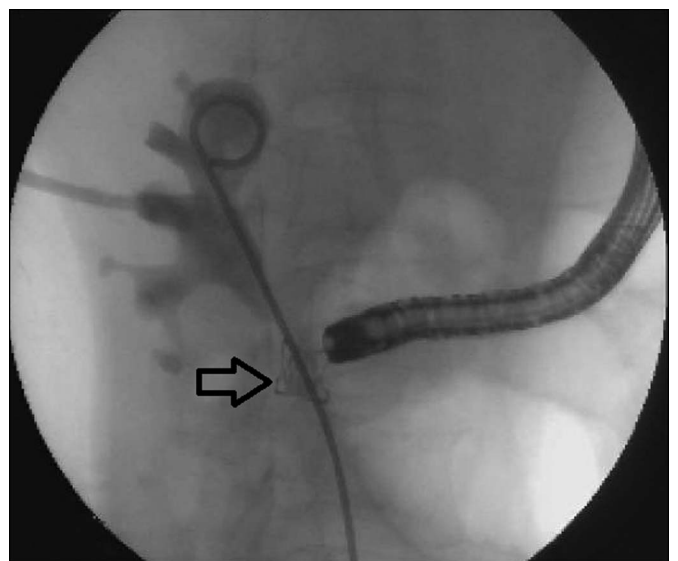

Figure 4. Fluoroscopy image taken during the esophagogastroduodenoscopy procedure showing an over-the-scope clip after placement (arrow). Contrast is being inserted through the nephrostomy tube without any evidence of extravasation.

fistulas result from chronic renal inflammatory disease.^{5,6} The posterior aspect of the second duodenal segment lies near the right renal pelvis. Inflammation of the perirenal area easily involves the duodenum because it is a relatively immobile organ without a posterior peritoneal covering.^{5,7,8}

PDF is often confirmed with retrograde pyelography, although upper gastrointestinal series can also be diagnostic. IV urography is used less because of poor renal function in these patients.⁵ CT of the abdomen is considered the best imaging modality for PDFs because it can quantify perinephric inflammation, involvement with surrounding structures, and renal contrast that may be extravasating from the urologic system.⁹

The first treatment of PDF is documented in 1935 via nephrectomy with primary closure of the duodenum. This open surgical approach remains the standard of care for PDFs but comes with its complications, including contamination of the abdominal cavity, loss of a functioning kidney, and extensive inflammatory processes which are amplified by enteric urinary tract flora.^{5,6,9,10} Conservative treatments include use of nasogastric tube, total parenteral nutrition, ureteral stenting, and complete bowel rest. These interventions focus on controlling rather than curing the infection and are favored in patients of advanced age or poor clinical picture.

A more aggressive treatment path was pursued in our particular patient's case. Although the patient was asymptomatic and had a normal renal function, she did not want to continue nephrostomy tube drainage for a prolonged period of time, considering its increased infection risk and need for exchange every few months. Although there is no definitively known amount of time to allow for spontaneous PDF resolution, there are case reports of patients being monitored for signs of clinical improvement for 3 months.¹¹ At the time of the esophagogastroduodenoscopy, conservative management with nephrostomy tube placement and ureteral stenting had failed for a little over 3 months. There was also concern that small particles of retained stone within the fistula would prevent spontaneous closure. The patient ultimately wanted a more definitive treatment.

The OTSC system is an endoscopic hemostatic clip designed to complete a full-thickness closure of the mucosa via tissue approximation. OTSC was chosen to close the larger defect site to secure an increased volume of tissue and for long-lasting durability. OTSC was preferred over endoscopic suturing because of ease of deployment, especially considering that a proximal duodenum is a difficult place for the maneuvering necessary for endoscopic suturing.

Although nephrectomy remains the preferred treatment for fistulas because of suppurative processes of the kidney, an

endoscopic approach can and should be considered in other cases.⁹ A literature review shows one other case report of a PDF treated by endoscopic ligation and one abstract documenting OTSC system used for closure of a duodenal-renal-enteric fistula.¹⁰ Our case is, to our knowledge, the second-ever documented PDF closure by endoscopic OTSC system.¹²

DISCLOSURES

Author contributions: All authors contributed equally to this manuscript. K. Chang is the article guarantor.

Financial disclosure: None to report.

Informed consent was obtained for this case report.

Received July 2, 2019; Accepted September 30, 2019

REFERENCES

1. Cohen MH, Becker MH, Hotchkiss RS. Pyeloduodenal fistula: Report of a case and review of the literature. *J Urol*. 1966;95:678–80.
2. Mahameed F, Khatib F, Azfar M. Pyeloduodenal fistula: A case report. *Kuwait Med J*. 2017;49(3):249–51.
3. Maggio P, Clark D. Management of duodenal and pancreatic trauma in adults. *Up to Date*. (<https://www.uptodate.com/contents/management-of-duodenal-and-pancreatic-trauma-in-adults>) (2019). Accessed May 29, 2019.
4. Asensio JA, Feliciano DV, Britt LD, et al. Management of duodenal injuries. *Curr Probl Surg*. 1993;30:1023–93.
5. Rodney K, Maxted WC, Pahira JJ. Pyeloduodenal fistula. *Urology*. 1983;22:536–9.
6. Matsuki M, Takahashi S, Hisasue S, et al. A case with fistula formation between a perinephric retroperitoneal abscess and the duodenum: Successful outcome after conservative management. *J Infect Chemother*. 2011;17:541–3.
7. Ginsberg DA, Stein JP, Grossfeld GD, Tarter T, Skinner DG. Traumatic pyeloduodenal fistula: A case report and review of the literature. *Urology*. 1996;47:588–91.
8. Ross JM, Tanna DD. Pyeloduodenal fistula. *J R Coll Surg Edinb*. 1974;19:51–3.
9. Campobasso D, Granelli P, Maestroni U, Cerasi D, Ferretti S, Cortellini P. Are nephroenteric fistulas only a surgical trouble? *Indian J Surg*. 2015;77(3):222–5.
10. Lee KN, Hwang IH, Shin MJ, et al. Pyeloduodenal fistula successfully treated by endoscopic ligation without surgical nephrectomy: Case report. *J Korean Med Sci*. 2014;29(1):141–4.
11. Kobayashi T, Munoz Casablanca N, Harrington M. Pyeloduodenal fistula diagnosed with technetium-99m scintigraphy and managed with a conservative strategy. *BMJ Case Rep*. 2018;2018:bcr-2017-223425.
12. Aslam B, Frandah W, Mardini H. "A novel use of over-the-scope clip for management of duodenal-renal enteric fistula." *Am J Gastroenterol*. 2018;113:1199–S1200.

Copyright: © 2019 The Author(s). Published by Wolters Kluwer Health, Inc. on behalf of The American College of Gastroenterology. This is an open-access article distributed under the terms of the Creative Commons Attribution-Non Commercial-No Derivatives License 4.0 (CCBY-NC-ND), where it is permissible to download and share the work provided it is properly cited. The work cannot be changed in any way or used commercially without permission from the journal.