








The “microwave oven” practice in Brazil

Yara Vieira Lemos^{a,b,c} , Luciene Menrique Corradi^{a,c} , Melina Calmon Silva^c ,
Lorena de Oliveira Couto^b, Giovanna Hooper Bittencourt^b , Alexander Santos Dionísio^a,
Adriana Zatti Lima^a, Márcio Alberto Cardoso^a and Eugénia Cunha^c 

^aForensic Anthropology Laboratory, Medico-Legal Institute André Roquette in Belo Horizonte, Minas Gerais, Brazil; ^bMedical Sciences Faculty of Minas Gerais, Minas Gerais, Brazil; ^cBrazilian Association of Forensic Anthropology (ABRAF), Brasília, Brazil.

ABSTRACT

This article presents a forensic case of an unusual illegal cremation of a person using a process colloquially known as the “microwave oven” practice in Brazil. The microwave process involves two actions: placing the victim in a tire stack and then setting the structure on fire using flammable substances to accelerate the progression. A similar practice, identified as “necklacing”, has also been reported in other countries such as South Africa. This report presents a case of microwave oven cremation of a body found in a rural area of Minas Gerais, Brazil. The forensic work helped determine the biological profile and identity of the victim using radiological comparisons. Although the microwave oven cremation practice is rare, it can impose challenges for investigators. Therefore, fully understanding this practice can be helpful to the academic and forensic communities.

KEY POINTS

- Killings or cremations involving carbonization inside a pile of tires are colloquially called “microwave oven” practice in Brazil.
- The goal of this article is to present the details of an unusual forensic case of illegal cremation of a person with this “microwave oven” practice.
- This illegal practice can also be used to intimidate rivals and be extremely cruel—many cases involve torture.
- Despite carbonization and putrefaction of the corpse, the experts in this case were able to positively identify the individual and detect signs of the “microwave oven” practice, which suggested homicide.

ARTICLE HISTORY

Received 8 December 2021
Accepted 15 April 2022

KEYWORDS

Forensic sciences;
carbonization; cremation;
homicide; human
identification

Introduction

According to Mikton et al. [1], the rate of homicides in low-to-middle income South American countries is 28.5 per 100 000 inhabitants per year, which is the highest at global level. Homicide rates in Brazil are 12 times higher among men, particularly between young black men with lower educational upbringing [2,3]. The major causes for shorter life expectancy for Brazilian men are homicides and road traffic accidents [4]. Over 59.1% of causes of death among Brazilian men between 15–19 years old is credited to homicide [5]. The primary method of committing homicide in Brazil is using firearms [5,6].

The killings and cremations involving carbonization inside a pile of tires are colloquially called “microwave oven” practice in Brazil. There is no connection to the microwave appliance. The goal of this unusual practice is to cremate the body to obstruct forensic practitioners from identifying the

victim and determining the cause of death. Sometimes the immobility of the victim created by the tires is used to produce torture before or during the action of the fire [7]. It can also be used to intimidate rivals, as it shows power and dominance [8].

The improvised crematoriums are frequently located in an open space in areas neglected by the state and dominated by drug traffickers. The microwave process involves two actions: placing the victim in a tire stack and then setting the structure on fire using gasoline or other flammable substances to accelerate the progression [8]. Tires have combustible properties, so they can be rapidly inflamed by a propellant [9].

Death can precede, succeed, or be concomitant to the “microwave oven” course. Therefore, different causes of death can be involved (gunshot wounds, fire, asphyxiation, stab wounds, and others).

Determining if the victim was alive when exposed to the fire is the foremost matter for addressing proper justice in Brazil because it is highly involved in the sentencing of the perpetrator. In the Brazilian justice system, the liability of the murderer is increased if the victim's death involved asphyxiation [10].

Carbonization produces a vast shortage of soft and hard tissues and changes the structure and form of the corpse, resulting in partial or total charred remains [11]. From a forensic perspective, when analysing the intensity of a fire in human tissues, the experts can use the categorization of Eckert et al. [12] or the Crow-Glassman Scale [13], which classify cases into different degrees of carbonization and cremation.

Few cases involving the "microwave oven" practice have been reported in Brazil. Durão et al. [7] published in 2015 four different cases that occurred in slums. In other countries, such as South Africa, Haiti, Nigeria, and Sri Lanka, the "necklacing" practice has been reported [14,15]. In this case, a single tire is placed around the neck of the victim with their hands and feet tied, followed by setting the fire.

The "microwave oven" practice is rare but understanding this very violent action is important for the forensic community [7]. Providing this knowledge is the main goal of the case study described here.

Case study

The forensic team was assigned to examine an unknown charred corpse that was found on a rural side road of Minas Gerais, Brazil in 2014. According to the police report, the body was suspected to be a person who had a history of involvement with drug trafficking and homicides close to the crime scene. Due to permanence in the prison system, the state provided digitalized biometric information that could be useful to experts for achieving identification. The victim's family also provided medical and dental documentation.

As in many cases involving drug cartels, the investigation was severely impaired by a lack of testimonial reports because of fear of retaliation. This issue only increased the duties of the forensic experts in charge of the body analysis. As a routine procedure, before opening the body bag in the morgue, a full radiology examination was performed. This showed multiple semi-circular metallic high-density structures, compatible with the internal structure of a tire, surrounding the abdominal, thoracic, and cervical regions. The right arm was in abduction with external rotation of the shoulder and therefore was not encircled by the wired forms. No high-density material in the remains were consistent with ballistic elements. The radiological examination

revealed materials with high radiological density near the teeth, such as material commonly used in dental treatment.

The opening of the body bag revealed a carbonized human corpse that showed destruction of the cutaneous and muscle-aponeurotic planes in a diffuse manner. It was putrefied in the coliquativa phase with focal areas of partial skeletonization, such as the anterior surface of the rib cage and vertebral column (Figure 1). Carbonized male external genitalia were observed, which in cross section showed remnants of spongy bodies and urethra.

Focal areas of muscle segments were partially preserved, notably below the carbonized shallow soft tissue, especially on the right arm and above the scapulae. Exposure of viscera showing different degrees of carbonization and putrefaction and exposure of the vertebral column and remanent viscera in the posterior view were observed. The limbs had different degrees of carbonization, fractures with bone exposure, and partial amputations of right distal radio and ulna; left distal humerus; left medium radio and ulna; distal right and left femurs. There was carbonization of the face and head with fractures in the viscerocranium and neurocranium. The internal examination showed that the brain was in the coliquativa stage of putrefaction. The tracheal light showed blood boiled inside.

The age at death was determined by applying the Suchey-Brooks method, which showed consistency with Stage III (28.7 ± 6.5 years) [16,17]. The height was evaluated first by estimating the total length of the right humerus using the regression formula of Müller modified by Steele [18]. The 1st, 2nd, and 3rd segments of the humerus corresponded to 11.4%, 7.6%, and 69.2% of the bone, respectively [18]. The measurements of these three bone segments corresponded to 300 mm (88.2% of the total bone length), and the total bone length was estimated to be 340.1 mm. The Mendonça method [19] was then applied using the regression formula of humerus for males ($64.25 + 0.3065 \times \text{humerus length}$), resulting in an estimated height of (168.49 ± 7.7) cm.

The biological profile of the case was compatible with the missing individual (young adult male, 27 years old, medium height, 166 cm). The context of the disappearance and location of the corpse also corroborated this potential match. The comparison of antemortem and postmortem radiological exams of the cranium and dental treatments were able to provide a positive identification by coincidences in the morphology of the skull (*sella turcica*; frontal sinus), aspect of the axis bone trabeculate, anatomy, angulation, and proportion of dental elements, and location, morphology, and proportion of dental treatments of the first and second lower molars (Figures 2 and 3).



Figure 1. Posterior view of the human carbonized remains surrounded by multiple metallic filaments that involve the cervical and thoracoabdominal regions (A). High-density filaments in the radiological examination (B) and a close view of the filaments after opening the body bag (C).

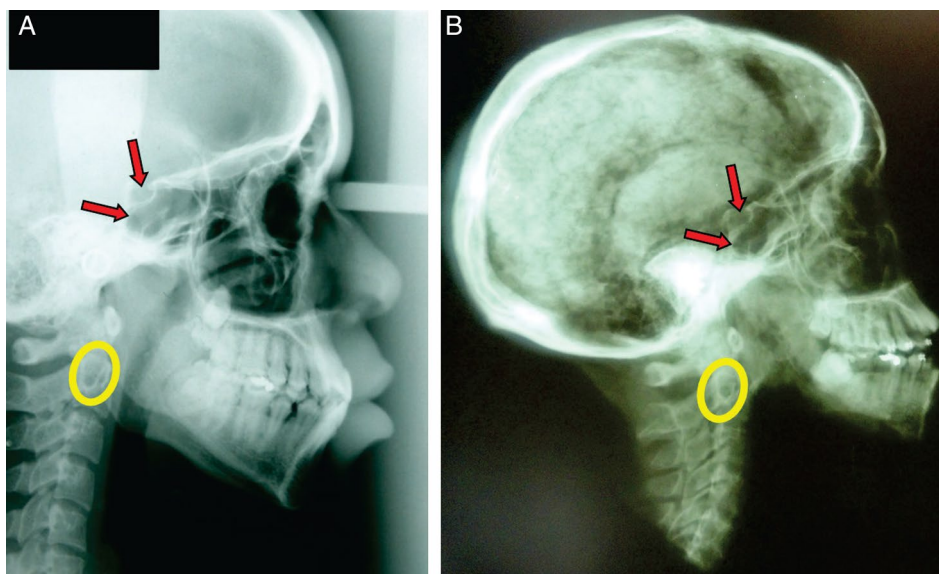


Figure 2. Radiological confrontation posing some of the elements used for this positive identification: morphology of the *sella turcica* (red arrows) and the aspect of the axis bone trabeculate (yellow ellipse). (A) Antemortem examination in 2009 provided by family members of the missing person. (B) Postmortem examination of the unidentified body performed by the forensic team in 2014.

Because the blood was deteriorated by putrefaction and heat, it was not possible to determinate the carbon monoxide rates. The analysis of the organs was also impaired by advanced putrefaction

and carbonization. Because there was no soot in the tracheal light, it was not possible to determine if the person was alive at the time of the cremation. Analysis of the fractures showed consistency with

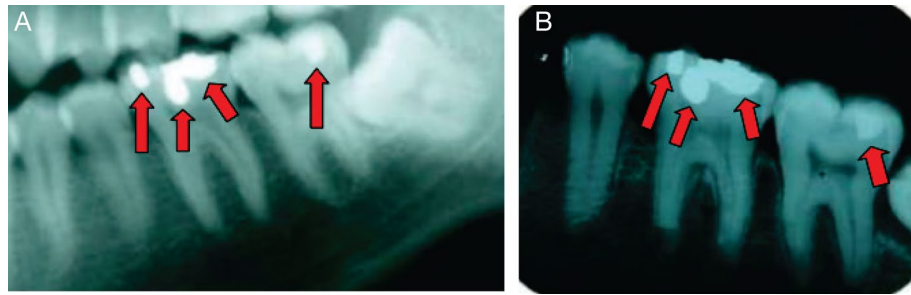


Figure 3. Periapical radiological confrontation showing some of the elements used for the positive identification: anatomy, angulation, and proportion of the first and second lower molars; the location, morphology, and proportion of dental treatments (red arrows) of the first and second lower molars. (A) Antemortem examination in 2009 provided by family members of the missing person. (B) Postmortem examination of the unidentified body performed by the forensic team in 2014.

fire action, but the cause of death could not be determined because the corpse was compromised by the intensity of carbonization and putrefaction. The manner of death was addressed using the investigative context and forensic work. It was established as a homicide related to the “microwave oven” practice.

Conclusions

The “microwave oven” practice is an unusual and illegal act of human cremation performed in Brazil, often by drug traffickers to hamper identification. It results in a partial or complete carbonization, dependent on the number of tires employed and how long the fire burns.

The damage from the heat and fire may pose difficulties for differentiating among types of traumas and manners of death, as well as for positively identifying the deceased individual. A careful inspection of the scene and human remains can deliver sufficient clues to identify signs of the “microwave oven” practice.

The positive identification of this individual was achieved by the work done at the Forensic Anthropology Laboratory at the Medico-Legal Institute André Roquette in Belo Horizonte, Minas Gerais, Brazil [20]. Different fields of expertise, such as medical, dental, and radiology, were applied to this forensic anthropological case and assisted in the successful identification [21].

Acknowledgements

The authors would like to thank the Brazilian Association of Forensic Anthropology (ABRAF), the Medico-Legal Institute André Roquette of Belo Horizonte, the Civil Police of Minas Gerais, and the Superintendência de Polícia Técnico Científica da Polícia Civil de Minas Gerais.

Authors' contributions

Yara Vieira Lemos, Adriana Zatti Lima, Melina Calmon Silva and Eugénia Cunha had the idea for the article; Yara Vieira Lemos, Melina Calmon Silva and Eugénia Cunha performed the literature search; Yara Vieira

Lemos, Lorena de Oliveira Couto and Giovanna Hooper Bittencourt participated in its design and coordination and drafted the manuscript. Yara Vieira Lemos, Luciene Menrique Corradi, Alexander Santos Dionísio and Márcio Alberto Cardoso performed the forensic evaluation, study and analysis. Lorena de Oliveira Couto and Adriana Zatti Lima drafted the figures; Lorena de Oliveira Couto and Giovanna Hooper Bittencourt drafted the references. Yara Vieira Lemos, Eugénia Cunha, Márcio Alberto Cardoso, Luciene Menrique Corradi, Alexander Santos Dionísio, Adriana Zatti Lima and Melina Calmon Silva critically revised the work. All authors contributed, revised, and approved the final version of this manuscript.

Compliance with ethical standards

All procedures performed in this study involving human participants were conducted in accordance with the ethical standards of the institutional ethics committee and the 1964 Declaration of Helsinki and its later amendments or comparable ethical standards. This work was approved by the Research Ethics Committee of the Faculty of Medical Sciences of Minas Gerais (Approval No. 4.407.412) and the consent form and free informed consent were waived.


Disclosure statement

The authors have no funding sources or conflicts of interest to disclose.

ORCID

Yara Vieira Lemos  <http://orcid.org/0000-0002-7448-7195>

Eugénia Cunha  <http://orcid.org/0000-0003-2998-371X>

Giovanna Hooper Bittencourt  <http://orcid.org/0000-0001-9430-9022>

Luciene Menrique Corradi  <http://orcid.org/0000-0001-6513-3240>

Melina Calmon Silva  <http://orcid.org/0000-0002-7622-4460>

References

- [1] Mikton CR, Butchart A, Dahlberg LL, et al. Global status report on violence prevention 2014. *Am J Prev Med.* 2016;50:652–659.

- [2] Araújo EMD, Costa MDCN, Oliveira NFD, et al. Spatial distribution of mortality by homicide and social inequalities according to race/skin color in an intra-urban Brazilian space. *Rev Bras Epidemiol.* 2010;13:549–560.
- [3] Murray J, Cerqueira DRC, Kahn T. Crime and violence in Brazil: systematic review of time trends, prevalence rates and risk factors. *Aggress Violent Behav.* 2013;18:471–483.
- [4] Auger N, Le Serbon E, Rasella D, et al. Impact of homicide and traffic crashes on life expectancy in the largest Latin American country. *J Public Health (Oxf).* 2016;38:467–473.
- [5] Cerqueira D, Lima RSD, Bueno S, et al. Atlas da violência 2017 [2017 atlas of violence]. Rio de Janeiro (Brazil): IPEA e FBSP; 2017. Available from: http://repositorio.ipea.gov.br/bitstream/11058/7956/1/Atlas%20da%20viol%C3%Aancia_2017.pdf. Portuguese.
- [6] Lemos YV, Wainstein AJA, Savoi LM, et al. Epidemiological and toxicological profile of homicide victims in a legal medicine unit in Brazil. *J Forensic Leg Med.* 2019;65:55–60.
- [7] Durão C, Machado MP, Júnior ED. Death in the “microwave oven”: a form of execution by carbonization. *Forensic Sci Int.* 2015;253:1–3.
- [8] Jaguaribe B, Rogério R. The violence of the real: a conversation with Rogério Reis. *Public Culture.* 2009;21:229–233.
- [9] Coelho HA, Rezende EN. A responsabilidade civil ambiental na Inglaterra [Environmental liability in England]. *RDUNISC.* 2016;1:167–186. Portuguese.
- [10] Criminal code. Article 121 decree law 2848/40. Brazil: Criminal Code; 1940. Available from: <https://legislacao.presidencia.gov.br/atos/?tipo=DEL&numero=2848&ano=1940&ato=1bb0za61ENNRkTf8b>. Portuguese.
- [11] Montenegro JB, Leal JLF, Cruz DB, et al. Perícia nas vítimas de carbonização [Medical examination in carbonized victims]. *Derecho y Cambio Social.* 2013;10:29. Portuguese.
- [12] Eckert WG, James S, Katchis S. Investigation of cremations and severely burned bodies. *Am J Forensic Med Pathol.* 1988;9:188–200.
- [13] Glassman DM, Crow RM. Standardization model for describing the extent of burn injury to human remains. *J Forensic Sci.* 1996;41:152–154.
- [14] Nomoyi N, Schurink W. An exploratory study of insider accounts of necklacing in three Port Elizabeth townships. In: Bornman E, van Eeden R, Wentzel M, editors. *Violence in South Africa: a variety of perspectives.* Pretoria: HSRC. 1998. p. 147–174.
- [15] Symes SA, L’Abbé EN, Pokines JT, et al. Thermal alteration to bone. In: Pokines J, Symes SA, editors. *Manual of forensic taphonomy.* 1st ed. Boca Raton (FL): CRC Press; 2013. p. 367–402.
- [16] Brooks S, Suchey J. Skeletal age determination based on the os pubis: a comparison of the Acsádi-Nemeskéri and Suchey-Brooks methods. *Hum Evol.* 1990;5:227–238.
- [17] Baccino E, Sinfield L, Colomb S, et al. Technical note: the two step procedure (TSP) for the determination of age at death of adult human remains in forensic cases. *Forensic Sci Int.* 2014;244:247–251.
- [18] Steele DG. Estimation of stature from fragments of long limb bones. In: Stewart TD, editor. *Personal identification in mass disasters.* Washington, DC: Smithsonian Institution Press. 1970. p. 85–97.
- [19] de Mendonça MC. Estimation of height from the length of long bones in a Portuguese adult population. *American J Phys Anthropol.* 2000;112:39–48.
- [20] Cunha E. Devolvendo a identidade: a antropologia forense no Brasil [Returning identity: the forensic anthropology in Brazil]. *Cienc Cult.* 2019;71:30–34. Portuguese.
- [21] Ubelaker DH, Shamlou A, Kunkle A. Contributions of forensic anthropology to positive scientific identification: a critical review. *Forensic Sci Res.* 2019;4:45–50.