



Electrocautery Incisional Therapy for Refractory Anastomotic Stricture in a Child: Report from Ahvaz, Iran

Hazhir Javaherizadeh^{1*}, Marjaneh Khalighi², Shahnam Askarpour³, Afshin Rezazadeh⁴

¹ Alimentary Tract Research Center, Clinical Sciences Research Institute, Ahvaz Jundishapur University of Medical Sciences, Ahvaz, Iran

² Department of Pediatric Gastroenterology, Abuzar Children's Hospital, Ahvaz Jundishapur University of Medical Sciences, Ahvaz, Iran

³ Department of Pediatric Surgery, Abuzar Children's Hospital, Ahvaz Jundishapur University of Medical Sciences, Ahvaz, Iran

⁴ Department of Pediatric Radiology, Abuzar Children's Hospital, Ahvaz Jundishapur University of Medical Sciences, Ahvaz, Iran

ABSTRACT

Endoscopic electrocautery incisional therapy (EIT) is one of the methods for the treatment of refractory esophageal stricture among adult cases. There are few reports among children. Herein we report the successful use of EIT for a 13-year-old boy with an anastomotic stricture who was visited in our hospital due to poor feeding and inability to feed. The boy had undergone gastric resection due to gastric necrosis. This is the first report of electrocautery surgery using a needle knife for the treatment of benign esophageal stricture in our country.

Please cite this paper as:

Javaherizadeh H, Khalighi M, Askarpour S, Rezazadeh A. Electrocautery incisional therapy for refractory anastomotic stricture in a child: report from ahvaz, iran. *Middle East J Dig Dis* 2022;14(2):258-260. doi: 10.34172/mejdd.2022.281.

INTRODUCTION

Esophageal stenosis had several causes including caustic ingestion, esophageal atresia, and other congenital anomaly.¹ Several methods including balloon dilation and Savary dilator were used more frequently in the treatment of esophageal stenosis.^{2,3} Endoscopic electrocautery incisional therapy (EIT) is the method that is recommended for refractory esophageal stricture especially anastomotic stricture. We discuss the first report of endoscopic electrocautery surgery for the child with refractory anastomotic stricture.

CASE REPORT

A 13-year-old boy with esophagojejunostomy after total gastrectomy was visited due to weight loss and dysphagia. The patient had undergone total gastrectomy and Roux-en-Y esophagojejunostomy due to gastric necrosis. Barium swallow was requested (Figure 1). A severe anastomotic stricture was seen. Three sessions of esophageal dilatation with Savary dilator number 33-39 French and balloon number 18-20 French were done. There was no good response, and dysphagia to solid food persisted (Figure 2). As a result, we decided to perform EIT for the treatment of benign anastomotic stricture. EIT was used for the patient (Figure 3 and 4). An electrosurgical knife (Endo-Flex, Germany) was used in the procedure. An incision was made at four quadrants of anastomotic stricture. 40-watt cut and coagulation features were used.

An endoscope was passed through the stricture till the duodenum

*Corresponding Author:

Hazhir Javaherizadeh, MD
Alimentary Tract Research Center,
Clinical Sciences Research Institute,
Ahvaz Jundishapur University of Medical
Sciences, Ahvaz, Iran
Tel : + 98 61 34443051
Fax : + 98 61 34443051
Email: hazhirja@yahoo.com

Received: 21 Jul. 2021
Accepted: 10 Jan. 2022
Published: 30 Apr. 2022



© 2022 The Author(s). This work is published by Middle East Journal of Digestive Diseases as an open access article distributed under the terms of the Creative Commons Attribution License (<https://creativecommons.org/licenses/by-nc/4.0/>). Non-commercial uses of the work are permitted, provided the original work is properly cited.

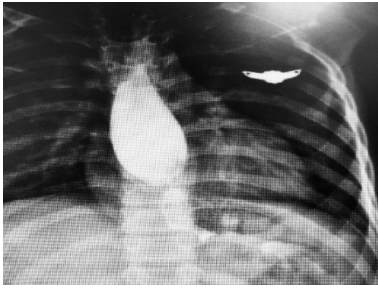


Fig. 1: Severe anastomotic stricture was seen in gastrografin swallow. Prestenotic dilatation was seen .

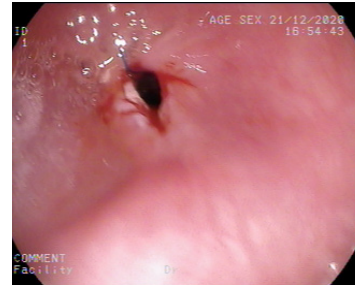


Fig. 4: The incision was made using electroknife at four quadrants of anastomotic stricture .

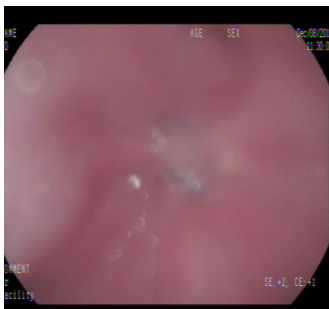

Fig. 2. Endoscopic view of severe esophageal stenosis was seen.

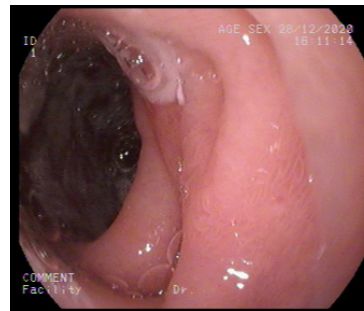


Fig. 5: Endoscope passed till duodenum after EIT.

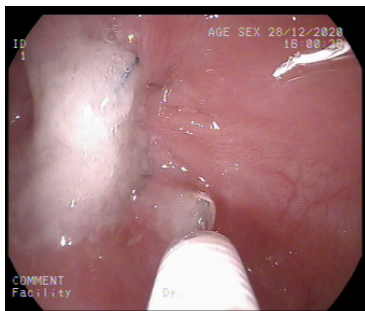


Fig. 3: Electroknife was seen in the figure .

(Figure 5). In the follow-up, the patient showed a good response. No complication was recorded during the 1-year follow-up.

DISCUSSION

Esophageal stricture is a rare condition among pediatric patients but is difficult to treat. Esophageal stricture has some causes, including repaired esophageal atresia, caustic ingestion , and anastomotic stricture due to other causes.^{1,4} According to a literature search in PubMed, there are few reports of EIT among children. Our report is maybe the first report of endoscopic incisional therapy among children in our country. The first use of incisional therapy was described for Schatzki ring and esophageal stenosis with an unknown origin.⁵

Electrocautery was used for the treatment of refractory anastomotic stricture in a few studies.⁶

There is no agreement in pediatric gastroenterology about refractory esophageal strictures. Manfredi and colleagues recommended a definition of refractory stricture according to esophageal lumen by different ages.⁷ EIT was recommended as the treatment for refractory esophageal strictures.

Manfredi and colleagues used a 100-watt electrocautery setting for the treatment.⁶ In the study by Tan and others, 50-60 cut features were used for EIT. But we used 40 watts to avoid complications. ⁸ Our case showed a good response to this setting.

EIT was recommended as the first treatment modality for anastomotic stricture after esophagojejunostomy stricture compared with balloon dilatation because EIT had a lower rate of recurrences.⁹ EIT had a limitation in the treatment of long and angulated stricture and increased the risk of perforation.¹⁰

In a case report by Chao and co-workers, endoscopic electrocauterization and balloon dilatation showed a more favorable response than balloon dilatation for a child with dysphagia due to congenital esophageal web.¹¹ In the study by Yasuda and colleagues, EIT in addition to other endoscopic methods might avoid

surgery in congenital esophageal stenosis.¹²

Our patient had severe dysphagia. We used EIT for this child. A good response was seen. Dysphagia to solid food was resolved. It seems that EIT may help the patients with refractory esophageal stenosis, and is recommended before surgical intervention.

No complication was seen following EIT in our patient. In the study by Manfredi and colleagues, the overall adverse events were seen in 5.3% of cases, but the surgical intervention was not required.⁷ A major adverse event was seen in 2.3% of the cases.⁷

Limitation

Due to technical limitations, our system cannot record video files.

ACKNOWLEDGMENTS

We thank the personnel of the endoscopy unit.

ETHICAL APPROVAL

Informed consent was obtained from the parents of the patient for publication of this report .

CONFLICT OF INTEREST

The authors declare no conflict of interest related to this work.

REFERENCES

- Honar N, Haghghat M, Mahmoodi S, Javaherizadeh H, Kalvandi G, Salimi M. Caustic ingestion in children in south of Iran. Retrospective study from Shiraz-Iran. *Rev Gastroenterol Peru* 2017;37(1):22-5.
- Ahmadi M, Manzari-Tavakoli M, Javaherizadeh H, Hakimzadeh M, Mirkarimi M, Sharhani A. Efficacy of endoscopic balloon dilation in Iranian pediatric patients with esophageal stricture. *Arq Gastroenterol* 2021;58(4):520-4. doi: [10.1590/s0004-2803.202100000-93](https://doi.org/10.1590/s0004-2803.202100000-93)
- Dehghani SM, Honar N, Sehat M, Javaherizadeh H, Shahramian I, Kalvandi G, et al. Complications after endoscopic balloon dilatation of esophageal strictures in children. Experience from a tertiary center in Shiraz-Iran (Nemazee Teaching Hospital). *Rev Gastroenterol Peru* 2019;39(1):7-11.
- Askarpour S, Ostadian N, Peyvaste M, Alavi M, Javaherizadeh H. End-to-end versus end-to-side anastomosis in the treatment of esophageal atresia or tracheo-esophageal fistula. *Arq Bras Cir Dig* 2016;29(1):48-9. doi: [10.1590/0102-6720201600010012](https://doi.org/10.1590/0102-6720201600010012)
- Raskin JB, Manten H, Harary A, Redlhammer DE, Rogers AI. Transendoscopic electrosurgical incision of lower esophageal (Schatzki) rings: a new treatment modality. *Gastrointest Endosc* 1985;31(6):391-3. doi: [10.1016/s0016-5107\(85\)72257-2](https://doi.org/10.1016/s0016-5107(85)72257-2)
- Hordijk ML, Siersema PD, Tilanus HW, Kuipers EJ. Electrocautery therapy for refractory anastomotic strictures of the esophagus. *Gastrointest Endosc* 2006;63(1):157-63. doi: [10.1016/j.gie.2005.06.016](https://doi.org/10.1016/j.gie.2005.06.016)
- Manfredi MA, Clark SJ, Medford S, Staffa SJ, Ngo PD, Hamilton TE, et al. Endoscopic electrocautery incisional therapy as a treatment for refractory benign pediatric esophageal strictures. *J Pediatr Gastroenterol Nutr* 2018;67(4):464-8. doi: [10.1097/mpg.0000000000002008](https://doi.org/10.1097/mpg.0000000000002008)
- Tan Y, Zhang J, Zhou J, Duan T, Liu D. Endoscopic incision for the treatment of refractory esophageal anastomotic strictures in children. *J Pediatr Gastroenterol Nutr* 2015;61(3):319-22. doi: [10.1097/mpg.0000000000000801](https://doi.org/10.1097/mpg.0000000000000801)
- Pih GY, Kim DH, Na HK, Ahn JY, Lee JH, Jung KW, et al. Comparison of the efficacy and safety of endoscopic incisional therapy and balloon dilatation for esophageal anastomotic stricture. *J Gastrointest Surg* 2021;25(7):1690-5. doi: [10.1007/s11605-020-04811-3](https://doi.org/10.1007/s11605-020-04811-3)
- Mark J, Narkewicz MR. Cutting-edge treatment for benign pediatric esophageal strictures, a step forward, more to go. *J Pediatr Gastroenterol Nutr* 2018;67(4):433-4. doi: [10.1097/mpg.0000000000002009](https://doi.org/10.1097/mpg.0000000000002009)
- Chao HC, Chen SY, Kong MS. Successful treatment of congenital esophageal web by endoscopic electrocauterization and balloon dilatation. *J Pediatr Surg* 2008;43(1):e13-5. doi: [10.1016/j.jpedsurg.2007.08.059](https://doi.org/10.1016/j.jpedsurg.2007.08.059)
- Yasuda JL, Staffa SJ, Clark SJ, Ngo PD, Zendejas B, Hamilton TE, et al. Endoscopic incisional therapy and other novel strategies for effective treatment of congenital esophageal stenosis. *J Pediatr Surg* 2020;55(11):2342-7. doi: [10.1016/j.jpedsurg.2020.01.013](https://doi.org/10.1016/j.jpedsurg.2020.01.013)